

**REVIEW OF ROLE OF TELOMERASE IN THE
MANAGEMENT OF AGE-RELATED MACULAR
DEGENERATION**

ABSTRACT

INTRODUCTION: Age related macular degeneration is degenerative disorder which is more prevalent in the Western developed countries but can become a major threat in India as well. It affects the macula and leads to the senescence of retinal pigment epithelium. Most commonly affected is the central vision as macula is involved in central vision. On Optical Coherence Tomography (OCT) reduction in retinal epithelium can be seen along with accumulation of blood in the sub retinal space due to haemorrhage in the wet type of ARMD. It is a multifactorial disease and some of the major risk factors of this disease include sunlight exposure i.e. production of large amounts of reactive oxygen species (ROS), smoking, blue iris etc. It is more commonly seen in females and in Caucasians. It is of two major types which include the dry type (85%) and the remaining wet type. Wet type is characterised by neovascularisation whereas the dry type shown the presence of drusens and hyperpigmentation of the retina on examination. Clinical features of this disease include gradual loss of vision, but in wet type due to fragile vessels there occurs haemorrhage which can lead to sudden loss of vision. ARMD can be prevented by introduction of telomerase in the treatment line. Telomerases help in increasing the life span of RPE, thereby delaying the senescence of the retinal cells. Other treatment modalities also include the administration of lutein, zeaxanthine, various antioxidants and anti-VEGF (vascular endothelium growth factor) medication. All these measures together can help in reducing the number of cases of ARMD and providing a better vision to the older population to increase the quality of life.

METHODOLOGY: The data were collected from various electronic databases which include PubMed, Google Scholar, Elsevier, etc.

KEYWORDS: ARMD, telomerase, retinal epithelium cells, carotenoids, macular degeneration.

INTRODUCTION:

One of the leading and the most important causes of diminution of vision in people over 60 years of age in the developed nations is macular degeneration due to aging. It is more common in the developing world due to various risk factors which are prevalent in the western world. The incidence of early macular degeneration due to aging in India is similar to that of the Western

population, but grade 3 appears to be on the lower side when compared to other grades. The prevalence of grade 4 macular degeneration due to aging (last stage) in people over 60 years is comparable to that in Western populations. It is likely that the prevalence in people aged 80 and up is understated(1). Therefore, with passage of time, macular degeneration due to aging might become a major issue in India as well. Prevention of such a disease can help to preserve the vision of millions of old age people. Increase in the number of treatment modalities and also increase in prophylactic measures can play a major role in reducing the incidence of the disease.

TYPES OF AGE RELATED MACULAR DEGENERATION

Macular degeneration due to aging occurs when a portion of retina called macula which provides central vision wears down. ARMD is a disease associated with various factors like impaired regulation of the complement, lipid, angiogenic, inflammatory pathways. Numerous genetic loci which are susceptible have been implicated, with the CFH and ARMS2 genes being the most important(2). There are two major types of macular degeneration due to aging which include the dry type (non-exudative) and the wet type (exudative), former being more common. In dry type of macular degeneration due to aging the macula becomes thin with age. Dry AMD occurs in three stages:- early, intermediate, late. In late and intermediate type of dry ARMD, one can see formation of drusens and hyperpigmentation of retinal pigment epithelium (RPE). Dry age related macular degeneration patients progress to wet age related macular degeneration. In wet ARMD the transparent and fragile retinal blood vessels start leaking leading to haemorrhage(3). Wet age related macular degeneration can be distinguished from dry age related macular degeneration by the formation of an abnormal choroidal neovascularisation (CNV) which then leads to formation of choroidal neovascular membrane of the macula which may be present in the sub-retinal space or sub-retinal epithelium space and is prone to leakage or haemorrhage due to its fragility beneath the retina in the sub-retinal space, resulting in retinal scarring and sudden vision loss(4). Wet macular degeneration due to aging (ARMD) therefore, progresses faster when compared to dry type of macular degeneration due to aging (ARMD). Wet macular degeneration due to aging is therefore a vascular disease and inhibitors of VEGF (vascular endothelial growth factor) could help in its treatment(5).

ASSOCIATED RISK FACTORS

There are various risk factors associated with age macular degeneration due to aging which include the following age more than 50 years, smoking, UV light exposure, poor nutrition, lack of exercise, hereditary, blue iris, female gender, hyperopia etc. Exposure to UV radiations is more common in the people who work outdoors and hence, the rural population might be at risk of developing ARMD.

Fovea present in retina has a yellow pigmentation which is majorly composed of carotenoids which include lutein and zeaxanthine. Smoking leads to decrease in the level of these carotenoids and reduction in the Macular Pigment optical density (MP) which acts as an antioxidant and plays a major role in protecting macula from actinic damage(6).

Most of these risk factors are preventable and therefore preventing their occurrence can lead to decreased incidence of macular degeneration due to aging (ARMD). Cessation of smoking helps

in preventing the onset of disease. Although the exact origin of ARMD is unknown, damage to the retinal pigment epithelium (RPE) due to oxidative stress is thought to be an early event in age related macular degeneration induction(7).

PATHOGENESIS

The pigment epithelium of retina is a specialised part of the retina which interacts with photoreceptors present above it and the Bruch's membrane on the basal side. The RPE ages with time leading to decrease in visual acuity. Eventually this epithelium dies due to aging leading to loss of central vision as it majorly involves the macula. Macular degeneration does not lead to complete blindness as macula is associated only for central vision, peripheral vision is spared and is therefore unaffected. DNA damage response, autophagy, and cell senescence can all be induced by oxidative stress, which is a major contributor in macular degeneration due to aging (ARMD) pathogenesis (5). Therefore, this oxidative stress can be prevented by the action of certain antioxidants. Antioxidants may be useful in reducing the combined effects of oxidative stress in RPE cells by preventing telomere shortening(8). Carotenoids like lutein and zeaxanthine are abundant in the macula and play a protective role. Therefore, deficiency of any one of the two macular carotenoids might lead to the development of the disease(9). Because there is no treatment for the degenerative processes itself, a large proportion of ARMD patients eventually develop blindness or severe vision impairment (4). Dry ARMD does not involve fragile vessels. But, dry ARMD may proceed to wet ARMD. In wet ARMD, the vessels become fragile and as the retinal pigment epithelium becomes dysfunctional, these vessels enter the sub-retinal space and start bleeding leading to haemorrhage. Most of the studies suggest that oxidative stress due to ROS and aging or senescence of the cells play the most significant role in the pathogenesis of most of the age related disorders(10).

CLINICAL FEATURES

The clinical features include the following major symptoms gradual progressive diminution of vision which is commonly seen in dry or atrophic macular degeneration due to aging (ARMD). Some of the most common visual complaints include central visual field loss which usually appears as shadowed areas in the field of vision of the patient. This is central vision loss as the macula is involved which is concerned majorly with central vision. Amsler grid can be used in the patients to detect metamorphopsia (the shape of objects appear distorted). In Amsler's grid, a patient with age related macular degeneration (ARMD) perceives the straight lines of the grid as wavy lines. Therefore, the patient might come with the complaint that the straight wall appears wavy to him. In wet age related macular degeneration (ARMD) as with time haemorrhage occurs therefore, patient might complain of sudden painless loss of vision. Drusen and pigment abnormalities can be visualised in retina when examined. Pigment epithelium detachment (PED) can also be seen on examination. On Fundus fluorescein angiography (FFA) the dye collects in the macula suggesting some pathology. Optical Coherence Tomography (OCT) may also show collection of blood in the sub-retinal space suggestive of wet type of age related macular degeneration. All these signs and symptoms point towards the most probable diagnosis being ARMD. Following diagnosis treatment depends on the type of age related macular degeneration (ARMD).

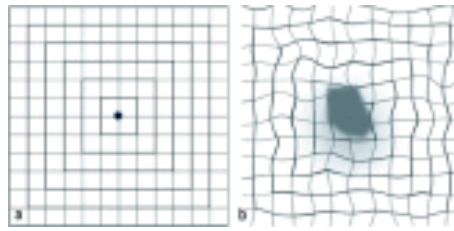


Fig: 1- Amsler's grid in a patient having ARMD when compared to a normal patient. Normal person can see straight lines and boxes whereas a person having age related macular degeneration (ARMD) would perceive those lines as curved lines. The grid would appear wavy to a patient having ARMD(11). Therefore, one of the major complaint that the patient comes with is that he perceives a straight wall as a wavy one or an irregular one.

ROLE OF TELOMERASE

Retinal pigment epithelium (RPE) cells are somatic cells which undergo only a definitive or limited number of divisions and then eventually proceed to irreversible arrest which is known as senescence(12). Telomerases can therefore play an important role in preventing age related macular degeneration by prolonging the life of retinal pigment epithelium (RPE) cells by delaying the process of senescence. Telomeres are protein-DNA complexes with the 50-TTAGGG-30 repeating sequence pattern, which are mostly single-stranded. They protect the chromosome ends against degradation, but they get shorter with each cycle of DNA replication. Telomere attrition may be linked to the retina's high metabolic rate which accounts for its maximum use of oxygen and hence, release of large quantities of ROS. Telomeres are susceptible to oxidative damage due to their high guanine concentration, yet their complex structure prevents DNA repair proteins from reaching the site of damage. Senescence is induced by telomeres that are critically short or defective, and it plays a pivotal role in pathogenesis of macular degeneration due to aging (3). According to a study conducted, the length of telomere is longest in neural retina in the eye whereas the length of telomeres in retinal pigment epithelium is shorter (around four times) than that of the neural retina making it more susceptible to aging(13). A small study was conducted in which 38 patients were randomly given TA (telomerase activator)-65 or placebo orally for a year. After a year the macular function showed improvement in the patients receiving TA-65 when compared to the controls receiving placebo(14). TA-65 prolongs the activity of telomerase thereby increasing the life of telomeres present in RPE. Through mTORC1 suppression, telomerase can stimulate autophagy, which may help to delay ageing of various cells and hence, plays a pivotal role in delaying age related disorders including ARMD(3).

Various studies that were conducted earlier show that telomerase plays a significant role in preventing neurodegenerative disorder. One of the main mechanisms of Alzheimer's disease and Parkinsonism is cell senescence. This aging process can be prevented with the use of telomerases. Telomerase reverse transcriptase (TERT) has been shown to exert a protective role on cellular aging and therefore neurodegenerative disorders(15). Similarly telomerase might have the potential to prevent aging of retinal pigment epithelium cells. It could help prolong the life of the aging cells and hence, the vision of the patient.

When human brain and bovine retinal micro-vascular endothelial cells (HBECs) were lysated or co-cultured with human telomerase reverse transcriptase (hTERT), the adults HBECs were able to cross the first checkpoint of mortality but not the second one. Therefore, it can be concluded from the study or experiment that hTERT was able to prolong or increase the life span of the endothelial cells but cannot immortalise them(16). hTERT has the ability to interact with various different proteins including autophagy regulators which are responsible for age related macular degeneration pathogenesis(17).

Mitochondrial metabolism is regulated by various regulators including peroxisome proliferator-activated receptor γ coactivator 1 (PGC1)(18). One of the major functions of this regulator is to remove the harmful reactive oxygen species (ROS)(18). It helps in increasing mitochondrial function and also aids removal of the harmful by-products of mitochondrial metabolism like ROS(3). Therefore, mitochondrial metabolism leads to a large production of ROS which can severely damage RPE(18). Up regulation of PGC-1 by various agents resulted in over expression of its related transcriptional factors, antioxidants, and mitochondrial genes, according to Saint-Geniez's research which in turn prolongs or increases the life of retinal cells(19).

Some of the studies suggest that the use of pluripotent stem cells (PSC) could be useful in the treatment of retinal disorders(20-25). Pluripotent stem cells transplantation could therefore in near future help in treatment of retinal diseases including age related macular degeneration (ARMD)(20).

Therefore, telomerase could play a very crucial role in the treatment of age related macular degeneration (ARMD) as it might prolong the life of telomeres. It could help to increase the life span of retinal pigment epithelium hence, improving the vision of the patient. It has shown to play a crucial role in various neurodegenerative disorders. Therefore, it has the potential to treat age related macular degeneration as well.

Wet type of age related macular degeneration which occurs majorly due to neo-vascularisation can be treated by anti-VEGF medications like Bevacizumab, Ranibizumab, Aflibercept, Brolucizumab. Dry type of age related macular degeneration accounts for around 85% of all ARMD cases, has few treatment options, which include antioxidant, vitamin, and mineral supplements in the diet(4). Antioxidants like melatonin has shown to have beneficial effects on retinal pigment epithelium (RPE). According to a clinical trial, for three months, age related macular degeneration patients were given 3 mg of melatonin by oral route every night before bedtime which helped in reducing macular damage and hence preventing ARMD(8). Therefore, in such cases where not much treatment options are available, telomerase therapy or treatment could help in reducing the incidence of the disease. Also the use of other alternatives like melatonin, antioxidants and various other carotenoids like lutein and zeaxanthine could prove to be useful and efficient in the treatment of ARMD.

DISCUSSION

After referring and viewing various articles on role of telomerase therapy in age related macular degeneration from sources like PubMed, Elsevier, Google Scholar etc, it can be stated that telomerase could play a major role in preventing age related macular degeneration by delaying aging of RPE cells. It can also be concluded on the basis of various researches that antioxidants and carotenoid pigments like lutein and zeaxanthine are very useful and effective in the

treatment of macular degeneration due to aging. Orally administered drugs like TA-65 can help prolong the life of retinal pigment epithelium. Reducing exposure to UV rays and cessation of smoking could help delay the development of age related macular degeneration. Various treatment modalities available in the present time include anti-VEGF medications like Bevacizumab, Ranibizumab, Aflibercept, Brolucizumab for wet type of age related macular degeneration. Use of melatonin has also been found to be effective.

CONCLUSION

Telomeres decrease in size with increasing age of the cell. Hence, short telomeres are linked with a large number of age-related or degenerative disorders. Telomerases can help maintain the size of the telomere thereby increasing the life span of the cell but it cannot immortalise it. As mentioned earlier orally administered drugs like TA-65 can help prolong the life of retinal pigment epithelium. Various other regulators like PGC-1 help in the reduction of various harmful by-products including reactive oxygen species and also aids in the better functioning of mitochondria. According to studies on endogenous telomerase, active telomerase in retinal pigment epithelium cells may postpone degenerative changes in the retinal pigment epithelium without turning into malignancy. Macular carotenoids like lutein and zeaxanthin can reduce the risk of retinal pigment epithelium aging. In a randomised clinical trial, some of the subjects displayed decrease in the incidence of retinopathies of prematurity who were supplemented with carotenoids. Various antioxidants can also help in reducing the incidence of the disease. Age related macular degeneration can hence be prevented by various methods and the burden of the disease can be reduced. Telomerase can bring about a major change in the treatment line of the disease. It could help increase the life span of various aging cells and hence, has a great potential in treating age related diseases or degenerative diseases. Prevention of various risk factors already mentioned can significantly reduce the incidence of age related macular degeneration. Cessation of smoking plays the major role in reducing the number of cases as it would prevent the exposure to the major risk factor. Primary prevention which includes prevention of exposure to various risk factors of the disease plays a major role in prevention of any disease. Therefore, preventing exposure to various risk factors associated with macular degeneration due to aging can reduce its incidence.

REFERENCES:

1. Krishnan T, Ravindran RD, Murthy GVS, Vashist P, Fitzpatrick KE, Thulasiraj RD, et al. Prevalence of Early and Late Age-Related Macular Degeneration in India: The INDEYE Study. *Invest Ophthalmol Vis Sci.* 2010 Feb;51(2):701–7.
2. Mitchell P, Liew G, Gopinath B, Wong TY. Age-related macular degeneration. *Lancet Lond Engl.* 2018 Sep 29;392(10153):1147–59.
3. Blasiak J, Szczepanska J, Fila M, Pawlowska E, Kaarniranta K. Potential of Telomerase in Age-Related Macular Degeneration-Involvement of Senescence, DNA Damage Response and Autophagy and a Key Role of PGC-1 α . *Int J Mol Sci.* 2021 Jul 3;22(13):7194.

4. Lee KS, Lin S, Copland DA, Dick AD, Liu J. Cellular senescence in the aging retina and developments of senotherapies for age-related macular degeneration. *J Neuroinflammation*. 2021 Jan 22;18(1):32.
5. Yeo NJY, Chan EJJ, Cheung C. Choroidal Neovascularization: Mechanisms of Endothelial Dysfunction. *Front Pharmacol*. 2019;10:1363.
6. Hammond BR, Wooten BR, Snodderly DM. Cigarette smoking and retinal carotenoids: implications for age-related macular degeneration. *Vision Res*. 1996 Sep;36(18):3003–9.
7. Kaarniranta K, Pawlowska E, Szczepanska J, Jablkowska A, Blasiak J. Role of Mitochondrial DNA Damage in ROS-Mediated Pathogenesis of Age-Related Macular Degeneration (AMD). *Int J Mol Sci*. 2019 Jan;20(10):2374.
8. Rastmanesh R. Potential of melatonin to treat or prevent age-related macular degeneration through stimulation of telomerase activity. *Med Hypotheses*. 2011 Jan 1;76(1):79–85.
9. Nolan JM, Stack J, O' Donovan O, Loane E, Beatty S. Risk factors for age-related maculopathy are associated with a relative lack of macular pigment. *Exp Eye Res*. 2007 Jan;84(1):61–74.
10. Gong X, Rubin LP. Role of macular xanthophylls in prevention of common neovascular retinopathies: Retinopathy of prematurity and diabetic retinopathy. *Arch Biochem Biophys*. 2015 Apr 15;572:40–8.
11. Stahl A. The Diagnosis and Treatment of Age-Related Macular Degeneration. *Dtsch Arzteblatt Int*. 2020 Jul 20;117(29–30):513–20.
12. Kang MK, Park N-H. Extension of cell life span using exogenous telomerase. *Methods Mol Biol Clifton NJ*. 2007;371:151–65.
13. Drigeard Desgarnier M-C, Zinflou C, Mallet JD, Gendron SP, Méthot SJ, Rochette PJ. Telomere Length Measurement in Different Ocular Structures: A Potential Implication in Corneal Endothelium Pathogenesis. *Invest Ophthalmol Vis Sci*. 2016 Oct 21;57(13):5547–55.
14. Dow CT, Harley CB. Evaluation of an oral telomerase activator for early age-related macular degeneration - a pilot study. *Clin Ophthalmol Auckl NZ*. 2016;10:243–9.
15. Ding X, Liu X, Wang F, Wang F, Geng X. Role of Senescence and Neuroprotective Effects of Telomerase in Neurodegenerative Diseases. *Rejuvenation Res*. 2020 Apr;23(2):150–8.
16. Gu X, Zhang J, Brann DW, Yu F-SX. Brain and retinal vascular endothelial cells with extended life span established by ectopic expression of telomerase. *Invest Ophthalmol Vis Sci*. 2003 Jul;44(7):3219–25.
17. Ségal-Bendirdjian E, Geli V. Non-canonical Roles of Telomerase: Unraveling the Imbroglia. *Front Cell Dev Biol*. 2019;7:332.

18. Austin S, St-Pierre J. PGC1 α and mitochondrial metabolism – emerging concepts and relevance in ageing and neurodegenerative disorders. *J Cell Sci.* 2012 Nov 1;125(21):4963–71.
19. Satish S, Philipose H, Rosales MAB, Saint-Geniez M. Pharmaceutical Induction of PGC-1 α Promotes Retinal Pigment Epithelial Cell Metabolism and Protects against Oxidative Damage. *Oxid Med Cell Longev.* 2018 Nov 5;2018:e9248640.
20. Ahmed I, Johnston RJ, Singh MS. Pluripotent stem cell therapy for retinal diseases. *Ann Transl Med.* 2021 Aug;9(15):1279.
21. Gajbhiye, Varsha, and Yeshwant Lamture. “Minoxidil a Youth Elixir for Eyebrow Hypotrichosis.” *JOURNAL OF CLINICAL AND DIAGNOSTIC RESEARCH* 14, no. 2 (February 2020). <https://doi.org/10.7860/JCDR/2020/42801.13474>.
22. Kedia, Palak, and Bhushan Madke. “Unilateral Molluscum Contagiosum Following Eyebrow Grooming.” *JOURNAL OF CLINICAL AND DIAGNOSTIC RESEARCH* 13, no. 11 (November 2019): WD01–2. <https://doi.org/10.7860/JCDR/2019/42600.13283>.
23. Khasbage, Suwarna Dangore, and Arvind S. Bhake. “Cervical Lymphadenopathy in a Dental Patient: An Eye Opener Case Report.” *SPECIAL CARE IN DENTISTRY* 39, no. 1 (February 2019): 59–64. <https://doi.org/10.1111/scd.12336>.
24. Laad, Gaurish, Bhushan Madke, and Balkrishna Nikam. “Cirroid Aneurysm of Upper Eyelid.” *JOURNAL OF DERMATOLOGY DERMATOLOGIC SURGERY-JDDS* 23, no. 2 (December 2019): 109–10. https://doi.org/10.4103/jdds.jdds_30_19.
25. Mahatme KG, Deshmukh P, Sable P, Chakole V. Ultrasonography: The Third Eye of Anaesthesiologist. *JOURNAL OF PHARMACEUTICAL RESEARCH INTERNATIONAL.* 2021;33(37A):235–8.