

## **Case study**

### **Chemotherapy Induced Secondary Spontaneous Pneumothorax in a female with Endometrial Cancer- A Case Report**

#### **Abstract**

Endometrial cancer is one of the leading causes of death in post-menopausal women. It has significant impact on mortality and morbidity of women in the post-menopausal age group often requiring Hysterectomy along with Chemotherapy. Chemotherapy can be used to treat endometrial cancer with hematogenous metastases. Chemotherapy induced secondary pneumothorax is a rare complication. We present a case of a 68-year-old female patient with endometrial cancer who had pulmonary metastasis and was subjected to carboplatin, paclitaxel-based chemotherapy. During the fourth cycle she developed tension pneumothorax. This case highlights the importance of knowledge of life-threatening complications of chemotherapy regimens, so that the treating of physician/oncologists are ready to tackle these anticipated conditions.

Key Words: cancer, cycle, chemotherapy, endometrial

#### **Introduction**

The most prevalent gynaecological malignancy in women is endometrial cancer. Endometrial cancer accounts for over five percent of diagnosed cancers and about two percent of cancer related mortality in women worldwide<sup>(1)</sup>. In developed countries, it is the 4th most common malignant tumour in females. Genetic variables, anthropometric characteristics, lifestyle factors (e.g., cigarette smoking, alcoholism, physical inactivity, and regular diet), and clinical

disorders (e.g., diabetes, polycystic ovary) are all linked to endometrial cancer risk, according to current research. Furthermore, numerous reproductive variables that enhance continuous oestrogen stimulation, including as parity age at menarche, oral contraceptive use <sup>(2)</sup>, and breastfeeding, can raise the risk of endometrial cancer.

Individuals with stage IIIB or stage IIIC illness of any histology, as well as patients with stages IA (with myometrial invasion), IB, II, or IIIA serous or clear cell carcinoma, should consider adjuvant treatment, according to current NCCN guidelines.

Pneumothorax is the presence of air in the pleural space. The most common mechanism involved in pneumothorax are 1) communication between alveolar spaces and pleura; 2) direct or indirect communication between the atmosphere and the pleural space; or 3) presence of gas-producing organisms in the pleural space.<sup>(3,4)</sup> Secondary spontaneous pneumothorax may be caused by a variety of conditions like chronic obstructive pulmonary disease, malignancies, vasculitis, collagen vascular disorders, trauma.<sup>(5,6,7,8)</sup>

One main cause of spontaneous pneumothorax is when it occurs secondarily to malignancy, either original lung malignancy or metastasis to pulmonary tissue. Metastatic lung sarcoma<sup>(9,10)</sup> is the most common cancer that causes secondary spontaneous pneumothoraces; however, primary lung cancer<sup>(11)</sup>, renal cell carcinoma<sup>(12,)</sup>, breast malignancy<sup>(13)</sup>, thyroid neoplasms<sup>(14)</sup>, germ cell tumour, and lymphomas in the mediastinum have also been implicated in development of pneumothorax.

## Case report

A 68-year-old woman (para 2 living 2) presented to OPD with complaints of postmenopausal bleeding on & off since past 4 months; bleeding had increased from past 1 week which warranted her visit to hospital. After an initial gynaecological examination, and sonographic evaluation which suggested Endometrial thickness of 8 mm; office Biopsy was performed. Histopathology was suggestive of Poorly Differentiated Endometrioid carcinoma Grade III. We proceeded with staging laparotomy and performed Radical hysterectomy with bilateral pelvic lymph nodes dissection (BPLND). On Microscopic examination, Tumour was composed predominantly of sheets of cells. Tumour invaded more than half thickness of myometrium & serosa was free of tumour. Lymphovascular emboli were seen; though perineural space invasion was absent. Tumour invaded less than half of cervical stromal thickness. Fallopian tubes & ovaries were free of tumour. Bilateral pelvic lymph node metastasis was present. Patient was labelled as FIGO Stage III C1. ER / PR status was positive with Her 2 Neu status as negative. Post-operative chemotherapy with Carboplatin (AUC 5) & Paclitaxel ( $175 \text{ mg/m}^2$ ) was instituted and without any complications, full remission was achieved after the first three cycles of treatment. Unfortunately, a single metastatic nodule to the lungs, along with multiple nodules on both sides developed three months when she came for fourth cycle of chemotherapy. After the fourth cycle of chemotherapy was administered; She suddenly developed chest pain on right side which was severe, sharp & was radiating to ipsilateral shoulder & arm. It was also associated shortness of breath & cough.

On examination patient was tachypnic with a respiratory rate of 35 cycles/min, heart rate was 152 beats per minute, BP was 90/60 mm hg, SpO<sub>2</sub> while breathing ambient air was 78%. Respiratory system examination revealed diminished chest movements on left hemithorax,

Trachea was grossly shifted to right side, hyper resonant note was present on left hemithorax in percussion, air entry was absent on left hemithorax.

Patient was immediately given high flow oxygen 12 litres per minute through nasal cannula and an urgent x ray of chest revealed massive pneumothorax on left side with gross mediastinal shift. Immediate intercostal chest tube drainage was performed and the patient's condition stabilised.

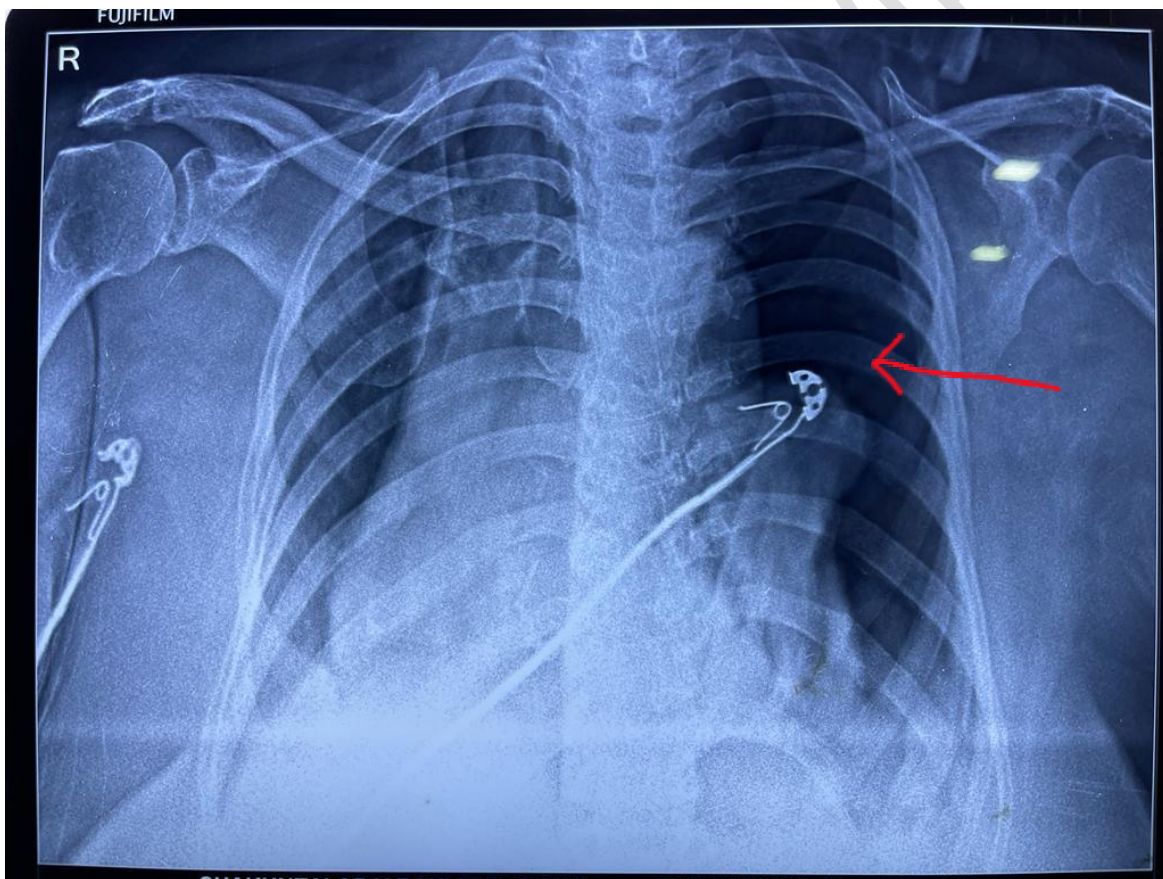


Fig 1. Chest X ray PA view showing features of left sided pneumothorax.

## Discussion

The aetiology of a spontaneous pneumothorax determines whether it is primary or secondary. The mechanism that causes primary spontaneous pneumothoraces is unknown. Secondary spontaneous pneumothoraces, on the other hand, are caused by a number of disorders that impact the airways and parenchyma. One reason for the development of spontaneous pneumothoraces is secondary to a malignancy, either original lung malignancy or metastasis to pleural or pulmonary tissue. Secondary pneumothorax is most commonly seen as a result of metastatic lung sarcoma; however, secondary spontaneous pneumothoraces have also been reported in patients with pulmonary tumours, thyroid malignancy, sex cord tumour, breast neoplasms, renal cell carcinoma, and lymphomas.

The possible mechanisms may be tumours directly damaging broncho-alveolar tissue, capillary endothelium, and the pleural tissue<sup>(15)</sup>. A second idea is that various treatment techniques, such as chemotherapy or molecular targeted therapy, produce fast shrinking of space-occupying tumours<sup>(12)</sup>. Third, molecularly targeted therapeutics, particularly gefitinib, inhibit alveolar capillary development and injure normal tissue<sup>(16)</sup>. A chemosensitive lung metastatic cancer may have decreased rapidly after successful chemotherapy in the example documented here, resulting in a spontaneous pneumothorax.

In the example documented here, a metastatic cancer of the lung which is sensitive to chemotherapy reduced rapidly in size due to successful chemotherapy resulting in spontaneous pneumothorax. The consequences of a delayed pneumothorax diagnosis are substantial and life-threatening. This could be the first

incidence of a spontaneous pneumothorax occurring after receiving paclitaxel and carboplatin for metastatic endometrial cancer treatment.

## **Conclusion**

Finally, our case provides an important and well timed assessment of the likelihood of developing endometrial carcinoma in females having (Post menopausal bleeding)PMB, and it can be used as an accurate reference for the prevalence of PMB in females with carcinoma of the endometrium, the chance of occurrence of carcinoma endometrium in those with PMB, the risk prediction for endometrial cancer, and secondary and tertiary prophylaxis in females with PMB. If new markers are identified or new clinical management strategies are attempted, our findings will aid in the assessment of their potential therapeutic significance and will improve clinical and epidemiologic risk prediction models to support clinical decision making. We should be on the alert for any pulmonary issues following chemotherapy and fast shrinking of pulmonary tumours. Spontaneous pneumothorax is an uncommon but potentially fatal situation that can strike at any time. Finally, our research provides a critical and timely assessment of endometrial cancer risk.

## References

1. Ferlay J, Soerjomataram I, Dikshit R, et al. Cancer incidence and mortality worldwide: sources, methods and major patterns in GLOBOCAN 2012. *Int J Cancer*. 2015;136(5):E359-E386. doi:10.1002/ijc.29210
2. Setiawan VW, Yang HP, Pike MC, et al; Australian National Endometrial Cancer Study Group. Type I and II endometrial cancers: have they different risk factors? *J Clin Oncol*. 2013;31(20):2607-2618. doi:10.1200/JCO.2012.48.2596
3. Noppen M, Schramel F. Pneumothorax. *Eur Respir Mon* 2002; 22: 279–296.
4. Baumann MH, Noppen M. Pneumothorax. *Respirology* 2004; 9: 157–164.
5. Acharya S, Andhale A, gupte Y, et al. Acute exacerbation of COPD triggered by pneumonia, and secondary spontaneous pneumothorax (SSP). *J. Evolution Med. Dent. Sci*. 2020;9(32):2314-2315, DOI: 10.14260/jemds/2020/501
6. Kumar S, Pawani N, Honmode A, Bawankule S, Diwan S K, Jain S. Wegener's granulomatosis presenting as spontaneous pneumothorax in young adult. *J Assoc Chest Physicians* 2014;2:75-7
7. Jain S, Kumar S, Deshmukh P, Gaurkar S. Bilateral pneumothorax: Perils of emergency tracheostomy . *J Laryngol Voice* 2014;4:36-8

8- Kumar, S., Diwan, S., Singh, A., & Koppatiwar, S. (2012). Spontaneous Pneumothorax Complicating Hemodialysis. *Journal of Medicine*, 13(1), 125.

<https://doi.org/10.3329/jom.v13i1.10094>

9..Upadya A, Amoateng-Adjepong Y, Haddad RG. Recurrent bilateral spontaneous pneumothorax complicating chemotherapy for metastatic sarcoma. *South Med J* 2003;96:821e3.

10. Kurokawa T, Morikawa T, Ohtake S, Kaji M, Sugiura H, Okushiba S, et al. Spontaneous pneumothorax secondary to radiographically occult lung metastasis from parapharyngeal synovial sarcoma: report of a case. *Surg Today* 2002;32:267e9.

11. Kryger-Baggesen N. Spontaneous pneumothorax following regression of pulmonary metastases. *Eur Respir J* 1990;3:485e6.

12.Daryanani S, Knausenberger HP, de Takats PG, Guest PJ, Kerr DJ. Spontaneous pneumothorax associated with expectoration of a lump of metastatic renal cancer. *Clin Oncol (R Coll Radiol)* 1997;9:262e3.

13. Bini A, Zompatori M, Ansaloni L, Grazia M, Stella F, Bazzocchi R. Bilateral recurrent pneumothorax complicating chemotherapy for pulmonary metastasis.

14. Kryger-Baggesen N. Spontaneous pneumothorax following regression of pulmonary metastases. *Eur Respir J* 1990;3:485e6.

15. SrinivasS,VaradhacharyG.Spontaneouspneumothoraxinmalignancy:acase report and review of the literature. *Ann Oncol* 2000;11:887e9.

16. Mori M, Nakagawa M, Fujikawa T, Iwasaki T, Kawamura T, Namba Y, et al.

Simultaneous bilateral spontaneous pneumothorax observed during the administration of

gefitinib for lung adenocarcinoma with multiple lung metastases. Intern Med 2005;44:862e4.

UNDER PEER REVIEW