

## Original Research Article

### **Evaluation of sexual dimorphism of inter condylo-coronoid process distance by digital orthopantomogram in south indian population**

#### **Running Title: Sexual dimorphism and inter condylo-coronoid distance using OPG**

##### **Abstract:**

**Background:** Sexual dimorphism is a condition where the sexes of an equivalent species exhibit different characteristics beyond the differences in their sexual organs. Sexual identification is most significant in huge fatality accidents where the body is beyond recognisable. Coronoid process is a triangular eminence, thin and flattened in size and shape. The Condylar process is the process of the mandible and it is thicker than the coronoid process.

**Aim:** To evaluate the sexual dimorphism of inter condylo-coronoid process distance by digital orthopantomogram in the south indian population.

**Materials and methods:** A total of 50 digital orthopantomogram collected from a private dental college in chennai. The distance between the condylar and the coronoid process is measured on both sides of a digital orthopantomogram using adobe photoshop. The data was analysed and observed using SPSS v23.0 and the standard deviation was calculated.

**Results:** The mean of left and right distance of inter condylo-coronoid distance is 2.45cm and 2.52cm respectively. The standard deviation of left and right distance of inter condylo-coronoid distance is 0.32cm and 0.31cm respectively.

**Conclusion:** From the results obtained, within the limitations of the study it can be concluded that there is no significant difference in the measure of distance between inter

condyle-coronoid processes in terms of age and gender. Future studies should be conducted with large samples to get conclusive results.

**Keywords:** Sexual dimorphism; orthopantomogram; coronoid process; condylar process; mandible; innovative technique.

### **Introduction:**

Determination of sex by morphological assessment has been one among the oldest approaches in forensic anthropology and medico-legal examinations. The tactic may vary and depend on the available bones and their conditions. The identification of sex is significant in cases of huge fatality accidents where bodies are destroyed beyond recognition. When entire adult skeleton is out there for analysis, sex are often determined up to 100% accuracy (Pelvis)(1). But in cases of mass disasters where usually fragmented bones are found, sex determination with 100% accuracy isn't possible and it depends largely on the available parts of skeleton. Skull is the most dimorphic and simply sexed portion of the skeleton after the pelvis (2). But in cases where intact skull isn't found, mandible may play an important role in sex determination, because it is that the most dimorphic bone of skull. Anthropometry of the intraoral regions and face can help in the field of forensic odontology when forensic data are not available (3). 'Sexual dimorphism' refers to those differences in size, stature and appearance between male and feminine which will be applied to dental identification because no two mouths are alike(4).

The term coronoid process is given to thoroughly two different structures that are found inside the physical body. The primary structure is seen within the jawbone mentioned as mandible. The opposite coronoid process is seen in ulna, an extended bone which is found within the forearm. The coronoid process of the mandible has an appearance of triangular shape(5). The mandible's coronoid process (from Greek korone, "like a crown") may be a thin, triangular eminence, which is flattened from side to side and varies in shape and size.

the method projects upwards and slightly forwards. it's a top border and it's convex in its shape, while its lower part is concave in shape.(6)

The condyle presents an articular surface for articulation with the articular disk of the temporomandibular joint; it's convex from before backward and from side to side, and extends farther on the posterior than on the anterior surface. Its long axis is directed medialward and slightly backward, and if prolonged to the center line will meet that of the other condyle near the anterior margin of the foramen. At the lateral extremity of the condyle may be a small tubercle for the attachment of the temporomandibular ligament. The articular surface of the condyle is roofed by animal tissue, and interfaces with an articular disk (or meniscus) of avascular, non-innervated animal tissue (collagen, fibroblasts). The experience from our previous studies (7) (8,9) (8)(10)(11)(12)(13)(11,13)(14)(15) (16) have led us to focus on the current topic.

Estimation of sex and hence, age and identity of remains is of significance not only in forensic Science but also in Anatomy, Forensic Odontology, Anthropology and Palaeontology(17,18). The mandible is the strong bone and large and retains the shape than other bones within the physical anthropological field and forensic. The mandible is often won't distinguish among ethnic groups and between sexes. Our team has extensive knowledge and research experience that has translate into high quality publications (19–26),(27),(28),(29),(30,31),(32),(33),(34–38) Thus the present study attempted to evaluate the sexual dimorphism of inter condylo-coronoid process distance by digital orthopantomogram in the south indian population.

### **Materials and methods:**

This is an anthropometric study conducted in a private dental college and hospital and examines 49 digital orthopantomogram of the South Indian population in Chennai. The study is approved by the institutional review board. It is a retrospective study. The distance between the coronoid process and the condylar process were measured in the digital orthopantomogram for both sides using the scale option in Adobe Photoshop and all the values were tabulated. Analysis was done using SPSS version 23. Mean and standard deviation was done for the values. Independent -t- test was done for gender comparison analysis. Panoramic radiographic images with intact teeth were included for the study. Radiographic images with missing or fractured teeth were excluded.

## Results :

In our study we found the mean of left and right distance of condylo-coronoid distance is 2.45cm and 2.52cm respectively. The current study was carried out on 49 digital orthopantomogram to determine the sex. Further analysis done by categorising it into male and female. This study includes 26 males and 23 females samples. The mean of left inter condylo-coronoid distance in male and females are 2.5cm and 2.3cm respectively with significance level of P Value < 0.08, (Fig 1). The mean of right distance in male and females are 2.5cm and 2.4cm respectively with significance level of P Value < 0.11 (Fig 2).

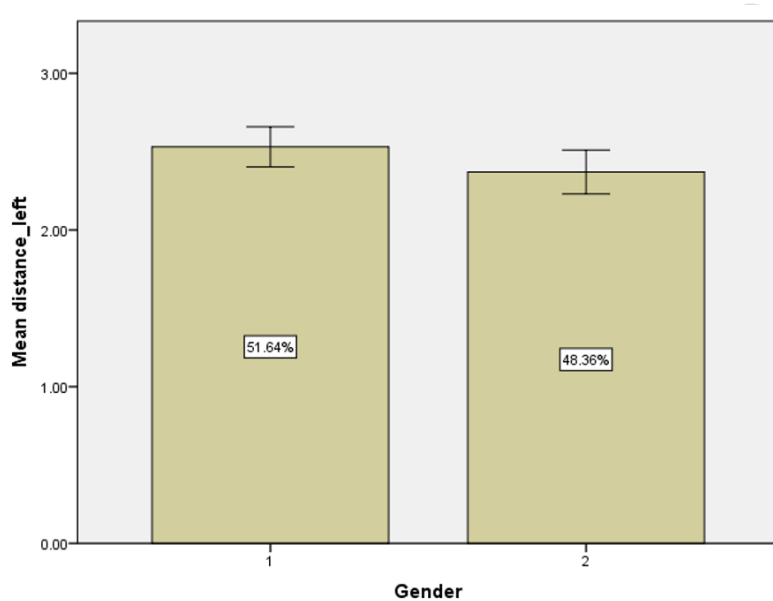


Figure 1: This graph represents the comparison analysis of mean left distance of condylo-coronoid process between Gender. In the X axis, 1 represents male and 2 represents female, Y axis represents the mean distance in centimeters. By this graph, the mean of left inter condylo-coronoid distance is higher in male compared to females, with p value < 0.08, which is not statistically significant.

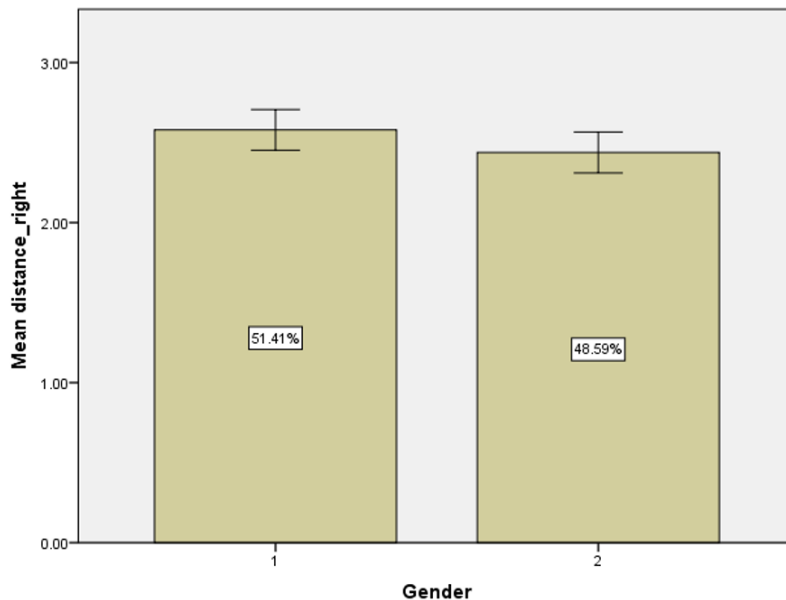


Figure 2: This graph represents the comparison analysis of mean right distance of condylo-coronoid process between Gender. In the X axis, 1 represents male and 2 represents female. Y axis, represents the mean distance in centimeters. By this graph, the mean of right inter-condylo-coronoid distance is higher in male compared to females, with p value < 0.11, which is not statistically significant.

### Discussion:

In our study we found the mean of left and right distance of condylo-coronoid distance is 2.45cm and 2.52cm respectively. In a study on Thailand population by (39), the mean values for the bicondylar diameter were 12.38 cm and 11.61 cm respectively and this was found to be significant and they concluded that it can be used in forensic for determining the gender of the population.

Tohno et al in his study reported that the mandible of the condyle region is one of the sexual dimorphic regions and it can be used in forensic cases. (40) and this is similar to our finding. In a study, conducted on sex determination by using mandible by morphometric and morphological analysis. He found that mandibles exhibit sexual dimorphism and concluded that morphometric and morphological parameters were important to find the gender of the mandible.(41) A study by sultana et al., observed 7 morphometric and 5 morphological and measured and evaluated. They found that males have higher mean values compared to females and the parameter was found to be highly significant. They concluded that adult mandible is highly significant and highly accurate in determination of sex (42).

A study Sambhana et al. by on determination of sex using digital OPG. Their study was conducted on 384 individuals and concluded that all variables of the mandible were reliable for sex determination in forensic use. (43) A study by Okkesim and sezen on determination of sex using mandibular ramus. Their study was conducted on 70 individuals and five parameters were measured and concluded that sex determination using measurement of mandibular ramus is an useful tool. The limitation of our study was the inability to find the gender of the mandible using digital orthopantomogram and larger samples were not conclusive due to limited sample size. Future research has to be conducted on a large scale in this context as it may have forensic significance in gender determination,

### **Conclusion:**

From the results obtained within the limitations of the study it can be concluded that there is no significant difference in the measure of distance between inter condyle-coronoid processes in terms of age and gender. Future studies should be conducted with large samples to get conclusive results.

### **References:**

1. Kolesova O, Větra J. Sexual dimorphism of pelvic morphology variation in live humans [Internet]. Vol. 20, Papers on Anthropology. 2012. p. 209. Available from: <http://dx.doi.org/10.12697/poa.2011.20.21>
2. Sanger TJ, Sherratt E, McGlothlin JW, Brodie ED, Losos JB, Abzhanov A. CONVERGENT EVOLUTION OF SEXUAL DIMORPHISM IN SKULL SHAPE USING DISTINCT DEVELOPMENTAL STRATEGIES [Internet]. Vol. 67, Evolution. 2013. p. 2180–93. Available from: <http://dx.doi.org/10.1111/evo.12100>
3. Sivapathasundharam B. Shafer's Textbook of Oral Pathology E-book. Elsevier Health Sciences; 2020. 868 p.
4. Kieser JA. Human Adult Odontometrics [Internet]. 1990. Available from: <http://dx.doi.org/10.1017/cbo9780511983610>
5. Hamilton WJ. Textbook of Human Anatomy. 1976. 753 p.
6. Rajasree G, Hema L. Morphological variations in the coronoid process of mandible [Internet]. Vol. 67, Journal of the Anatomical Society of India. 2018. p. S29–30. Available from: <http://dx.doi.org/10.1016/j.jasi.2018.06.012>
7. Shruthi M, Preetha S. Effect of Simple Tongue Exercises in Habitual Snorers [Internet].

Vol. 11, Research Journal of Pharmacy and Technology. 2018. p. 3614. Available from: <http://dx.doi.org/10.5958/0974-360x.2018.00665.0>

8. Preetha S, Packyanathan J. Comparison of the effect of Yoga, Zumba and Aerobics in controlling blood pressure in the Indian population [Internet]. Vol. 9, Journal of Family Medicine and Primary Care. 2020. p. 547. Available from: [http://dx.doi.org/10.4103/jfmpc.jfmpc\\_607\\_19](http://dx.doi.org/10.4103/jfmpc.jfmpc_607_19)
9. J SK, Saveetha Dental College and Hospitals, Road PH, Chennai, Tamilnadu, Preetha S, et al. Effect of aerobics exercise and yoga on blood pressure in hypertensives [Internet]. Vol. 6, International Journal of Current Advanced Research. 2017. p. 3124–6. Available from: <http://dx.doi.org/10.24327/ijcar.2017.3126.0200>
10. Prathap L, Suganthirababu P, Ganesan D. Fluctuating Asymmetry of Dermatoglyphics and DNA Polymorphism in Breast Cancer Population [Internet]. Vol. 10, Indian Journal of Public Health Research & Development. 2019. p. 3574. Available from: <http://dx.doi.org/10.5958/0976-5506.2019.04141.x>
11. Lavanya J, Prathap S, Alagesan J. Digital and palmar dermal ridge patterns in population with breast carcinoma. Biomedicine. 2014 Jul 1;34(3):315–21.
12. Prathap L, Jagadeesan V. Association of quantitative and qualitative dermatoglyphic variable and DNA polymorphism in female breast cancer population. Online J Health [Internet]. 2017; Available from: [https://www.researchgate.net/profile/Prathap\\_Suganthirababu/publication/321606278\\_Association\\_of\\_Quantitative\\_and\\_Qualitative\\_Dermatoglyphic\\_Variable\\_and\\_DNA\\_Polymorphism\\_in\\_Female\\_Breast\\_Cancer\\_Population/links/5a28c8f1a6fdcc8e8671c0cd/Association-of-Quantitative-and-Qualitative-Dermatoglyphic-Variable-and-DNA-Polymorphism-in-Female-Breast-Cancer-Population.pdf](https://www.researchgate.net/profile/Prathap_Suganthirababu/publication/321606278_Association_of_Quantitative_and_Qualitative_Dermatoglyphic_Variable_and_DNA_Polymorphism_in_Female_Breast_Cancer_Population/links/5a28c8f1a6fdcc8e8671c0cd/Association-of-Quantitative-and-Qualitative-Dermatoglyphic-Variable-and-DNA-Polymorphism-in-Female-Breast-Cancer-Population.pdf)
13. Lavanya J, Kumar VJ, Sudhakar N, Prathap S. Analysis of DNA repair genetic polymorphism in breast cancer population. Int J Pharma Bio Sci [Internet]. 2015; Available from: [https://scholar.google.ca/scholar?cluster=8949053652564257518&hl=en&as\\_sdt=0,5&sciodt=0,5](https://scholar.google.ca/scholar?cluster=8949053652564257518&hl=en&as_sdt=0,5&sciodt=0,5)
14. Prathap L, Suganthirababu P. Estrogen Exposure and its Influence in DNA Repair Genetic Variants in Breast Cancer Population [Internet]. Vol. 13, Biomedical and Pharmacology Journal. 2020. p. 1321–7. Available from: <http://dx.doi.org/10.13005/bpj/2001>
15. Ravikumar H, Prathap L, Preetha S. ANALYSIS OF PALMAR ATD ANGLE IN POPULATION WITH MALOCCLUSION. 2020 Jan 1;1174–82.
16. Prathap L. INTERPLAY OF OXIDATIVE STRESS AND LIPOPROTEINS IN BREAST CARCINOMA INITIATION, PROMOTION AND PROGRESSION -A SYSTEMATIC REVIEW. PalArch's Journal of Archaeology of Egypt/ Egyptology [Internet]. 2021 Jan 7 [cited 2021 Mar 9];17(7). Available from: <http://dx.doi.org/>
17. G V, Vinay G. Sex Determination of Human Mandible Using Metrical Parameters [Internet]. JOURNAL OF CLINICAL AND DIAGNOSTIC RESEARCH. 2013. Available from: <http://dx.doi.org/10.7860/jcdr/2013/7621.3728>
18. Jayakumar K, Ramar S, Dajah S. Sexual Dimorphism of Mandibular Canine in South Indian population [Internet]. Vol. 5, International Journal of Health and Rehabilitation Sciences (IJHRS). 2016. p. 64. Available from:

<http://dx.doi.org/10.5455/ijhrs.0000000104>

19. Sekar D, Lakshmanan G, Mani P, Biruntha M. Methylation-dependent circulating microRNA 510 in preeclampsia patients. *Hypertens Res.* 2019 Oct;42(10):1647–8.
20. Princeton B, Santhakumar P, Prathap L. Awareness on Preventive Measures taken by Health Care Professionals Attending COVID-19 Patients among Dental Students. *Eur J Dent.* 2020 Dec;14(S 01):S105–9.
21. Logeshwari R, Rama Parvathy L. Generating logistic chaotic sequence using geometric pattern to decompose and recombine the pixel values. *Multimed Tools Appl.* 2020 Aug;79(31-32):22375–88.
22. Johnson J, Lakshmanan G, M B, R M V, Kalimuthu K, Sekar D. Computational identification of MiRNA-7110 from pulmonary arterial hypertension (PAH) ESTs: a new microRNA that links diabetes and PAH. *Hypertens Res.* 2020 Apr;43(4):360–2.
23. Paramasivam A, Priyadharsini JV, Raghunandhakumar S, Elumalai P. A novel COVID-19 and its effects on cardiovascular disease. *Hypertens Res.* 2020 Jul;43(7):729–30.
24. Pujari GRS, Subramanian V, Rao SR. Effects of *Celastrus paniculatus* Willd. and *Sida cordifolia* Linn. in Kainic Acid Induced Hippocampus Damage in Rats. *Ind J Pharm Educ.* 2019 Jul 3;53(3):537–44.
25. Rajkumar KV, Lakshmanan G, Sekar D. Identification of miR-802-5p and its involvement in type 2 diabetes mellitus. *World J Diabetes.* 2020 Dec 15;11(12):567–71.
26. Ravisankar R, Jayaprakash P, Eswaran P, Mohanraj K, Vinitha G, Pichumani M. Synthesis, growth, optical and third-order nonlinear optical properties of glycine sodium nitrate single crystal for photonic device applications. *J Mater Sci: Mater Electron.* 2020 Oct;31(20):17320–31.
27. Wu S, Rajeshkumar S, Madasamy M, Mahendran V. Green synthesis of copper nanoparticles using *Cissus vitiginea* and its antioxidant and antibacterial activity against urinary tract infection pathogens. *Artif Cells Nanomed Biotechnol.* 2020 Dec;48(1):1153–8.
28. Vikneshan M, Saravanakumar R, Mangaiyarkarasi R, Rajeshkumar S, Samuel SR, Suganya M, et al. Algal biomass as a source for novel oral nano-antimicrobial agent. *Saudi J Biol Sci.* 2020 Dec;27(12):3753–8.
29. Alharbi KS, Fuloria NK, Fuloria S, Rahman SB, Al-Malki WH, Javed Shaikh MA, et al. Nuclear factor-kappa B and its role in inflammatory lung disease. *Chem Biol Interact.* 2021 Aug 25;345:109568.
30. Rao SK, Kalai Priya A, Manjunath Kamath S, Karthick P, Renganathan B, Anuraj S, et al. Unequivocal evidence of enhanced room temperature sensing properties of clad modified Nd doped mullite Bi<sub>2</sub>Fe<sub>4</sub>O<sub>9</sub> in fiber optic gas sensor [Internet]. Vol. 838, *Journal of Alloys and Compounds.* 2020. p. 155603. Available from: <http://dx.doi.org/10.1016/j.jallcom.2020.155603>
31. Bhavikatti SK, Karobari MI, Zainuddin SLA, Marya A, Nadaf SJ, Sawant VJ, et al. Investigating the Antioxidant and Cytocompatibility of *Mimusops elengi* Linn Extract over Human Gingival Fibroblast Cells. *Int J Environ Res Public Health* [Internet]. 2021 Jul 4;18(13). Available from: <http://dx.doi.org/10.3390/ijerph18137162>

32. Marya A, Karobari MI, Selvaraj S, Adil AH, Assiry AA, Rabaan AA, et al. Risk Perception of SARS-CoV-2 Infection and Implementation of Various Protective Measures by Dentists Across Various Countries. *Int J Environ Res Public Health* [Internet]. 2021 May 29;18(11). Available from: <http://dx.doi.org/10.3390/ijerph18115848>
33. Barma MD, Muthupandiyani I, Samuel SR, Amaechi BT. Inhibition of *Streptococcus mutans*, antioxidant property and cytotoxicity of novel nano-zinc oxide varnish. *Arch Oral Biol*. 2021 Jun;126:105132.
34. Vijayashree Priyadharsini J. In silico validation of the non-antibiotic drugs acetaminophen and ibuprofen as antibacterial agents against red complex pathogens. *J Periodontol*. 2019 Dec;90(12):1441–8.
35. Priyadharsini JV, Vijayashree Priyadharsini J, Smiline Girija AS, Paramasivam A. In silico analysis of virulence genes in an emerging dental pathogen *A. baumannii* and related species [Internet]. Vol. 94, *Archives of Oral Biology*. 2018. p. 93–8. Available from: <http://dx.doi.org/10.1016/j.archoralbio.2018.07.001>
36. Uma Maheswari TN, Nivedhitha MS, Ramani P. Expression profile of salivary micro RNA-21 and 31 in oral potentially malignant disorders. *Braz Oral Res*. 2020 Feb 10;34:e002.
37. Gudipani RK, Alam MK, Patil SR, Karobari MI. Measurement of the Maximum Occlusal Bite Force and its Relation to the Caries Spectrum of First Permanent Molars in Early Permanent Dentition. *J Clin Pediatr Dent*. 2020 Dec 1;44(6):423–8.
38. Chaturvedula BB, Muthukrishnan A, Bhuvanaraghavan A, Sandler J, Thiruvengkatachari B. Dens invaginatus: a review and orthodontic implications. *Br Dent J*. 2021 Mar;230(6):345–50.
39. Franklin D, Oxnard CE, O'Higgins P, Dadour I. Sexual dimorphism in the subadult mandible: quantification using geometric morphometrics. *J Forensic Sci*. 2007 Jan;52(1):6–10.
40. Tohno S, Ongkana N, Ke L, Mahakkanukrauh P, Minami T, Suwannahoy P, et al. Gender Differences in Elements of Human Anterior Commissure and Olfactory Bulb and Tract [Internet]. Vol. 137, *Biological Trace Element Research*. 2010. p. 40–8. Available from: <http://dx.doi.org/10.1007/s12011-009-8559-7>
41. Talwad R, Professor A, Department of Anatomy, KVG Medical College and Hospital, Kurunjibag, Sullia, et al. MORPHOMETRIC AND MORPHOLOGICAL STUDY OF HUMAN DRY MANDIBLE [Internet]. Vol. 4, *International Journal of Anatomy and Research*. 2016. p. 2037–40. Available from: <http://dx.doi.org/10.16965/ijar.2016.140>
42. Sultana Z, Professor A, Department of Anatomy, Shadan Institute of Medical Sciences, Hyderabad, India T 500086, et al. Sexual Dimorphism in Adult Human Mandible of South Indian Origin [Internet]. Vol. 8, *Indian Journal of Anatomy*. 2019. p. 283–8. Available from: <http://dx.doi.org/10.21088/ija.2320.0022.8419.6>
43. Sambhana S, Sanghvi P, Mohammed RB, Shanta PP, Thetay AAR, Chaudhary VS. Assessment of sexual dimorphism using digital orthopantomographs in South Indians. *J Forensic Dent Sci*. 2016 Sep;8(3):180.