

Case study

CASE REPORT ON CERVICAL DYSPLASIAS

Abstract

Introduction: - Cervical dysplasia is a precancerous disorder in which abnormal cell growth occurs on the cervix's surface lining or endocervical canal, which connects the uterus and the vaginal canal. Cervical intraepithelial neoplasia is another name for it (CIN). **Clinical finding:-** Abdominal pain, weight loss, fever (Temperature – 101°F) **Diagnostic evaluation:-** Blood test: HB- 10.8 gm%, Total RBC count- 4.15 millions/cu mm, RDW –13.1%, Total WBC count-6100 /cu mm, Total platelets- 2.381ACS/MM3 **Cytopathology Examination:-** Cervical cytology Smear shows only scattered superficial and intermediated squamous cell with few neutrophils. **Colposcopy Examination:-** moderated dysplasia, chronic cervicitis. **Colposcopy findings-** cervical erosion seen on post lip, -Mosaic pattern of blood vessels seen on green filter, Aceto white areas seen at 7o'clock position, Less iodine uptake at 7o'clock and 12o'clock positions, aceto white areas reduced as compared to previous colposcopy.

Therapeutic Intervention:- Vaginal hysterectomy lateral Sphincterotomy I/V/O Cervical Dysplasia Inj. Gentamazine 80 mg iv 12 hrly, Inj. Ctax 1 gm IV 12hrly, Inj. Pan 40 mg iv 12 hrly, Inj Metro 100 ml /8 hrs, Inj. Neomal 100 ml Iv 12 hrly, Inj Pause 8 hrly, zonac suppository TDS, Tab-Gabapentin 300 mg HS, Glucose powder, protein powder 2tbsp BD with milk. **Outcomes:-** After treatment the patient shows improvement. Her abdominal pain and fever were relived and the surgery precancerous cells are removed, Patient condition was improved. **Conclusion:-** My patient was hospitalized to AVBRH gynecology unit with abdominal pain, fever, weight loss. After receiving proper therapy, her condition has improved.

Keywords:- Cervical dysplasia, precancerous cell

Introduction:-- Cervical dysplasia is a precancerous disorder in which abnormal cell growth occurs on the cervix's surface lining or end cervical canal, which connects the uterus and the vaginal canal. Cervical intraepithelial neoplasia is another name for it (CIN).(1)

. Cervical cancer starts in the cervix, which is the lower, narrow part of the uterus. The uterus holds the growing fetus during pregnancy.(2)The cervix connects the lower part of the uterus to the vagina and, with the vagina, forms the birth canal.Cervical cancer begins when healthy cells on the surface of the cervix change or get infected with human papillomavirus (HPV) and grow out of control, forming a mass called a tumor. (3)Long-term infection of HPV on the cervix can result in cancer, leading to a mass or tumour on the cervix. A tumour can be cancerous or benign.(4) A malignant tumour is one that has the potential to spread to other regions of the body. The term "benign tumour" refers to a tumour that will not spread.(5)

At first, the changes in a cell are abnormal, not cancerous, and are sometimes called "atypical cells." Researchers believe that some of these abnormal changes are the first step in a series of slow changes that can lead to cancer. (6)Some of the atypical cells go away without treatment, but others can become cancerous. This phase of precancerous disease is called cervical dysplasia, which is an abnormal growth of cells. Sometimes, the dysplasia tissue needs to be removed to stop cancer from developing. Often, the dysplasia tissue can be removed or destroyed without harming healthy tissue, but in some cases, a hysterectomy is needed to prevent cervical cancer. (7)A hysterectomy is the removal of the uterus and cervix.Cervical cancer is the second most common cancer in india in women, accounting for women 16.5 % of all cancer cases in women and 8.35% death among all cancer in both men and women (Globocan 2018).FIGO staging for carcinoma cervix is predominantly based on clinical examination.(8)precise staging is imperative for rendering cervical cancer is the second most common cancer in india in women ,accounting for 16.5% of all cancerappropriate therapy,with concurrent chemo-radiation being the preferred of primary treatment for stages IB3 and above(NCCN version 5.2019).clinical staging is subject to high inaccuracy with error rates ranging between 26 and 66%.(9)Hence,for proper assessment of the size and the extent of tumor, examination under anesthesia is required.Since there is muscle relaxation,the parametrium is better assessed under anaesthesia,which may not be feasible in a conscious patient like CT and MRI there have been claims of better assessment stages .(10)This study attempts to identify the concordance between clinical examination

,examination under anesthesia and CECT with respect to the various parameter involved in staging of carcinoma cervix and to define the relevance of EUA in current scenario.

Patients identification:-A Female of age 33 years old from AVBRH Sawangi meghe Wardha admitted to gynecology ward, AVBRH on 03/06/2021 with complaint of Abdominal pain weight loss and fever. He is 52 kg and his height is 152 cm.

Present Medical History:- A Female of age 33 yrs old was brought to AVBRH 3rd June 2021 by her relative with complaints of abdominal pain, fever, weight loss and She was admitted to gynecology ward. After investigation she is diagnose as cervical dysplasia.

Past Medical History:-My patient was apparently alright 1 month back when she started experiencing pain in abdomen, it was insidious in onset, continuous type, not associated with bleeding PV.

My Patient having history of spontaneous and MTP (maternal termination of pregnancy).

DOM: - 6 years

P₁L₁A₅

P₁L₁:- Female /5 years /FTND

A₁:- Spontaneous /1.5 months /D and C done /3 year back

A₂:- Spontaneous /1.5 months/ D and C done / 2 year back

A₃:- 1.5 months /MTP by pills / 1 year back

A₄:- 1.5 months /MTP by pills/1 year back

A₅:- 1.5 months /MTP by pills

Last menstrual date:- 01/05/2021

My client having history of Laparoscopic funbral cysts resection done in 2016.

History of cervical biopsy in 2020 in that histopath s/o moderate dysplasia with chronic cervicitis on date 07/12/2020.

Family History:- There are Three members in family .Type of marriage of parents is non-consanguineous. All other member of family were not having complaint in their health expect for my patient .who was being admitted in the hospital.

Past intervention and outcomes:- Patient taking treatment for cervical dysplasia in national cancer institute. As shows hypertrophied ectocervical lining with moderate dysplasia, they when went to private clinics from where she was referred to AVBRH for further treatment.

Clinical findings:- Abdominal pain , weight loss, fever (Temperature – 101°F)

Etiology:- The signs and symptoms of cervical dysplasia normally arise gradually and might be very subtle at first.

In the rare cases there are some signs are present they are ;

1. Abdominal pelvic pain
2. Loss of appetites
3. Weakness

Physical examination:- There is not much abnormality found in head-to-toe examination, the patient is look dull and not active. she is weak and not cooperative.

Diagnostic assessment:- Blood test: HB- 10.8 gm%, Total RBC count- 4.15 millions/cu mm, RDW – 13.1%, Total WBC count-6100 /cu mm ,Total platelets- 2.381ACS/MM3

Cytopathology Examination:- Cervical cytology Smear shows only scattered superficial and intermediated squamous cell with few neutrophils.

Colposcopy Examination:- moderated dysplasia, chronic cervicitis.

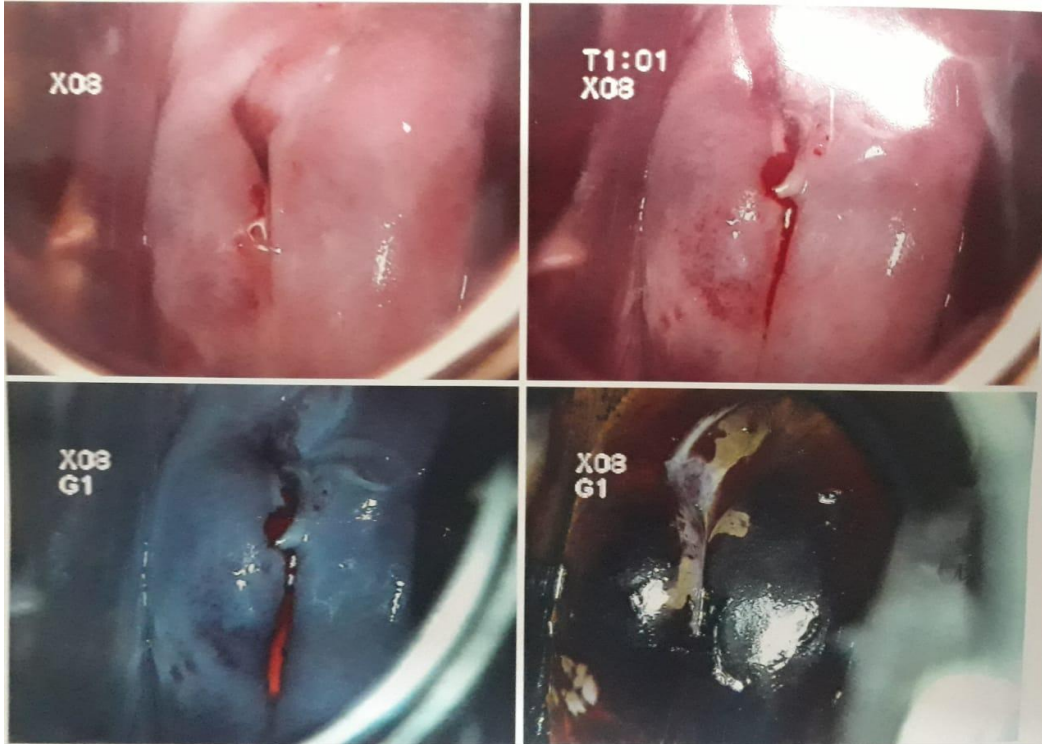
Colposcopy finings- cervical erosion seen on post lip.

-Mosaic pattern of blood vessels seen on green filter.

-Aceto white areas seen at 7o'clock position.

-Less iodine uptake at 7o'clock and 12o'clock positions

-aceto white areas reduced as compared to previous colposcopy.



Therapeutic Intervention:-Vaginal hysterectomy lateral Sphincterotomy I/V/O Cervical Dysplasia Inj. Gentamaine 80 mg iv 12 hrly, Inj. Ctax 1 gm IV 12hrly, Inj. Pan 40 mg iv 12 hrly, Inj Metro 100 ml /8 hrs, Inj. Neomal 100 ml Iv 12 hrly,

Inj Pause 8 hrly ,zonac suppository TDS, Tab-Gabapentin 300 mg HS, Glucose powder, protein powder 2tbsp BD with milk.

Discussion:-The majority of cervical carcinoma staging is based on clinical examination. Anaesthesia-assisted examination is an important aspect of the staging of cervical cancer. A number of studies have demonstrated the superiority of EUA over clinical examination, dating back to the work of J.R. Van Nagell et al, who found that EUA raised overall staging accuracy from 54 to 74 percent. B After EUA, Stefanon et al found a 24.5 percent change in clinical stage and a 10% change in therapeutic decision in 24.5 percent of patients. 3 In our study, there was an 11.2 percent difference in tumour size between EUA and clinical evaluation. Clinical examination failed to detect involvement in 7.4 percent of patients undergoing parametrium evaluation.(11)

Clinical examination failed to detect sidewall involvement in 68 percent of patients, indicating a considerable disparity in the extent of parametrial involvement. When compared to clinical evaluation, cross-sectional imaging modalities such as CT and MRI have been observed to increase staging accuracy. According to Hricak H et al., clinical staging has a sensitivity of 29 percent, CT has a sensitivity of 42 percent, and MRI has a sensitivity of 53 percent for detecting advanced stage (> or = IIB). When compared to surgical results, Ozsarlak et al. found that the overall accuracy of staging for clinical examination, CT, and MRI was 47, 53, and 86 percent, respectively.(12)

Despite the fact that CT has superior staging accuracy than EUA in the research described above, there is a substantial difference between CT and EUA in our study. In comparison to EUA, CECT severely understaged tumour size in 21.2 percent of patients. Cervical cancer can be depicted using CT, however it has limits. On contrast-enhanced CT, up to 50% of tumours are isodense to cervical stroma and so cannot be distinguished. As a result, there is a large disparity in the reported tumour size. Hancke et al. found that CT and MRI results were no better than palpation in the assessment of parametrial invasion (accuracy: CT 61 percent and 54 percent , MRI 61 percent and 56 percent , respectively). Whitley et al. also found that CT had low sensitivity in detecting pelvic side wall invasion. In our analysis, there was no parametrial involvement reported by CECT in 28.3 percent of patients who had parametrial involvement in EUA, which was similar to their experience.(13)

CECT has a low sensitivity for detecting side wall involvement, with 68 percent of individuals with illness reaching up to the side wall having no HUN or obvious lateral wall involvement in EUA. T.V Prasad et al. observed a similar low detection rate of pelvic sidewall involvement by CT. There is no significant difference between EUA and clinical evaluation when it comes to detecting fornix involvement. Pathological confirmation was not available to determine the accuracy of CECT and clinical findings since advanced cancer of the cervix is typically treated with chemoradiation.(14)

Conclusion: - A Female of 33 year admitted to gynecology ward AVBRH on 03/-6/2021 with chief complaint of abdominal pain, fever(Temperature 101°F), weight loss. As soon as she is admitted in hospital all investigation are done and were diagnose a case of cervical dysplasia. She is 52 kg and her height is 152 cm. After treatment were started and gone through surgery this

is non descending vaginal hysterectomy with sphincterectomy. It is very important to diagnose in early stage so that the patient will not have future complication. After getting treatment, she shows great improvement and the treatment was still going on till my last date of care.

Ethical clearance: - Not required.

Reference:-

1. What Is Cervical Cancer? | Types of Cervical Cancer [Internet]. [cited 2021 Dec 4]. Available from: <https://www.cancer.org/cancer/cervical-cancer/about/what-is-cervical-cancer.html>
2. Cervical Cancer: Introduction | Cancer.Net [Internet]. [cited 2021 Dec 4]. Available from: <https://www.cancer.net/cancer-types/cervical-cancer/introduction>
3. Cervical Cancer - Introduction [Internet]. Cancer.Net. 2012 [cited 2021 Dec 4]. Available from: <https://www.cancer.net/cancer-types/cervical-cancer/introduction>
4. Human papillomavirus (HPV) and cervical cancer [Internet]. [cited 2021 Dec 4]. Available from: [https://www.who.int/news-room/fact-sheets/detail/human-papillomavirus-\(hpv\)-and-cervical-cancer](https://www.who.int/news-room/fact-sheets/detail/human-papillomavirus-(hpv)-and-cervical-cancer)
5. Cancer Glossary: what does this word mean? [Internet]. [cited 2021 Dec 4]. Available from: <https://www.cancerouncil.com.au/cancer-information/understanding-cancer/glossary-what-does-this-word-mean/>
6. Are benign tumours different from cancerous tumours? - Cancer Research UK - Cancer news [Internet]. [cited 2021 Dec 4]. Available from: <https://news.cancerresearchuk.org/2020/03/02/science-surgery-are-benign-tumours-different-from-cancerous-tumours/>
7. Cervical Dysplasia: Symptoms, Treatments, Causes, and More [Internet]. [cited 2021 Dec 4]. Available from: <https://www.webmd.com/cancer/cervical-cancer/cervical-dysplasia-symptoms-causes-treatments>
8. Cervical cancer [Internet]. [cited 2021 Dec 4]. Available from: https://www.who.int/health-topics/cervical-cancer#tab=tab_1
9. Dabi Y, Simon V, Carcopino X, Bendifallah S, Ouldamer L, Lavoue V, et al. Therapeutic value of surgical paraaortic staging in locally advanced cervical cancer: a multicenter cohort analysis from the FRANCOGYN study group. *J Transl Med.* 2018 Nov 26;16:326.
10. : JKSR :: Journal of the Korean Society of Radiology [Internet]. [cited 2021 Dec 4]. Available from: <https://jksronline.org/DOIx.php?id=10.3348/jksr.2017.77.2.67>

11. Measurement of tumor size in early cervical cancer: an ever-evolving paradigm | International Journal of Gynecologic Cancer [Internet]. [cited 2021 Dec 4]. Available from: <https://ijgc.bmj.com/content/30/8/1215>
12. Susikar S, Subbiah S, Raja X. A prospective study to analyse the concordance in staging of carcinoma cervix between clinical examination, examination under anaesthesia and CECT. *Indian J ObstetGynecol Res.* 2020 Dec 28;7:467–9.
13. Maggino T, Bonetto F, Catapano P, Franco F, Valente S, Marchesoni D. Clinical staging versus operative staging in cervical cancer. *Clin Exp Obstet Gynecol.* 1983;10(4):201–4.
14. Rubin GD. Computed Tomography: Revolutionizing the Practice of Medicine for 40 Years. *Radiology.* 2014 Nov;273(2S):S45–74.

UNDER PEER REVIEW

UNDER PEER REVIEW