

# **Original Research Article**

## **TO EVALUATE THE SUCCESS RATE OF PULPOTOMY IN PRIMARY MOLARS USING FERRIC SULPHATE (FS) AND MINERAL TRIOXIDE AGGREGATE (MTA): A CLINICAL AND RADIOGRAPHIC STUDY**

### Abstract

Purpose: The aim of this present study was to observe clinical, radiographic response of pulp to Ferric Sulphate and Mineral Trioxide Aggregate when used as pulpotomy agent in primary molars.

Materials and Methods: Sixty restorable primary molars were selected for the study. The children were chosen who require minimum two pulpotomies in either arch preferably each on the opposite side (i.e. right and left). Primary molars on the right side of the patient were assigned to Ferric Sulphate (FS) (Group A) and left side was assigned for the Mineral Trioxide Aggregate (MTA) (Group B). Statistical analysis was done using the chi-square test.

Results: outcome of the present study was observed for 3 and 6 months. The clinical success rate for MTA and ferric sulphate during 3 and 6 month follow up was 100%. The radiographic follow up of MTA was 100% during 3 and 6 month, whereas it was 96.6% for 3 and 6 month follow up with respect to ferric sulphate. There were no significant differences in the clinical ( $p>0.1$ ) and radiographic ( $p> 0.98$ ) success rates among both the groups.

Conclusion: No significant difference was seen between ferric sulphate (Group A) and MTA (Group B) as medicaments for use following pulpotomy. Radiographic success rate was lower for Ferric sulphate (Group A) than that of MTA (Group B) with occurrence of one internal

resorption seen with first primary molar.

Key words

MTA, ferric sulphate, pulpotomy, stainless steel crown

## Introduction

There have been many advances in the prevention of dental caries thereby understanding the importance of preserving natural teeth has increased (Caicedo et al., 2006). It has been suggested that the main concept of modern paediatric endodontics should be to keep the pulp of primary teeth vital until their normal physiological resorption rather than just maintaining the teeth (Ibricevic and Al-Jame, 2003). There are many choices for conservative pulp therapies like direct pulp capping, indirect pulp capping, pulpotomy, pulpectomy procedures (Fuks, 2002)

Pulpotomy in primary dentition is the most common endodontic treatment for inflammation of coronal pulp caused by caries or trauma. The rationale for pulpotomy of primary teeth is based on the assumption that inflammation is limited to coronal portion of dental pulp and that the radicular pulp has the potential to heal (Malekafzali et al., 2011). It is difficult to determine the histopathological status of the pulp clinically. Histologically, most primary molars with proximal caries have inflammation in pulp horns, even in small lesion extending less than half intercuspal distance, and manifesting well before clinical exposure (Duggal et al., 2002). The operator relies on subjective criteria to determine whether the remaining pulp is affected or not such as bleeding time of the radicular pulp stump after amputation, color of hemorrhage and consistency of the tissue (Malekafzali et al., 2011)

Pulpotomy procedure involves removing coronal pulp tissue that has undergone inflammation or degenerative changes and leaving vital tissue in root canals. Medicaments used for primary tooth pulpotomy are classified by action on pulp as, devitalisation (mummification, cauterization), preservation (minimal devitalisation, non-inductive) or regeneration (inductive, reparative) (Ranly, 1994)

Ferric sulphate has gained some popularity because it is claimed to have low toxicity and no systemic side effects. Ferric sulphate is a material which has shown potential for preservation. Ferric sulphate agglutinates blood proteins and controls hemorrhage in the process without clot formation. The agglutination of blood proteins results from reaction of blood with ferric and sulphate ions. This ferric ion- protein complex mechanically seals the cut vessels thus producing haemostasis (Odabas et al., 2012).

Currently interest in more biocompatible material with regeneration potential has promoted Mineral Trioxide Aggregate (MTA) as an alternative pulpotomy medicament. This is non-resorbable, nontoxic, non-carcinogenic material.

Improved and more conservative pulp management has the potential to reduce the need for more invasive endodontic treatment. However, if this is to be achieved in primary teeth, there is a need for better materials for endodontic procedures, especially pulpotomy.

This study was undertaken to compare reaction of ferric sulphate (FS) and mineral trioxide aggregate (MTA) to pulp though their physiochemical reaction to the pulp are different and to look forward for the best possible results to guide our research and development.

The objective of this standardized clinical study is to evaluate effect on clinical and

radiographic signs in deciduous molars.

### **MATERIALS AND METHODS:**

It was a split mouth study with follow up period of 6 month. Total 60 primary molars in 30 children were selected for the study. 60 teeth were equally distributed between group A (30 teeth) and Group B (30 teeth). Primary molars on the right side of the patient were assigned to Ferric Sulphate (FS) (Group A) and on the left side for the Mineral Trioxide Aggregate (MTA) (Group B). The study was carried out in the department of pedodontics and preventive dentistry, SDKS dental college and hospital, Nagpur, Maharashtra. The study was started on January 2021 and completed on September 2021. Ethical clearance was obtained from institutional review board (IEC/Rep/STRP/03101).

Children fulfilling following criteria's were included in study

1. without any systemic disease
2. Primary molars with carious lesions close to the Pulp and no signs of irreversible pulpitis,
3. No radiographic signs of pathological root resorption, furcation radiolucency.

### **PROCEDURE:**

Tell show do technique was used before starting the procedure. Topical anesthetic gel was applied before local anesthesia administration. After successful administration of local anesthesia rubber dam was placed with carious tooth (figure 1).

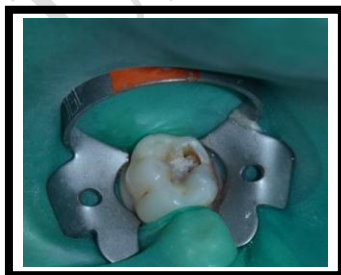

Figure 1

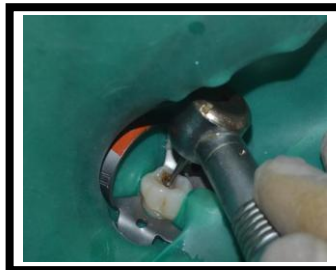

Figure 2

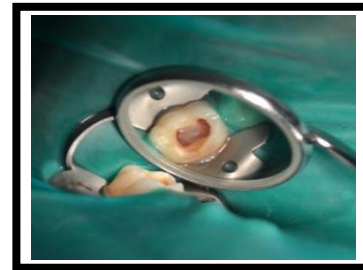

Figure 3

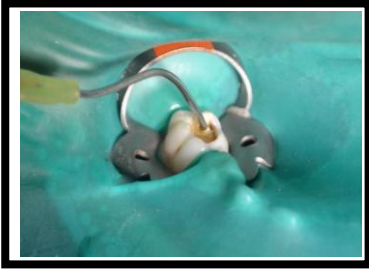

FIGURE 4

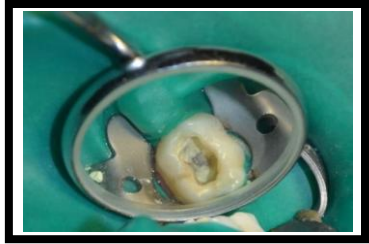

FIGURE 5

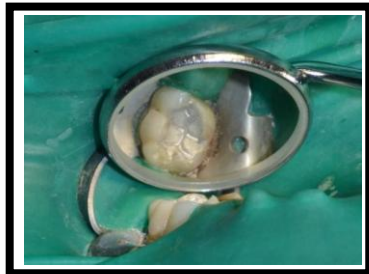

FIGURE 6

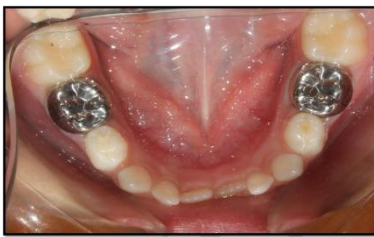

FIGURE 7

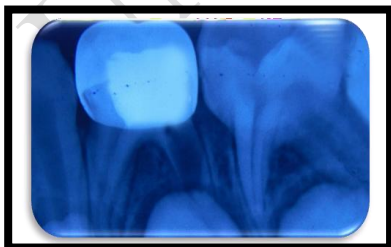


FIGURE 8

Fig. 1-8. Procedure for local anesthesia rubber dam with carious tooth

Carious excavation was done using slow speed round bur from the axial wall (figure 2). After caries excavation excess cavity was prepared and complete de-roofing was done. Pulp amputation was done using sterile large spoon excavator (figure 3). Complete removal of coronal pulp was inspected visually. Pulp chamber was irrigated with normal saline. After irrigation one or more moistened cotton pellets were applied over the pulp stumps and pressure was applied for few minutes. When cotton pellets were removed hemostasis was apparent. Following hemostasis, ferric sulphate (group A) (figure 4), MTA (group B) (figure 5) was placed over the pulp stumps. In group A, ferric sulphate (Ultradent, Germany) was placed in contact with radicular pulp for fifteen seconds with applicator (Dento-infuser) supplied by manufacturer. After irrigation with normal saline and observation of hemostasis, zinc oxide eugenol was placed in the coronal pulp chamber and cavity was filled with amalgam (figure 6). After eight days, teeth were restored with preformed stainless steel crowns (figure 7).

#### Follow-ups

All the procedure was performed by single operator. Clinical and radiographic follow-up was done after 3 and 6 months. Clinical success was established after negative reporting of spontaneous pain, mobility, swelling and sinus. Absence of external and internal root resorption and bone loss destruction provides the radiographic success.

#### Statistical analysis

Statistical analysis was done using SPSS version 21. Chi- square test was used to compare the different clinical and radiographic findings.

## RESULTS

60 (38 first molar and 22 second molars) primary molars in 30 children were analyzed (Table 1).

Table 1:- The distribution of primary molars in the two groups

	First Primary Molar		Second Primary Molar		Total
	No	%	No	%	
Ferric Sulphate (Group A)	19	63.3	11	36.7	30
MTA (Group B)	19	63.3	11	36.7	30
Total	38		22		60

Clinical assessment for FS and MTA was 100% for period of 3 and 6 months and thus results were statistically not significant (  $p = 1$  ) (Table 2). Radiographic assessment for MTA for period of 3 and 6 month was 100 % whereas; it was 96.6% for ferric sulphate (Table3). After statistical analysis the results were statistically not significant ( $p = 0.98$ ).

Table 2:- Clinical assessment by various clinical signs observed for pain, swelling and Sinus/ fistula in pulpotomized primary molars for 3 and 6 month follow up

Total	No. of primary molars without pain	Percentage of primary molars without pain	No. of primary molars without swelling	Percentage of primary molars without swelling	No. of primary molars without sinus/fistula	Percentage of primary molars without sinus/fistula

Ferric Sulphate (Group A)	30	30	100 %	30	100 %	30	100 %
MTA (Group B)	30	30	100 %	30	100 %	30	100 %

By Chi Square Test

p = 1.0, Not Significant

Table 3:- Radiographic appearance of pulp observed for internal resorption, furcation radiolucency, periapical radiolucency in primary molars for 3 and 6 month follow up

	Total	No. of primary molars without internal resorption	Percentage of primary molars without internal resorption	No. of primary molars without furcation involvement	Percentage of primary molars without furcation involvement	No. of primary molars without periapical radiolucency	Percentage of primary molars without periapical radiolucency
Ferric Sulphate (Group A)	30	29	96.6 %	30	100 %	30	100%
MTA (Group B)	30	30	100 %	30	100%	30	100%

By Chi Square Test

p = 0.98, Not Significant

## DISCUSSION

This study intended to examine clinical and radiographic success rate in primary molars and to compare the findings between ferric sulphate (FS) (Group A) and mineral trioxide aggregate (MTA) (Group B).

Criteria for selection of primary molars for our study was vital carious pulp exposures, no clinical symptoms or evidence of pulp degeneration such as pain on percussion, history of swelling or sinus tracts, no radiographic signs of internal or external resorption and no furcation radiolucency (Agamy et al., 2004). It is important to assess the history of pain and other clinical signs and symptoms including intensity of bleeding from amputation site, to aid in diagnosing radicular pulp tissue. Thus it reiterates the importance of early and accurate diagnosis of pulpal status (Duggal et al., 2002).

Clinically the success rate was 100% with both the groups at all observation. When assessed for various clinical signs analysis showed that not a single case had failure. Many authors in their clinical study reported favorable results with ferric sulphate pulpotomy, however they had compared their results with formocresol pulpotomy (Ibricevic and Al-Jame, 2003), (Smith et al., 2000), (Casas et al., 2003), (Havle et al., 2013), (Neamatollahi et al., 2006).

Our results revealed comparison of FS (Group A) and MTA (Group B) which showed that the difference was not statistically significant. Clinically they were 100% successful. The clinical success of Ferric Sulphate (FS) in this study could be attributed to right case selection technique protocol and appropriate use of medicament. In addition to this better antibacterial property of ferric sulphate (FS) contributed to success (Cinar et al., 2012).

Ferric sulphate generates plug by agglutination of blood protein that seals blood capillaries. Though controversies considering internal root resorption as pulpotomy failure in different studies have been observed, other authors considered it as normal due to absence of radiographic changes after thirty four months (Fuks et al., 1997).

Failure of pulpotomy is normally detected radiographically. The first sign of failure may be

internal resorption adjacent to pulpal medicament. Radiographically in our study internal resorption observed in ferric sulphate (Group A) was considered as failure as per methodology. Radiographic success rate of ferric sulphate (FS) pulpotomy evaluated in this study was 96.6% with one failure at the end of three months. Result of FS pulpotomies in our study confirmed the findings of previous studies that recorded one tooth failure at the end of three months (Fei et al., 1991). Some authors reported internal resorption in 40% cases treated with ferric sulphate (Vargas et al., 2005).

Internal resorption is the result of odontoclastic activity and suggests that the tooth is retaining some degree of vitality and function over time. Although the cause of internal resorption is unknown, there is a speculation that whatever the precipitating factor, it produces vascular changes in the pulp that involves an inflammation and formation of granulation tissue (Smith et al., 2000).

In the current study ZOE was chosen as base material over treated pulp stumps. The use of zinc oxide and eugenol may have shown irritation resulting to chronic inflammation and necrosis with ferric sulphate (FS) (Group A). The clot is the only entity separating the zinc oxide eugenol from vital tissue which may not act as barrier to radicular pulp. Therefore ZOE may not be an ideal base for ferric sulphate pulpotomies due to inflammatory tissue (Smith et al., 2000).

Previous investigation of ZOE as a pulpotomy agent or as a base for pulpotomies suggests that ZOE can cause pulp inflammation with a risk for subsequent internal resorption (Holan et al., 2005). ZOE as a base in direct contact with pulpal floor plays important role in the healing process (Garcia-Godoy et al., 1987). Taking into account the type of failure (internal resorption) and time period in which failure occurred, it may be due to undiagnosed chronic

inflammation. Despite of promising findings regarding the use of ferric sulphate, further studies under the following aspects i.e. longer follow up period and greater number of sample is important.

Study showed radiographic failure amongst FS (Group A) (figure 8) pertaining to the first primary molar which had not depicted any clinical failure.

Three months after the treatment average success rate was 100% in MTA (Group B). Findings of study coincide with many other authors (Malekafzali et al., 2011), (Eidelman et al., 2001), (Sonmez et al., 2008) (Kabaktchieva et al 2009), ( Naik and Hegde, 2005), (Haghgoo and Abbasi, 2010)

The success rate of MTA (Group B) in this study was, clinically as well as radiographically, with all the thirty primary molars, 100% successful. Favourable treatment outcome of MTA in comparison to FS could be because of MTA having excellent sealing ability, biocompatibility, alkalinity and ability to regenerate the hard tissue. Effects of MTA on amputated pulpal tissue seem to suggest that the material preserves the pulp tissue and promotes the regeneration of hard tissue (Agamy et al., 2008).

There are reports of complete bridge formation when MTA was used as endodontic material (Torabinejad and Chivian, 1999), (Eidelman et al., 2001), (Salako et al., 2003) and pulp canal obliteration was a common radiographic finding (Subramaniam et al., 2009). However in the present study no dentin bridge formation, pulp canal obliteration was seen radiographically which may be due to short follow up period i.e. three months. Results of present study are in accordance with previous short follow up study (Naik and Hegde, 2009).

Advantage of MTA (Group B) over FS (Group A) and its greater success rate in this study attributed to physical property, biocompatibility and sealing ability of material. MTAs advantages might be related to its sealing ability to prevent bacterial penetration and to its

high level biocompatibility (Godhi et al., 2011). One of the factors limiting the routine use of MTA is the high cost of the material.

It is well established fact that healing of dental pulp is directly related to the capacity of both the pulp dressing and definitive restorative material which should provide a biological seal against microleakage along the entire restoration interface. Despite the difference in the radiographic success of ferric sulphate (Group A) and MTA (Group B), in this split mouth clinical study both the materials have promising biological properties.

### **Conclusion**

Following conclusions were drawn from the present study

- No significant difference was seen between ferric sulphate (Group A) and MTA (Group B) as medicaments for use following pulpotomy. The result achieved in the present study following application of MTA was promising when compared to ferric sulphate.
- Radiographic success rate was lower for Ferric sulphate (Group A) than that of MTA (Group B) with occurrence of one internal resorption seen with first primary molar.
- Overall success rate at recall should be assessed radiographically to monitor any pathologic changes along with the clinical evaluation.
- Vital amputation of the pulp with MTA is a reliable biological method for pulp treatment of primary teeth and could be recommended for clinical practice.
- Despite the promising finding regarding the use of ferric sulphate, there is need for further study with longer follow up period and greater number of teeth treated with ferric sulphate to determine long term effects on primary teeth.
- Well-designed randomized clinical trial with adequate sample size and follow up times are required to confirm the superiority of Mineral Trioxide Aggregate.

## **Ethical approval**

Ethical clearance was obtained from institutional review board (IEC/Rep/STRP/03101)

## **Data and material availability**

All data associated with study are presented in paper.

## **COMPETING INTERESTS DISCLAIMER:**

**Authors have declared that no competing interests exist. The products used for this research are commonly and predominantly use products in our area of research and country. There is absolutely no conflict of interest between the authors and producers of the products because we do not intend to use these products as an avenue for any litigation but for the advancement of knowledge. Also, the research was not funded by the producing company rather it was funded by personal efforts of the authors.**

## REFERENCES

1. Caicedo R, Abbott PV, Alongi DJ, Alarcon MY. Clinical, radiographic and histological analysis of the effects mineral trioxide aggregate used in direct pulp capping and pulpotomies of primary teeth. *Australian Dental Journal* 2006;51:(4):297-305.
2. Ibricevic H, Al-Jame Q. Ferric sulphate and formocresol in pulpotomy of primary molars: long term follow-up study. *European Journal of Paediatric Dentistry* 2003; 1:28-32.
3. Fuks A.B. Current concepts in vital primary pulp therapy. *European Journal of Paediatric Dentistry* 2002;3:115-120.
4. Malekafzali B, Shekarchi F, Asgary S. Treatment outcomes of pulpotomy in primary molars using two endodontic biomaterials. A 2-year randomized clinical trial. *European Journal of Paediatric Dentistry* 2011; 12(3):189-193.
5. Duggal Ms, Nooh A, High A. Response of the primary pulp to inflammation: a review of Leeds studies and challenges for the future. *European Journal of Paediatric Dentistry* 2002;3:111-114.

6. Ranly D.M. Pulpotomy therapy in primary teeth : new modalities for old rationales. Pediatric dentistry November/December 1994 ; 16(6): 403-409.
7. Odabas M.E, Alaçcam A, Sillelioglu H, Deveci C. Clinical and radiographic success rates of mineral trioxide aggregate and ferric sulphate pulpotomies performed by dental students. European Journal of Paediatric Dentistry 2012; 13(2): 118-122.

UNDER PEER REVIEW

8. Agamy Hadeer.A, Bakry Niveen.S, Mounir Maha.M, Avery David.R. Comparison of Mineral Trioxide Aggregate and formocresol as pulp-capping agents in pulpotomized primary teeth. *Pediatric Dentistry* 2004; 26(4): 302-309.
9. Fei Ay-Luen,Udin Richard D,Johnson R. A clinical study of ferric sulfate as a pulpotomy agent in primary teeth. *Pediatric Dentistry*:November/December 1991;13(6):327-332.
10. Torabinejad M, Chivian N. Clinical Applications of Mineral Trioxide Aggregate. *Journal of Endodontics* ;March 1999; 25(3):197-205.
11. Smith Nikki L, Seale Sue N, Nunn Martha E. Ferric sulfate pulpotomy in primary molars: A retrospective study. *Pediatric Dentistry* 2000;22(3):192-199.
12. Casas Michael J, Layug Michael A, Kenny David J, Johnston Douglas H, Judd Peter L .Two –year Outcomes of Primary Molar Ferric Sulfate Pulpotomy and Root Canal Therapy. *Pediatric Dentistry* 2003;25(2):97-102.
13. Havle Raghavendra, Anegundi Rajesh T, Indushekar KR, P.Sudha . Clinical and Radiographic Evaluation of Pulpotomies in Primary Molars with Formocresol, Glutaraldehyde and Ferric sulphate. *OHDM-March*,2013;12(1):24-31.
14. Neamatollahi H, Tajik A .Comparison of clinical and radiographic success rates of pulpotomy in primary molars using Formocresol, Ferric sulfate and Mineral Trioxide Aggregate (MTA). *Journal of Dentistry, Tehran University of Medical Sciences, Tehran* ,Iran 2006; 3(1):6-14.
15. Cinar Cagdas,Odabas Mesut Enes, Akca Gulcin, Isik Berrin. Antibacterial effect of a new haemostatic agent on oral microorganisms *Journal of Clinical and Experimental Dentistry*. 2012;4(3):e151-155

16. Fuks Anna B, Holan Gideon, Davis John M, Eidelman Eliezer, Dr.Odont. Ferric sulfate versus dilute formocresol in pulpotomized primary molars: long-term follow-up. *Pediatric Dentistry*.1997;19(5):327-330.
17. Vargas Kaaren G, Packham Brett Radiographic Success of Ferric Sulfate and Formocresol Pulpotomies in Relation to Early Exfoliation. *Pediatric Dentistry*. 2005; 27(3): 233-237.
18. Holan Gideon, Eidelman Eliezer,Dr.Odont, Fuks Anna B. Long-term Evaluation of Pulpotomy in Primary Molars Using Mineral Trioxide Aggregate or Formocresol. *Pediatric Dentistry* 2005; 27(2): 129-136.
19. Garcia-Godoy Franklin, Ranly Don M. Clinical evaluation of pulpotomies with ZOE as the vehicle for glutaraldehyde. *Pediatric Dentistry* June 1987;9(2):144- 146.
20. Eidelman Eliezer, Dr.Odont, Holan Gideon, Fuks Anna B. Mineral trioxide aggregate vs. formocresol in pulpotomized primary molars:A preliminary report. *Pediatric Dentistry* 2001;23(1):15-18
21. Sonmez Deniz, Sari Saziye, Cetinbaş Tugba. A Comparison of Four Pulpotomy Techniques in Primary Molars: A Long-term Follow-up. *Journal of Endodontics* 2008;34(8):950-955.
22. Noorollahian H. Comparison of mineral trioxide aggregate and formocresol as pulp medicaments for pulpotomies in primary molars. *British Dental Journal* 2008;204:Online Article No E20:1-4

23. Kabaktchieva R ,Gateva N. Vital pulpotomy in primary teeth with mineral trioxide aggregate (MTA).Journal of IMAB –Annual proceeding (scientific papers) 2009,book 2:102-108
24. Naik S, Hegde Amitha M. Mineral trioxide aggregate as a pulpotomy agents in primary molars: An in vivo study. Journal of Indian Society of Pedodontics and Preventive Dentistry 2005;23(1):13-16
25. Haghgoo Roza, Abbasi Farid. Clinical and radiographic success of pulpotomy with MTA in primary molars:30- months follow up. Iranian Endodontic Journal 2010;5(4):157-160
26. Salako Nathanael, Joseph Bobby, Ritwik Priyanshi, Salonen Jukka, John Preethi, Junaid T.A. Comparison of bioactive glass, mineral trioxide aggregate, ferric sulfate, and formocresol as pulpotomy agents in rat molar. Dental Traumatology 2003;19:314-320.
27. Subramaniam Priya, Konde Sapna, Mathew Sony, Sugnani Sony. Mineral Trioxide Aggregate as Pulp Capping Agent for Primary Teeth Pulpotomy: 2 Year Follow Up Study. Journal of Clinical Pediatric Dentistry. 2009; 33(4):311–314.
28. Godhi Bindra, Sood P.B, Sharma Arun . Effects of mineral trioxide aggregate and formocresol on vital pulp after pulpotomy of primary molars:An in vivo study. Contemporary Clinical Dentistry October-December 2011;2(4):296-301.