

Short communication

A RARE FINDING OF ABUNDANT CRYSTALS IN THYROID FNAC A SHORT COMMUNICATION

Abstract

Thyroid is a versatile endocrine organ. FNAC is the famous technique which is safe, easy to perform, cost effective and more accurate in diagnosing benign and malignant thyroid lesions. Our case shows a rare presentation of numerous calcium oxalate crystals within the colloid in thyroid smear which indicates degenerative and atrophic changes in the follicles, and can also be seen in numerous other benign and systemic conditions which roots the underlying pathology and helps in treatment as well as stays as a unique rare finding.

INTRODUCTION:

Thyroid is a spectacular ancient gland in medical history. Anatomical structure of the thyroid gland was invented by Wang around 1475. The gland was named by Thomas Warton meaning shield since it resembles the shield which is commonly used in ancient Greece. The gland assumes butterfly shape where it has two lobes connected in the middle by the isthmus. In past few decades, Fine needle aspiration cytology procedure of thyroid gland is being performed at an increased rate of identifying thyroid lesions with high rate of sensitivity and specificity as a single diagnostic method. Moreover, Fine needle aspiration cytology is considered to be the easiest, cost effective, safer and more accurate investigation in the diagnosis of benign as well as malignant thyroid lesions in view of early diagnosis of malignancies, reducing unnecessary surgical procedures and improving patient well being.⁶ The benign thyroid gland under Fine needle aspiration cytology will show clusters of follicular epithelial cells in a background of colloid. Usually crystals are not commonly noticed in a thyroid smear. The crystals in thyroid aspirate was first described by Zeiss in the year 1877. Calcium crystals in thyroid FNAC are rarely seen within the colloid of normal thyroid glands. They are usually variable in size and shape, most of the crystals are specifically birefringent under polarized light microscope.

ABBREVIATIONS:

AUS-Atypia of undetermined significance.

FLUS- Follicular lesion of undetermined significance.

SFN- Follicular neoplasm /suspicious for follicular neoplasm.


CASE REPORT:

A 59 years old euthyroid female was referred to cytology department for Fine needle aspiration of swelling over left side of neck for one year, slowly increasing in size. On Local examination, left lobe was diffusely enlarged , measuring 4x6 cm, soft in consistency, swelling moved with deglutition. Ultrasound showed cyst measuring 6x8cm with thick walled septations. Contrast enhanced computed tomography confirmed well defined cystic lesion arising from left lobe of thyroid. Under aseptic precautions, and patient in supine position, 50 ml of straw yellow, slightly turbid fluid was aspirated totally.

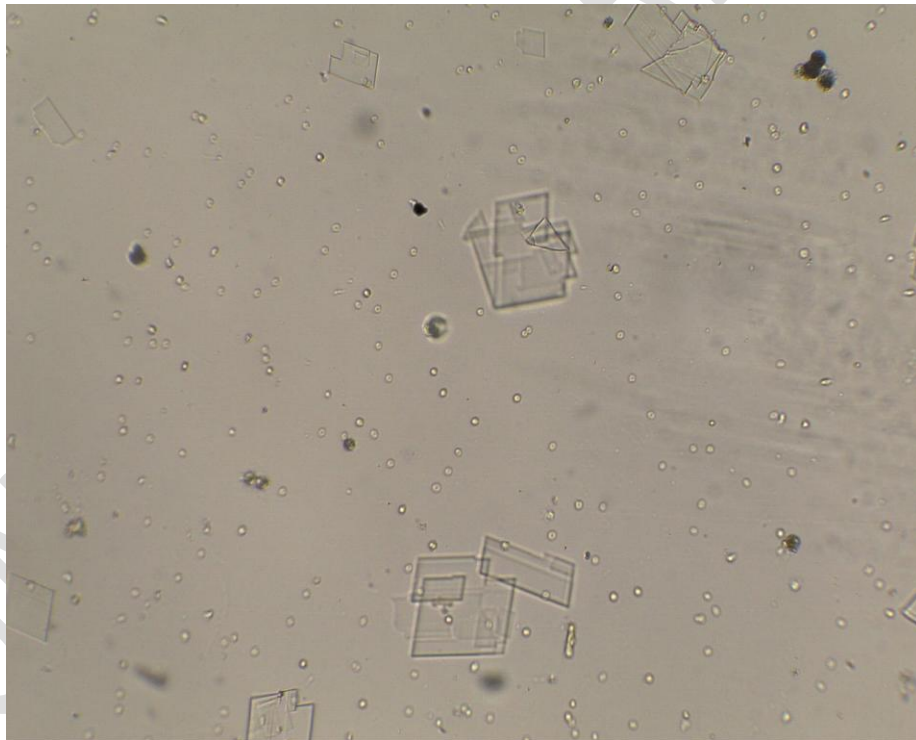WET MOUNT PREPARATION:

Uncentrifuged wet mount preparation (fig 1 & 2) showed presence of abundant transparent pale refractile crystals, mostly of uniform shape.

Fig (1) wet mount, 10x10X showing abundant transparent pale refractile crystals.



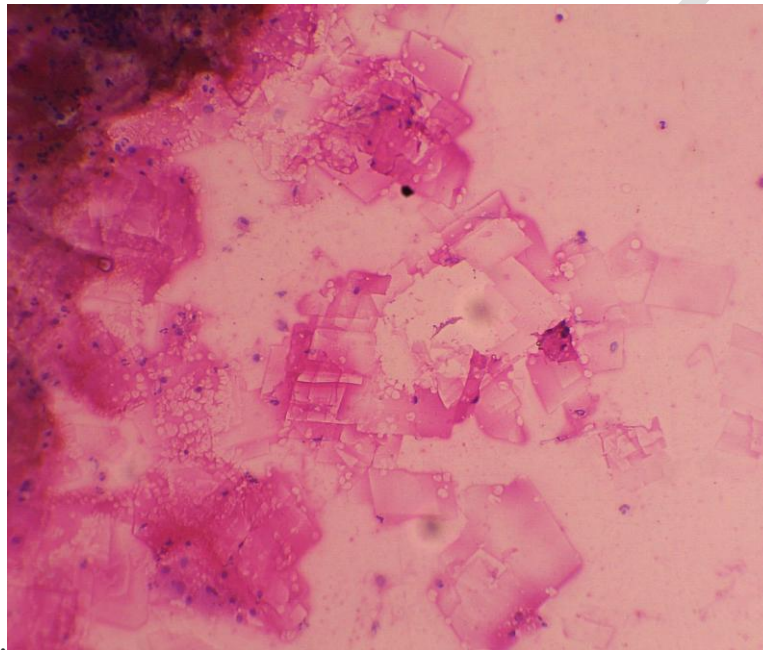
Fig(2) wet mount, 10x40X showing transparent pale refractile octahedral crystals



HAEMATOXYLIN AND EOSIN SMEARS:

Haematoxylin and eosin smears of the aspirate shows abundant hexagonal to octahedral crystals with similar morphology in a background of cyst macrophages and colloid. The report was finalised as cystic degeneration in colloid nodule of thyroid.

Fig (3) Hematoxylin& eosin, 10X40X showing cyst macrophages, few RBC's with crystals



DISCUSSION:

Thyroid FNAC reports is being reported according to the Bethesda System for Reporting Thyroid Cytopathology which was invented in the year 2007. The Bethesda system includes six categories for thyroid cytology reporting including Nondiagnostic, Benign, Atypia of undetermined significance (AUS) / Follicular lesion of undetermined significance (FLUS), Follicular neoplasm /Suspicious for follicular neoplasm (SFN), Suspicious for malignancy, and Malignancy.

Thyroid crystals are seen less in cytology smears compared to histopathological thyroid specimens and appears as birefringent crystals of different sizes classically within the colloid but do not appear within the follicular epithelial cells cytoplasm or in the stromal background of the thyroid. They are usually an indication of old

age or associated with benign thyroid pathologies. The most common crystals in thyroid are calcium oxalate crystals which usually differentiates thyroid tissue from parathyroid tissue where there is absence of crystal. Colloid often contains heavy deposition of calcium oxalate crystals, particularly in nodular goiter but also in aged or hypoactive benign thyroid and rarely in tumors. Occurrence of calcium crystals in normal human thyroid is associated with a low functional state of the thyroid follicles especially in inactive follicles of aged individuals. Crystals within the colloid can be seen in chronic renal failure because of systemic oxalate deposition.

Accumulation of cystine crystals is also found in cystinosis and leads to destruction and atrophy of follicular cells which can cause calcifications in future. Anisotropic crystals will be colorless and refractile foci variable in size and shape. There is no association with any specific thyroid condition. Crystals can be also seen in cysts of parathyroid origin. In such scenario, elevated serum calcitonin levels in aspirate favours diagnosis of cysts from parathyroid origin. In our case, computer tomography confirmed thyroid as the tissue of origin. These crystals of thyroid origin appears birefringent under polarizing light unlike parathyroid origin. Other crystals which can be seen includes slender needle like bilirubin crystals and cholesterol crystals having broken pan appearance.

CONCLUSION:

Crystals in Thyroid FNAC smears are identified more significantly in older individuals and benign lesions. In our case, we noted calcium crystals which is a clue to the diagnosis of degenerative changes occurring in old age, inactive thyroid gland or identification of probably benign lesions of thyroid. This short communication was presented to share an interesting finding of crystals in thyroid fine needle aspiration cytology.

REFERENCES:

1. Bilirubin crystals in thyroid, 6-Apr-2019

Rashmi [HYPERLINK](#)

["https://www.jdrntruhs.org/searchresult.asp?search=&author=Rashmi+Patnayak&journal=Y&but_search=Search&entries=10&pg=1&s=0"](https://www.jdrntruhs.org/searchresult.asp?search=&author=Rashmi+Patnayak&journal=Y&but_search=Search&entries=10&pg=1&s=0) [HYPERLINK](#)

["https://www.jdrntruhs.org/searchresult.asp?search=&author=Rashmi+Patnayak&journal=Y&but_search=Search&entries=10&pg=1&s=0"](https://www.jdrntruhs.org/searchresult.asp?search=&author=Rashmi+Patnayak&journal=Y&but_search=Search&entries=10&pg=1&s=0) Patnayak, Kaushambi [HYPERLINK](#)

["https://www.jdrntruhs.org/searchresult.asp?search=&author=Kaushambi+Chakraborty&journal=Y&but_search=Search&entries=10&pg=1&s=0"](https://www.jdrntruhs.org/searchresult.asp?search=&author=Kaushambi+Chakraborty&journal=Y&but_search=Search&entries=10&pg=1&s=0)Chakraborty, Rajesh
[HYPERLINK](#)

["https://www.jdrntruhs.org/searchresult.asp?search=&author=Rajesh+Bhola&journal=Y&but_search=Search&entries=10&pg=1&s=0"](https://www.jdrntruhs.org/searchresult.asp?search=&author=Rajesh+Bhola&journal=Y&but_search=Search&entries=10&pg=1&s=0)Bhola, Amitabh Jena

Department of Pathology, Institute of Medical Sciences and SUM Hospital, Bhubaneswar, Odisha, India

Department of Surgical Oncology, Institute of Medical Sciences and SUM Hospital, Bhubaneswar, Odisha, India

2. Birefringent crystals in thyroid fine-needle aspiration cytology:

August 2016

Diagnostic Cytopathology 44(10)

DOI: 10.1002/dc.23562

3. Virchows Arch A Pathol Anat Histopathol

1993;422(4):301-6.

doi: 10.1007/BF01608339.

Nature and significance of calcium oxalate crystals in normal human thyroid gland. A clinicopathological and immunohistochemical study

[R HYPERLINK](#)

["https://pubmed.ncbi.nlm.nih.gov/?term=Katoh+R&cauthor_id=8506623"](https://pubmed.ncbi.nlm.nih.gov/?term=Katoh+R&cauthor_id=8506623)Katoh¹, K Suzuki, [A HYPERLINK](#)

["https://pubmed.ncbi.nlm.nih.gov/?term=Hemmi+A&cauthor_id=8506623"](https://pubmed.ncbi.nlm.nih.gov/?term=Hemmi+A&cauthor_id=8506623)
[HYPERLINK](#)

["https://pubmed.ncbi.nlm.nih.gov/?term=Hemmi+A&cauthor_id=8506623"](https://pubmed.ncbi.nlm.nih.gov/?term=Hemmi+A&cauthor_id=8506623)Hemmi, [A HYPERLINK](#)

["https://pubmed.ncbi.nlm.nih.gov/?term=Kawaoi+A&cauthor_id=8506623"](https://pubmed.ncbi.nlm.nih.gov/?term=Kawaoi+A&cauthor_id=8506623)Kawaoi

4. Am J Surg Pathol

1993 Jul;17(7):698-705.

doi: 10.1097/00000478-199307000-00007.

Birefringent (calcium oxalate) crystals in thyroid diseases. A clinicopathological study with possible implications for differential diagnosis

R [HYPERLINK](#)

["https://pubmed.ncbi.nlm.nih.gov/?term=Katoh+R&cauthor_id=8317610"](https://pubmed.ncbi.nlm.nih.gov/?term=Katoh+R&cauthor_id=8317610)Katoh¹,

A [HYPERLINK](#)

["https://pubmed.ncbi.nlm.nih.gov/?term=Kawaoi+A&cauthor_id=8317610"](https://pubmed.ncbi.nlm.nih.gov/?term=Kawaoi+A&cauthor_id=8317610)Kawaoi,

A [HYPERLINK](#)

["https://pubmed.ncbi.nlm.nih.gov/?term=Muramatsu+A&cauthor_id=8317610"](https://pubmed.ncbi.nlm.nih.gov/?term=Muramatsu+A&cauthor_id=8317610)Muramatsu, [A](#) [HYPERLINK](#)

["https://pubmed.ncbi.nlm.nih.gov/?term=Hemmi+A&cauthor_id=8317610"](https://pubmed.ncbi.nlm.nih.gov/?term=Hemmi+A&cauthor_id=8317610)Hemmi, K Suzuki

5. The History of the Thyroid Gland

A Timeline Report^Â

6. Cytojournal [HYPERLINK](#)

["https://www.ncbi.nlm.nih.gov/pmc/articles/PMC5841007/"](https://www.ncbi.nlm.nih.gov/pmc/articles/PMC5841007/). 2018; 15: 4.

Published online 2018 Feb 16. doi: [10.4103/cytojournal.cytojournal_32_17](https://doi.org/10.4103/cytojournal.cytojournal_32_17)

PMCID: PMC5841007

PMID: [29531571](#)

Classification of thyroid fine-needle aspiration cytology into Bethesda categories: An institutional experience and review of the literature

Safa [HYPERLINK](#)

["https://www.ncbi.nlm.nih.gov/pubmed/?term=Alshaikh%20S%5BAuthor%5D&cauthor=true&cauthor_uid=29531571"](https://www.ncbi.nlm.nih.gov/pubmed/?term=Alshaikh%20S%5BAuthor%5D&cauthor=true&cauthor_uid=29531571) [HYPERLINK](#)

["https://www.ncbi.nlm.nih.gov/pubmed/?term=Alshaikh%20S%5BAuthor%5D&cauthor=true&cauthor_uid=29531571"](https://www.ncbi.nlm.nih.gov/pubmed/?term=Alshaikh%20S%5BAuthor%5D&cauthor=true&cauthor_uid=29531571) Alshaikh, MBBS,* Zainab Harb, MB BCh

BAO, Eman Aljufairi, MD, and S. Ali [HYPERLINK](#)

["https://www.ncbi.nlm.nih.gov/pubmed/?term=Almahari%20SA%5BAuthor%5D&cauthor=true&cauthor_uid=29531571"](https://www.ncbi.nlm.nih.gov/pubmed/?term=Almahari%20SA%5BAuthor%5D&cauthor=true&cauthor_uid=29531571) Almahari, MD

7. Thyroid & parathyroid

Other thyroid nonneoplastic

Crystals

Author: Andrey Bychkov, M.D., Ph.D.

Topic Completed: 1 August 2017

Minor changes: 3 June 2021

Copyright: 2003-2021, PathologyOutlines.com, Inc.

PubMed search: Crystals [title] thyroid.

UNDER PEER REVIEW