

## **Oral submucous fibrosis with and without associated oral squamous cell carcinoma**

### **Abstract**

**Introduction:** Oral submucous fibrosis (OSF) is a potentially malignant disorder of the oral cavity. **Aims and objectives:** The core objective of the study is to analyze the oral submucous fibrosis with and without associated oral squamous cell carcinoma (OSCC). **Material and methods:** This cross sectional study was conducted in Baqai Dental College Karachi during October 2020 to June 2021. The data was collected from 100 patients of both genders who were confirmed with OSF on the basis of history and clinical examinations were included in the study. Demographic and clinical information were recorded. **Results:** The data were collected from 100 patients of both females and males. The age distribution of the sample was analyzed. The patients were mostly above 50 years of age in both categories. However, the number of patients who were with OSCC at an age below 50 was greater in the OSF-positive group (23.8% vs. 21.9%). Similarly, the mean age of OSF + OSCC patients was 57.5 years while this value was 59.5 years for those without. **Conclusion:** It is concluded that tumors show well-differentiated histology and less lymph node involvement. However, a statistical significance was not observed among these variables, when comparing the OSCC patients with OSF to those who are without.

### **Introduction**

Oral submucous fibrosis (OSF) is a potentially malignant disorder of the oral cavity. Oral squamous cell carcinoma (OSCC) is a critical health problem affecting millions of people worldwide. Despite the fact that the causes may fluctuate territorially, the course of the malady and enduring wins unflinching. The conceivably dangerous time of OSCC is a perspective that gives an advantageous way to deal with anticipation [1]. This period might

be showed as confined or summed up changes of the epithelium, driving towards carcinogenesis.

OSF may cause decay in the epithelium, consequently expanding the cancer-causing agent infiltration. Arecoline is a drying up operator and may recoil the cells enough to allow permeation of cancer-causing agents through the epithelium to arrive at the basal layer, which is the separating cell layer where neoplastic cell transformation may happen [2]. The penetrability of the epithelium to cancer-causing agents is a powerful instrument that may assume a job in arecoline-related carcinogenesis. Oral submucous fibrosis (OSF) is one such conceivably harmful condition that subjects the oral hole to a broad adjustment in morphology and physiology [2,4].

The clinical appearance contains the great set of three: whitening of the mucosa, consuming sensation on disturbance with fiery nourishment, and depapillation of the tongue [3]. These will be trailed by depigmentation of the lips and loss of flexibility of the mucosa with advancement of obvious stringy bands in the oral cavity, advancing from the foremost area to the back locale of the mouth [4]. There are additionally clear woody changes of delicate sense of taste and tongue, eventually bringing about loss of portability of the tongue alongside confined mouth opening [5].

Oral submucous fibrosis (OSF) is known as a ceaseless sickness which prompts constrained mouth opening and it being a pre harmful injury is another especially significant reality. It is every now and again found in the area of South and Southeast Asia where the vast majority of the individuals bite areca nut in its rough structure or with betel quid and tobacco. Areca nut has been arraigned as most grounded danger for causing OSF and as indicated by WHO particular, it has been named as a malignancy making substance the human [6].

## **Theoretical background**

Oral submucous fibrosis (OSF) is a chronic, progressive, premalignant condition. It has high prevalence because of dynamic powerlessness to open mouth due to juxta epithelial fibrous response and dynamic fibrosis of lamina propria [7]. The biting propensity for paan, chaliya, gutka, naswar, mava and manpuri are the potential danger of OSF in the creating nations like Pakistan. It has been seen that critical death pace of OSF can transform into oral squamous cell carcinoma (OSCC). It has been accounted for that TP53 mutation at DNA binding area was found in OSCC patients of Pakistan [8].

## **Aims and objectives**

The core objective of the study is to analyze the oral submucous fibrosis with and without associated oral squamous cell carcinoma (OSCC).

## **Material and methods**

This cross sectional study was conducted in Baqai Dental College Karachi during October 2020 to June 2021. The data was collected from 100 patients of both genders who were confirmed with OSF on the basis of history and clinical examinations were included in the study. Demographic and clinical information were recorded.

## **Exclusion criteria**

- All the patients who were suffering from any other major disease excluded from this study.

## **Data collection**

The data was collected through a questionnaire. All the demographic and social data were included in this designed questionnaire.

The study groups were divided into two:

1: OSF with OSCC

2: OSF without OSCC

All OSF patients presenting with an ulcer were biopsied under local anesthesia by the researchers. For histopathological examination biopsies were performed to confirm the diagnosis of OSCC.

### Statistical analysis

Each experiment was repeated three times and data were displayed as mean $\pm$ SD and analyzed through SPSS 22.0 (IBM, USA). Student t-test was applied for results in two groups and one-way ANOVA was for results more than two.  $P < 0.05$  was considered to have significant meaning.

### Results

The data were collected from 100 patients of both females and males. The age distribution of the sample was analyzed. The patients were mostly above 50 years of age in both categories. However, the number of patients who were with OSCC at an age below 50 was greater in the OSF-positive group (23.8% vs. 21.9%). Similarly, the mean age of OSF + OSCC patients was 57.5 years while this value was 59.5 years for those without.

**Table 01:** Demographic characteristics of all selected patients

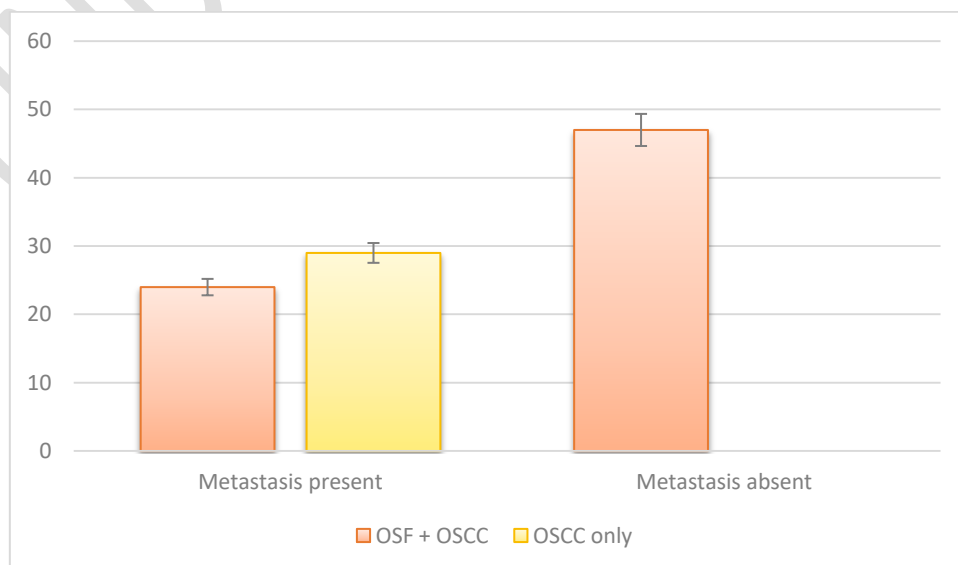
	OSF with OSCC	OSF without OSCC	P value
Sex	M: F	M:F	
	3.2	2.3	
Habits			
Betel quid chewing	99	23	<0.05
Quid with alcohol or smoking	13	10	
Alcohol and smoking	0	5	
All 3 habits	22	9	
Primary site			
Commissure	1	7	
Buccal mucosa	47	51	
Floor of the mouth	9	10	
Tongue	39	38	
Alveolar ridge (upper and lower)	30	33	
Lip	2	1	
Palate	0	5	

Degree of fibrosis and Histological differentiation			
Early fibrosis:			
EISCC	02	02	P=0.195
WDSCC	32	91	
MDSCC	15	42	
PDSCC	05	06	
Intermediate fibrosis:			
EISCC	03		
WDSCC	23		
MDSCC	16		
PDSCC	01		
Advanced fibrosis:			
EISCC	01		
WDSCC	16		
MDSCC	14		
PDSCC	02		
Lymph node metastasis	24 (22.6%)	29 (30.8%)	P=1.89

Lymph node metastasis was seen more among OSCC only patients (30.8% vs 22.6%). But this association was not statistically significant ( $p=1.89$ ). The degree of fibrosis was assessed in relation to metastasis.

**Table 2:** Nodal metastasis and its relationship with OSF.

	Metastasis present	Metastasis absent	Total
OSF with OSCC	24 (22.6%)	47 (48.3%)	100
OSCC without OSF	29 (30.8%)		



**Fig 1: Graphical representation of nodal metastasis and its relationship with OSF****Discussion**

In a recent study it was established that OSF was the main contributor to an increase in the age standardized incidence of oral premalignant lesions over a 14 years period. Another investigation has likewise revealed that OSF patients were more youthful and had shorter span of biting propensities [9]. Shah et al likewise affirmed that a higher extent of little youngsters normally utilized areca nut and its items. One more examination reports that OSF is progressively normal in second decade of life, and with expanding age more patients continued to OSCC [10].

In past examinations it has been indicated that the submucosa, in OSF, experiences neurotic changes because of over the top fibrosis, irregular collagen union, diminished vascularity, and hypoxia. Thusly, their pathway of harmful transformation takes course affected by hereditary and atomic adjustments [11]. The reason for anticipating early recognition, less attack, and metastasis might be because of over the top collagen fiber creation with expanded cross linkages that are not corrupted by collagenase [12]. Nonetheless, the diminished vascularity in a domain with fibrosis drags out the gathering of cancer-causing agents that pervade the mucosa and empowers their activity to last longer [13]. Eventually when tumor beginning happens, they may have distinctive prognostic ascribes in contrast with OSCC in a situation that needs OSF. Nearness of OSF was seen in 48% of the patients in the present investigation. This exists in the range 25.77% to 66%, saw in the writing [14].

**Conclusion**

It is concluded that tumors show well-differentiated histology and less lymph node involvement. However, a statistical significance was not observed among these variables, when comparing the OSCC patients with OSF to those who are without.

**COMPETING INTERESTS DISCLAIMER:**

**Authors have declared that no competing interests exist. The products used for this research are commonly and predominantly use products in our area of research and country. There is absolutely no conflict of interest between the authors and producers of the products because we do not intend to use these products as an avenue for any litigation but for the advancement of knowledge. Also, the research was not funded by the producing company rather it was funded by personal efforts of the authors.**

**References**

1. R. Gadbail, M. Chaudhary, M. Gawande et al., “Oral squamous cell carcinoma in the background of oral submucous fibrosis is a distinct clinicopathological entity with better prognosis,” *Journal of Oral Pathology & Medicine*, vol. 46, no. 6, pp. 448–453, 2017.
2. F. Guo, X. C. Jian, S. H. Zhou, N. Li, Y. J. Hu, and Z. G. Tang, “A retrospective study of Oral squamous cell carcinoma originated from oral sub mucous fibrosis,” *Zhonghua Kou Qiang Yi Xue Za Zhi*, vol. 46, no. 8, pp. 494–497, 2011.
3. P. Chaturvedi, S. S. Vaishampayan, S. Nair et al., “Oral squamous cell carcinoma arising in background of oral submucous fibrosis: a clinicopathologically distinct disease,” *Head & Neck*, vol. 35, no. 10, pp. 1404–1409, 2013.
4. N. R. Chourasia, R. M. Borle, and A. Vastani, “Concomitant Association of Oral Submucous Fibrosis and Oral Squamous Cell Carcinoma and Incidence of Malignant Transformation of Oral Submucous Fibrosis in a Population of Central India: A Retrospective Study,” *Journal of Maxillofacial and Oral Surgery*, vol. 14, no. 4, pp. 902–906, 2015.
5. S. Vaishampayan, P. Chaturvedi, S. Nair, and D. Nair, “O34. Oral cancers in patients with submucous fibrosis are clinico-pathologically different from those without submucous fibrosis,” *Oral Oncology*, vol. 47, pp. S39–S40, 2011.
6. G. Singh, A. S. Rana, A. Kumar, A. Prajapati, S. Kumar, and P. Singh, “Nodal involvement in Oral Squamous Cell Carcinoma (SCC) patients with and without Oral Sub

- Mucous Fibrosis (OSMF): A Comparative Study,” *Journal of Oral Biology and Craniofacial Research*, vol. 7, no. 3, pp. 171–177, 2017.
7. S. Pugazhendi, V. Thangaswamy, A. Venkatasetty, and L. Thambiah, “The functional neck dissection for lymph node neck metastasis in oral carcinoma,” *Journal of Pharmacy and Bioallied Sciences*, vol. 4, no. 6, p. 245, 2012.
  8. L. A. G. M. D. Ries and M. Krapcho, *SEER Cancer Statistics Review*, D. G. Stinchcomb et al., Ed., National Cancer Institute, Bethesda, MD, USA, 2008.
  9. M. Alkhalil, A. Smjilagic, and A. Redzie, “The lymph node neck metastasis in oral cancer and elective neck dissection as the method of choice,” *MedcinskiGlasnik*, vol. 4, no. 2, pp. 94-95, 2007.
  10. S. C. Sarode and G. S. Sarode, “Better grade of tumor differentiation of oral squamous cell carcinoma arising in background of oral submucous fibrosis,” *Medical Hypotheses*, vol. 81, no. 4, pp. 540–543, 2013.
  11. W. M. Tilakaratne, Z. Iqbal, M. T. Teh et al., “Upregulation of HIF-1 $\alpha$  in malignant transformation of oral submucous fibrosis,” *Journal of Oral Pathology & Medicine*, vol. 37, no. 6, pp. 372–377, 2008.
  12. R. P. Illeperuma, M. H. Ryu, K. Y. Kim, W. M. Tilakaratne, and J. Kim, “Relationship of fibrosis and the expression of TGF- $\beta$ 1, MMP-1, and TIMP-1 with epithelial dysplasia in oral submucous fibrosis,” *Oral Medicine & Pathology*, vol. 15, no. 1, pp. 21–28, 2010.
  13. S. Bazarsad, X. Zhang, K. Kim et al., “Identification of a combined biomarker for malignant transformation in oral submucous fibrosis,” *Journal of Oral Pathology & Medicine*, vol. 46, no. 6, pp. 431–438, 2017.
  14. M. Lingen, A. Pinto, R. Mendes et al., “Genetics/epigenetics of oral premalignancy: Current status and future research,” *Oral Diseases*, vol. 17, no. 1, pp. 7–22, 2011. View at Publisher ·

UNDER PEER REVIEW