

Acute polyarticular gout due to chronic kidney disease

ABSTRACT

Gout is a crystal deposition disorder that typically affects the first meta-tarsophalangeal joint of the great toe. Rarely gout can present as a poly-articular disease with involvement of multiple joints. Appropriate investigations like uric acid levels, renal function tests and synovial fluid analysis should be carried out in patient's polyarticular swelling to diagnose and evaluate polyarticular gout. Early diagnosis and treatment with urate lowering agents provides immediate pain relief and good outcomes.

Keywords- gout, acute polyarticular, chronic renal disease, mono-sodium urate crystals, multiple joint swellings

1. INTRODUCTION

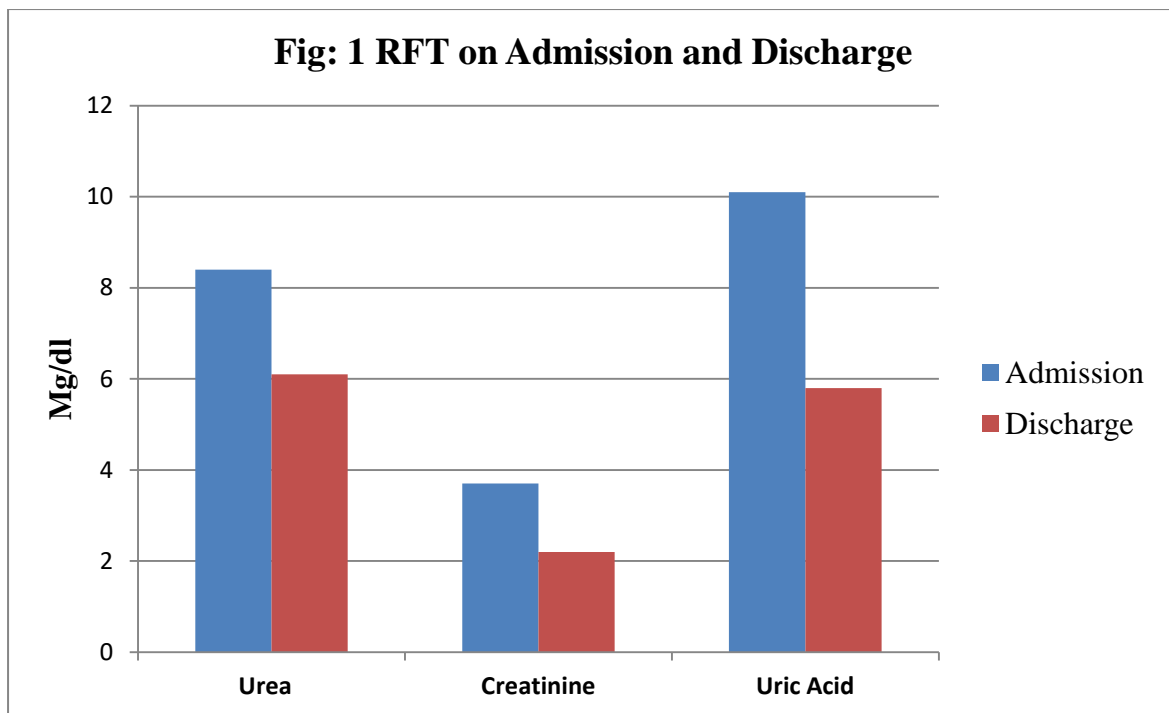
Gout is crystal deposition disorder caused by deposition of monosodium urate crystals in joints and other tissues secondary to hyper-uricaemia. Gout generally presents as uni-articular disease with 75 percent of affected individuals having involvement of first meta-tarsophalangeal joint alone (Solomon et al., 2010). Acute polyarticular gout involving multiple large joints is often underdiagnosed and undertreated. All joints with multiple joint swellings should always be screened for elevated uric acid levels.

Written consent was obtained from the patient to publish the clinical data.

2. CASE PRESENTATION

A 57 year old man came with complaints of pain & swelling of Left Knee, left elbow, right wrist & right finger for the past 10 days. There was no history of trauma and no history of fever. There was history of decreased urine output. There were no skin lesions. There was

history of surgery for coronary artery disease 3 years and patient was on medication for the same. Patient was not a known case of diabetes mellitus, hypertension, rheumatoid arthritis or chronic kidney disease. There was no history of allergies and no history of bingeing on alcohol or heavy protein meal. On Examination bilateral pitting pedal edema was present in both lower extremities. The patient's left knee, left elbow, right wrist & right proximal interphalangeal joint were warmth and Swollen. Range of motion at all the affected joints was painful & restricted. Immediately on admission tapping of his left knee joint was done for symptomatic pain relief and synovial fluid was sent for analysis. Analgesics were started and routine blood tests were done. Total count and inflammatory markers erythrocyte sedimentation rate (ESR), C-reactive protein (CRP) was found to be elevated. Synovial Fluid analysis showed increased white blood cell count (WBC) counts and negative birefringent, needle-shaped mono sodium urate crystals. Renal function tests showed (Fig 1) elevated urea (8.4mg/dl), creatinine (3.7mg/dl) & uric acid (10.1mg/dl) on admission. USG abdomen was then taken which showed bi-lateral contracted kidneys suggestive of renal parenchymal disease. Patient was then diagnosed to have acute onset poly articular gout secondary to chronic renal disease and patient was started on urate lowering agents (T. colchicine & T. febuxostat). Patient then improved symptomatically & was then discharged.



3. DISCUSSION

Acute polyarticular gout is frequently underdiagnosed and undertreated as its features are less familiar, when compared to acute mono-articular gout and chronic tophaceous gout (Solomon et al., 2010). Therefore in any patient presenting with acute polyarticular disease it is important to rule out of gout by checking serum uric acid levels as well synovial fluid analysis for crystals.

Gout frequently involves first metatarsophalangeal joint of foot in 75% of the cases even though other joints like knee, ankle, elbow, mid-foot & wrist can be involved (Raddatz et al., 1983).

Hyper-uricemia with or without gout is commonly present in patients with chronic renal disease and therefore renal function test and ultrasound abdomen should always be done in patients with elevated uric acid levels to rule out renal dysfunction as a cause for gout (Vargas-Santos et al., 2017).

4. CONCLUSIONS

Chronic kidney disease is frequently found among patients with gout. Gout is individually related with chronic kidney disease. Patients with gout would be actively screened for chronic kidney disease and its significances.

REFERENCES

1. Solomon L, Warwick D, Nayagam S, editors. Apley's system of orthopaedics and fractures. CRC press; 2010 Aug 27.
2. Raddatz DA, Mahowald ML, Bilka PJ. Acute polyarticular gout. Annals of the Rheumatic diseases. 1983;42:117-22.
3. Vargas-Santos AB, Neogi T. Management of gout and hyperuricemia in CKD. American Journal of Kidney Diseases. 2017 ;70:422-39.