

## **A CASE REPORT OF SCAPULAR FRACTURE TREATED USING ORIF PLATING.**

### **ABSTRACT:**

Scapular fractures are uncommon and are basically caused due to high-energy trauma<sup>1</sup>. Computed tomography with 3D reconstruction may be help in diagnosing the involvement of glenoid surface. Where a large number of case are managed conservatively but fracture with significant displacement may require operative fixation to achieve functional stability<sup>2</sup>. This a case report of 55years old male, presenting with displaced comminuted fracture involving the body of right scapula following a RTA trauma and having undergone open reduction internal fixation plating with excellent clinical outcomes with constant score of 100 following 1 year of regular follow-up.

**Keyword** : scapular fracture, high-energy trauma, open reduction internal fixation, constant score.

### **INTRODUCTION:**

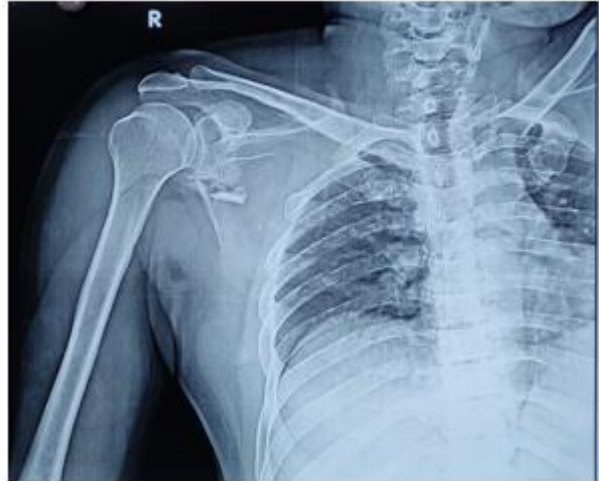Scapular fractures are uncommon type of fractures that represent only 5% of all shoulder injuries<sup>3</sup>. These types of fracture are caused due to high velocity trauma to the upper part of the shoulder resulting in malunion, with reduced range of motion and reduced shoulder strength<sup>6</sup>. So it is important to stabilize the fracture to regain the good clinical outcome. Here we report a case of scapular fracture following a road traffic accident fixed by ORIF with plating.

### **CASE REPORT:**

55year old male presented with complaints of pain over the right shoulder following trauma RTA 2 wheeler vs 2 wheeler patient landing on the dorsal surface of the thorax, associated with head injury with loss of consciousness. On clinical examination bruising noted over the right scapular region & shoulder movements were painful without any neuro-vascular deficit or any respiratory distress.

**ON RADIOGRAPHIC EXAMINATION:**

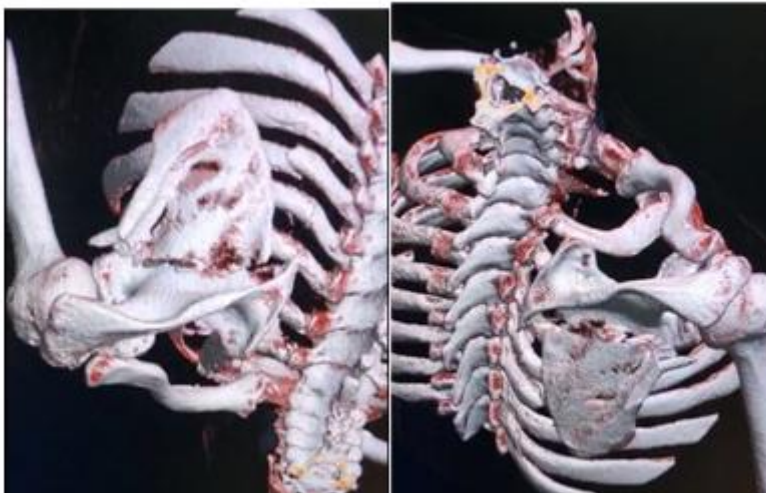
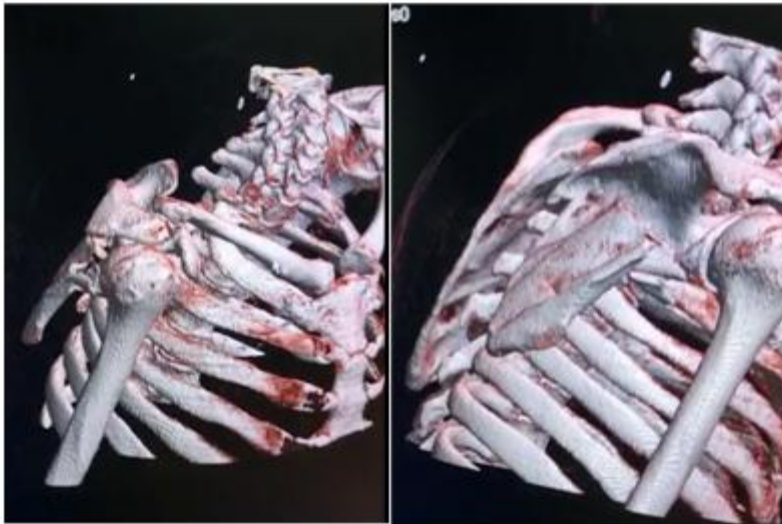
X-Ray shows comminuted fracture of the body of the scapula. CT study shows displaced comminuted fracture involving body of the right scapula with posterior displacement of distal fragment & fracture line seen extending to the spine of scapula and anteriorly to the coracoid process. Associated with fracture involving posterior aspect of right 4<sup>th</sup> to 7<sup>th</sup> ribs with displacement involving 4<sup>th</sup> and 5<sup>th</sup> ribs.



UNDER PEEI

EW

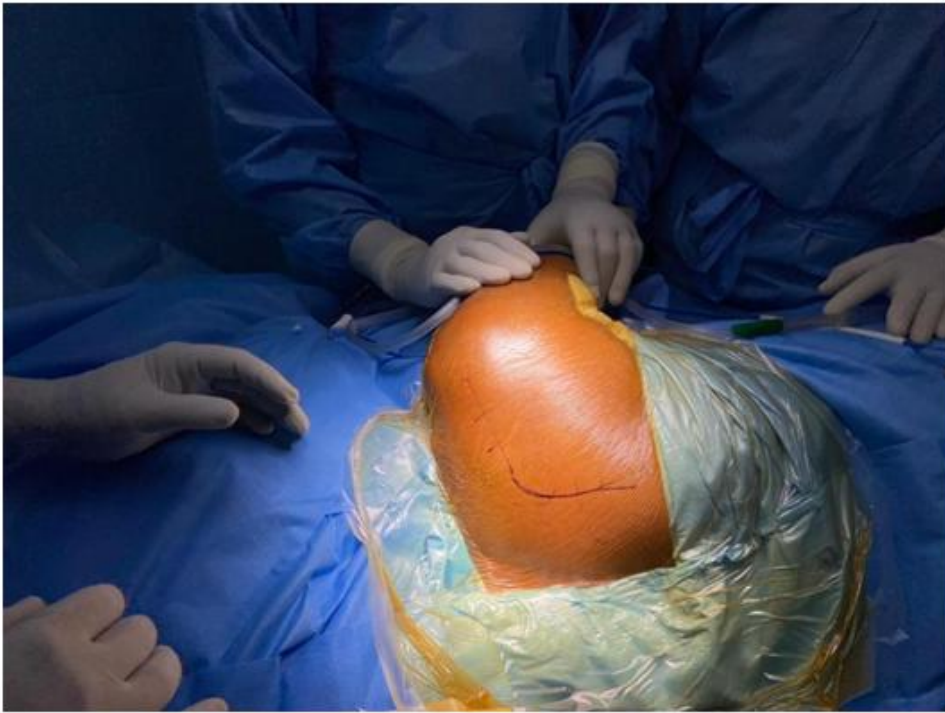



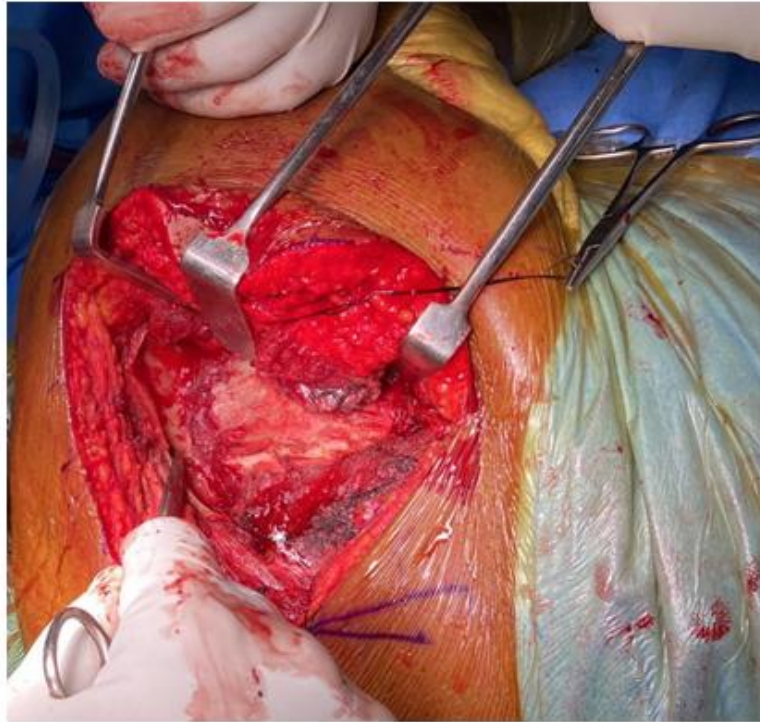
Since the x-ray and CT images are consistent with diagnosed of scapular fracture. Patient was performed open reduction internal fixation with plating. Patient in left lateral position position, approach – Judet’s approach, a 20cm Curvilinear incision is made from the postero-lateral angle of acromion extending along the spine of scapula (Horizontal incision) and continued as vertical incision along the medial border of the scapula. Skin & subcutaneous tissue cut & retracted, fibers of trapezius incised and retracted superiorly, posterior deltoid belly visualized, which was cut and retracted laterally. Fibers of Infraspinatus is visualized & erased from its attachment of scapula and retracted laterally & teres minor is retracted inferiorly. Fracture site visualized , which was fixed using 7 holed LC-LCP, the plate was pre-contoured and placed under the spine of scapula & fixed horizontally with 3 screws and vertically using 4 screws

along the medial border of the scapula. Reduction found to be satisfactory, incised muscle fibres are approximated & wound closed in layers.

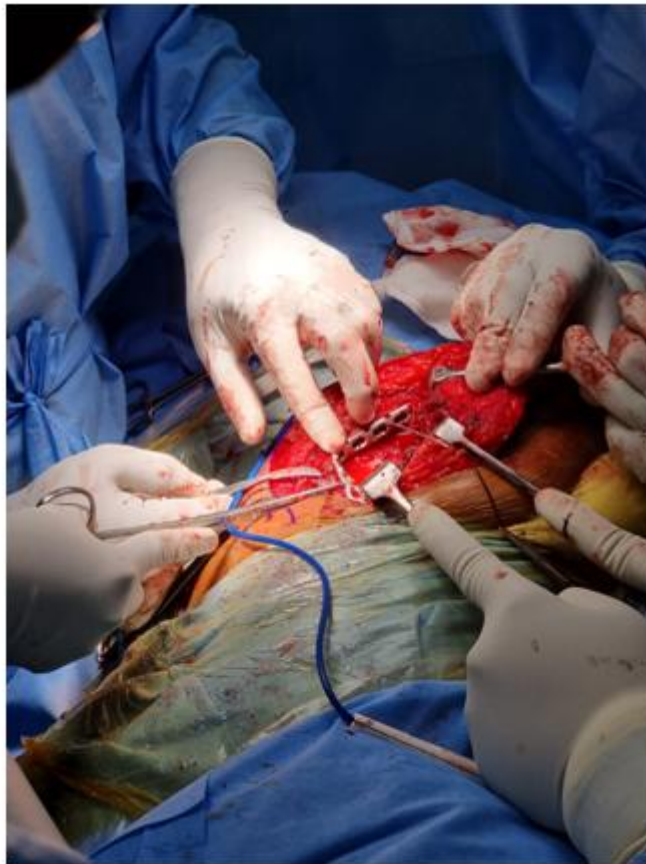
#### INTRA-OP PICTURES



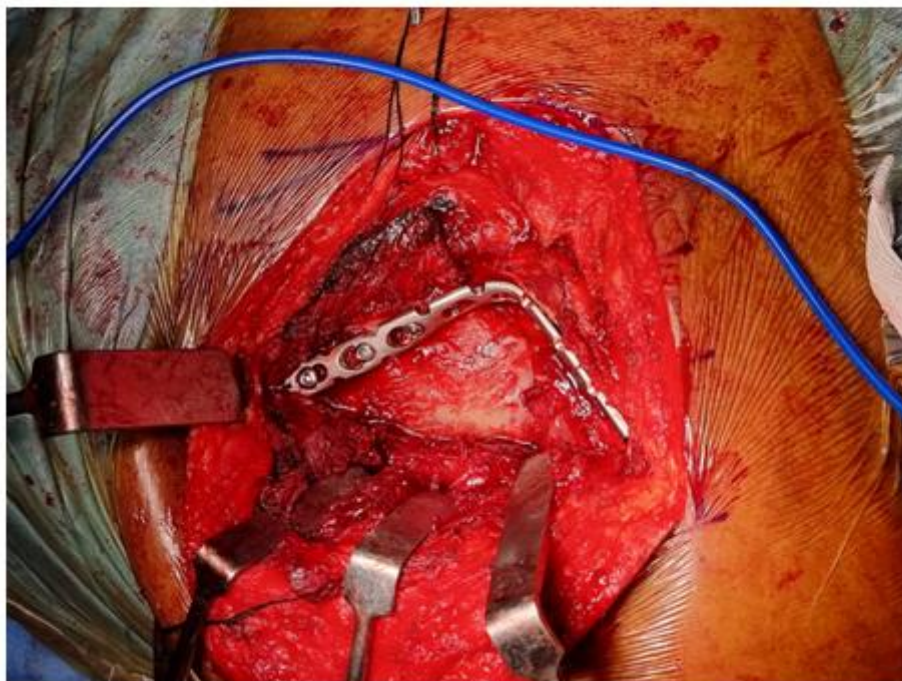
UNDER I



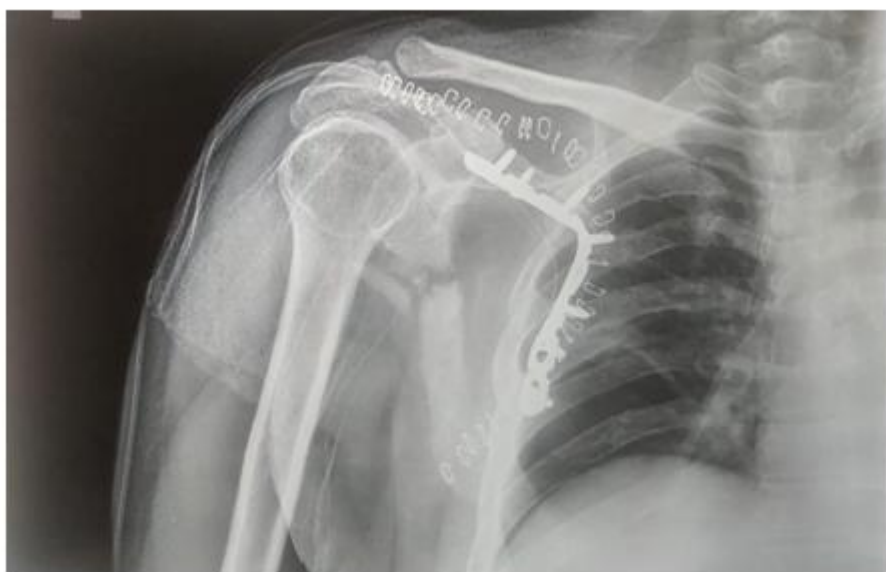FR

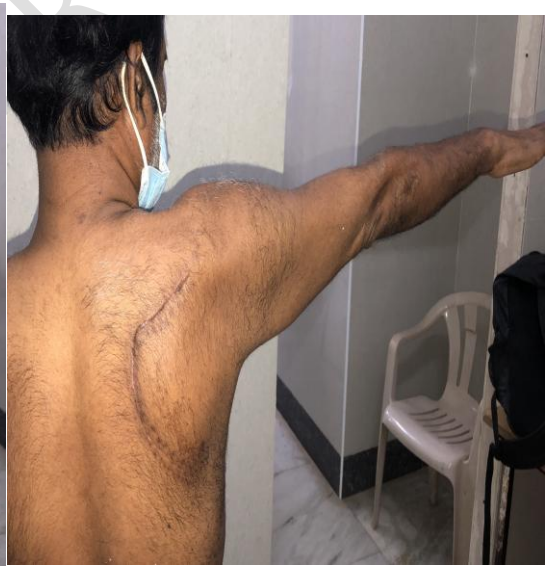
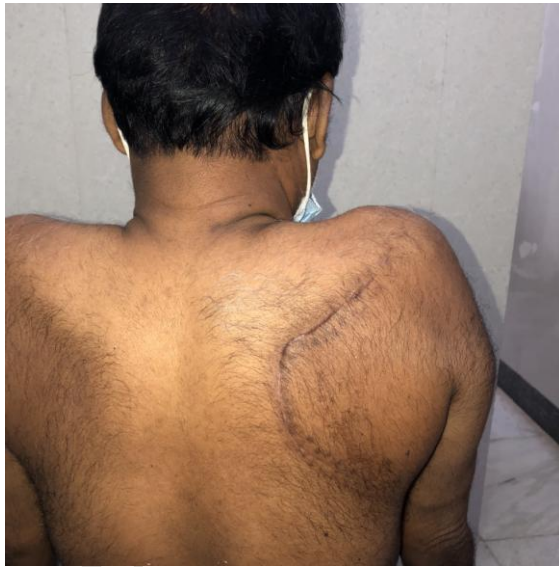
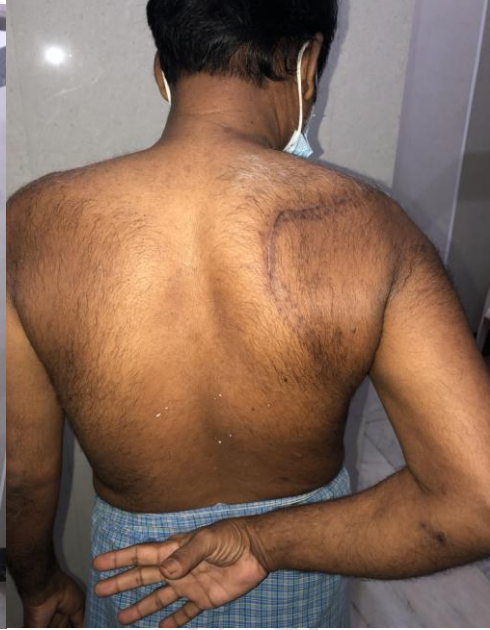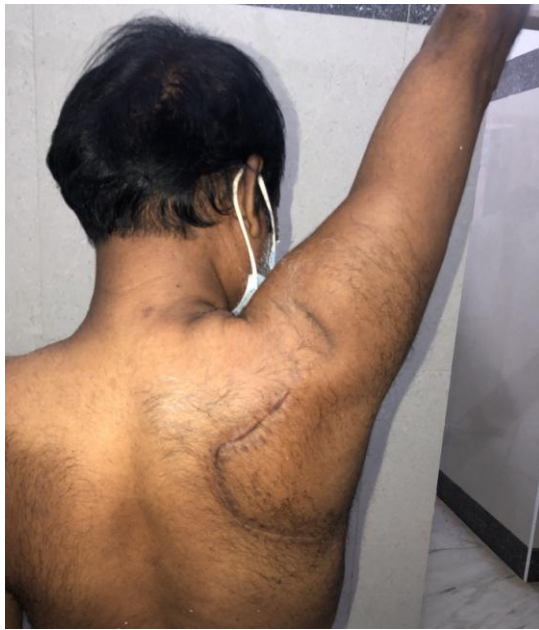FR



Post-op X-ray:





## **DISCUSSION :**

Scapular fracture are uncommon injuries in day to day trauma. It is often associated with pulmonary damage that can be life threatening<sup>6</sup>. A direct trauma over the posterior aspect of thorax by RTA is one of the common cause of this injury, other mechanisms where during seizures & electrocution.

Scapula fracture are classified based on anatomically by Zdravkovic and Dambolt which is three types, where type-1 involves scapula body (most common) , type-2 apophyseal fracture, including the acromion and coracoid ; type-3 fracture of superolateral angle, including scapular neck and glenoid. In our case it is type-1 fracture.

Computed tomography with 3D reconstruction is helpful in description the fracture line & rule out articular component of the glenoid<sup>5</sup>.

Fractures associated with glenoid involvement & open scapular fracture should be always treated surgical to avoid the risk of osteoarthritis of glenohumeral joint and stiffness and reduced range of motion<sup>8</sup>. So it is always important to do early surgical fixation and start the rehabilitation.

With absolute stability achieved after surgery, immediate active & passive mobilization should be started, with light strengthening and resistance in the initial phase , after 12weeks patient can return to his normal day to day activity<sup>9</sup>. To find out the clinical outcome constant score used for the assessment of shoulder joint.

In our case, it a scapular fracture of Zdravkovic and Dambolt type-1 involving the body, associated with rib fractures. Where for scapula treatment option chosen was ORIF with Plating. Which provide good stability, high chances of union and to achieve full range of motion of the shoulder joint.

## **CONCLUSION :**

The indication for surgery in scapular fracture are based on fracture displacement and angular deformity. The surgical risk of ORIF with plating in scapular fracture is relatively low across studies and relatively low-risk and provides 100% union. It also provide immediate effect by pain relief, quick recovery to daily day to day activity. hence we recommend surgical fixation for all displacement scapular fracture for better clinical outcome.

## REFERENCES:

1. ROWE CR. Fractures of the scapula. Surg Clin North Am. 1963;43:1565-71.
2. Butters KP. The scapula. In: Rockwood CA Jr, Matsen FA II, editors. The shoulder. Philadelphia: WB saunders.
3. Ada JR, Miller ME. Scapular fractures. Analysis of 113 cases. Clin Orthop Relat Res.1991;269.
4. Nordqvist A, Petersson C. Fracture of the body, neck, or spine of the scapula. A long-term follow-up study. Clin Orthop Relat Res. 1992;283.
5. Martin SD, Weiland AJ. Missed scapular fracture after trauma. A case report and a 23 year follow-up report.
6. Bozkurt M, Can F, Kirdemir V, et al. conservative management of scapular neck fracture; the effect of stability and glenopolar angle on clinical outcomes. Injury 2005.
7. McGahan JP, Rab GT, Dublin fractures of the scapula. J trauma. 1980; 20.
8. Armstrong CP, Van der spuy J. The fractured scapula; importance and management based on a series of 62 patients. Injury 1984.
9. Gagey O, Curey JP, Mazas F. Recent fractures of the scapula. Apropos of 43 cases.
10. Bartonicek J, fric V. Scapular body fractures: results of Operative treatment. Int Orthop. 2011.