

### **Success of Immediate Manual Detorsion of Testicular Torsion**

#### **Abstract**

Evidence shows that patients having testicular torsion usually present to the emergency department to apply immediate interventions. Immediate manual detorsion has been validated among different investigations as a productive technique for the initial management of testicular torsion. In the present literature review, we have elaborated on the success of manual detorsion for patients with torsion according to findings from previous relevant studies. Our findings indicate the favorable events that can be obtained after using manual detorsion. However, some studies reported that the success rate for the modality is not very high. In addition, it has been reported to reduce the time of ischemia as a temporary measure until surgery is prepared. Evidence also shows that the approach's efficacy is superior to that of surgical exploration and should be used since the time of diagnosis to prevent further deterioration of the affected case and enhance perfusion. However, the current evidence is based on a limited number of investigations that validated the efficacy of manual detorsion among a small population. Accordingly, we encourage further studies to be conducted in this context further to validate the current evidence with more adequate sample sizes.

**Keywords:** Testicular torsion; manual detorsion; emergency; management; efficacy.

#### **Introduction**

Evidence shows that patients having testicular torsion usually present to the emergency department to apply immediate interventions (1). The mechanism of the condition is initiated when the testes rotate around the spermatic cord (2). A remarkable impairment can follow this in the blood supply of the affected testicles that can subsequently lead to permanent ischemia and tissue infarction (1). Different factors can determine the severity of ischemia to the affected testicular tissue. These include the extent of rotation around the cord and the period until the management modality is conducted (2).

Estimates show that testicular torsion can affect different ages. However, it has been demonstrated that young infants are the most commonly affected with 12-18-year-old children. Furthermore, the peak incidence has been reported to occur at 13-14 years of age. Moreover, a previous study reported that 1 in every 4000 males < 25 years old are affected by testicular torsion (3). Therefore, early management of the condition is essential to enhance the prognosis. In addition, evidence shows that reduced infertility and testicular infarction rates have been associated with early diagnosis and management of testicular torsion. This can lead to improved testicular salvage rates with enhanced outcomes (4).

Immediate manual detorsion has been validated among different investigations as a productive technique for the initial management of testicular torsion (3, 4). In the present literature review study, we aim to shed more light on the success of immediate manual testicular detorsion for patients with torsion according to findings from previous relevant studies.

## **Methods**

To retrieve relevant studies, we conducted an extensive literature search of the Medline, Cochrane, and EMBASE databases which was performed on 27<sup>th</sup> October 2021 using the medical subject headings (MeSH) or a combination of all possible related terms, according to the database. To avoid missing potential studies, a further manual search for papers was done through Google Scholar, while the reference lists of the initially included papers. Studies

discussing success of immediate manual detorsion of testicular torsion were screened for useful information, with no limitations posed on date, language, age of participants, or publication type. Only Saudi-based studies were included.

## **Discussion**

Testicular torsion has been reported to be a timely challenge that should be immediately managed to prevent any histological changes regarding tissue perfusion and subsequent ischemia of the testicular tissues (5, 6). Following testicular torsion, evidence shows that following 4-6 hours after the initiation of ischemia, irreversible necrosis is usually observed in the affected scrotal tissue. Moreover, a previous study estimated that if the testis is not nourished after 24 hours from necrosis, 80% of the affected patients will eventually have orchiectomy (6-8). Prolonged duration interval between the onset of symptoms and treatment initiation was also reported to affect the quality of semen via well-established autoimmune mechanisms (9). Evidence shows that surgical exploration has been recommended as the first line of treatment of testicular torsion cases, with reported favorable outcomes regarding restoring the testicular normal blood flow and derotation of the spermatic cord (5, 6). However, the preparation of this procedure can consume a prolonged period that might extend for hours. This has been indicated in a previous investigation that showed that time loss between diagnosis and treatment had been estimated to be 80-90 minutes when surgical exploration has been planned, based on a five-year experience (10).

Among the different studies in the literature, evidence has been contradicting about the exact maximum duration of testicular salvage following torsion. For instance, a previous study reported that salvage was achieved at 7-12 hours postoperatively in 89% of the cases with testicular torsion. On the other hand, another similar study reported that a 4-8 hours delay after detorsion had been associated with reduced testicular salvage from 100% to 90%

postoperatively. Various investigations have reported manual detorsion in the literature as a valid technique for managing cases with testicular torsion. These studies have reported the high efficacy of the modality with minimal adverse events on the patient's outcomes. The modality was first introduced to the literature in 1893 to achieve immediate pain relief and prevent further ischemia of the affected testicular tissues (11-13). However, evidence indicates that testicular detorsion is not considered a definitive treatment modality, and some authors even call it a time-buying procedure. This is because the approach is usually used to reduce the severity of infarction when surgical preparation for managing torsion is being conducted. The technique of detorsion usually differs from the left side to the right side torsions, although the main steps are similar for both sides (**Figure 1**). It has been evidenced that a 180-degree rotation of the testes should be initially conducted clockwise in cases of testicular torsion to the left side. Following this, evidence indicates that the procedure can be repeated up to 2 or 4 times.

Moreover, it has been demonstrated that 180-720-degree rotations can also be needed in some cases. Repeated manual detorsion of the testes should be done by using clinical and radiographic parameters. For instance, using Doppler ultrasonography can be helpful in the assessment of blood flow to the affected testis, in addition to the clinical signs of pain relief as reported by the patient. On the other hand, evidence shows that the rotation should be conducted following the same previous steps but with a counterclockwise direction for right-sided testicular torsion. Following these steps, orchidopexy and surgical exploration should be performed as the definitive treatment modalities of testicular torsion and enhance the prognosis (10). Different studies have reported the efficacy of testicular detorsion. For instance, previous research by Demirbas et al. (10) said that among 26 patients that were included for testicular torsion, manual detorsion was successful in 20 of the included cases. It has been furtherly demonstrated that the

median days for performing a subsequent elective surgery following manual detorsion was ten days, at a range of 0-45 days. The authors also demonstrated that none of the included patients had any testicular torsion recurrent episodes within the period between manual detorsion and surgery. On the other hand, it has been estimated that patients indicated to have surgical exploration without performing testicular detorsion had a median ischemia free-time of 90 minutes, at a range of 20-40 minutes.

Evidence shows that the approach of immediate manual detorsion is routinely performed with needing general anesthesia of the affected patients. However, the current evidence demonstrated that patient compliance is an essential part of achieving successful detorsion. In addition, as we previously mentioned, pain can be used as a guidance tool to indicate recurrence of torsion and successful detorsion. Therefore, conducting anesthesia is not preferable for this reason. In addition, different contraindications were reported for conducting manual detorsion of testicular torsion. Some of these include the development of a reactive hydrocele, inflammation, and scrotal wall thickening (14). Previous studies also validated immediate testicular detorsion as a non-invasive, easy, and fast management modality for testicular torsion in adolescents and pubertal patients (12, 15). However, whether general or local, using anesthesia has been unfavorable in these events. This makes patients asymptomatic, which might mislead the attending surgeon about the relief of pain. Therefore, it is considered a landmark that the testis is in its proper position while still rotated. However, it has been previously demonstrated that patients usually remain symptomatic when other associated conditions, like epididymis-orchitis and torsion of the appendix testis (12).

On the other hand, some authors suggested that using anesthetic modalities and analgesics can be helpful in some cases. This has been attributed to inducing a remarkable relaxation of the

cremasteric muscles, which will subsequently lead to improved effectiveness of detorsion and enhanced risk of developing potential complications. Like opening a book, testicular detorsion should be conducted outwardly because the testis usually rotates inwards. However, a previous study estimated that the testis rotates laterally in around 1/3 of the cases (16). Moreover, it has been observed that the testes usually descend with the scrotum in cases when manual detorsion has been successfully achieved (17). Thus, residual testicular torsion can represent a hazard when testicular detorsion has been conducted due to the partially untwisted testicles. A previous investigation further demonstrated that 32% of the cases suffered residual testicular torsion (16). This is logical as it has been shown that testicular detorsion can be performed at a range of 180 to 1080°.

Evidence is also still controversial regarding the validity and efficacy of manual approaches or surgical exploration in these situations. For instance, some clinicians prefer manual detorsion and elective surgery, while others prefer immediate surgical exploration. Furthermore, although manual detorsion has been reported as a fundamental approach for the affected patients, it has been shown that choosing the appropriate management modality is dependant on the time since clinical manifestations occurred and the severity of the condition, in addition to the experience of the attending surgeon. Therefore, urgent surgical exploration should be conducted when manual detorsion cannot intervene against permanent testicular loss and infertility. However, evidence still indicates that orchiopexy will be definitely executed to achieve enhanced outcomes despite the reported efficacy. In this context, many previous investigations have reported that to prevent further deterioration in cases with testicular torsion, elective bilateral orchiopexy should be urgently conducted following a successful manual detorsion (12, 15, 18).

The rete of the testicular tissue reperfusion was also described in another investigation by Kutikov et al. (19) following detorsion secondary to the presence of localized compartment syndrome. It has been reported that testicular fasciotomy following testicular detorsion makes a window through the tunica albuginea. As a result, the authors noticed a normalization of the testicular color and a dramatic reduction in the intracompartmental pressure. This has been further indicated in another investigation by Figueroa et al. (20) that showed that testicular salvage was better among patients with fasciotomy with flap coverage of the tunica vaginalis following detorsion. A previous investigation compared the outcomes of patients with testicular torsion after detorsion, immediate orchiopexy, or orchiectomy. The authors reported that the median duration of pain was similar following detorsion and orchiopexy. However, it has been shown that the difference between the three groups in the same outcome was statistically significant (10).

Another case series study by Cattolica et al. (11) also reported that manual detorsion was successfully conducted in all included patients (n= 34). It has been furtherly demonstrated that the ischemic testis was successfully saved with no apparent adverse events, and retorsion was not observed in any of the included patients. Another case series in the Netherlands also demonstrated successful detorsion in 14 out of 17 patients with testicular torsion after manual detorsion. Orchiopexy was then performed in these patients, with a mean waiting time of 12 hours (range= 2-3 months). The authors also demonstrated that after following patients for 22 months following the surgery, neither testicular atrophy nor retorsion was reported by any included patients. However, manual detorsion was not successfully achieved in 3 of the included patients. This has been attributed to pain and excessive scrotal edema because no anesthesia was used in this investigation (12). Another investigation by Sessions et al. (16) also reported that

orchiopexy should not be postponed in patients with testicular torsion following manual detorsion. This is because residual testicular torsion was observed among 38% of the included patients. Finally, another 5-year-based investigation by Vasconcelos-Castro et al. (21) also validated the success of manual detorsion among the included patients. It has been reported that the success rate in their study was 26%. Moreover, 9% of the cases with unsuccessful manual detorsion approaches had gonadal loss. All of these cases were then indicated to have emergency surgical procedures.

## **Conclusion**

Some studies reported that the success rate for the modality is not very high. In addition, it has been reported to reduce the time of ischemia as a temporary measure until surgery is prepared. Evidence also shows that the approach's efficacy is superior to that of surgical exploration and should be used since the time of diagnosis to prevent further deterioration of the affected case and enhance perfusion. However, the current evidence is based on a limited number of investigations that validated the efficacy of manual detorsion among a small population. Accordingly, we encourage further studies to be conducted in this context further to validate the current evidence with more adequate sample sizes.

## References

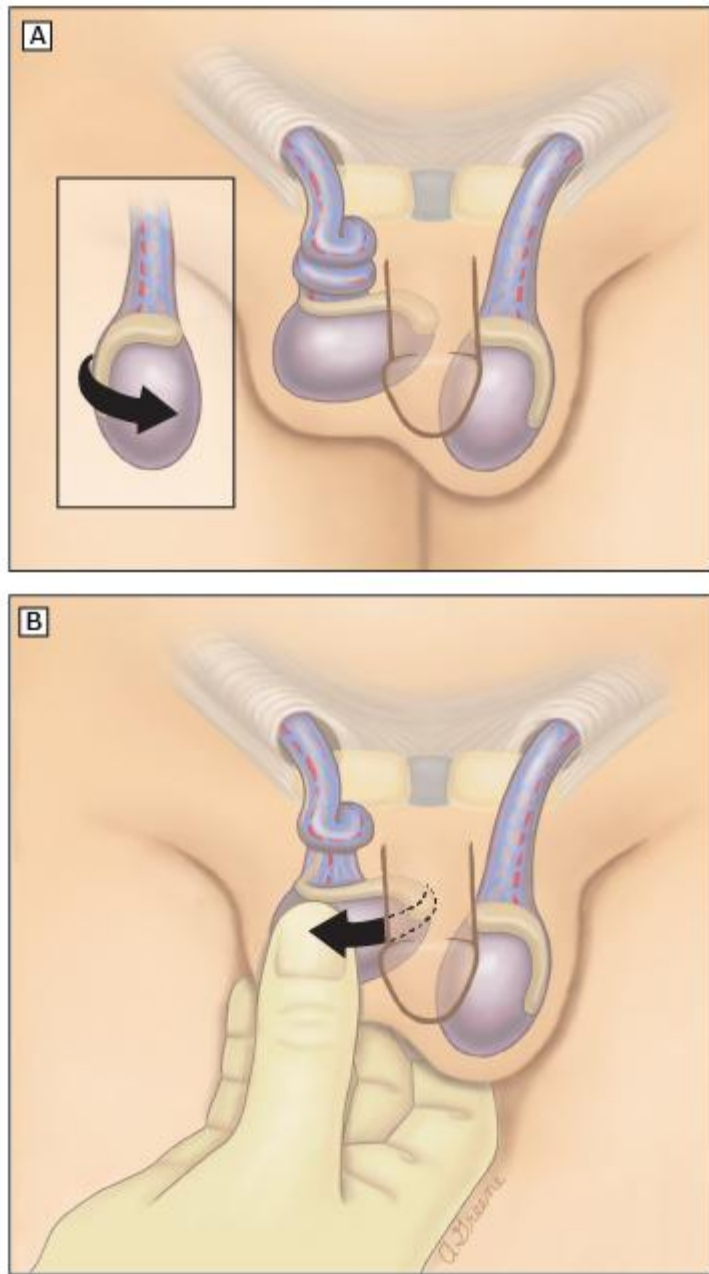
1. Korkes F, Cabral PR, Alves CD, Savioli ML, Pompeo AC. Testicular torsion and weather conditions: analysis of 21,289 cases in Brazil. *International braz j urol : official journal of the Brazilian Society of Urology*. 2012;38(2):222-8; discussion 8-9.
2. Fujita N, Tambo M, Okegawa T, Higashihara E, Nutahara K. Distinguishing testicular torsion from torsion of the appendix testis by clinical features and signs in patients with acute scrotum. *Research and reports in urology*. 2017;9:169-74.
3. Sharp VJ, Kieran K, Arlen AM. Testicular torsion: diagnosis, evaluation, and management. *American family physician*. 2013;88(12):835-40.
4. Laher A, Ragavan S, Mehta P, Adam A. Testicular Torsion in the Emergency Room: A Review of Detection and Management Strategies. *Open access emergency medicine : OAEM*. 2020;12:237-46.
5. Kapoor S. Testicular torsion: a race against time. *International journal of clinical practice*. 2008;62(5):821-7.
6. Tekgül S, Riedmiller H, Gerharz E, Hoebcke P, Kocvara R, Nijman R, et al. Guidelines on paediatric urology. *European Society for Paediatric Urology*. 2015:20-1.
7. Anderson JB, Williamson RC. Testicular torsion in Bristol: a 25-year review. *The British journal of surgery*. 1988;75(10):988-92.
8. Sessions AE, Rabinowitz R, Hulbert WC, Goldstein MM, Mevorach RA. Testicular torsion: direction, degree, duration and disinformation. *The Journal of urology*. 2003;169(2):663-5.
9. Anderson JB, Williamson RC. Fertility after torsion of the spermatic cord. *British journal of urology*. 1990;65(3):225-30.
10. Demirbas A, Demir DO, Ersoy E, Kabar M, Ozcan S, Karagoz MA, et al. Should manual detorsion be a routine part of treatment in testicular torsion? *BMC urology*. 2017;17(1):84.
11. Cattolica EV. Preoperative manual detorsion of the torsed spermatic cord. *The Journal of urology*. 1985;133(5):803-5.
12. Cornel E, Karthaus H. Manual derotation of the twisted spermatic cord. *BJU international*. 1999;83(6):672-4.
13. Kiesling VJ, Jr., Schroeder DE, Pauljev P, Hull J. Spermatic cord block and manual reduction: primary treatment for spermatic cord torsion. *The Journal of urology*. 1984;132(5):921-3.
14. Cornel EB, Karthaus HF. Manual derotation of the twisted spermatic cord. *BJU international*. 1999;83(6):672-4.
15. Drlík M, Kočvara R. Torsion of spermatic cord in children: a review. *Journal of pediatric urology*. 2013;9(3):259-66.
16. Sessions AE, Rabinowitz R, Hulbert WC, Goldstein MM, Mevorach RA. Testicular torsion: direction, degree, duration and disinformation. *The Journal of urology*. 2003;169(2):663-5.
17. Gatti JM, Murphy JP, editors. *Current management of the acute scrotum*. Seminars in pediatric surgery; 2007: Elsevier.
18. Sharp VJ, Kieran K, Arlen AM. Testicular torsion: diagnosis, evaluation, and management. *American family physician*. 2013;88(12):835-40.
19. Kutikov A, Casale P, White MA, Meyer WA, Chang A, Gosalbez R, et al. Testicular compartment syndrome: a new approach to conceptualizing and managing testicular torsion. *Urology*. 2008;72(4):786-9.
20. Figueroa V, Pippi Salle JL, Braga LH, Romao R, Koyle MA, Bägli DJ, et al. Comparative analysis of detorsion alone versus detorsion and tunica albuginea decompression (fasciotomy) with tunica vaginalis flap coverage in the surgical management of prolonged testicular ischemia. *The Journal of urology*. 2012;188(4S):1417-23.

21. Vasconcelos-Castro S, Flor-de-Lima B, Campos JM, Soares-Oliveira M. Manual detorsion in testicular torsion: 5 years of experience at a single center. *Journal of pediatric surgery*. 2020;55(12):2728-31.
22. Greenfield R. *Textbook of pediatric emergency procedures*. 1997.

UNDER PEER REVIEW

**Figure legends**

**Figure 1.** Manual detorsion of the right testicle (22).



MEV