

AN INTERESTING CASE OF MELIODOSIS

Running Title: AN INTERESTING CASE OF MELIODOSIS

ABSTRACT

20 year old male presented with history of fever, swelling over multiple sites of the body, reddish discharge from the swelling, with history of planting trees in the past. Routine investigation showed leucocytosis and multiple abscess in liver and spleen. Blood culture showed positive for burkholderia pseudomallei. Started treatment with meropenam and linezolid for 2 weeks and patient resolved from symptoms completely and discharged. Melioidosis is an infection caused by bacteria burkholderia pseudomallei. Here we discuss about an clinical course and treatment response to bacteria burkholderia pseudomallei.

Keywords: burkholderia pseudomallei, melioidosis, abscess

INTRODUCTION

Melioidosis is endemic in South East Asia, Asia and northern Australia. Infection usually follows percutaneous inoculation or inhalation of the causative bacterium, *Burkholderia pseudomallei*, which is present in soil and surface water in the endemic region. While 20–36% of melioidosis cases have no evident predisposing risk factor, the vast majority of fatal cases have an identified risk factor, the most important of which are diabetes, alcoholism and chronic renal disease (Currie, 2003). Melioidosis primarily affects persons who have regular exposure to soil and water, whereby the bacteria enters the human body via a penetrating injury or open wound, inhalation, or ingestion of contaminated food and water. Common clinical presentations include pneumonia, superficial and deep organ abscesses, bacteremia, and genitourinary and musculoskeletal infections (Lee and Lau, 2014). The present case report highlights an interesting case of melioidosis.

CASE PRESENTATION

20 year old boy doing graduation in botany in Bangalore came with history of fever on and off for 7 days, intermittent type, low grade fever. History multiple swelling all over the body with reddish discharge from the swelling (Figure 1, Figure 2, Figure 3), discharge aggravated while walking and relieved by rest. History of pain over the swelling, not a known case of diabetic, chronic kidney disease, no history of any drug intake in the past, no history of sexual contact. On examination patient was conscious oriented febrile, no signs of lymphadenopathy. Vitals were stable on admission. Routine investigation showed leucocytosis, raised ESR and CRP, raised serum alkaline phosphate, negative viral serology, USG abdomen showed multiple hypoechoic lesions with central hyperechoic pattern in the spleen. CT abdomen showed multiple small well defined, non enhancing hypodense lesions seen within liver and spleen (Figure 4). Blood culture and sensitivity showed gram negative organism within typical bipolar staining in the Gram stain and sensitive only to ceftazidime and meropenam and resistant to most of the antibiotics. Hence patient was started on injection meropenem 1g iv 8th hourly and Tablet linezolid 600 mg twice a day for 2 weeks. Surgery opinion sought out planned for incision and drainage over abscess procedure was uneventful. Patient was discharged after 2 weeks course of iv antibiotics with sulfamethoxazole/trimethoprim (800/180 mg) for 1 month and advised to review. Patient was reviewed after 1 month symptoms resolved completely (Figure 5, Figure 6).

DISCUSSION

Melioidosis is an infection caused by gram negative bacteria *Burkholderia pseudomallei* affect men mostly who had contact with soil [1]. The organism most commonly affects immunosuppressive patients like diabetes mellitus, chronic kidney disease, post organ transplant, patient on steroids. Among these the most common predisposing factor is diabetes mellitus [2]. The common presentation swelling over multiple sites resembling abscess over subcutaneous region, multiple joints involving knee, ankle, wrist. A recent study from Australia suggested that the most common involvement in melioidosis is bone and joint, with elevated erythrocyte sedimentation rate and C-reactive protein [3]. The disease rapidly progresses to septic shock, multiorgan failure and death.

The diagnosis is mainly any patient presents you with fever, joint pain, multiple swelling, and symptoms of pneumonia like cough, cold and breathlessness with history of soil contact

melioidosis should be ruled out. Sample should be sent for routine investigation and 2 samples for blood culture and sensitivity and pus culture and sensitivity before the start of antibiotics.

Treatment consists of two phases, acute phase and eradication phase. In acute phase parental antibiotic given for 2 weeks. Most of the antibiotic are resistant to burkholderia pseudomallei sensitive only to fewer antibiotics like amoxicillin with potassium clavulunate, cefotazidime, and carbapenems. Treatment with carbapenam has good outcome[4].In eradication phase oral antibiotics is given of 20 weeks recent study in Thailand suggested that preferred drug is Cotrimaxazole (sulfamethaxazole and trimethoprim)[4].

CONCLUSION

Due to increase in number of cases in India it is necessary to consider melioidosis when patient presents with bone and joint infection. Early diagnosis is mandatory as the virulence of the organism is high which cause septic shock and death.

COMPETING INTERESTS DISCLAIMER:

Authors have declared that no competing interests exist. The products used for this research are commonly and predominantly use products in our area of research and country. There is absolutely no conflict of interest between the authors and producers of the products because we do not intend to use these products as an avenue for any litigation but for the advancement of knowledge. Also, the research was not funded by the producing company rather it was funded by personal efforts of the authors.

REFERENCE

1. Hassan MR, Pani SP, Peng NP, Voralu K, Vijayalakshmi N, Mehanderkar R, et al. Incidence, risk factors and clinical epidemiology of melioidosis: A complex socio-ecological emerging infectious disease in the Alor Setar region of Kedah, Malaysia. BMC Infect Dis. 2010;10:302.
2. Gopalakrishnan R, Sureshkumar D, Thirunarayan MA, Ramasubramanian V. Melioidosis: An emerging infection in India. J Assoc Physicians India. 2013;61:612–4.

3. Shetty RP, Mathew M, Smith J, Morse LP, Mehta JA, Currie BJ. Management of melioidosis osteomyelitis and septic arthritis. *Bone Joint J.* 2015;97-B:277–82.
4. Dance D. Treatment and prophylaxis of melioidosis. *Int J Antimicrob Agents.* 2014; 43:310–8.
5. Currie BJ. Melioidosis: an important cause of pneumonia in residents of and travellers returned from endemic regions. *European Respiratory Journal.* 2003 Sep 1;22(3):542-50.
6. Lee P, Lau YL. Considerations for primary immune deficiency disorders in Asia. In: *Stiehm's Immune Deficiencies 2014* Jan 1 (pp. 965-976). Academic Press.

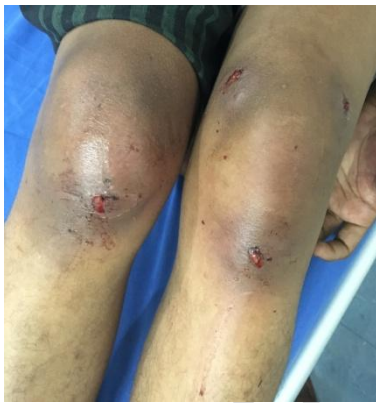

Figure 1 Abscess over bilateral knee joint

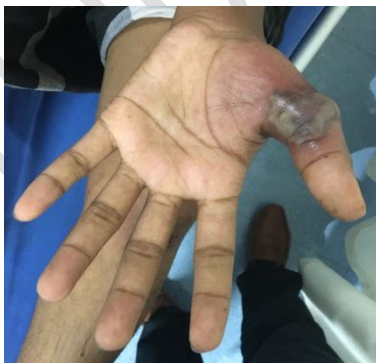

Figure 2 Abscess over Left Hand

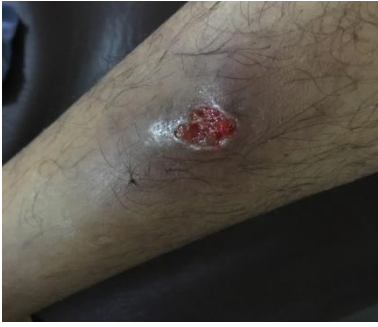

Figure 3 Abscess over Right Leg

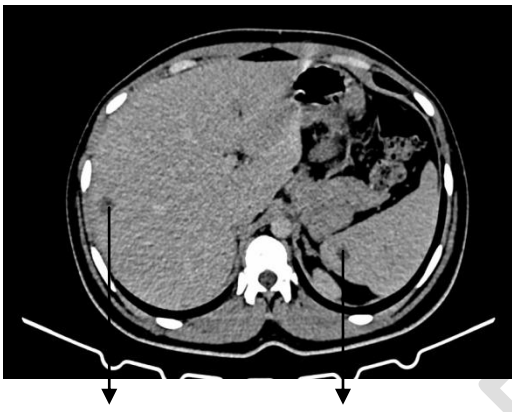


Figure 4 Abscess over liver and spleen

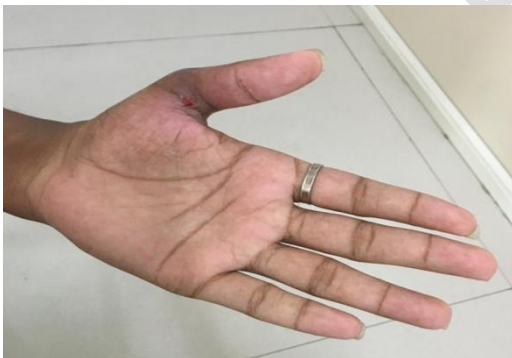

Figure 5 Resolution of abscess in hand

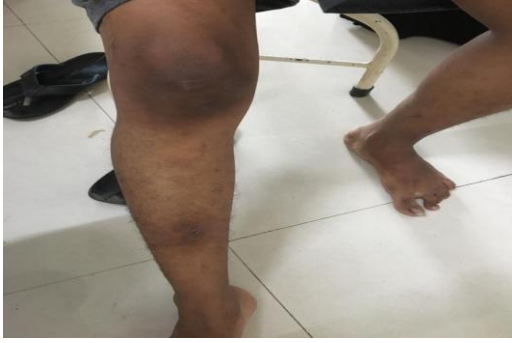

Figure 6 Resolution of abscess in leg

UNDER PEER REVIEW