

## **Case study**

### **Impact of short term exercise program on functional independence in patient with hydro pneumothorax: A Case Study**

#### **ABSTRACT:**

##### **Background:**

Hydro-pneumothorax is a rare variant of pneumothorax. It occurs when both free fluid and air is present within the pleural space. The goal of the treatment is to relieve the pressure on the lung, allowing it to re-expand. Treatment options may involve solely observation or needle aspiration or intercostal tube drainage (ICD), along with antibiotic cover, all of this anchored with physiotherapeutic management.

##### **Case presentation:**

A 54 years old male visited hospital with complaints of dyspnoea (MMRC grade II), dry cough and high-grade fever since one month along with a history of chronic alcohol consumption and tobacco chewing since more than 10 years.

##### **Investigations:**

Laboratory investigations include Chest X-ray which showed fairly large opacities with fluid level in right side. The costo-phrenic angle on the right side was obliterated, multiple small patchy opacities are also seen in right lower zones. Along with these findings, there was contralateral mediastinal shift.

##### **Treatment:**

Physiotherapy intervention included patient education, breathing retraining, airway clearance techniques, positioning, walking program with supplemented oxygen and psychological

support. Outcome measures have shown improvement in functional independence and performance of activities of daily living.

**Conclusion:**

Physiotherapy management showed efficient results in improving the lung function, quality of life, inducing relaxation and early return to pre-disease life in patient with hydro pneumothorax.

**KEY WORDS:** Hydropneumothorax, Physical activity, Functional independence  
Physiotherapy, Rehabilitation

**INTRODUCTION:**

Hydro-pneumothorax is a rare variant type of pneumothorax. It occurs when both free fluid and air present within the pleural space. Patients with hydro-pneumothorax presents with features of cardiorespiratory distress along side anorexia, cough and weight loss which alerted towards diagnosis. Physical examination reveals decreased breath sounds on the affected side and an audible succussion splash. (1)The cornerstone of establishing an etiological diagnosis in hydropneumothorax is extensive pleural fluid examination and investigations, including biochemical and microbiological work-up. Alongside along antimicrobial chemotherapy, ICD remains the management(2), ICD is a flexible plastic tube that is introduced into the pleural space through the chest wall.

Increased respiratory demands, such as increased breathing rate, reduced chest expansion and dyspnea, arise from the buildup of fluid and air. Physiotherapy including traditional breathing exercises are recommended because they maintain chest expansion, reduce dyspnea, and aid fluid drainage. Physiotherapists use a range of strategies to help persons with respiratory disorders alleviate and improve abnormal breathing pattern.(3) The objective of medical treatment for a hydro-pneumothorax is to relieve pressure on the lung and enable it to expand again. A second aim is determined by the severity of the lung collapse and, in certain cases, general health, depending on the origin of the hydro pneumothorax.(1,4) Observation, needle aspiration, chest tube insertion, non-surgical repair, and surgery are all possible strategies in resolution.

Positive expiratory pressure (PEP) treatment uses a threshold resistor or a fixed-orifice resistor to provide positive airway pressure. Patient-administered PEP breathing has been suggested as a successful therapy approach in these patients for eliminating mucus and increasing ventilation distribution. Increased oxygenation and, as a result, increased functional exercise capability may be the result of improved gas mixing. During exhalation, back pressure is applied to the airways, which helps PEP Therapy work. It allows more air to enter through the peripheral airways and collateral routes, re-inflating collapsed alveoli. Fluid migrates outside as pressure builds up distal to a blockage. (5) It can be given as 10 repetitions forming a set and 3 sets per sitting.

All respiratory treatment necessitates the use of positioning. It has an effect on the pulmonary volumes, decreases lungs collapsing, increases gas exchange (6) and stimulate normal physiological effect of gravity. Gravity and manual posture alter the distribution and ventilation of air in the lungs. (7–10)

#### **PATIENT INFORMATION:**

A 54 years old male visited respiratory medicine department with complaints of breathlessness (Modified medical research council scale grade II), dry cough and high-grade fever since one month. He also complaints of generalized weakness and loss of weight of about 2-3 kgs and has a history of chronic alcohol consumption and tobacco chewing since almost 10 years. Patient had undergone primary treatment in the private hospital but experienced no relief, he was referred to rural hospital at Sawangi, Wardha, where he underwent for various lab investigations followed by medical and physiotherapy management.

#### **CLINICAL FINDINGS:**

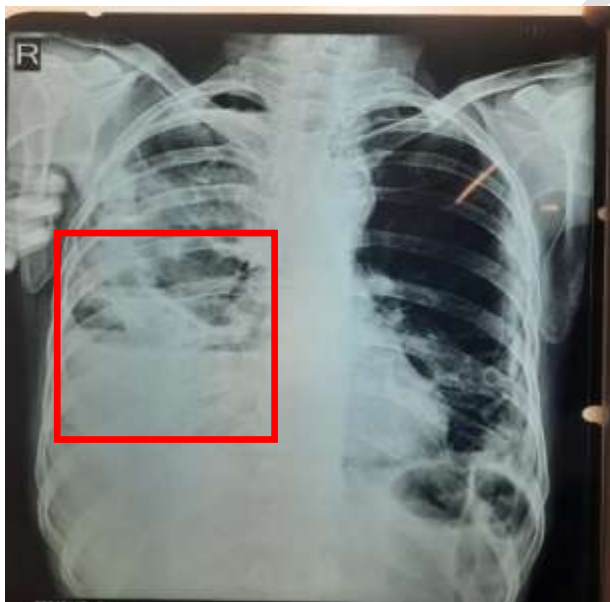
On observation, the patient was noted using accessory muscles while breathing. On examination, the patient was febrile (103°F) and pulse rate was 130 beats per minute, respiratory rate was 20 breaths per minute, blood pressure was 135/63mmHg and SpO<sub>2</sub>- 97% on 4 Liters of O<sub>2</sub>. On palpation, decreased tactile vocal fremitus on right side and chest expansion revealed a difference of 2cm, 2cm and 1cm at axillary, nipple and xiphisternum levels, respectively. On auscultation, decreased breath sounds on right side and crepitation were found bilaterally.

## TIMELINE

Date of admission	02/01/2021
Date of ICD Insertion	03/01/2021
Date of ICD Removal	12/01/2021
Date of discharge	25/01/2021
Date of follow up	10/02/2021

## DIAGNOSTIC ASSESSMENT:

Laboratory investigations showed WBC count 18,600/ml, rest all blood investigations are within normal limits. The arterial blood gases analysis revealed PO<sub>2</sub> as 69. Chest X-ray findings showed fairly large opacities with fluid level in right side. The costophrenic angle on the right side is obliterated. Multiple, small patchy opacities are present in right lower zones. Along with these findings, there was contralateral mediastinal shift.



**FIG:1** Chest X-ray showing right sided Hydropneumothorax

## THERAPEUTIC INTERVENTION:

Medical intervention: Intercostal tube drainage was the first line of treatment. Chest tube was inserted at the right side to drain out the fluid. The patient's call was noted for physiotherapeutic management.

Physiotherapeutic intervention: The goal of physiotherapy management for this patient was to resume his daily activities with minimal fatigue and least shortness of breath. Keeping the patient's goal in mind, our goal was to relieve dyspnea, relieve pain, improve ventilation, induce relaxation and overall functional status. The interventions given are summarized in the table 1. below.

Sr. No.	Intervention	Description	Advantage
1.	Counseling	Patient and his relatives were counseled about the need and importance of performing exercises.	Counseling is important for gaining the consent and adequate cooperation from the patient and his family members.
2.	Manual positioning	Semi-fowler's position was given for 2 hours in morning and afternoon each, persistently for 2 weeks.	Consequent change of the gravity effect and adapting various positions cause change in respiratory function at various intensities, it even aids in secretion clearance, skin breakdown prevention, facilitates diaphragm and improving ventilation perfusion.(7),
3.	Monitored in bed transitioning training	Half seated position (45 to 60 degrees) was promoted thrice a day for at least 10 minutes.	Good positioning helps preventing bed sores, facilitates drainage of secretions and improves ventilation.
4.	Breathing retraining exercises.	These exercises include breathing control, pursed lip breathing, segmental breathing and diaphragmatic breathing. He was advised to perform each exercise 10	It will improve the breathing efficiency, reduce the work of breathing and improve gas exchange and oxygenation.

		times, twice daily. However, The frequency of these exercises was fully controlled by the patient to avoid worsening effect of training.	
5.	Airway secretion clearance techniques.	Postural drainage (PD) positions and active cycle of breathing technique (ACBT). PD positions are given for 15-20 minutes along with manual percussion and vibration till the secretions comes in the central airways which can then be coughed out. ACBT is given as per patient's convenient frequency.	Tedious secretions can be coughed out using the following maneuvers and patient can rest in ease.
6.	PEP therapy	Flutter was given for 15-20 minutes with break of 1 minute every 3 minutes, this was given in sitting position and secretions were cleared using forced expiratory techniques whenever necessary.	To increase the expiratory capacity of the lung.
7.	Active range of motion exercises of upper and lower limbs.	Each range of motion exercise was given twice daily, with 8-10 repetitions at each joint.	To maintain the joint mobility this can be decreased because of prolonged immobilization.
8.	Monitored bed side mobilization techniques.	Patient was progressed from bed side sitting to standing to spot walking. As the patient's general condition was improved gradually, mild exercise training was started maintaining 3-4 on Borg's scale.	Early mobilization reduces the chances of prolonged immobilization complications such as disuse muscle atrophy, osteoporosis etc.
9.	Volume centered coach 2 incentive spirometer	Markings were recorded (changed from 400cc/sec to 600cc/sec to 800cc/sec to 1000cc/sec).	To increase the inspiratory capacity and vital capacities of the lung.

--	--	--	--

Table 1. Summary of in hospital physiotherapy interventions given in the patient.

### OUTCOME MEASURES

Table 2. Summarization of the outcome measures achieved in the patient in the following weeks.

Sr. No.	SCALES	Day -4	Discharge	Follow-up
1.	FIMS	Maximal assistance	Moderate assistance	Minimal assistance
2.	6MWT	Unable to perform	190m with rest pause	250m without rest pause
3.	HADS	Severe depression and anxiety	Moderate depression and anxiety	Moderate depression and anxiety

Outcome measures used included FIMS (Functional independent measure score) and 6MWT (6 minute walk test) and HADS (Hospital anxiety and depression scale). The outcome measures achieved in the subsequent weeks have been summarized in the following table 2.

### DISCUSSION:

This case shows a patient's initial complaint of breathlessness (MMRC grade II), dry cough and high-grade fever. General and systemic examination gave a clear picture of the condition which made it easy for the medical team to manage the patient's complaints easily. Our patient was put on oxygen support initially and underwent the chest tube drainage. Medical management along with physiotherapy management has shown excellent results in improving

the lung function of the patient. Along with regular physiotherapy management of a respiratory patient such as breathing exercises and postural drainage and mobilization, manual positioning and PEP therapy was also administered.

In a study done by Kasyap and Sagar (7), after administering semi-fowler's position, the tidal volume and functional residual capacities have been shown to increase along with better oxygen transport, hence, beside regular physiotherapy treatment in this patient manual positioning in semi-fowler's position was administered, which showed significant improvements in the vital parameters taken after 2 and 3 weeks.

PEP therapy was also proven effective by Ansari and Dhake, as they found that positive Expiratory Pressure treatment combined with conventional therapy improves respiratory parameters in patients with intercostal drain better than conventional therapy alone. During expiration, PEP treatment maintains a steady back pressure on the airways. It enhances ventilation and the length-tension connection of the inspiratory muscles.(5)

## **CONCLUSION:**

Well monitored in-patient physiotherapy management including therapeutic positioning, PEP along with regular physiotherapy such as mobilization, breathing exercises and airway clearance techniques shows brilliant results in bettering the lung function, quality of life, inducing relaxation and early return to pre-disease life in patient with hydro pneumothorax.

## **REFERENCES:**

1. EJBPS | ABSTRACT, 1 [Internet]. [cited 2021 Mar 21]; Available from: [https://www.ejbps.com/ejbps/abstract\\_id/5847](https://www.ejbps.com/ejbps/abstract_id/5847)
2. Garrod R, Lasserson T. Role of physiotherapy in the management of chronic lung diseases: An overview of systematic reviews. *Respiratory Medicine*. 2007 Dec 1;101(12):2429–36.
3. Morrow B, Brink J, Grace S, Pritchard L, Lupton-Smith A. The effect of positioning and diaphragmatic breathing exercises on respiratory muscle activity in people with chronic obstructive pulmonary disease. *South African Journal of Physiotherapy*. 2016 Feb 26;72.
4. Waqar M, Naqvi W, Thakre T, Deshmukh S. Crucial role of physiotherapy in treating COVID-19 patients. *International Journal of Research in Pharmaceutical Sciences*. 2020 Dec 22;11:967–71.

5. (PDF) Positive Expiratory Pressure (PEP) Therapy in Patients with Diseases of the Pleura | International Journal of Health Sciences and Research (IJHSR) - Academia.edu [Internet]. [cited 2021 Nov 17]. Available from: [https://www.academia.edu/44130686/Positive\\_Expiratory\\_Pressure\\_PEP\\_Therapy\\_in\\_Patients\\_with\\_Diseases\\_of\\_the\\_Pleura](https://www.academia.edu/44130686/Positive_Expiratory_Pressure_PEP_Therapy_in_Patients_with_Diseases_of_the_Pleura)
6. Koulouras V, Papathanakos G, Papathanasiou A, Nakos G. Efficacy of prone position in acute respiratory distress syndrome patients: A pathophysiology-based review. *World J Crit Care Med.* 2016 May 4;5(2):121–36.
7. EBSCOhost | 138553142 | Effect of Manual Positioning as an Adjunct to Intercostal Drainage in Hydropneumothorax. [Internet]. [cited 2021 Nov 9]. Available from: <https://web.a.ebscohost.com/abstract?direct=true&profile=ehost&scope=site&authtype=crawler&jrnl=09760245&AN=138553142&h=V4p%2f6DfwG3PmmPUzs0aH7E%2fvqKPxFeTa20XXwwQtSDLVGhOlvpvI0AGjOTknYvikPBdy1pqwNrU7Mqe11Pc0bw%3d%3d&crl=c&resultNs=AdminWebAuth&resultLocal=ErrCrlNotAuth&crlhashurl=login.aspx%3fdirect%3dtrue%26profile%3dehost%26scope%3dsite%26authtype%3dcrawler%26jrnl%3d09760245%26AN%3d138553142>
8. Lakkadsha TM, Kumar K, Naqvi WM, Phansopkar P. Pre-eminence of moderate to robust physical activity in battling COVID-19: A narrative review. *International Journal of Research in Pharmaceutical Sciences.* 2020;934–7.
9. Sinha RK, Sinha S, Varadharajulu G. Effectiveness of structured exercise protocol on functional performance in subjects with COVID-19. *International Journal of Research in Pharmaceutical Sciences.* 2020;1244–9.
10. A rare case report on post tuberculosis sequelae with right ventricular failure in young adult and the positive impact of cardio-pulmonary rehabilitation on functional independence. *IJPR* [Internet]. 2020 Jul 2 [cited 2021 Nov 8];12(sp1). Available from: <http://www.ijpronline.com/ViewSpecialArticleDetail.aspx?ID=321>