

Original Research Article

Evaluation of Sodium Valproate-Induced Hepatotoxicity and Protective Role of Vitamin C (Ascorbic Acid) and Silymarin in Adult Albino Rats

Running title:

Vitamin C and Silymarin protect against Sodium Valproate-Induced Hepatotoxicity

Abstract:

Background and objectives: Drugs hepatotoxicity is one of the most prevalent problems seen in medical practice. Many medications are linked to hepatotoxicity, including sodium valproate (VPA). The objective of this study is to investigate the preventive impact of silymarin (SIL) and /or vitamin C (Vit.C) on hepatotoxic Sodium Valproate in albino Rats. **Methods:** Thirty adult male albino rats were divided equally into six groups; group (I): normal control, group (II): VPA, group (III): VPA + SIL, group (IV): VPA+ Vit.C, and group (VI): VPA + SIL +Vit.C. The animals were killed after 14 days, and livers were taken for histological and biochemical analysis. **Results:** After 14 days, animals were sacrificed, and livers were collected for histopathologic examination and biochemical assessment. VPA group exhibited a significant increase in serum alanine aminotransferase and aspartate aminotransferase. Liver sections showed loss of normal pattern of hepatocytes, inflammatory infiltration, congested central vein and fatty infiltration. Each of ascorbic acid and silymarin partially improved th the histological pattern of the liver. When they were combined together, they depict marked improvement in the measured parameters and showed normal liver sections. **Conclusion:** silymarin (SIL) and /or vitamin C (Vit.C) has hepatoprotective effects against VPA induced toxicity on liver.

Keywords: Hepatoprotective; sodium valproate; silymarin; vitamin C; liver enzymes; histological examination

1. Introduction:

Within the human body, the liver is the largest organ. It supports nearly every other organ in the body by performing metabolic, synthetic, and excretory activities. The liver is responsible for a number of important metabolic activities, including the elimination of poisons and other xenobiotics. The liver is vulnerable to a variety of injuries due to its strategic position and multifaceted roles, including acute liver damage, hepatitis, cholestasis, non-alcoholic fatty liver disease, fibrosis, and cirrhosis, and eventually hepatocellular cancer. The human body is incapable of coping with any changes in these critical processes that arise as a result of substantial liver damage [1,2].

Valproic acid (VPA) is a medication that can be used to treat epilepsy, migraines, and bipolar disorder. Although a powerful medication, it has significant adverse effects in animals and humans, including pancreatitis, thrombocytopenia and platelet aggregation[3–5]. VPA, like other xenobiotics, is metabolized in the liver and causes broad dose-independent hepatotoxicity, which can lead to permanent catastrophic liver failure [6]. While several research have attempted to discover the hidden mechanism of VPA's hepatotoxic action, it remains unknown. Mitochondrial fatty acid oxidation dysfunction and ATP depletion appear to be important contributors. Furthermore, oxidative stress is considered to play a role in mediating VPA-induced hepatotoxicity by producing reactive oxygen species, increasing lipid peroxidation, and depleting antioxidant enzymes [7–9]. Because VPA is still widely used, finding novel treatments to prevent its hepatotoxic effects may be critical.

Silymarin (SIL), an antioxidant flavonoid complex derived from the herb milk thistle (*Silybum marianum*). SIL is made up of four flavonolignan isomers: Silybin, Isosilybin, Silydianin, and Silychristin. It is taken orally and eliminated mostly as sulfates and conjugates in the bile [10,11]. Alcoholic liver illness, liver cirrhosis, viral hepatitis, drug-induced liver diseases, and diabetes have all been treated with silymarin. It's believed to help with protein synthesis, liver tissue regeneration, inflammation reduction, glucuronidation improvement and glutathione protection [12]. Silymarin has been demonstrated in clinical and experimental investigations to have antioxidative, anti-lipid

peroxidative, antifibrotic, anti-inflammatory, membrane stabilizing and immunomodulatory properties [13].

Ascorbic acid, often known as "vitamin C," is a well-known vitamin found in a variety of fruits and vegetables [14]. Ascorbic acid has an important physiological role in cells as a reducing agent, antioxidant and free radical scavenger [15]. Ascorbic acid supplementation improve liver function and prevent fibrosis in patients with non-alcoholic steatohepatitis[16]. Furthermore, ascorbic acid reduces hepatic injury in an experimental model of acute ischemia in rats[17].

So that, the objective of the current study is to investigate the preventive impact of silymarin and / or vitamin C on hepatotoxic Sodium Valproate in albino Rats.

2. Materials and methods:

2.1. Animals:

Adult male albino rats weighing 220 g n=30, were acclimated at the King Fahd Medical Research Center's Animal House, Department of Medicine, Faculty of Medicine, King Abdul-Aziz University, Jeddah, Saudi Arabia. Ethical approval was obtained from the institution's Bioethics and Research Committee under the reference number of (442-42-60688-DS).

2.2. Materials:

Sodium valproate (VPA), Silymarin (SIL), and diagnostic kits were purchased from Sigma Aldrich Chemicals, (St. Louis, Missouri, USA). For intraperitoneal (I.P.) injection, VPA was dissolved in 0.9 percent w/v saline. Vitamin C (Vit.C) was purchased from local pharmacy in Jeddah in the form of tablets, each containing 500 mg of ascorbic acid. SIL was purchased in the form of sachets containing 140 mg of SIL. Each of SIL and Vit. C were suspended in 5.0 mL of distilled water and received orally once daily.

2.3. Experimental study:

30 adult male albino rats were weighed and placed into five groups (n = 6) at random. By injecting VPA (700 mg/kg, I.P.) twice daily for 14 days, liver damage was produced as described by Nazmy et al [5]. **Group I (Control)** received 0.5 ml of distilled water, once daily and twice daily I.P normal saline. **Group II (VPA)** rats received VPA [5]. **Group III (VPA+ SIL)** rats received VPA and SIL 50 mg/kg [18,19]. **Group IV (VPA +Vit.C)** rats received VPA and Vit.C 200 mg/kg [19]. **Group V (VPA + SIL +Vit.C)** rats received VPA, Vit.C and SIL. All drugs were given for 14 days. One day after the previous treatment, the control and treated groups were fasted overnight before being killed under ether inhalation anesthesia.

2.4. Methods:

2.4.1. Histological examination:

After being exposed to ether in a desiccator housed under a working hood, animals were decapitated and slaughtered. The livers were rinsed with ice cold saline then was fixed in 10% neutral buffered formalin, embedded in paraffin, sectioned (4 to 5 μ m), and stained with hematoxylin and eosin (H&E) as well as Masson trichrome stain [20]. Slides were examined and taken images by using Olympus BX51 microscope (Tokyo, Japan).

2.4.2. Blood Sampling:

Before they were culled, blood samples were extracted by cardiac puncture, centrifuged, and serum was collected for the assessment of hepatotoxicity markers. Blood samples tubes were centrifuged to extract serum samples (3000 rpm for 10 minutes). Reitman and Frankel's technique [21] was used to measure serum alanine aminotransferase [ALT] (U/L) and aspartate aminotransferase [AST] (U/L). The amount of pyruvate or oxaloacetate generated by synthesizing 2, 4-dinitrophenylhydrazine was used to assess ALT or AST calorimetrically, which has a color wavelength of 546 nm.

2.5. Statistical analysis:

Data were expressed as mean \pm standard error of the mean (SEM) and were analyzed by IBM SPSS Statistics for Windows, version 26 (IBM SPSS, IBM Corp., Armonk, N.Y., USA) for comparative analysis between pairs of groups using ANOVA followed by Tukey's multiple comparison test and with software GraphPad Prism version 9.

3. Results:

3.1. Haematoxylin & Eosin (H&E) staining:

Examination of H&E-stained sections of the liver collected from the **control group** revealed the normal histological architecture of the liver. The control liver was formed of classical hepatic lobules; each lobule was formed of a central vein with cords of hepatocytes radiating from the central vein towards the periphery of the lobule (Fig. 1A). The portal tracts appeared normal and contained branches of the hepatic artery, portal vein, and bile duct (Fig. 1B). Sections from the **VPA group** revealed many histopathological changes, such as hepatocellular damage that was clearly evident through the hepatic steatosis (macro and microvesicular) and inflammation. Mononuclear inflammatory cell infiltrate, enlarged kupffer cells, dilated and congested central veins with disarray of hepatocytes were also seen. There was marked dilatation and congestion of the central vein and blood sinusoids (Fig. 1C). The portal areas showed peri-portal cellular infiltration, dilated congested portal vein and hepatic artery branches and proliferation of bile duct (Fig. 1D). However, sections from **VPA + SIL group** (Figs. 1E & F) and **VPA + Vit.C group** (Figs. 1G & H) revealed less degenerative changes, compared to the **VPA group**. In particular, **VPA + SIL + Vit.C group** revealed marked improvement of the liver and appeared nearly as to the control rats (Figs. 1I & J).

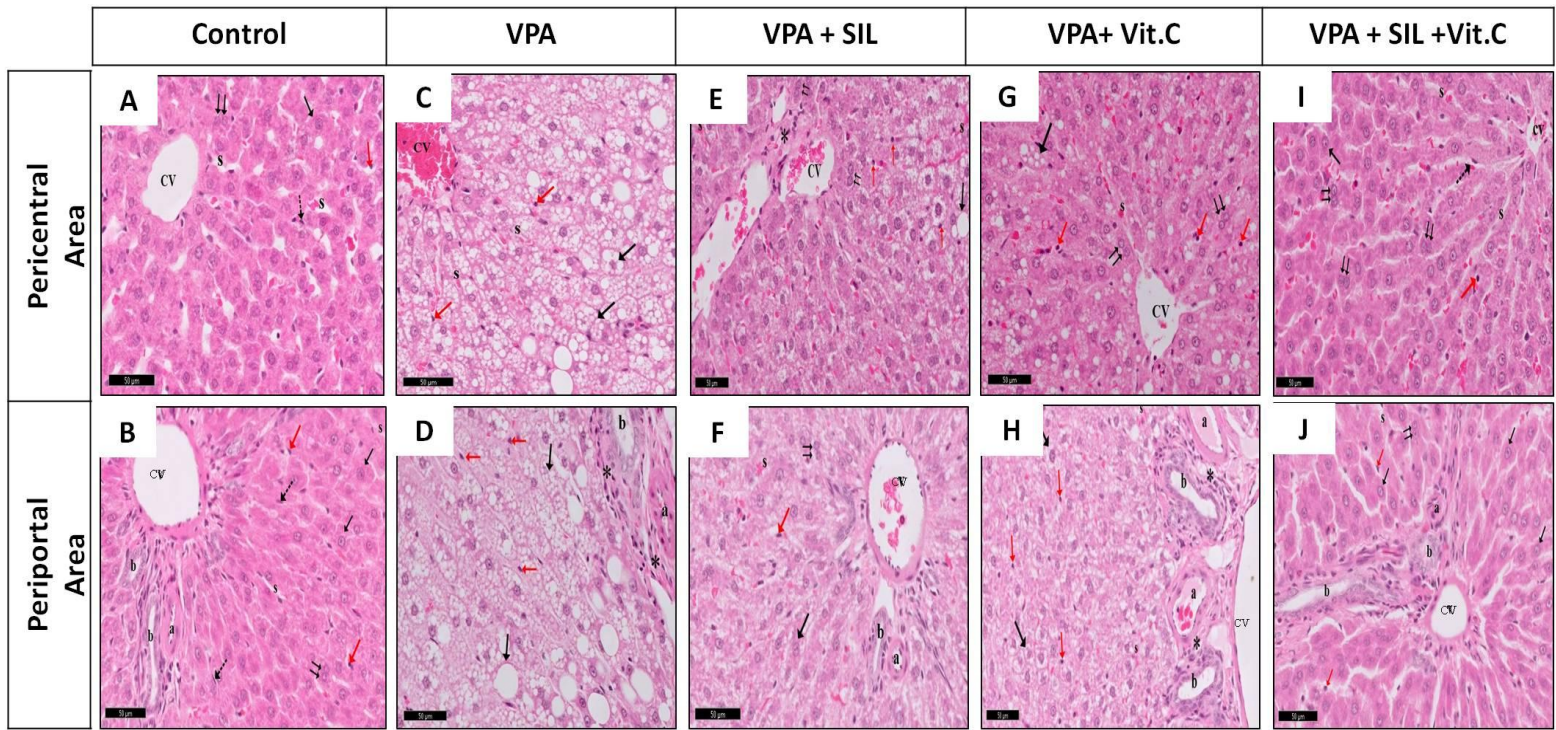


Figure. 1. Photomicrograph of H&E-stained (original magnification X 400) liver sections in the pericentral and periportal area of the different groups:

(A & B) **Control group** showing normal hepatic architecture with the hepatic lobule formed of cords of hepatocytes (↑) some are binucleated (↑↑), Kupffer cells (red arrow), and sinusoids (s) lined with endothelial cells (dot arrow). Portal tract containing portal vein (V), hepatic artery (A), bile duct (B). (C & D) **VPA group** showing marked steatosis and inflammation. Dilated and congested central veins (CV) with disarray of hepatocytes with most of the hepatocytes with the presence of microvesicular and macrovesicular steatosis (↑). Kupffer cells are increased in size (red arrow). Marked dilatation and congestion of portal vein (v) with massive periportal cellular infiltration (*).

Note proliferation of bile duct (B). (E & F) **VPA + SIL group** and (G & H) **VPA + Vit.C group** showing near normal hepatic architecture with mild congestion of central vein (CV) and portal vein (v). Few hepatocytes show microvesicular and macrovesicular steatosis changes (↑) and apparent increase of binucleated cells (↑↑). Normal appearance of Kupffer cells (red arrow), and mild congestion of blood sinusoids (s) and inflammatory cells are few (*). Note proliferation of bile duct (B). (E & F) **VPA + SIL + Vit.C group** shows normal histological structure of central vein (CV), portal area and surrounding hepatocytes.

3.2. Masson's trichrome staining.

Masson's trichrome-stained sections of the control group I revealed few collagen fibers around the central veins, and in the portal tract area. (Figs. 2 A, B). The stained sections of the **VPA group** revealed marked increase of collagen fiber deposition around the central veins, in the portal tract areas, and in the perisinusoidal spaces (Figs. 2 C, D). Sections from **VPA + SIL group** (Figs.2E &F) and **VPA + Vit.C group** (Figs.2G & H) showed a noticeable reduction in collagen fiber deposition compared with the **VPA group**, especially in **VPA + SIL + Vit.C group**, which showed presented as nearly similar to the control (Fig.2 I &J).

3.3. Effect on serum hepatotoxicity parameters

The serum enzyme markers of the liver as aspartate aminotransferase (AST),and alanine aminotransferase (ALT) for both control and experimental groups are presented in **Table 1 and Figure3 A &B**. There were significant increases in the AST and ALT in the serum of treated rats of **VPA group**, in contrast with the control rats. Moreover, there was a significant decrease in the serum activity of AST and ALT of those treated with **VPA +SIL** group, treated with **VPA + Vit.C**, and **treated with both VPA + SIL + Vit.C** as compared to **VPA** only. While there was no significant difference between **VPA + SIL + Vit.C and control group**.

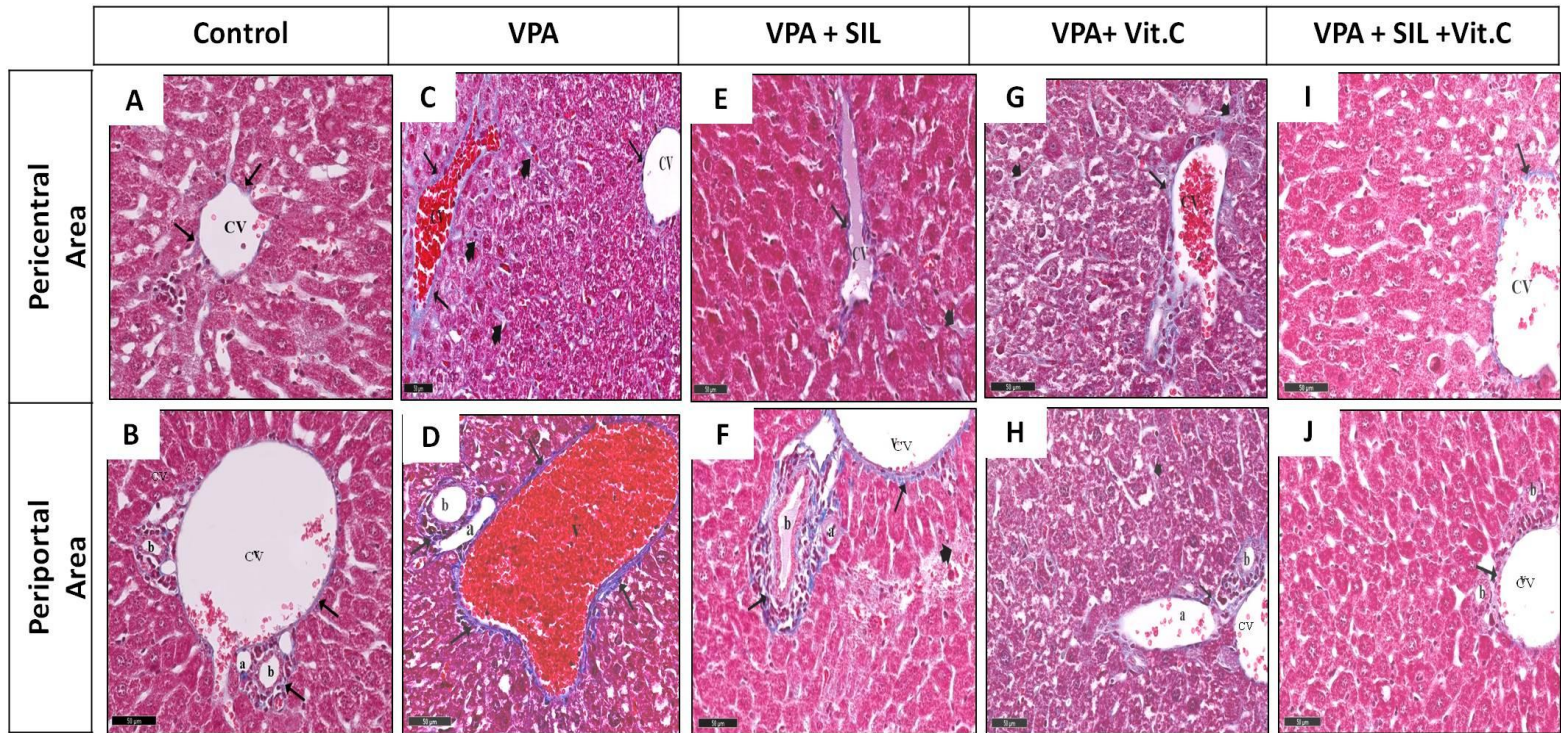


Figure. 2. Photomicrograph of Masson's Trichrome-stained (original magnification X 400) liver sections of the different groups:

(A & B) Control group showing minimal collagen fibers (↑) around the central vein and in the portal tract area. **(C & D) VPA group** showing extensive collagen fibers (↑) accumulation around a dilated central vein (CV), in the portal tract area and extending in the perisinusoidal spaces. **(E & F) VPA + SIL group** and **(G & H) VPA + Vit.C group** showing moderate amount of collagen fibers (↑) around the central vein (CV), in the portal tract area and extending in the perisinusoidal spaces (arrowhead). **(E & F) VPA + SIL + Vit.C group** appears nearly as to the control group.

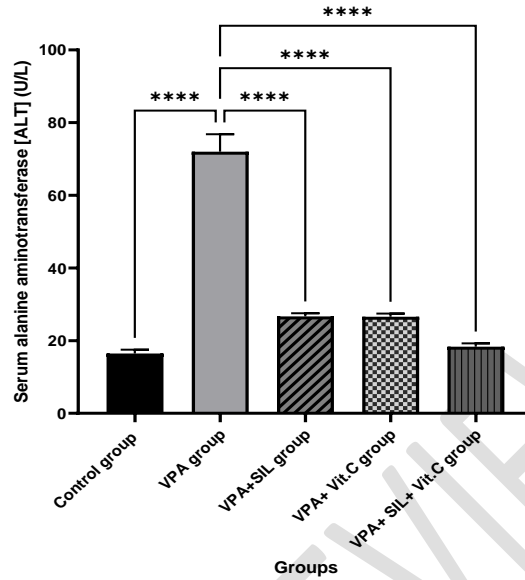
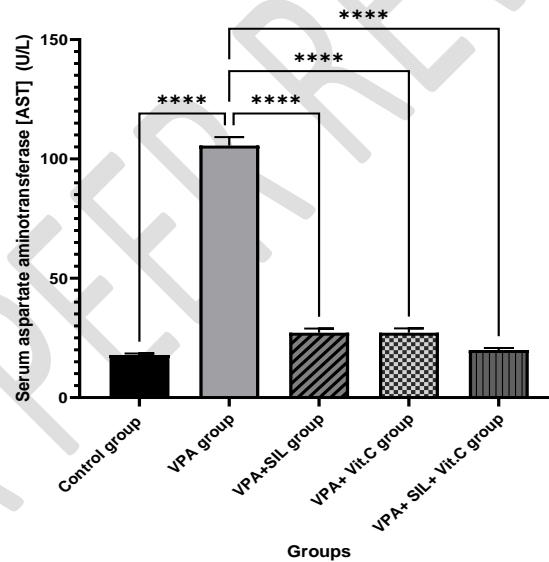
A**B**

Figure 3. Data Values are Mean \pm Std. Error of Mean (SEM) of serum liver function enzymes (serum alanine aminotransferase [ALT] (U/L) (A) and aspartate aminotransferase [AST] (U/L) (B) for control, VPA group, VPA + SIL group, VPA + Vit.C group and VPA + SIL + Vit.C group after 7 days (n=6 rat/group), One-way ANOVA followed by Tukey's multiple comparison test ****P < 0.0001 as compared to control group and VPA group. VPA: Sodium valproate, SIL: Silymarin, Vit.C: Vitamin C.

Table 1: serum liver function enzymes (serum alanine aminotransferase [ALT] (U/L) (A) and aspartate aminotransferase [AST] (U/L) (B) for control, VPA group, VPA + SIL group, VPA + Vit.C group and VPA + SIL + Vit.C group after 7 days (n=6 rat/group):

Report		
Groups (N=6)	Serum alanine aminotransferase [ALT] (U/L) Mean \pm SEM	Serum aspartate aminotransferase [AST] (U/L) Mean \pm SEM
Control group	16.48 \pm 1.010	17.85 \pm .65
VPA group	72.00 \pm 4.79 ●, ■	105.58 \pm 3.60 ●, ■
VPA+ SIL group	26.66 \pm .88 ●, ▲, ■	27.16 \pm 1.75 ●, ▲, ■
VPA+ Vit.C group	26.58 \pm .877 ●, ▲, ■	27.21 \pm 1.78 ●, ▲, ■
VPA+ SIL+ Vit.C group	18.31 \pm .94 ▲	19.96 \pm .82 ▲

Values are mean \pm Std. Error of Mean (SEM); N = number of animals/group. VPA: Sodium valproate, SIL: Silymarin, Vit.C: Vitamin C. One-way ANOVA followed by Tukey's multiple comparison test. ●P <0.05 in comparison to control group. ▲P <0.05 in comparison to VPA group, and ■ P <0.05 in comparison to VPA+ SIL+ Vit.C group.

4. Discussion:

The hepatoprotective effect of silymarin (SIL) and/or vitamin C (Vit.C) against SVP-induced liver damage was established in this investigation. As the therapeutic usage of SVP expanded as a result of its anticonvulsant efficacy, additional reports of hepatotoxicity emerged [22]. As a result, finding medications and hepatic supportive therapies that can help decrease VPA-induced hepatotoxicity and therefore enhance treatment outcomes is important.

VPA is a simple fatty acid that interacts with the cell membrane to produce both beneficial and harmful effects. VPA is predominantly metabolized in the liver via three pathways: cytochrome P450, fatty acid and β -oxidation, and conjugation to produce active and inactive metabolites [23]. Hypoglycin and Pantoic acid are the two primary hepatotoxic components of VPA. Pantoic acid is thought to impede β -oxidation, and β -oxidation inhibition is thought to be closely linked to hepatotoxicity [24].

In the present study, VPA causes degenerative changes in the liver cells with increase in infiltration of mononuclear cells, steatosis, and enlargement of Kupffer cells. Those changes were reported in other studies [25,25,26]. In VPA-treated rats, Nazmy *et al.* found comparable histological results, including a localized necrotic region [5]. They reported reduced hepatotoxicity, portal area infiltration with inflammatory cells, and localized necrosis after administering sulforaphane following VPA toxicity. Except for localized necrosis, our histopathologic findings are comparable to those of Nazmy and his colleagues [5]. The lack of localized necrosis after VPA administration might be related to the length of the VPA treatment and tissue harvesting time; however, in their results, they used short duration of VPA to induce toxicity. Fatty infiltration (micro and macrovesicular steatosis) was identified in liver sections in addition to these alterations, which is consistent with findings from previous research [25,27–29]. Fatty infiltration (steatosis) found in the current study has been proposed to be due to inhibition of some enzymes in β -oxidation cycle by VPA and its metabolites. This leads to interference

with oxidation of fatty acids ending up with accumulation of lipids inside hepatocytes. Additionally, VPA prolonged administration causes mobilization of fatty acids from their stores to the liver [19,30]. Enlarged Kupffer cells observed with VPA administration might be explained by both the accumulation of lipids and glycogen in their cytoplasm[28]. Vascular dilation was suggested to be a response to hypoxia and loss of ATP induced by VPA [25].

The serum aminotransferases ALT and AST are the most widely utilized serum indicators to diagnose liver disease [31]. Increased AST and ALT levels may indicate cellular leakage and a breakdown of the hepatocyte cell membrane's functional integrity. These enzymes leaked out of the liver into the circulation due to hepatocellular leakage. Serum ALT levels are thought to be more specific to the liver and a better indicator of the severity of liver damage [32,33]. Even though these enzymes have been studied as markers of liver injury in several experimental and clinical investigations [34,35], their specificity has been questioned. For example, whether or not there is an increase in the levels of these enzymes, liver necrosis can occur [36–38].

We investigated these enzymes as markers of liver injury in the current study. The present study revealed significant elevation of liver enzymes AST and ALT in the group administered VPA. These results are in parallel with the results from other studies [28,31,39]. In rats treated with only 300 mg/kg of VPA, Shaaban and his colleagues found that there was substantial increases in the levels of all of these enzymes [3]. Similarly, after treating rats with 700 mg/kg of VPA, Nazmy and his colleagues discovered elevated levels of ALT and AST [5]. Lee et al., on the other hand, found no significant changes in the levels of enzymes after giving 100-500 mg/kg of VPA [37]. They hypothesized an underlying explanation for their findings, such as the distribution of ALT and AST over the periportal region and its wide fluctuation.

In the present study, each of SIL and Vit.C alone showed hepatoprotective effects; however they did not improve the condition completely. The AST and ALT levels of the VPA treated with SIL group

were substantially higher in contrast with the control group and significantly lower versus to the VPA group. The group liver has a low degree of degradation and mild inflammation, according to histopathological testing. These findings are consistent with those of previous research [34,40–42]. The preclinical studies using different hepatotoxic substances showed that SIL has multiple actions as a hepatoprotective agent. Silybin; a major constituent of silymarin has been shown to decrease ALT, AST, as well as increase reduced glutathione and superoxide dismutase levels. This was related to its ability to inhibit oxidative stress, to stabilize mitochondrial membrane and to inhibit insulin resistance [43]. Furthermore, the antioxidant property and cell-regenerating activities as a result of enhanced protein synthesis are thought to be the most significant. It adds a crucial layer of defense against oxidative damage. Silymarin contains a number of antioxidants that protect against disease-causing oxidative damage [44].

In compared to the control group, VPA+ Vit.C treated rats had a highly significant rise in AST and ALT, while VPA treated rats had a substantial reduction. Histopathological evaluation of the livers reveals a little improvement. These results are in parallel with the results from other studies [45–47]. It was reported that vitamin C ameliorate the hepatotoxic effect of many chemicals and drugs. It was able to decrease liver enzymes (ALT and AST). It has also been able to improve antioxidant enzymes based on its antioxidant properties[46]. Moreover, Amel et al. reported the protective effect of vitamin C against VPA induced teratogenicity. They found that the group administered VPA and Vit.C showed a significant decrease in lipid peroxidation products [47].

The hepatoprotective effect of both SIL and Vit. C on myoglobinuric liver in rats was assessed in Sabzevarizadeh and Najafzadeh study where Vit. C and the combination of Vit. C and SIL lowered the liver enzymes significantly and improved histopathological findings. However, silymarin alone did not show any hepatoprotective effect; authors related that to the solvent used for silymarin (ethanol)[48]. This combination could also ameliorate the hepatotoxic effect due to acute lead toxicity[49]. Ibrahim et

al. reported the ability of each of Vitamin C and SIL to reduce the levels of liver enzymes (ALT and AST) and bilirubin, and to increase antioxidant enzymes and protein levels in rats administered hepatotoxic doses of acetaminophen. They could also ameliorate the hepatotoxic histological changes in those rats. When combined together, a remarkable improvement in all measured parameters was detected suggesting the power of their synergistic antioxidant effect [19].

5. Conclusion:

This study concluded that hepatotoxicity induced by VPA was associated with increased liver enzymes which indicated liver damage. Also, silymarin (SIL) and / or vitamin C (Vit.C) has hepatoprotective effects against VPA induced toxic effects on liver.

COMPETING INTERESTS DISCLAIMER:

Authors have declared that no competing interests exist. The products used for this research are commonly and predominantly use products in our area of research and country. There is absolutely no conflict of interest between the authors and producers of the products because we do not intend to use these products as an avenue for any litigation but for the advancement of knowledge. Also, the research was not funded by the producing company rather it was funded by personal efforts of the authors.

6. References:

- [1] C.D. Byrne, Targher G, NAFLD A Multisystem Dis. *J Hepatol.* 62 (2015) S47–S64.
- [2] D.P. Bogdanos, B. Gao, M.E. Gershwin, Liver immunology, *Compr. Physiol.* 3 (2013) 567–598.
- [3] A.A. Shaaban, D.S. El-Agamy, Cytoprotective effects of diallyl trisulfide against valproate-induced hepatotoxicity: new anticonvulsant strategy, *Naunyn. Schmiedebergs. Arch. Pharmacol.* 390 (2017) 919–928.
- [4] O. Oztopuz, H. Turkon, B. Buyuk, O. Coskun, M.H. Sehitoglu, M.A. Ovali, M. Uzun, Melatonin ameliorates sodium valproate-induced hepatotoxicity in rats, *Mol. Biol. Rep.* 47 (2020) 317–325.
- [5] E.A. Nazmy, O.A. El-Khouly, H. Atef, E. Said, Sulforaphane protects against sodium valproate-induced acute liver injury, *Can. J. Physiol. Pharmacol.* 95 (2017) 420–426.
- [6] M.F.B. Silva, C.C.P. Aires, P.B.M. Luis, J.P.N. Ruiter, L. IJlst, M. Duran, R.J.A. Wanders, I.T. De Almeida, Valproic acid metabolism and its effects on mitochondrial fatty acid oxidation: a review, *J. Inherit. Metab. Dis.* 31 (2008) 205–216.
- [7] K.H. Schulpis, C. Lazaropoulou, S. Regoutas, G.A. Karikas, A. Margeli, S. Tsakiris, I. Papassotiriou, Valproic acid monotherapy induces DNA oxidative damage, *Toxicology.* 217 (2006) 228–232.
- [8] T.K.L. Kiang, X.W. Teng, S. Karagiozov, J. Surendrass, T.K.H. Chang, F.S. Abbott, Role of oxidative metabolism in the effect of valproic acid on markers of cell viability, necrosis, and oxidative stress in sandwich-cultured rat hepatocytes, *Toxicol. Sci.* 118 (2010) 501–509.
- [9] T. Komulainen, T. Lodge, R. Hinttala, M. Bolszak, M. Pietilä, P. Koivunen, J. Hakkola, J. Poulton, K.J. Morten, J. Uusimaa, Sodium valproate induces mitochondrial respiration dysfunction in HepG2 in vitro cell model, *Toxicology.* 331 (2015) 47–56.
- [10] G. Kaur, M. Athar, M.S. Alam, Dietary supplementation of silymarin protects against chemically induced nephrotoxicity, inflammation and renal tumor promotion response, *Invest. New Drugs.* 28 (2010) 703–713.
- [11] E. Homsy, S.M. de Brito, P. Janino, Silymarin exacerbates p53-mediated tubular apoptosis in glycerol-induced acute kidney injury in rats, *Ren. Fail.* 32 (2010) 623–632.
- [12] S.C. Pradhan, C. Girish, Hepatoprotective herbal drug, silymarin from experimental pharmacology to clinical medicine., *Indian J. Med. Res.* 137 (2013).
- [13] S.F. Abdou, M. Al-Wakeel, M.H. El-Saied, Protective Effect of Silymarin and Vitamine-e in Hepatotoxicity Induced by Valporic Acid in Albino Rats, *J. Med. Sci.* 14 (2014) 290.
- [14] Z. Ghorbani, M. Hajizadeh, A. Hekmatdoost, Dietary supplementation in patients with alcoholic liver disease: a review on current evidence, *Hepatobiliary Pancreat. Dis. Int.* 15 (2016) 348–360.
- [15] A.M. Abdulrazzaq, M. Badr, O. Gammoh, A.A. Abu Khalil, B.Y. Ghanim, T.M. Alhussainy,

- N.A. Qinna, Hepatoprotective actions of ascorbic acid, alpha lipoic acid and silymarin or their combination against acetaminophen-induced hepatotoxicity in rats, *Medicina (B. Aires)*. 55 (2019) 181.
- [16] S.A. Harrison, S. Torgerson, P. Hayashi, J. Ward, S. Schenker, Vitamin E and vitamin C treatment improves fibrosis in patients with nonalcoholic steatohepatitis, *Am. J. Gastroenterol.* 98 (2003) 2485–2490.
- [17] S. Huseyin, O. Guclu, V. Yüksel, G.S.A. Erkul, N. Can, F.N. Turan, S. Canbaz, Avoiding liver injury with papaverine and ascorbic acid due to infrarenal cross-clamping: an experimental study, *Brazilian J. Cardiovasc. Surg.* 32 (2017) 197–201.
- [18] C. Girish, B.C. Koner, S. Jayanthi, K. Ramachandra Rao, B. Rajesh, S.C. Pradhan, Hepatoprotective activity of picroliv, curcumin and ellagic acid compared to silymarin on paracetamol induced liver toxicity in mice, *Fundam. Clin. Pharmacol.* 23 (2009) 735–745.
- [19] M.A. Ibrahim, R.I. Abdel-Karim, H.G. Tamam, A.A. Mohamed, F.A. Wani, Protective effect of silymarin and ascorbic acid in valproic acid-induced hepatic toxicity in male albino Rats, *Mansoura J. Forensic Med. Clin. Toxicol.* 25 (2017) 33–49.
- [20] J.D. Bancroft, M. Gamble, *Theory and practice of histological techniques*, 7th ed, Elsevier health sciences, USA: Churchill Livingstone, 2008.
- [21] S. Reitman, S. Frankel, A colorimetric method for the determination of serum glutamic oxalacetic and glutamic pyruvic transaminases, *Am. J. Clin. Pathol.* 28 (1957) 56–63.
- [22] S. Gopaul, K. Farrell, F. Abbott, Effects of age and polytherapy, risk factors of valproic acid (VPA) hepatotoxicity, on the excretion of thiol conjugates of (E)-2, 4-diene VPA in people with epilepsy taking VPA, *Epilepsia.* 44 (2003) 322–328.
- [23] S.N. Mandana, N. Fatemeh, N. Hossein, M. Azam, A. Saleh, Protective effect of ghrelin on sodium valproate-induced liver injury in rat, *J. Stress Physiol. Biochem.* 9 (2013).
- [24] J. Akhondian, M.A. Kiani, S.A. Jafari, M. Beiraghi Toosi, M. Mirzaei Najm Abad, H. Ahanchian, H. Kianifar, Evaluation of liver enzymes rising in patients treated with sodium valproate (VPA), *Int. J. Pediatr.* 3 (2015) 685–689.
- [25] E.M. Abdella, S.R. Galaly, H.M. Mohammed, S.M. Khadrawy, Protective role of vitamin E against valproic acid-induced cytogenotoxicity and hepatotoxicity in mice, *J. Basic Appl. Zool.* 67 (2014) 127–139.
- [26] A.M. Jassim, Protective Effect of *Petroselinum crispum* (parsley) extract on histopathological changes in liver, kidney and pancreas induced by Sodium Valproate-In male Rats, *Kufa J. Vet. Med. Sci.* 4 (2013).
- [27] V. Tong, X.W. Teng, T.K.H. Chang, F.S. Abbott, Valproic acid I: time course of lipid peroxidation biomarkers, liver toxicity, and valproic acid metabolite levels in rats, *Toxicol. Sci.* 86 (2005) 427–435.
- [28] N.M. Al-Rouby, S.M. Gawish, Histological study on the possible protective effect of nigella

sativa oil on experimentally induced hepatotoxicity in albino rats treated with sodium valproate, *Glob. Adv. Res. J. Med. Med. Sci.* 2 (2013) 90–99.

- [29] A.A. Hamza, F. El Hodairy, A. Badawi, Safranin ameliorates Sodium Valproate-induced liver toxicity in rats by targeting gene expression, oxidative stress and apoptosis, *J. Biomed. Pharm. Res.* 4 (2015) 46–60.
- [30] N.F. Abdelkader, M. Elyamany, A.M. Gad, N. Assaf, H.M. Fawzy, W.H. Elesawy, Ellagic acid attenuates liver toxicity induced by valproic acid in rats, *J. Pharmacol. Sci.* 143 (2020) 23–29.
- [31] B.B. Sokmen, S. Tunali, R. Yanardag, Effects of vitamin U (S-methyl methionine sulphonium chloride) on valproic acid induced liver injury in rats, *Food Chem. Toxicol.* 50 (2012) 3562–3566.
- [32] L. Duan, J.S. Davis, B.L. Woolbright, K. Du, M. Cahkraborty, J. Weemhoff, H. Jaeschke, M. Bourdi, Differential susceptibility to acetaminophen-induced liver injury in sub-strains of C57BL/6 mice: 6N versus 6J, *Food Chem. Toxicol.* 98 (2016) 107–118.
- [33] A.C. Knapp, L. Todesco, K. Beier, L. Terracciano, H. Sägesser, J. Reichen, S. Krähenbühl, Toxicity of valproic acid in mice with decreased plasma and tissue carnitine stores, *J. Pharmacol. Exp. Ther.* 324 (2008) 568–575.
- [34] S.M. Elshazly, M.A. El-Moselhy, W. Barakat, Insights in the mechanism underlying the protective effect of α -lipoic acid against acetaminophen-hepatotoxicity, *Eur. J. Pharmacol.* 726 (2014) 116–123.
- [35] S. Sabiu, T.O. Sunmonu, E.O. Ajani, T.O. Ajiboye, Combined administration of silymarin and vitamin C stalls acetaminophen-mediated hepatic oxidative insults in Wistar rats, *Rev. Bras. Farmacogn.* 25 (2015) 29–34.
- [36] S. Dalaklioglu, G.E. Genc, N.H. Aksoy, F. Akcıt, S. Gumuslu, Resveratrol ameliorates methotrexate-induced hepatotoxicity in rats via inhibition of lipid peroxidation, *Hum. Exp. Toxicol.* 32 (2013) 662–671.
- [37] M.S. Lee, Y.-J. Lee, B.J. Kim, K.J. Shin, B.C. Chung, D.-J. Baek, B.H. Jung, The relationship between glucuronide conjugate levels and hepatotoxicity after oral administration of valproic acid, *Arch. Pharm. Res.* 32 (2009) 1029–1035.
- [38] C. Loguercio, V. De Girolamo, A. Cuomo, F. Argenzio, C. Iannotta, D. Disalvo, A. Grella, C.D.V. Blanco, Determination of plasma α -Glutathione-S-transferases in chronic alcohol abusers: relationship with alcohol intake and liver involvement, *Alcohol Alcohol.* 33 (1998) 366–372.
- [39] M.A. Abdel-Dayem, A.A. Elmarakby, A.A. Abdel-Aziz, C. Pye, S.A. Said, A.M. El-Mowafy, Valproate-induced liver injury: modulation by the omega-3 fatty acid DHA proposes a novel anticonvulsant regimen, *Drugs R. D.* 14 (2014) 85–94.
- [40] İ. Aktaş, İ. Armağan, Investigation of the positive effects of silymarin on valproic acid-induced liver damage in rats, *Adıyaman Üniversitesi Sağlık Bilim. Derg.* 5 (2019) 1445–1458.

- [41] S. El-Khateeb, M. Arafa, T. Ibraheem, Influence of silymarin on valproic acid induced hepatotoxicity in adult male albino rats, *Ain Shams J. Forensic Med. Clin. Toxicol.* 20 (2013) 221–232.
- [42] M. Meganathan, K.M. Gopal, P. Sasikala, J. Mohan, N. Gowdhaman, K. Balamurugan, P. Nirmala, S. Santhakumari, V. Samuel, Evaluation of hepatoprotective effect of omega 3-fatty acid against paracetamol induced liver injury in albino rats, *Glob. J Pharmacol.* 5 (2011) 50–53.
- [43] J. Yao, M. Zhi, C. Minhu, Effect of silybin on high-fat-induced fatty liver in rats, *Brazilian J. Med. Biol. Res.* 44 (2011) 652–659.
- [44] P. Kosina, V. Křen, R. Gebhardt, F. Grambal, J. Ulrichová, D. Walterová, Antioxidant properties of silybin glycosides, *Phyther. Res.* 16 (2002) 33–39.
- [45] V. Murugesan, P. Subramanian, Enhancement of circulatory antioxidants by alpha-ketoglutarate during sodium valproate treatment in Wistar rats, *Pol. J. Pharmacol.* 55 (2003) 31–36.
- [46] E. Adikwu, O. Deo, Hepatoprotective effect of vitamin C (ascorbic acid), (2013).
- [47] A. Amel, Z. Djamila, B. Nassima, B. Ouahiba, M.Z.B. Fadila, B. Samir, B. Saverio, The protective effect of *Chrysanthemum fantanesii* extract, vitamin E and C on sodium valproate-induced embryotoxicity in pregnant mice, *J. Med. Plants Res.* 6 (2012) 3535–3544.
- [48] M. Sabzevarizadeh, H. Najafzadeh, Comparison effect of silymarin and vitamin C on liver function in myoglobinuric status in rats, *World Appl. Sci.* 17 (2012) 228–232.
- [49] M.G. Shalan, M.S. Mostafa, M.M. Hassouna, S.E.H. El-Nabi, A. El-Refaie, Amelioration of lead toxicity on rat liver with vitamin C and silymarin supplements, *Toxicology.* 206 (2005) 1–15.