

Psoriasiform mycosis fungoides involving the face- a rare case report

Abstract :

Mycosis fungoides is an epidermotropic cutaneous T-cell lymphoma caused by proliferation of atypical lymphocytes with cerebriform nuclei or Sezary cells. We report a rare presentation of mycosis fungoides in a 60-year-old male presenting with chronic psoriasiform plaque involving the face. Punch biopsy of the lesion from the forehead was obtained for routine histology and immuno-histochemical stains. Results of biopsy and immunohistochemical findings were consistent with mycosis fungoides and diagnosed as psoriasiform presentation of mycosis fungoides involving the face.

Keywords : Mycosis fungoides , persistent facial plaque , epidermotropism , atypical lymphocytes.

Introduction:

Mycosis fungoides is the most common form of cutaneous T-cell lymphoma. It is also defined as uncommon, indolent non-Hodgkin's lymphoma of T-cell origin with primarily involving the skin and present as patches, plaques, tumors or erythroderma. It is also called as Alibert-Bazin syndrome or granuloma fungoides.

It mainly affecting the male population with onset between 45 to 60 years of age-group. It usually manifests with erythematous scaly patches or plaques and may progress to generalized erythroderma, cutaneous tumors or extracutaneous involvement.

The skin lesions are usually confined to sun-protected areas mainly over the trunk and body folds. Patch or plaque stage of lesions involving the sun-exposed parts like face and scalp is very rare presentation. Tumor stage of MF are presenting sign in only 10% of cases mainly involving the face may lead to leonine facies.

Case report :

A 60-year-old male patient came to dermatology OPD with chief complaints of persistent raised thickened pigmented lesion over the face for past 4 years. Patient was apparently normal before 4 years followed by which he developed pruritic flat pigmented lesions initially over the forehead and then the lesions were gradually progressed to elevated lesions involving other sites of face with increased itching.

Patient had history of recurrent episodes of severe itching for past 4 years which were not relieved by oral anti-histamines. No history of similar lesions in the family members and no history of any drug intake . No history of any mucosal involvement.

On cutaneous examination , single ,non-tender, ill-defined , mild scaly , diffuse infiltrated hyperpigmented plaque were seen over the forehead and multiple infiltrated hyperpigmented patches involving the nose and sides of face. No scalp and oral involvement. No nail changes on examination. Lymph-nodes are not palpable and systemic examination was normal.

Provisional diagnosis of psoriasis vulgaris were made and started on topical tacrolimus 0.1% and topical corticosteroids on alternate days. But the lesions were persistent and not responding to any topical treatments.

Dermoscopy of facial plaque showed multiple white rosettes , which is mainly suggestive of mycosis fungoides.

Hence , 3.5mm punch biopsy was done from the plaque over the forehead. On histopathological examination , it showed epidermotropism of atypical lymphocytes with pautrier's microabscess and some cells showed cerebriform nuclei and clear cytoplasm.

Immunohistochemistry showed CD3 , CD4 , CD7 and CD8 positive and the findings of biopsy and immunohistochemistry were consistent with mycosis fungoides.

Hence , Final diagnosis of psoriasiform mycosis fungoides were made. We started the patient on systemic methotrexate 7.5mg / week and PUVA therapy twice weekly with topical corticosteroids and topical tacrolimus 0.1 % . Now, patient has been showing improvement and is on observation.

FIGURE 1 : Hyperpigmented diffuse plaque over forehead

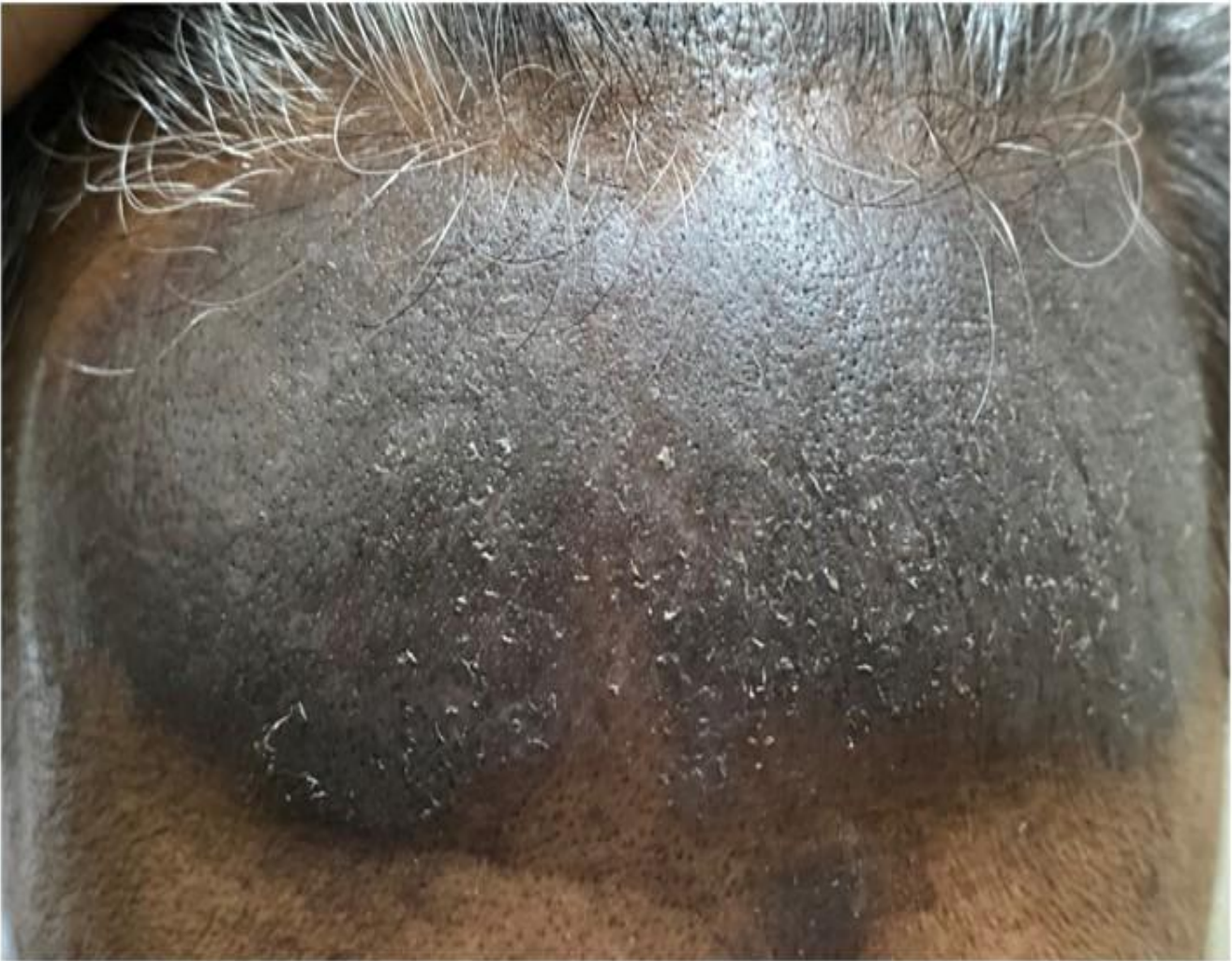

FIGURE 2 : multiple hyperpigmented plaque and patch over nose and sides of face :

UNDER PEER REVIEW

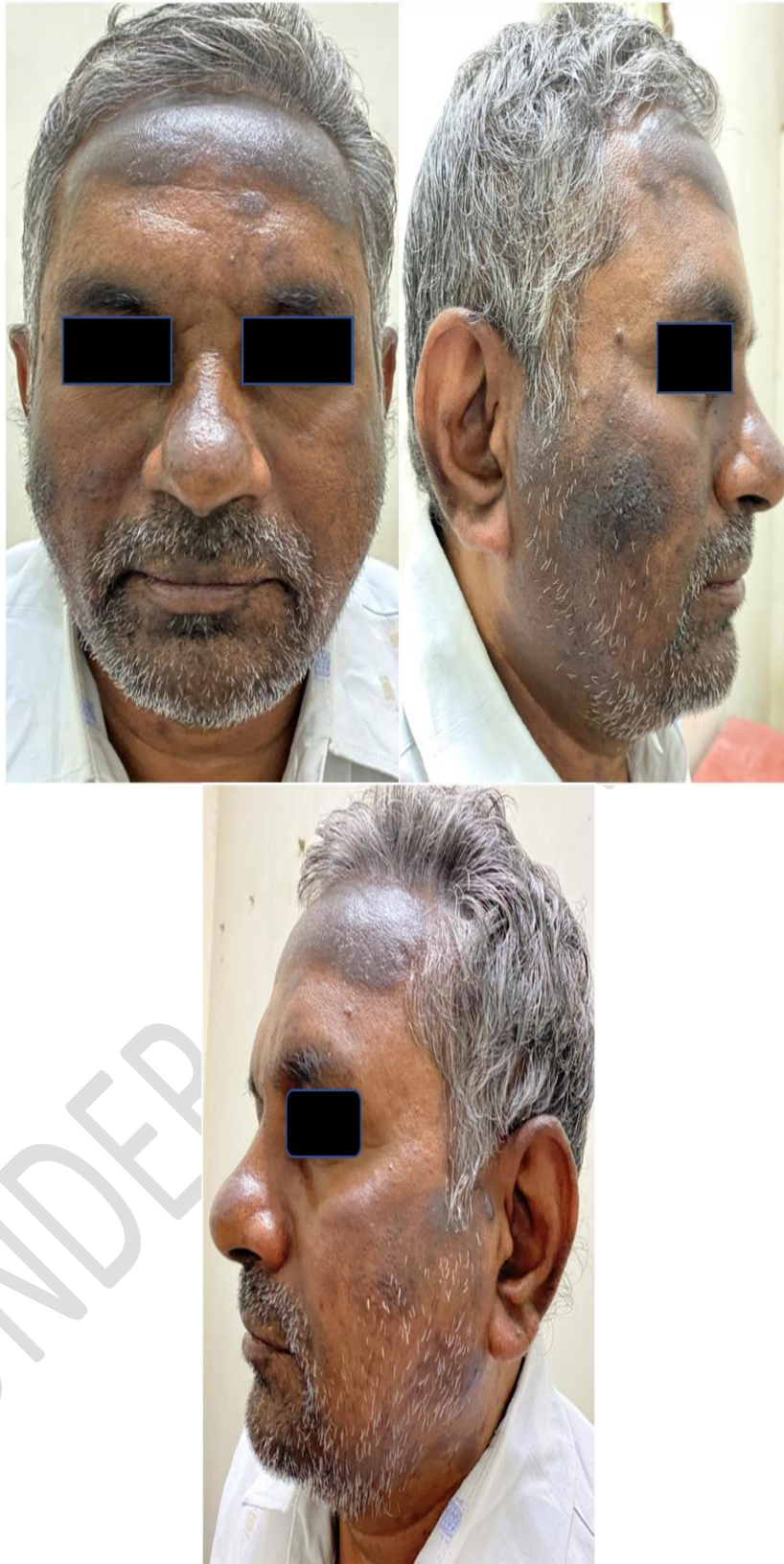

FIGURE 3 : HPE : epidermotropism & pautrier's microabscesses with atypical lymphocytes

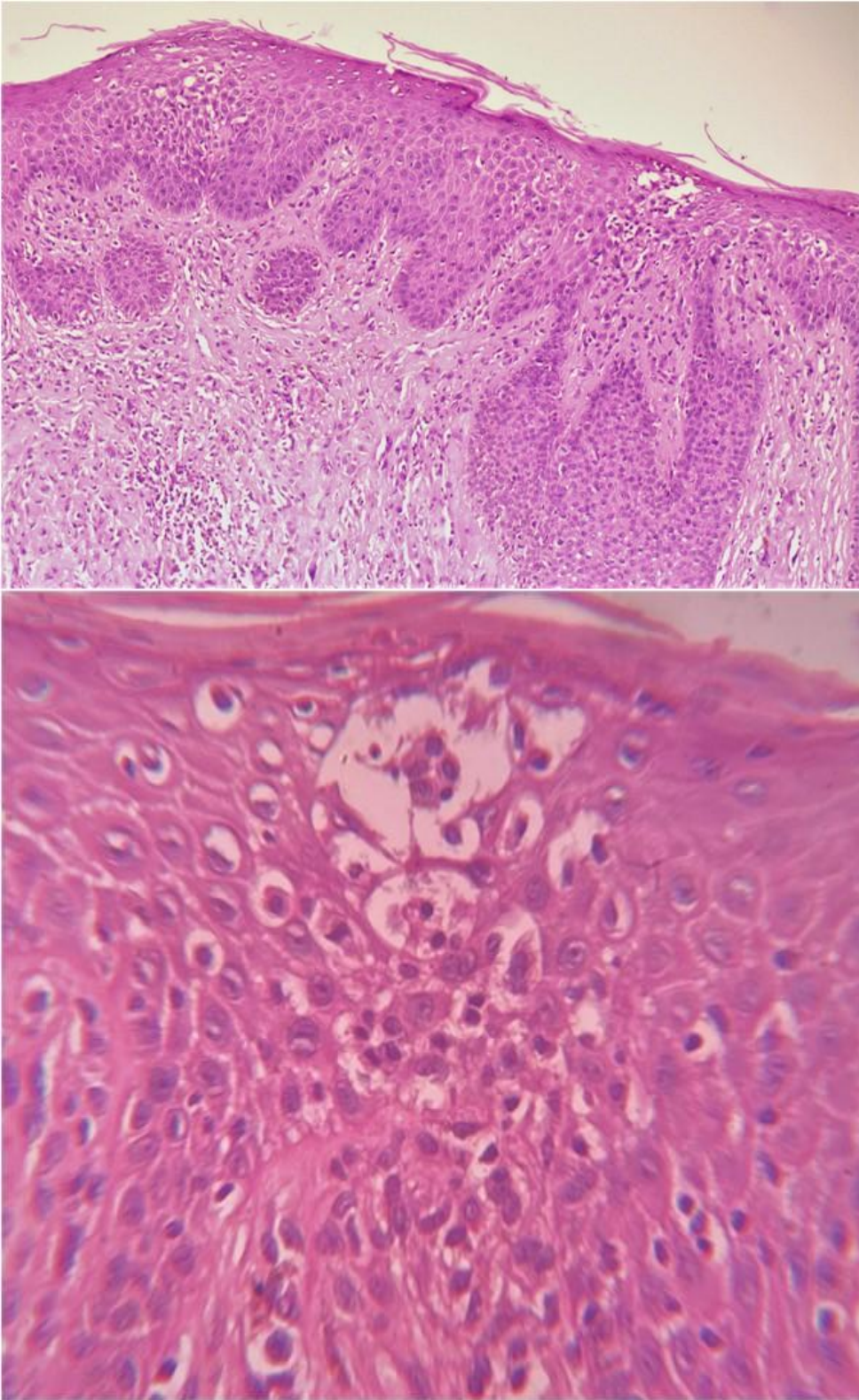
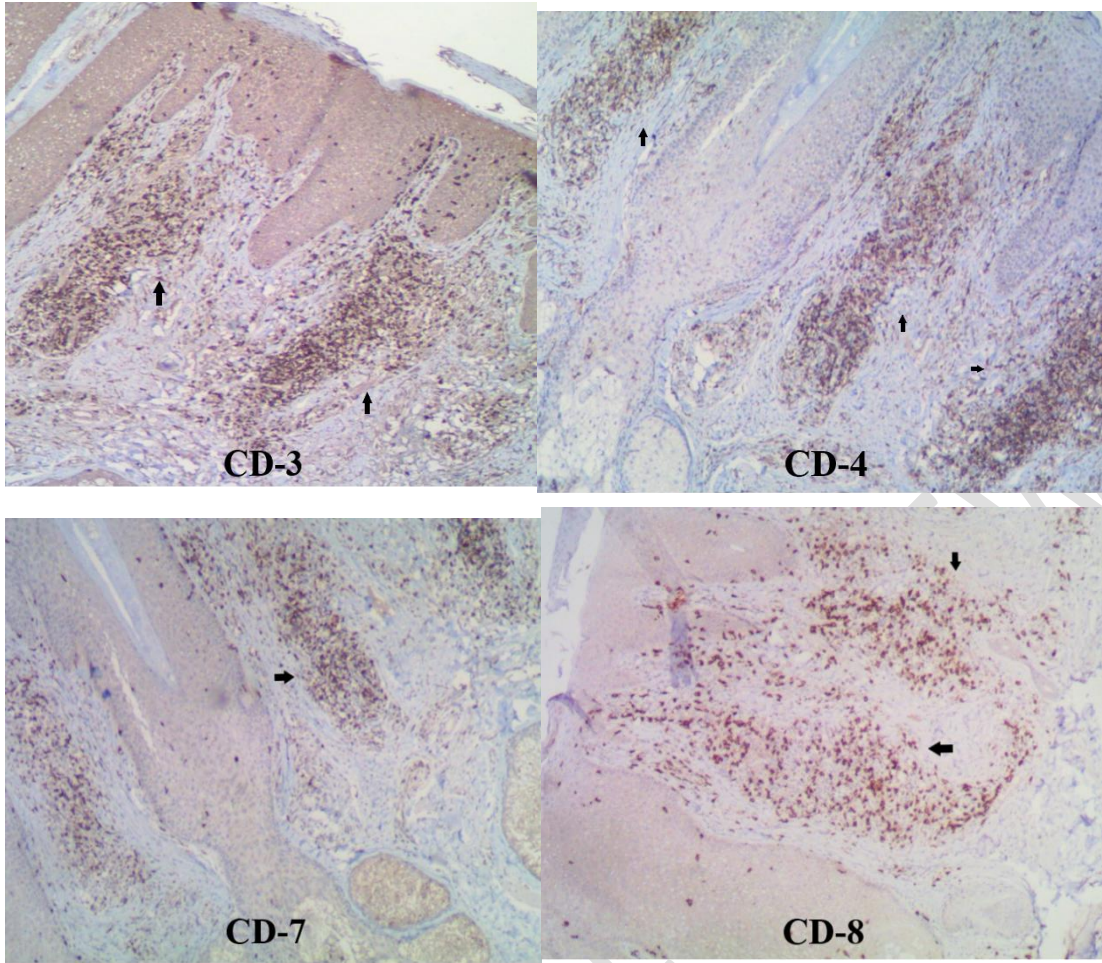


FIGURE 4 : IHC CD3 , CD4 , CD7 ,CD8 Positivity



Discussion :

Mycosis fungoides (MF) is a rare , extra nodal , non-Hodgkin's lymphoma with clonal , malignant T-lymphocytes with incidence of 0.36 / 1,00,000 persons per year. MF is mainly classified according to its clinical presentation as patch , plaque , tumor and erythrodermic stage. Patch or plaque stage lesions of MF usually present over the covered parts of body (trunk , breast , buttocks , medial thighs) and occurrence of plaque or patch stage of lesions over the face is very rare presentation. Patch and plaque stage lesions may be presented as hypopigmentation , hyperpigmentation , atrophy or petechiae . In addition to various clinical presentation , lesion can be associated with severe pruritus or it could be asymptomatic. Patch stage of mycosis fungoides may progress to infiltrated plaque with generalized distribution and minority of cases may progress to exophytic tumor. Lymphadenopathy and visceral dissemination are usually a late occurrence.

The diagnosis of MF is difficult in early stages, because it is mainly misdiagnosed as chronic contact dermatitis and chronic plaque type psoriasis. Diagnosis is made through a combination of clinical pictures and examination and it is confirmed by skin biopsy and immune-histochemistry.

The histologic features include epidermotropism (migration of atypical lymphocytes from dermis into

epidermis with in the basal cell layer), atypical dermal lymphocytes with cerebriform nuclei, pauquier's microabscesses and grandiosity sign. Classically, MF shows a CD2+, CD3+, CD4+, CD8-, CD30-, CD45RO+ immunophenotype.

Management of MF with skin directed therapies like topical corticosteroids, topical nitrogen mustard, topical bexarotene and PUVA therapy have been shown to give good response in early stage of MF. systemic methotrexate or targeted therapy with monoclonal antibodies, oral bexarotene, recombinant IFN alpha and fusion proteins are used in more advanced stages of MF.

Systemic methotrexate used in advanced stages of MF were instituted in our patient because of poor response with topical glucocorticoids alone.

Conclusion:

Mycosis fungoides is the commonest variant of primary cutaneous T-cell lymphoma with wide spectrum of clinical manifestations mainly involving the covered parts of body and involvement of face is very rare presentation mainly during early stages of patch or plaque lesions. Hence, we hereby report a rare psoriasiform presentation of mycosis fungoides involving face disguised as chronic dermatitis and the importance of skin biopsy and immune-histochemistry in such cases.

References:

1. Pope E, Weitzman S, Ngan B, et al. Mycosis fungoides in the pediatric population: report from an international childhood registry of cutaneous lymphoma. *J Cutan Med Surg*. 2010;14(1):1–6.
2. Mycosis Fungoides: Case Report and Literature Review: Akinbami et al. Mycosis Fungoides: Case Report and Literature Review. *Clinical Medicine Insights: Case Reports* 2014;7 95–98 doi: 10.4137/CCRep.S15724.

3. A Rare Presentation of Mycosis Fungoides Mimicking Psoriasis Vulgaris S. Doukaki M. Aricò M.R. Bongiorno Department of Dermatology, University of Palermo, Palermo, Italy. Case Rep Dermatol 2009;1:60–65 DOI: 10.1159/000249148.

4. The different faces of mycosis fungoides: results of a single-center study Polytimi Sidiropoulou¹ , MD, Vasiliki Nikolaou¹ , MD, MSc, PhD Leonidas Marinos² , MD, Dimitra Voudouri¹ , MD, Elena Komini¹ , MD, Afroditi Economidi¹ , MD, Dimitris Rigopoulos¹ , MD, PhD and Alexander Stratigos¹ , MD, PhD. 2019 The International Society of Dermatology ; doi: 10.1111/ijd.14735

5. Marschalko M, Eros N, Kontar O, et al. Folliculotropic mycosis fungoides: clinicopathological analysis of 17 patients. J Eur Acad Dermatol Venereol. 2015;29(5):964-972.

6. Alberti-Violetti S, Talpur R, Schlichte M, et al. Advanced-stage mycosis fungoides and Sézary syndrome: survival and response to treatment. Clin Lymphoma Myeloma Leuk. 2015; 15(6):e105-e112

7. Leonine facies (LF) and mycosis fungoides (MF):
A single-center study and systematic review
of the literature. Danielle Nicole Brown, BA, Iris
Wieser, MD, Casey Wang, MD, Boutnaina S. Dabaja,
MD, and Madeleine Duvic, MD. Houston, Texas, and
Salzburg, Austria. (J Am Acad Dermatol 2015;73:976-
86.)

UNDER PEER REVIEW