

Clinical and radio graphical evaluation of implants placed in ridge preserved sites versus naturally healed sites

Abstract

Introduction: Dental implant has proved to be a pioneer in prosthetic rehabilitation overcoming the disadvantage of a removable or a fixed partial denture. The aim of the study was to clinically and radiographically evaluate and compare changes of hard and soft tissues around the implants which will be placed in ridge preserved sites with implant placed in naturally healed extraction sites.

Materials & Methods: In this study 10 Patients having tooth with hopeless prognosis requiring tooth extraction followed by implant placement were enrolled. These patients were randomly divided in to two groups. Group I: Socket preservation with demineralized bone matrix putty group. Group II: Naturally healed socket after extraction, followed by implant placement in both groups.

Results: The results of the current study indicated that demineralisedbone matrix putty, when used in patients for dental augmentation in either mandibular or maxillary sites, resulted in replacement of the graft material with bone by as early as 4-6 months, there upon enabling implant placement and subsequent prosthetic reconstruction.

Conclusion: Bucco lingual ridge width and width of keratinized gingiva can be preserved by ridge preservation after extraction. Short-term survival rates and clinical outcomes of both groups were similar and were comparable. Further clinical trials with longer duration follow up with larger sample size should be done to get more affirmative and conclusive results.

Keywords: Demineralized, Implant, Bone Graft, Socket Preservation, Soft Tissue

Introduction

Dental implant has proved to be a pioneer in prosthetic rehabilitation overcoming the disadvantage of a removable or a fixed partial denture. It has brought a paradigm shift in periodontics from the philosophy of saving teeth at all costs to extracting compromised teeth and replacing them with a better and more predictable long term outcome.¹

Implant placement after extraction is usually two stage procedure where in bone is allowed to form before the implant is placed at the site. The first includes the placement of implants followed by a second stage surgery which consist of loading of implant with abutment. Infection in tooth extraction site has traditionally been considered as indication to postpone implant placement until the infection resolves.² In situation where teeth required extraction, **Adell and Lekholm**³ in their original protocol suggested a 6-12 month wait for healing of the site before implant placement to allow complete ossification of the extraction socket.

The morphology of the alveolus is very much tooth dependent in that the development of alveolar bone is determined by the form of the teeth and the axis of tooth eruption.⁴ The pattern and degree of dimensional changes that occur in the alveolar ridge after tooth extraction has been documented in the literature for more than 50 years. there is disproportionate resorption of the buccal plate compared to the palatal/lingual plate of the ridge with the buccal plate undergoing significantly more resorption.⁷ the final outcome of this is not only narrowing of the ridge but a palatal/lingual shift of the mid-line of the ridge. **Lekovic et al.**⁵ reported that loss of width was three times greater than loss of height. At a recent consensus meeting where four systemic reviews were analysed, it was reported that the alveolar ridge undergoes a mean horizontal reduction in width 3.8 mm and a mean vertical reduction in height of 1.24 mm within six months after extraction.⁶

As the periodontium undergoes atrophy after tooth extraction, it is therefore important to maintain the natural contours of the residual ridge and minimize the bone resorption, especially in the esthetic zone, where implant supported prosthesis have been planned. Taking into consideration the amount of resorption taking place after extraction a variety of therapeutic strategies aimed at preventing or minimizing alveolar ridge collapse have been proposed over the past three decades. Ridge preservation is a clinical procedure that is performed at the time of tooth extraction to minimize bone resorption of the socket walls.⁶

. Ridge preservation or 'socket preservation involves placement of graft material within the socket; this can be combined with either a membrane and/or an advanced or rotated flap. It is an implication that we are preserving or maintaining something in its original or existing state. The resorption of bundle bone is a physiologic certainly and no techniques currently available are able to prevent it. A plethora of ridge preservation materials and technique have been advocated recently with minimal evaluation in a strict scientific context.⁷

Delayed implant placement after healing of the socket is preferred, in an attempt to minimize the risk of implant failures and complications. Just after extraction, sockets can be subjected to a ridge preservation procedure to decrease the naturally occurring bone resorption. Various ridge preservation techniques are currently used, ranging from soft tissue grafts to autogenous or bone substitute grafts.⁸ The number of reliable RCTs is limited, however they showed that various ridge preservation procedures are effective in decreasing the physiological bone resorption¹³, even though some preservation techniques were associated with a substantial number of failures and complications or appear to be ineffective.⁹

Present study was drawn up with the following consideration in mind: to evaluate and compare changes of hard and soft tissues in post-extraction socket which received ridge

preservation procedure where a secondary soft tissue healing was left with post-extraction sockets which had healed naturally. Hence the aim of the study was to clinically and radiographically evaluate and compare changes of hard and soft tissues around the implants which will be placed in ridge preserved sites with implant placed in naturally healed extraction sites.

Materials & Methods

SOURCE OF DATA:

In this study 10 Patients having tooth with hopeless prognosis requiring tooth extraction followed by implant placement were enrolled from outpatient department of Periodontology and Implantology, Karnavati School of Dentistry, Uvarsad, Gandinagar. Informed consent was taken from patient before the procedure. These patients were randomly divided in to two groups.

Group I: Socket preservation with demineralized bone matrix putty group

Group II: Naturally healed socket after extraction

Followed by implant placement in both groups. This study was approved by scientific and ethics committee of Karnavati School of Dentistry.

METHOD OF COLLECTION OF DATA

Ten patients with tooth having hopeless prognosis indicated for extraction and they are planned for socket preservation and future implant placement.

Inclusion criteria:

1. Patients in age group of 18-60 years of either sex
2. Systemically healthy patients
3. Tooth with hopeless prognosis which require extraction
4. Patients who desire to participate in the study

5. Patients planning for the delayed implant placement

Exclusion criteria:

1. Tooth having acute infection at time of extraction
2. Subjects with any major systemic illness
3. Cigarette smokers, tobacco abuser and uncontrolled periodontal diseases
4. Patient who is pregnant or planning to become pregnant in study period

Preparation of patient:

All selected patients were explained about the surgical procedures, frequency of visits, importance of oral hygiene maintenance and follow up visits. A detail case history of patient was obtained. A preparatory phase consisting of implementation of specific oral hygiene regime to eliminate the incorrect practice along with scaling and root planing was carried out.

METHOD:

- Surgical procedure is carried out under strict aseptic condition. This included preoperative mouth rinses of patient's oral cavity with chlorhexidine (0.2%) for 1min and an extraoral skin scrub with povidone iodine. Surgeries were performed under local anaesthesia.
- Distance from the implant shoulder to first implant bone contact

TURESKY- GILMORE- GLICKMAN MODIFICATION OF QUIGLEY HEIN PLAQUE

INDEX:

The Quigley-Hein plaque index was modified by **Turesky S., Gilmore N.D. and Glickman in 1970.**¹⁰ This modification of the Quigley-Hein Plaque Index was done by strengthening the objectivity of Quigley-Hein Plaque Index criteria by redefining the scores of the gingival third area. This modification is recognized as a reliable index for measuring plaque, using an estimate

of the area of the tooth covered by plaque. Plaque was assessed on the labial, buccal and lingual surfaces of all the teeth after using a disclosing agent. This index will be recorded at the time of extraction, at the time of implant placement and at the time of abutment placement.

List 1: Scoring criteria:

| Score | Criteria |
|-------|---|
| 1 | No plaque |
| 2 | Separate flecks of plaque at the cervical margin of the tooth |
| 3 | A thin continuous band of plaque (up to one mm) at the cervical margin of the tooth. |
| 4 | A band of plaque wider than one mm but covering less than one-third of the crown of the tooth |
| 5 | Plaque covering at least one-third but less than two-thirds of the crown of the tooth |
| 6 | Plaque covering two-thirds or more of the crown of the tooth |

Interpretation:

The plaque score per person is obtained by adding the scores divided by the number of the surfaces examined.

MODIFIED GINGIVAL INDEX (MGI)

The Modified Gingival Index (MGI), devised by **Lobene et al. (1986)**¹¹ introduced changes in the criteria of the Gingival Index through a non-invasive (no probing) method for assessing the mild and moderate inflammation. Scores of the four areas of the tooth can be summed and divided by four to give the MGI for the tooth. This way, the following criteria are

adopted: This index will be recorded at the time of extraction, at the time of implant placement and at the time of abutment placement.

List 2 Scoring system:

| Score | Criteria |
|-------|---|
| 0 | Absence of inflammation |
| 1 | Mild inflammation or with slight changes in color and texture but not in all portions of gingival marginal or papillary |
| 2 | Mild inflammation: such as the preceding criteria, in all portions of gingival marginal or papillary |
| 3 | Moderate: bright surface inflammation, erythema, edema and/or hypertrophy of gingival marginal or papillary |
| 4 | Severe inflammation: erythema, edema and/or marginal gingival hypertrophy of the unit or spontaneous bleeding, papillary, congestion or ulceration. |

The MGI of the individual can be obtained by adding the values of each tooth and dividing by the number of teeth examined. The Modified Gingival Index may be scored for all surfaces of all or selected teeth or for selected areas of all or selected teeth. The MGI may be used for the assessment of prevalence and severity of gingivitis in populations, groups and individuals.

List 3 Interpretations:

| GINGIVAL SCORES | CONDITION |
|-----------------|-----------------|
| 0.1-1.0 | Mild gingivitis |

| | |
|---------|---------------------|
| 1.1-2.0 | Moderate gingivitis |
| 2.1-3.0 | Severe gingivitis |

The MGI has been used frequently in clinical trials of therapeutic agents. The sensitivity and reproducibility is good provided the examiner's knowledge of periodontal biology and pathology is optimal.

EARLY WOUND HEALING INDEX:

This parameter was taken after 1, 2, 4 weeks post surgically. Early Wound Healing Index was given by **Watchel et al** in 2003 to clinically evaluate the healing at the surgical site. It scores from 1 to 5.

List 4 SCORING CRITERIA:

| Score | Criteria |
|-------|--|
| 1 | Complete flap closure, no fibrin in the interproximal area |
| 2 | Complete flap closure, fine fibrin line in the interproximal area |
| 3 | Complete flap closure, fibrin clot in the interproximal area |
| 4 | Incomplete flap closure, partial necrosis of the interproximal tissue |
| 5 | Incomplete flap closure, complete necrosis of the interproximal tissue |

Ridge caliper was used to measure the thickness of bucco-lingual ridge width to the nearest 0.5mm at a distance 2mm apical to the crest of the bone at the mesio-distal midpoint of the

extraction socket at the time of extraction, implant and abutment placement. Width of the keratinized gingiva will be measured with the help of UNC-15 probe by measuring the distance between marginal gingiva and mucogingival junction at the time of extraction, implant and abutment placement. Buser's criteria were taken to know about the clinical success of the implants. The readings are dichotomous and subjective. The readings are taken as presence/absence.

The criteria's:

- Clinical mobility
- Pain/ subjective sensation
- Recurrent peri-implant infection
- Continuous radiolucencies around loading

DISTANCE FROM THE IMPLANT SHOULDER TO FIRST IMPLANT BONE CONTACT (DIB):

This parameter is recorded by taking radiograph accompanied with a standardized grid to measure the crestal bone loss around the implants. Crestal bone loss and horizontal defect dimensions were measured by counting the millimeter squares on the X-ray, thus eliminating errors arising from image elongation or shortening.

X1= length from crest of the bone to apical end of implant on mesial aspect at the time of implant placement

X2= length from crest of the bone to apical end of implant on distal aspect at the implant of implant placement

Y1=length from crest of the bone to apical end of implant on mesial aspect at various follow-up visits

Y2= length from crest of the bone to apical end of implant on distal aspect at various follow-up visits.

It is measured at the time of implant placement and at the time of abutment placement.

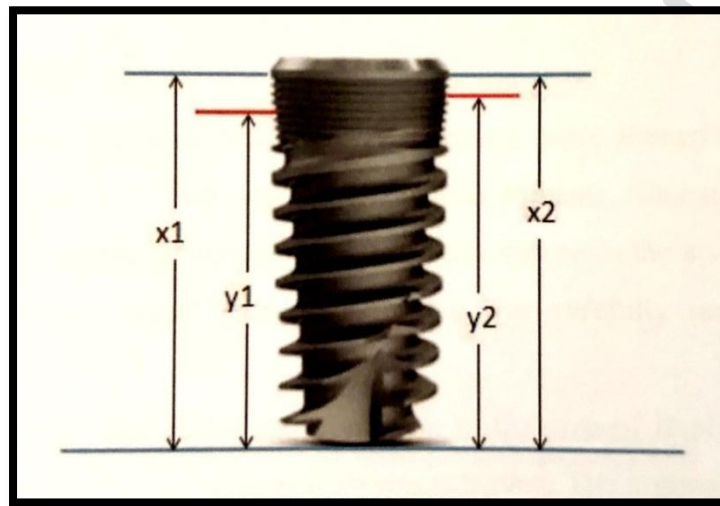


Figure 1: Landmarks for radiographic calculation

Average bone height immediately after implant placement is:

$$X = \frac{X1 + X2}{2}$$

Average bone height immediately at various follow up visits:

$$Y = \frac{Y1 + Y2}{2}$$

Distance from implant shoulder to first implant bone contact:

$$DIB = X - Y$$

PROCEDURE FOR SOCKET PRESERVATION:

After extraction, Socket was thoroughly debrided. All clinical analysis were measured.

Group I: DBM putty is placed in socket

Group II: natural healing of extraction socket

After extraction socket debridement was done. Following debridement, the graft material was tightly packed into the extraction socket in an incremental fashion. Socket with intact bone walls was grafted with DBM putty in group 1 patients. And cross mattress sutures 3-0 non resorbable silk was placed on top of the collagen plug to close the margins and aid in retention of graft material placed in socket. And group 2 patients received 3-0 non resorbable silk sutures to stabilize the clot without any grafting material.

POST OPERATIVE CARE

Post operatively patients were prescribed systemic antibiotics (Cap Amoxicillin 500 mg for 5 days) and anti-inflammatory drug (Tab Ibuprofen 400mg + tab paracetamol 325 mg TDS for 5 days). A protocol for the control of bacterial contamination consisting of 0.2% chlorhexidine mouth rinsing 3 times daily per 2 weeks was prescribed. Patients will be requested to avoid brushing and chewing in the treated area for a period of 2 weeks. The healing process was monitored weekly for the 1st month and then after each month until 6 months.

After 3 months second surgery was planned. Intraoral periapical radiograph was taken using paralleling technique with grid. Local anaesthesia was given with lignocaine 1:80000. Crestal incision was given and flap was reflected. Ridge width was measured with ridge caliper. Osteotomy site was prepared followed by implant placement in both groups. After 3 months abutment placement was done and all the clinical and radiographic evaluation was done.

Results

Table 1: Intergroup comparison of Plaque index

| | GROUP | N | Mean | Std. Deviation | t | df | P VALUE |
|------------------------------|--------------|----------|-------------|-----------------------|----------|-----------|----------------|
| Plaque index baseline | Group 1 | 5 | 0.44 | 0.045826 | - | 8 | 0.319 |
| | Group 2 | 5 | 0.516 | 0.153069 | 1.064 | | |
| Plaque index 3 months | Group 1 | 5 | 0.472 | 0.094181 | - | 8 | 0.22 |
| | Group 2 | 5 | 0.548 | 0.086429 | 1.329 | | |
| Plaque index 6 months | Group 1 | 5 | 0.538 | 0.093648 | - | 8 | 0.34 |
| | Group 2 | 5 | 0.616 | 0.143979 | 1.015 | | |

Comparison of the plaque index baseline between the two groups shows that plaque index baseline is higher in Group 2 group with a t value of -1.064 and is statistically non-significant with a p value of 0.319. Comparison of the plaque index 3 months between the two groups shows that plaque index 3 months is higher in Group 2 group with a t value of -1.329 and is statistically non-significant with a p value of 0.22. Comparison of the plaque index 6 months between the two groups shows that plaque index 6 months is higher in Group 2 group with a t value of -1.015 and is statistically non-significant with a p value of 0.34

Table 2: Intergroup comparison of Gingival index

| | GROUP | N | Mean | Std. Deviation | t | df | P VALUE |
|--------------------------------|--------------|----------|-------------|-----------------------|----------|-----------|----------------|
| gingival index baseline | Group 1 | 5 | 0.542 | 0.259846 | - | 8 | 0.568 |
| | Group 2 | 5 | 0.624 | 0.165318 | 0.595 | | |
| gingival index 3 months | Group 1 | 5 | 0.766 | 0.30262 | 0.344 | 8 | 0.739 |
| | Group 2 | 5 | 0.716 | 0.1176 | | | |
| gingival index 6 months | Group 1 | 5 | 0.796 | 0.30113 | 0.823 | 8 | 0.434 |
| | Group 2 | 5 | 0.656 | 0.23244 | | | |

Comparison of the gingival index baseline between the two groups shows that gingival index baseline is higher in Group 2 group with a t value of -0.595 and is statistically non-significant with a p value of 0.568. Comparison of the gingival index 3 months between the two groups shows that gingival index 3 months is higher in Group 1 group with a t value of 0.344 and is statistically non-significant with a p value of 0.739. Comparison of the gingival index 6 months between the two groups shows that gingival index 6 months is higher in Group 1 group with a t value of 0.823 and is statistically non-significant with a p value of 0.434

Table 3: Intergroup comparison of Early wound healing index

| | GROUP | N | Mean | Std. Deviation | t | df | P VALUE |
|-----------------------------------|--------------|----------|-------------|-----------------------|----------|-----------|----------------|
| early wound healing 1 week | Group 1 | 5 | 2.2 | 0.837 | - | 8 | 0.76 |
| | Group 2 | 5 | 2.4 | 1.14 | 0.316 | | |
| early wound healing 2 week | Group 1 | 5 | 1.6 | 0.548 | 0 | 8 | 1 |
| | Group 2 | 5 | 1.6 | 0.548 | | | |
| early wound healing 3 week | Group 1 | 5 | 1 | .000a | | | - |
| | Group 2 | 5 | 1 | .000a | | | |

A t cannot be computed because the standard deviations of both groups are 0.

Comparison of the early wound healing 1 week between the two groups shows that early wound healing 1 week is higher in Group 2 group with a t value of -0.316 and is statistically non-significant with a p value of 0.76. Comparison of the early wound healing 2 week between the two groups shows that early wound healing 2 week is higher in Group 1 group with a t value of 0 and is statistically non-significant with a p value of 1.

Table 4: Intergroup comparison of Bucco lingual ridge width

| | GROUP | N | Mean | Std. Deviation | t | df | P VALUE |
|--|--------------|----------|-------------|-----------------------|----------|-----------|----------------|
| bucco-lingual ridge width baseline | Group 1 | 5 | 10.8 | 0.837 | 0.316 | 8 | 0.76 |
| | Group 2 | 5 | 10.6 | 1.14 | | | |
| bucco-lingual ridge width implant placement | Group 1 | 5 | 10.2 | 0.837 | 2.646 | 8 | 0.029 |
| | Group 2 | 5 | 8.8 | 0.837 | | | |
| bucco-lingual ridge width abutment placemt | Group 1 | 5 | 9 | 0.707 | 3.5 | 8 | 0.008 |
| | Group 2 | 5 | 7.6 | 0.548 | | | |

Comparison of the bucco-lingual ridge width baseline between the two groups shows that bucco-lingual ridge width baseline is higher in Group 1 group with a t value of 0.316 and is statistically non-significant with a p value of 0.76. Comparison of the bucco-lingual ridge width at implant placement between the two groups shows that bucco-lingual ridge width at implant placement is higher in Group 1 group with a t value of 2.646 and is statistically significant with a p value of 0.029. Comparison of the bucco-lingual ridge width at abutment placement between the two groups shows that bucco-lingual ridge width at abutment placement is higher in Group 1 group with a t value of 3.5 and is statistically significant with a p value of 0.008

Table 5: Intergroup comparison of width of kearatinized gingiva

| | GROUP | N | Mean | Std. Deviation | t | df | P VALUE |
|--|--------------|----------|-------------|-----------------------|----------|-----------|----------------|
| width of keratinized gingiva baseline | Group 1 | 5 | 2.6 | 0.4183 | 0 | 8 | 1 |
| | Group 2 | 5 | 2.6 | 0.4183 | | | |
| width of keratinized gingiva implant placement | Group 1 | 5 | 2.4 | 0.5701 | 1.265 | 8 | 0.008 |
| | Group 2 | 5 | 1.7 | 0.4183 | | | |
| width of keratinized gingiva abutment placement | Group 1 | 5 | 2.1 | 0.4183 | 2.646 | 8 | 0.029 |
| | Group 2 | 5 | 1.4 | 0.4183 | | | |

Comparison of the width of keratinized gingiva baseline between the two groups shows that width of keratinized gingiva baseline is higher in Group 1 group with a t value of 0 and is statistically non-significant with a p value of 1. Comparison of the width of keratinized gingiva implant placement between the two groups shows that width of keratinized gingiva implant

placement is higher in Group 1 group with a t value of 1.265 and is statistically significant with a p value of 0.008. Comparison of the width of keratinized gingiva abutment placement between the two groups shows that width of keratinized gingiva abutment placement is higher in Group 1 group with a t value of 2.646 and is statistically significant with a p value of 0.029.

Table 6: Intergroup comparison of DIB score

| | GROUP | N | Mean | Std. Deviation | t | df | P VALUE |
|-------------------------------------|---------|---|-------|----------------|--------|----|---------|
| DIB score implant placement | Group 1 | 5 | 0.426 | 0.06914 | -2.326 | 8 | 0.149 |
| | Group 2 | 5 | 0.552 | 0.13312 | | | |
| DIB score abutment placement | Group 1 | 5 | 0.744 | 0.11718 | -1.7 | 8 | 0.128 |
| | Group 2 | 5 | 0.872 | 0.12091 | | | |

Comparison of the DIB score implant placement between the two groups shows that DIB score implant placement is higher in Group 2 group with a t value of 2.326 and is statistically non-significant with a p value of 0.149. Comparison of the DIB score abutment placement between the two groups shows that DIB score abutment placement is higher in Group 2 group with a t value of -1.7 and is statistically non-significant with a p value of 0.128

Discussion

The important goal of modern dentistry is to provide a healthy and beautiful smile that is accompanied by a functional and comfortable dentition. There are various treatment modalities available for treatment of missing teeth among which dental implant placement is the most advanced treatment modality which has proven to be predictable.¹²

Extraction sockets are self-healing defects. In a relatively short period of time, the void left by the extracted tooth is filled with new bone. However, this does not occur without side effects; the healing process may lead to resorption of the buccal plate of the socket and may jeopardize possible tooth replacement by implants. Although the degree of bone loss is not certain or constant, since it may vary among individuals and anatomical situations.¹³ It is well accepted that a large amount of alveolar width and height may be lost in the first 6 months following extraction. Different types of bone grafting materials accomplish this issue in different ways. Osteoinductive grafts contain bone morphogenetic proteins (BMPs) that can stimulate bone growth through the differentiation of cells into osteoblasts. Osteoconductive grafts provide a scaffold for bone regeneration on or within the surface of the graft material.¹⁴

When implant dentistry is anticipated following tooth extraction the clinician is faced with many choices. One option is to immediately place an implant in to fresh extraction socket. Another option is to perform the site preservation and then place the implant in a secondary procedure following healing. A third option is to allow socket to heal naturally and then place implant in secondary procedure.¹⁵

The present study consisted of 2 groups [Group 1(socket preserved with DBM putty) and Group 2(naturally healed socket)]. Each group consisted of 5 patients. In group 1 there were 3 males and 2 females having mean age of 38 years. Out of 5 implants 2 implants were placed in the anterior region and 3 implants were placed in posterior region of the jaw after socket preservation with DBM putty. In group 2 there were 2 males and 3 females having mean age of 40 years. Out of 5 implants 1 implant was placed in anterior region and 4 implants were placed in posterior region of the jaw after the healing of extraction socket without preservation.

In present prospective study, patients were selected after completion of phase I therapy. The patient who had tooth with hopeless prognosis and required extraction followed by socket preservation and implant placement were included in the study. This was a clinical and radiographical study to evaluate implants placed in socket preserved sites versus implants placed in naturally healed socket sites. All parameters were recorded at baseline and in second step of surgery implants were placed followed by third step in which abutments were placed.

DBM-based formulations became available for clinical use in 1991. DBM is thought to possess more inductive properties than regular allograft because growth factor availability is increased after the demineralization process. DBM is different from cortical graft because it is mainly cancellous bone tissue. Cortical graft is desirable for structural support but has decreased osteogenicity relative to cancellous bone or marrow bone.¹⁶ Cortical bone has less surface area per unit weight and, therefore, less connectivity. The term connectivity describes the ability of an osteoconductive graft material to be “connected” to host bone and relates to the surface area available in the local healing environment for incorporation into the fusion mass. Because of the increased density of cortical bone, the rate of vascular ingrowth is slower.¹⁷

Several factors are expected to influence the osteoinductive properties of a DBM, including the concentration of osteoinductive proteins in the bone matrix of the individual donor, the intrinsic osteoinductive potential of the individual donor, and the nature of the host response and implantation site. Processing procedures also are known to play an important role in the osteoinductive properties of a DBM. Pre-process handling, varying demineralization times and final particle sizes are among the many factors that may affect osteoinductivity. **Bae et al (2006)**¹⁸ conducted a study to evaluate and compare the quantity of BMPs among several different DBM formulations (inter product variability), as well as, examine the variability of

these proteins in different production lots within the same DBM formulation (intra-product variability). They reported that it was essential to relate osteoinductivity of a commercial compound to the methods of sterilization and processing, and to the relative proportion of BMPs remaining in the DBM product.

The results of the current study was in agreement with Babush (2003)⁷³ study which indicated that demineralised bone matrix putty, when used in patients for dental augmentation in either mandibular or maxillary sites, resulted in replacement of the graft material with bone by as early as 4-6 months, there upon enabling implant placement and subsequent prosthetic reconstruction. In our study we succeeded to overcome problems with handling and containing DBM particles which have limited the exclusive use of this material, as our material had a putty form. Maintenance of the graft material within the defect site was of paramount importance. Any migration of particles from the area could compromise the graft success because of inadequate regeneration of the defect and potential ectopic bone formation.

Plaque index indicates the oral hygiene maintained by patient and is important because it can influence the health of soft tissue around implant. Long term success with regenerative procedures has been directly correlated with plaque control and recall compliance⁷⁴. In these study the plaque score was recorded at baseline, 3 months and 6 months This assessment is confirmed by studies of **A Baroneet al**¹⁹ which also concluded rise in plaque score after surgical procedure but intergroup comparison was non-significant as well.

Modified gingival index is considered to be a true reflection of gingival status in health and disease. It is simple, easy and reproducible index and is used commonly in clinical periodontal research studies. Gingival index was recorded at baseline, 3 months and 6 months. As plaque index, this could also be due to the less recall visits and surgical procedure because of

which patients were not able to maintain proper oral hygiene. Similar results were observed by **A Barone et al**¹⁹ in his study.

Excellent functional and esthetic restoration of an implant depends on its placement to achieve the restorative goals. From, a surgical standpoint dimensions of the alveolar ridge influence implant position. For that bucco-lingual ridge width was measured at baseline, at time of implant placement and at time of abutment placement to evaluate the bone loss in both groups. Group 2 showed significant reduction in bucco-lingual ridge width compared to ridge preserved group. **Schropp et al. 2003**²⁰, and **Barone et al. 2011**² confirmed this assessment by concluding decrease in width and height of alveolar ridge after extraction due to palatal/lingual shift of the residual crest, which may be crucial in future implant placement according to **Abrams et al.**

Iasella et al. 2003 also concluded that ridge preservation have better results compared to tooth extraction alone. In this study both group showed decline in bucco-lingual ridge width after implant placement but, group 1(ridge preserved) showed significantly less reduction compared to group 2(naturally healed). This assessment was confirmed by study of **Barone et al 2012** which also concluded that ridge preserved site shows less horizontal bone loss than naturally healed site after implant placement.

Gingival phenotype which include width of keratinized gingiva which is associated with facial plate thickness. In this study width of keratinized gingiva was evaluated at baseline, at time of implant placement and at time of abutment placement..**Lekovic et al 1994**concluded that greater increment in keratinized gingiva can be obtain by incorporating coronal advancement of gingival tissue with ridge preservation. In contrast to that study of **Barone et al 2012** resulted in increment in width of keratinized gingiva in ridge preservation without coronal advancement of gingiva.

DIB score is used to evaluate the crestal/ marginal bone loss around implant. In this study DIB score was recorded at the time of implant placement and at the time of abutment placement. Both group showed crestal bone loss around implant..**Crespi et al. 2009** also compared the marginal bone loss which emerged that there was no statistically difference was observed among the groups after a period of 24 months. Similar radiographic assessment was used in study of **Johann Bui Quoc et al 2018** which concluded the same result as this study.

Buser's criteria were recorded dichotomously in 'yes' or 'no'; starting from the implant placement to each follow-up visit to record the clinical condition of the implant site as well as patient's comfort towards the treatment. The criteria were inclusive of the pain, clinical mobility, recurrent peri-implant infection, and continuous radiolucency after the loading of implant. All the readings amongst the patients were negative and showed 100% success in pertinence to the criteria.

Limitations:

A large sample size would have been preferable with a long term follow up. We have taken into consideration both the single and multi-rooted teeth, but the post extraction healing sequel is different for both these teeth which may be a limiting factor in the study. Clinical ridge measurements were made without the use of stents in this study. The lack of exact fixed reference points may have led to some error in measurements of ridge width taken at the time of extraction compared to similar measurements taken at the time of implant placement. In this study DBM putty was used as grafting material, but result may vary with different grafting material and different grafting technique.

Conclusion

Bucco lingual ridge width and width of keratinized gingiva can be preserved by ridge preservation after extraction. Short-term survival rates and clinical outcomes of both groups were similar and were comparable. Further clinical trials with longer duration follow up with larger sample size should be done to get more affirmative and conclusive results.

UNDER PEER REVIEW

References

- [1] Gazelakis E: The rectangular block implant: a novel implant design for the posterior atrophic ridge. 2018.
- [2] Barone A, Orlando B, Cingano L, Marconcini S, Derchi G, Covani U: A randomized clinical trial to evaluate and compare implants placed in augmented versus non-augmented extraction sockets: 3-year results. *Journal of periodontology* 2012, 83:836-46.
- [3] Adel R: A long term follow-up study of osseointegrated implants in the treatment of totally edentulous jaws. *Int J Oral Maxillofac Implants* 1990, 5:347-52.
- [4] Johnson K: A study of the dimensional changes occurring in the maxilla following tooth extraction. *Australian dental journal* 1969, 14:241-4.
- [5] Lekovic V, Camargo PM, Klokkevold PR, Weinlaender M, Kenney EB, Dimitrijevic B, Nedic M: Preservation of alveolar bone in extraction sockets using bioabsorbable membranes. *Journal of periodontology* 1998, 69:1044-9.
- [6] Hämmerle CH, Araújo MG, Simion M, Group OC: Evidence-based knowledge on the biology and treatment of extraction sockets. *Clinical oral implants research* 2012, 23:80-2.
- [7] Kassim B, Ivanovski S, Mattheos N: Current perspectives on the role of ridge (socket) preservation procedures in dental implant treatment in the aesthetic zone. *Australian dental journal* 2014, 59:48-56.
- [8] Felice P, Soardi E, Piattelli M, Pistilli R, Jacotti M, Esposito M: Immediate non-occlusal loading of immediate post-extractive versus delayed placement of single implants in preserved sockets of the anterior maxilla: 4-month post-loading results from a pragmatic multicentre randomised controlled trial. *Eur J Oral Implantol* 2011, 4:329-44.

- [9] Sans FA: Minimally Invasive Alternatives to Dental Extraction and Implant Placement. Minimally Invasive Approaches in Endodontic Practice: Springer, 2021. pp. 203-31.
- [10] Gupta P, Agarwal N, Anup N, Manujunath B, Bhalla A: Evaluating the anti-plaque efficacy of meswak (*Salvadora persica*) containing dentifrice: A triple blind controlled trial. Journal of pharmacy & bioallied sciences 2012, 4:282.
- [11] Lobene R: A modified gingival index for use in clinical trials. Clin Prevent Dent 1986, 8:3-6.
- [12] Jyothi S, Triveni M, Mehta D, Nandakumar K: Evaluation of single-tooth replacement by an immediate implant covered with connective tissue graft as a biologic barrier. Journal of Indian Society of Periodontology 2013, 17:354.
- [13] Caiazzo A, Brugnamì F, Mehra P: Buccal plate augmentation: a new alternative to socket preservation. Journal of oral and maxillofacial surgery 2010, 68:2503-6.
- [14] Damien CJ, Parsons JR: Bone graft and bone graft substitutes: a review of current technology and applications. Journal of Applied Biomaterials 1991, 2:187-208.
- [15] Caplanis N, Lozada JL, Kan JY: Extraction defect assessment, classification, and management. Cda Journal 2005, 33.
- [16] Kazemian A: Bone putty bioimplant improvement: evaluation of the influence of surface area and shape of the DBM (demineralised bone matrix) component on bone induction and biocompatibility properties of carrier (polymer)/demineralised bone matrix. University of Leicester, 2015.
- [17] Jones JR: Review of bioactive glass: from Hench to hybrids. Acta biomaterialia 2013, 9:4457-86.

[18] Bae HW, Zhao L, Kanim LE, Wong P, Delamarter RB, Dawson EG: Intersubject and intrasubject variability of bone morphogenetic proteins in commercially available demineralized bone matrix products. *Spine* 2006, 31:1299-306.

[19] Barone A, Ricci M, Tonelli P, Santini S, Covani U: Tissue changes of extraction sockets in humans: a comparison of spontaneous healing vs. ridge preservation with secondary soft tissue healing. *Clinical oral implants research* 2013, 24:1231-7.

[20] Schropp L, Wenzel A, Kostopoulos L, Karring T: Bone healing and soft tissue contour changes following single-tooth extraction: a clinical and radiographic 12-month prospective study. *International Journal of Periodontics & Restorative Dentistry* 2003, 23.

UNDER PEER REVIEW