

## **Comparison of efficacy of the PAP and H&E in identifying the various changes in liver samples of High fat diet induced rat - Original In vitro study**

**Running title :** Comparison of efficiency of the PAP and H&E in identifying the various changes in liver samples of high fat diet induced rat

### **Abstract**

#### **Introduction**

High fat induced (HFI) liver is associated with a high calorie intake and many other diet-induced complications, such as metabolic syndrome and cardiovascular disease. HFI is the most common chronic liver disease that develops due to high fat intake. A wide range of liver injuries is associated with HFI, ranging from simple steatosis to nonalcoholic steatohepatitis (NASH), advanced fibrosis and cirrhosis. The signs and symptoms of metabolic syndrome may be induced in rats by feeding them a diet rich in carbohydrates and fat. The aim of the study is Comparison of efficiency of the PAP (Papanicolaou) stain and H&E (Hematoxylin and eosin) stain in identifying the various changes in liver samples of high fat diet induced rat.

#### **Materials and Methods**

Liver samples of Normal control group animal and High fat diet induced animal were sectioned, weighed fixed 10% neutral buffer formalin and mounted in DPX compound. Four micrometer sections were stained with hematoxylin-eosin and PAP stains for the histological examination of microvesicular and macrovesicular steatosis in the liver tissue. The grading of steatosis was given from 0-3 based on the lipid accumulation (steatosis) : grade 0 - absence; grade 1 - mild Steatosis (<30% hepatocyte) ; grade 2- moderate steatosis (30%-70% hepatocyte); grade3- severe steatosis (>70%hepatocytes).Efficacy of grade of PAP stain and H&E stain where accessed and statistically evaluated by considering seven parameters and overall staining characters where compared.

#### **Results**

Our present study evaluated high fat induced hepatic steatosis of H&E and PAP stain and also evaluated efficacy of both the stain.In our study, Pie chart showing the percentage distribution of Number of microvesicles about 70% represents greater than 30, 10% represents 30-70, 20% represents less than 70 (figure 1). In our study 20% represents the greater than 30, 30% represents the 30-70 , 50% represents Less than 70 (figure 2). 30% represents mild steatosis , 20% represents moderate steatosis, 50% represents Severe Steatosis (figure 3).

#### **Conclusion**

We demonstrated the comparative efficiency of the PAP and H&E high fat diet induced rat liver by in vivo and conclude that both H&E and PAP stain has equal efficacy and clarity in observing the various minute parameters.

### **Key words**

Papanicolaou, Haematoxylin and eosin, innovative technique, High fat diet, steatosis

### **Introduction:**

A high-fat diet (HFD) is a diet consisting of at least 35% of total calories consumed from fats, both unsaturated and saturated (1). In addition to the popular processed foods, many other foods have a high fat content including but not limited to animal fat, chocolate, butter, and oily fish(2). In a previous study, it was observed that High fat induces significant lobular inflammation, hepatocellular necrosis, hepatocellular ballooning, portal tract inflammation, pericellular and portal fibrosis as described. Also liver collected from rats in different stages of experiment. Many previous studies performed on mice and rats suggested that obesity can be induced by a high fat diet(3).

High-fat diet intake allows animals to develop obesity, hyperinsulinemia, hyperglycemia, hypertension, and liver damage, similar to the phenotype observed in rats with HFD. Thus, review studies that use this model to study the effects of lipid intake(4). Consuming a high-fat, high-sugar diet causes a harmful accumulation of fat in the liver that may not reverse even after switching to a healthier diet, A high-fat diet causes liver injury in rats leading to periportal fibrosis. A role for oxidative stress is suggested via increased NADPH oxidase activity, lipid peroxidation, protein carbonyl formation, and low antioxidant defense(5).

Steatosis (fatty liver) is commonly caused by insulin resistance due to obesity. Histologically, it is characterized as hepatocytes containing excess fat and appearing to have multiple round, empty vacuoles in the cytoplasm(5,6). Hepatic steatosis is an intrahepatic fat of at least 5% of liver weight. Simple accumulation of triacylglycerols in the liver could be hepatoprotective; however, prolonged hepatic lipid storage may lead to liver metabolic dysfunction, inflammation, and advanced forms of nonalcoholic fatty liver disease(7).

Microvesicular steatosis is characterized by the presence of numerous small vesicles of fat that do not displace the nucleus. Macrovesicular steatosis is characterized by engorgement of the hepatocyte by a large fat globule that displaces the nucleus(8). Macrovesicular steatosis is the most common form and is histologically characterized by hepatocytes containing a single vacuole of fat filling up the hepatocyte and displacing the nucleus to the cell's periphery. Macrovesicular steatosis is typically caused by alcohol, diabetes, or obesity. The term

"microvesicular steatosis of the liver" refers to a variant form of hepatic fat accumulation whose histologic features contrast with the much more common macrovesicular steatosis.(9).

Hepatic tissue analysis from rats fed with HFD (High Fat Diet) revealed a progressive increase in steatosis and inflammatory damage in comparison with control diet fed animals. Hematoxylin-eosin stained liver samples obtained from the two groups fed HFD showed initial signs of liver inflammation characterized by the presence of mixed inflammatory cell infiltration and hepatocyte necrosis or apoptosis which appeared throughout the lobule and more evident at 8 weeks. HFD rats showed progressive time-dependent steatosis (from grade 2 to grade 3) with a histological pattern characterized by microvesicular steatosis, already evident after 5 weeks of HFD(10). The hepatocytes showed the cytoplasm filled with small vacuoles which were uniform in size and smaller than the centrally located nucleus. No alterations were observed in the liver of the rats fed with the control diet. To further characterize the progressive steatosis and inflammation, we assayed hepatic triglycerides, which were significantly increased in 8 weeks HFD-fed animals. The accumulated lipids induce oxidative stress, resulting in production of cytokines and reactive oxygen species which in turn activate apoptosis thereby initiating a sequence of disease events from steatosis to nonalcoholic steatohepatitis(11).

PAP(Papanicolaou) stain is a polychromatic stain that uses multiple dyes to differentially stain various components of the cells. It is a histological and cytopathological staining technique used to differentiate cells in a smear preparation(12). It is mainly used for oral and cervical cancer screening in asymptomatic populations and in the follow up of patients with cancer. Hematoxylin and Eosin (H&E) staining is used routinely in histopathology laboratories as it provides the pathologist/researcher a very detailed view of the tissue. It achieves this by clearly staining cell structures including the cytoplasm, nucleus, and organelles and extracellular components(13).

The challenges faced by others was that cell sections are prepared and shown by the morphological abnormalities. The research is needed to compare the efficacy of PAP and H&E stains in rat liver samples. The deficiency is fulfilled to identify the specificity and sensitivity of PAP and H&E stain liver structures. The aim of the study is Comparison of efficiency of the PAP and H&E in identifying the various changes in liver samples of high fat diet induced rat (14).

### **Materials and Methods :**

Liver samples of Normal control group animal and High fat diet induced animal were included in the present study ( normal control group -5 animal and high fat diet induced - 5 animal ) , Sectioning samples were collected from randomly 10 rat liver samples was examined at Pink Lab of Saveetha Dental College and Hospitals, Saveetha Institute of Medical and Technical Sciences. The study was approved by the Institutional Ethical committee with approval number IHEC/SDC/UG-1994/21/209. The criterion for choosing the sample was the high fat induced rat

liver. It's a cross-sectional in vivo study. The sample was taken from rats and a total of ten rats are engaged. The validation of the procedure was given by a research guide. The data collected and tabulated in excel spreadsheet and statistical analysis were done by SPSS - Version 23. The high fat induced liver rat samples and healthy rat liver samples are included in the study. Key risk factors like over weighted and an altered dietary pattern are excluded.

Liver samples of Normal control group animal and High fat diet induced animal were sectioned, weighed and fixed 10% neutral buffer formalin and mounted in DPX compound. Four micrometer sections were stained with hematoxylin-eosin and PAP stains for the histological examination of microvesicular and macrovesicular steatosis in the liver tissue. Our present study evaluated the grading of steatosis based on the lipid accumulation (steatosis) : grade 0 - absence; grade 1 - mild Steatosis (<30% hepatocyte) ; grade 2- moderate steatosis (30%-70% hepatocyte); grade3- severe steatosis (>70%hepatocytes). Efficacy of grade of PAP stain and H&E stain where accessed and statistically evaluated by considering seven parameters and overall staining characters where compared.

#### **Hematoxylin and eosin staining Procedure:**

The first step in performing an H&E stain, the slide has been kept in the suitable adhering agents, then slightly warm to melt the wax off, remove the wax with xylene by 3 changes and also with propanol for 3 changes, bring the smear to the water for 3 minutes, dip the smear in rapid nuclear stain for 60 sec then add 3 drops of scott's tap water buffer and wash after 10 seconds, dip the smear in eosin stain for 60 sec and also wash the smear for 15 sec to remove the excess water, finally clear with propanol then with xylene and mount with DPX.

#### **PAP staining procedure :**

Hydrate the fixed smear for 3-5 minutes in tap water and blot out excess water from the slide. Keep the slide on a staining rack and add a few drops of nuclear stain rapid PAP (R1) to cover the smear. Wait for 60 seconds and wash in running tap water. Add 3-5 drops of wash Buffer (R7) and wash after 20 Sec. Blot out excess water from the slide. Dehydrate with RAPID-PAP DEHYDRANT (R5) for 60 seconds. keep the slide on a staining rack and add a few drops of working CYTOPLASM STAIN (R2A+R2B) to cover the smear. Wait for 60 seconds. Wash in tap water, blot out excess water from the slide and may see under microscopy (unmounted). If the smear requires mounting, dehydrate with RAPID-PAP DEHYDRANT (R5) for 60 seconds and dry in the air. Rinse with Xylene (R6). Mount with cover glass using a drop of D.P.X.(R4).

#### **Results:**

Our present study evaluated high fat induced hepatic steatosis of H&E and PAP stain and also evaluated efficacy of both the stain.

**Table 1: Table showing Lipid Inclusion in PAP stain**

| <b>Samples</b> | <b>No. of microvesicles</b> | <b>No. of macrovesicles</b> | <b>Grade</b> |
|----------------|-----------------------------|-----------------------------|--------------|
| 1              | 28                          | 67                          | Moderate     |
| 2              | 26                          | 92                          | Severe       |
| 3              | 81                          | 25                          | Mild         |
| 4              | 85                          | 21                          | Mild         |
| 5              | 22                          | 90                          | Severe       |
| 6              | 28                          | 94                          | Severe       |
| 7              | 21                          | 63                          | Mild         |
| 8              | 25                          | 92                          | Severe       |
| 9              | 27                          | 64                          | Moderate     |
| 10             | 30                          | 90                          | Severe       |

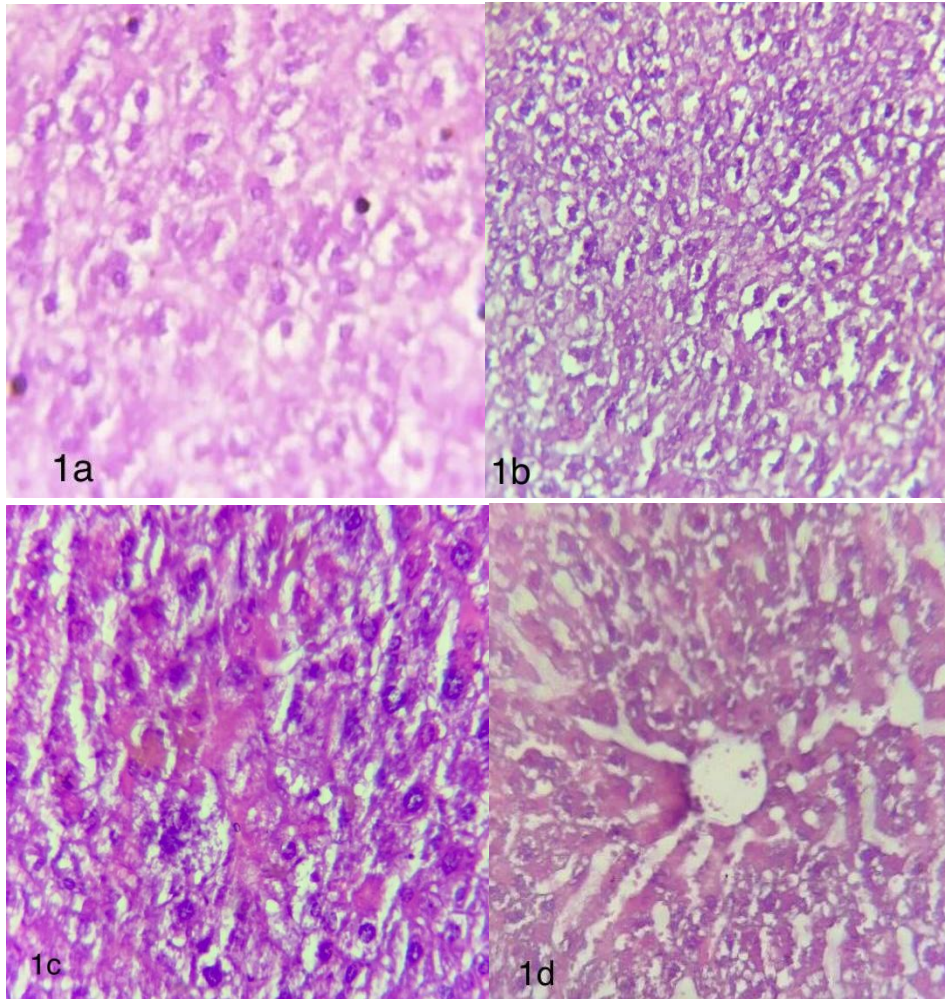


Image 1. Photomicrograph showing 1a: Lipid accumulation around the nucleus (H&E,40x), 1b: Microvesicular and focal macrovesicular steatosis (H&E,40x), 1c: Coalesced hepatocytes with moderate steatosis (H&E,40x) , 1d: Liver parenchyma with hepatic vein (H&E,40x).

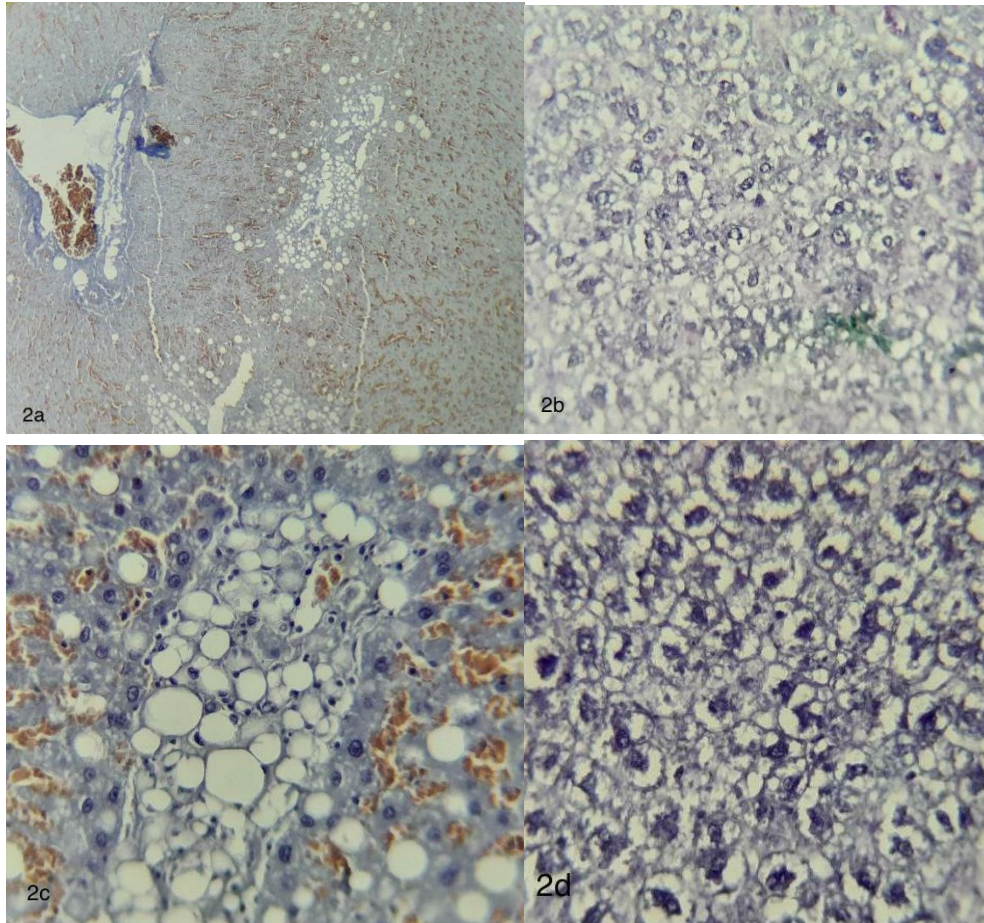
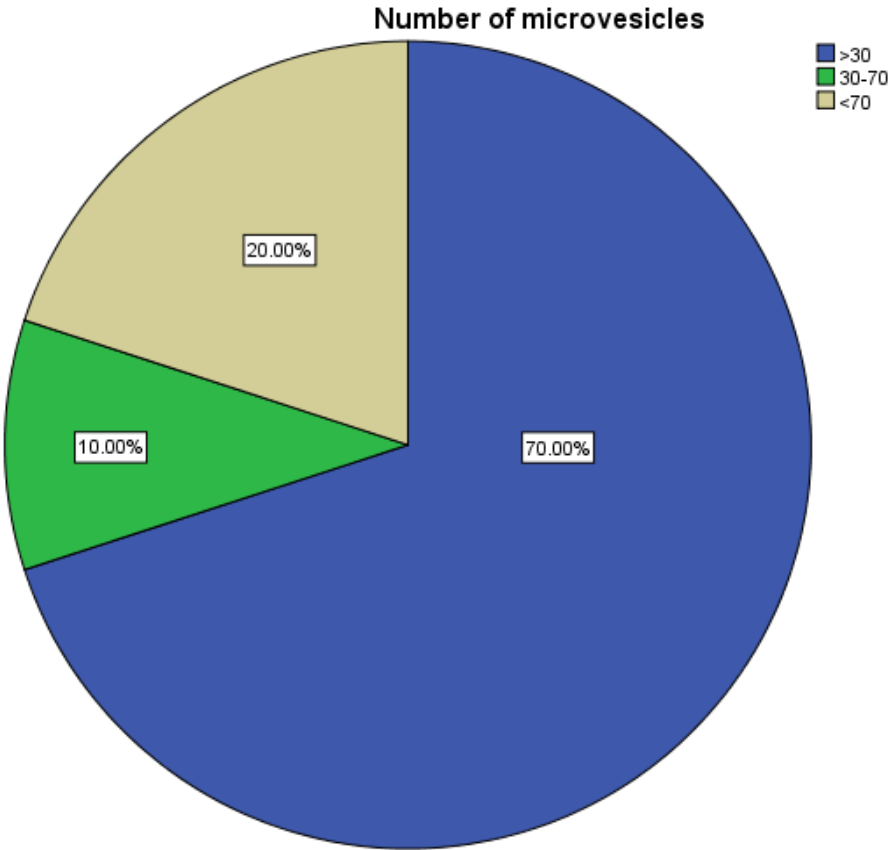
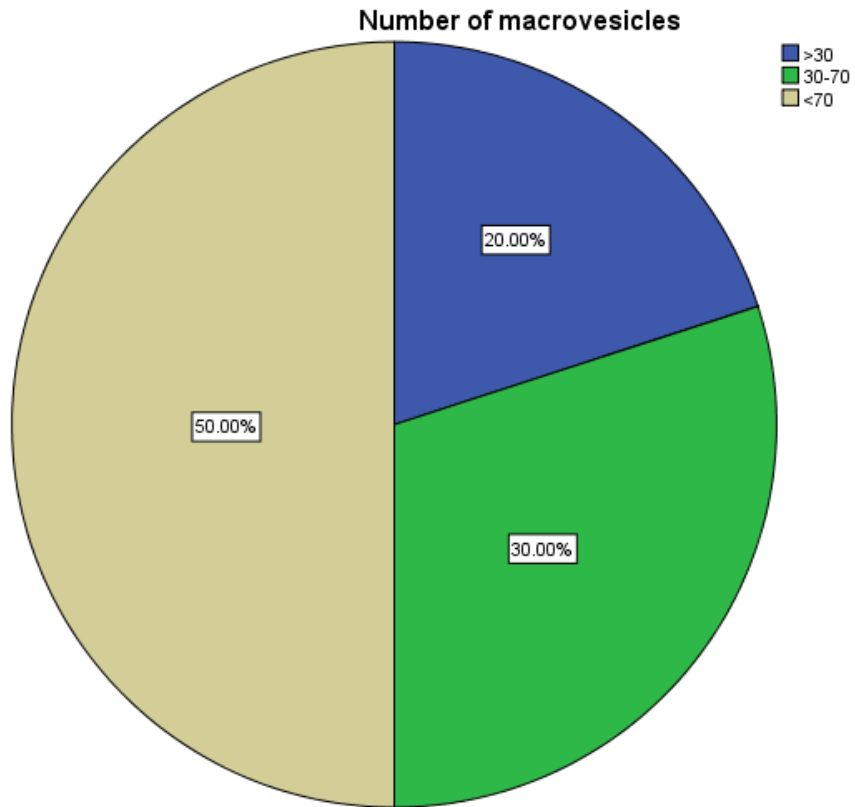


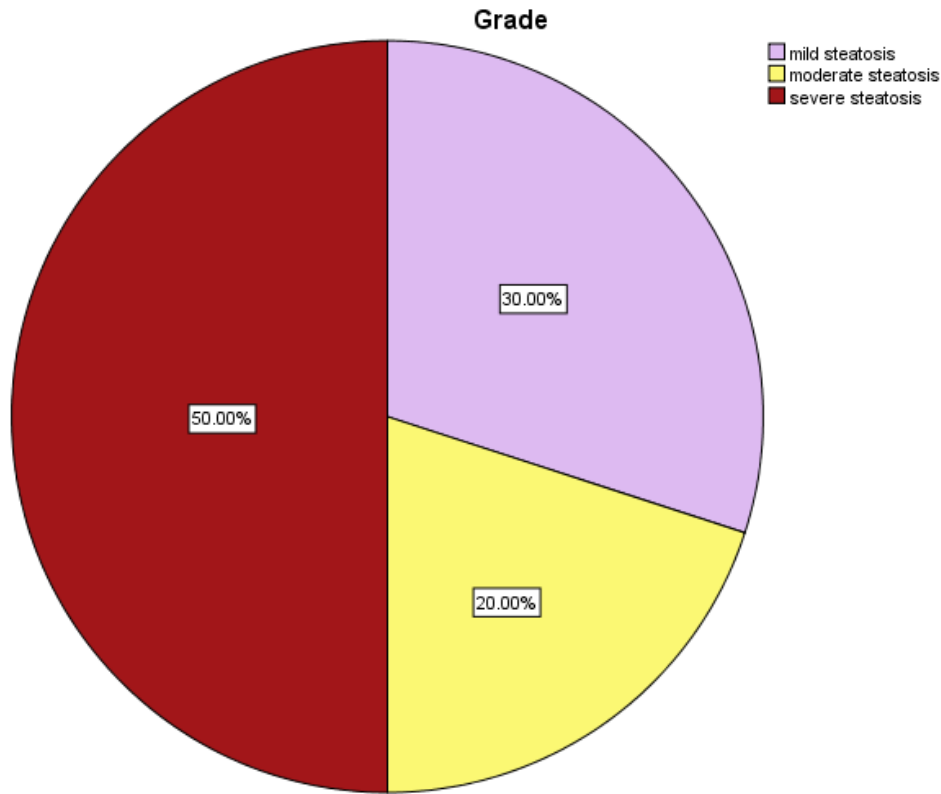
Image 2. Photomicrograph showing 2a: Liver parenchyma exhibiting steatosis, portal triad and congested sinusoids (PAP,10x), 2b: Liver parenchyma with moderate to severe steatosis (PAP,40x), 2c: Macrovesicular steatosis with lipid accumulation in the cytoplasm and peripherally pushed nucleus (PAP,40x), 2d: Hepatocytes showing perinuclear lipid accumulation (PAP,40x).



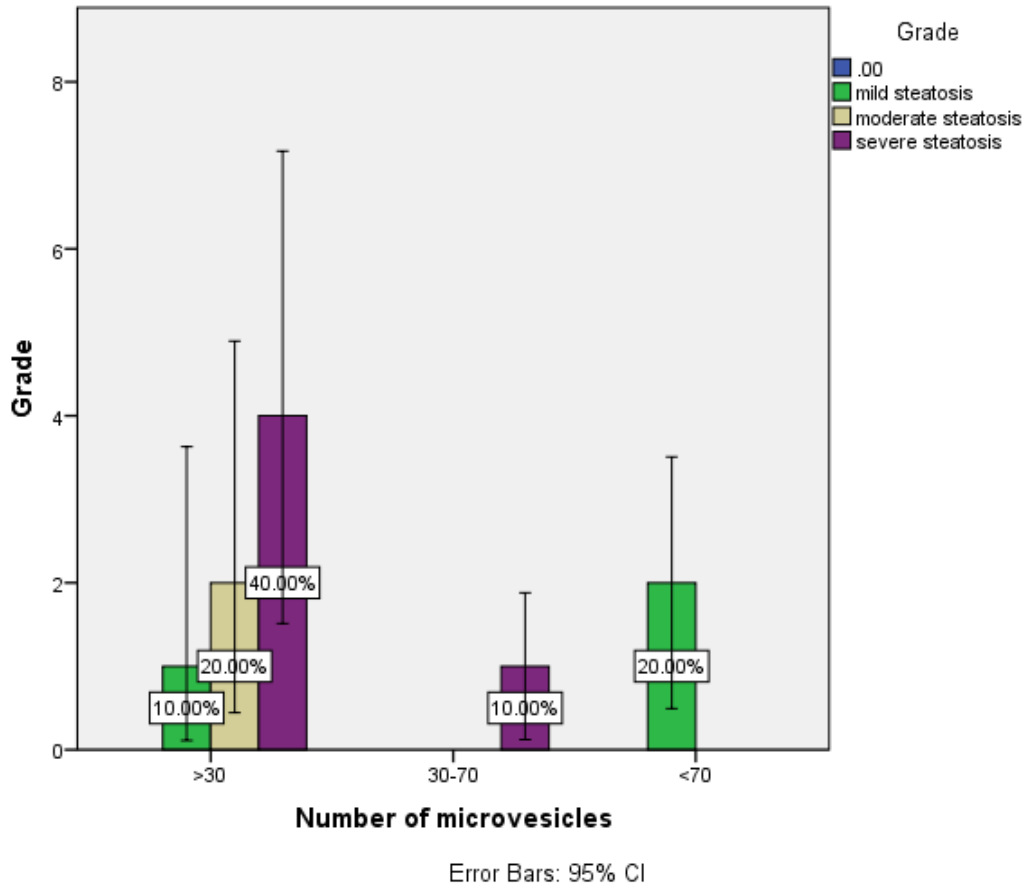
**Figure 1:** Pie chart showing percentage distribution of Number of microvesicles. 70% (Blue colour) represents the greater than 30, 10% (green colour) represents the 30-70 , 20% (beige colour) represents less than 70.



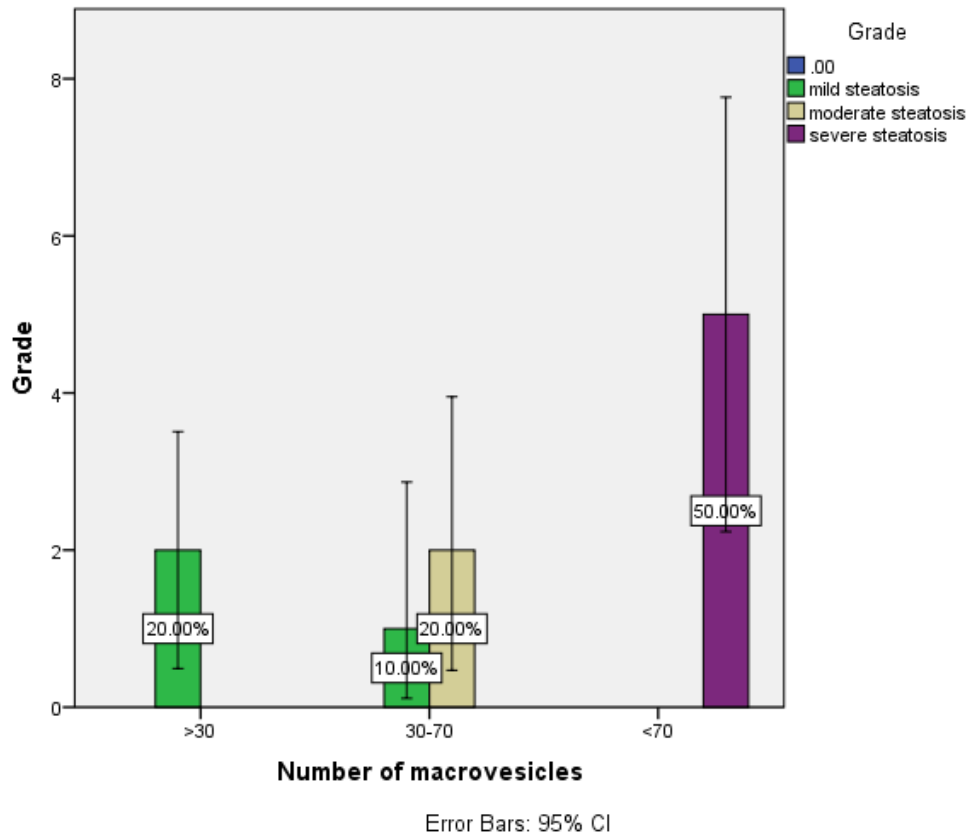
**Figure 2:** Pie chart showing percentage distribution of Number of macrovesicles. 20% (Blue colour) represents the greater than 30, 30% (green colour) represents the 30-70 , 50% (beige colour) represents Less than 70.



**Figure 3:** Pie chart showing percentage distribution of Grade. 30% (Lavender colour) represents mild steatosis, 20% (Yellow) represents moderate steatosis, 50% (Maroon colour) represents Severe Steatosis.



**Figure 4:** The above error graph depicts the number of microvesicles and Grade. 10% (green colour) represents mild steatosis, 20% (Beige colour) represents moderate steatosis, 40% (Purple colour) represents severe steatosis with number of microvesicles > 30. 10% (purple colour) represents severe steatosis with number of microvesicles 30-70. 20% (green colour) represents mild steatosis with number of microvesicles < 70.



**Figure 5:** The above error graph depicts the number of macrovesicles and Grade. 20% (green colour) represents mild steatosis with number of macrovesicles > 30. 10% (green colour) represents mild steatosis and 20% (beige colour ) represents moderate steatosis with number of microvesicles 30-70. 50% (purple colour) represents severe steatosis with number of macrovesicles < 70.

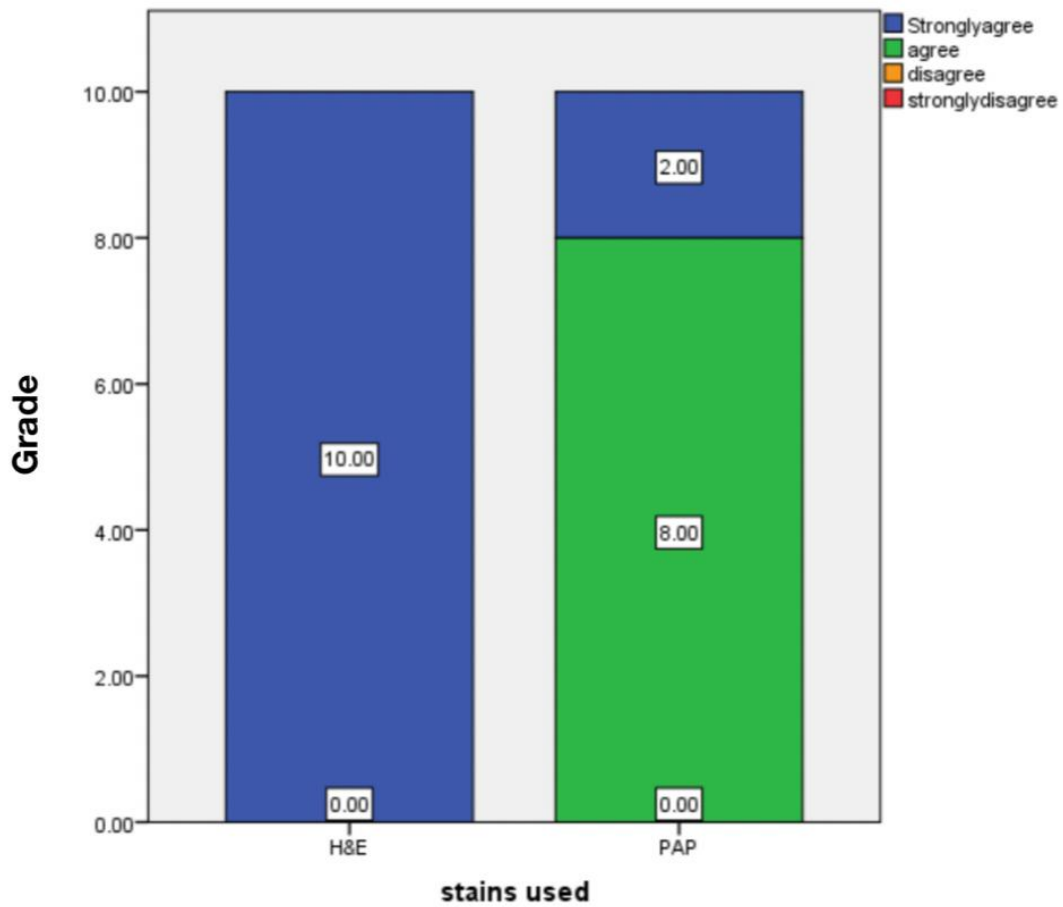


Figure 6: Bar Chart depicts the association between stain used (X-axis) and grades (Y-axis). In this bar graph it is evident that the Parenchyma 100% strongly agree for Hematoxylin and eosin staining and 80% agree and 20% strongly agree in PAP staining.

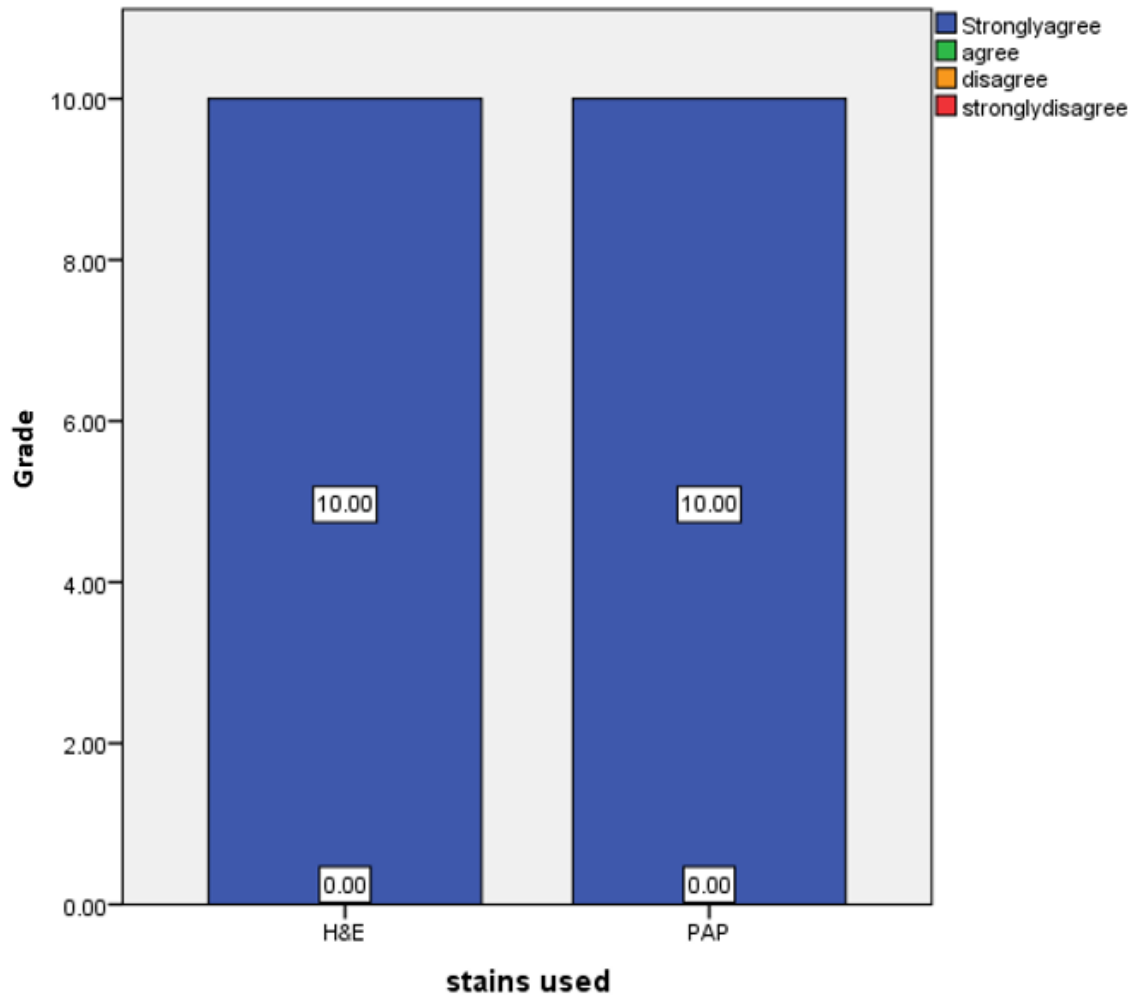


Figure 7: Bar Chart depicts the association between stain used (X-axis) and Grade (Y-axis). In this bar graph it is evident that the Hepatocytes 100% strongly agree for Hematoxylin and eosin staining and 100% Strongly agree in PAP staining.

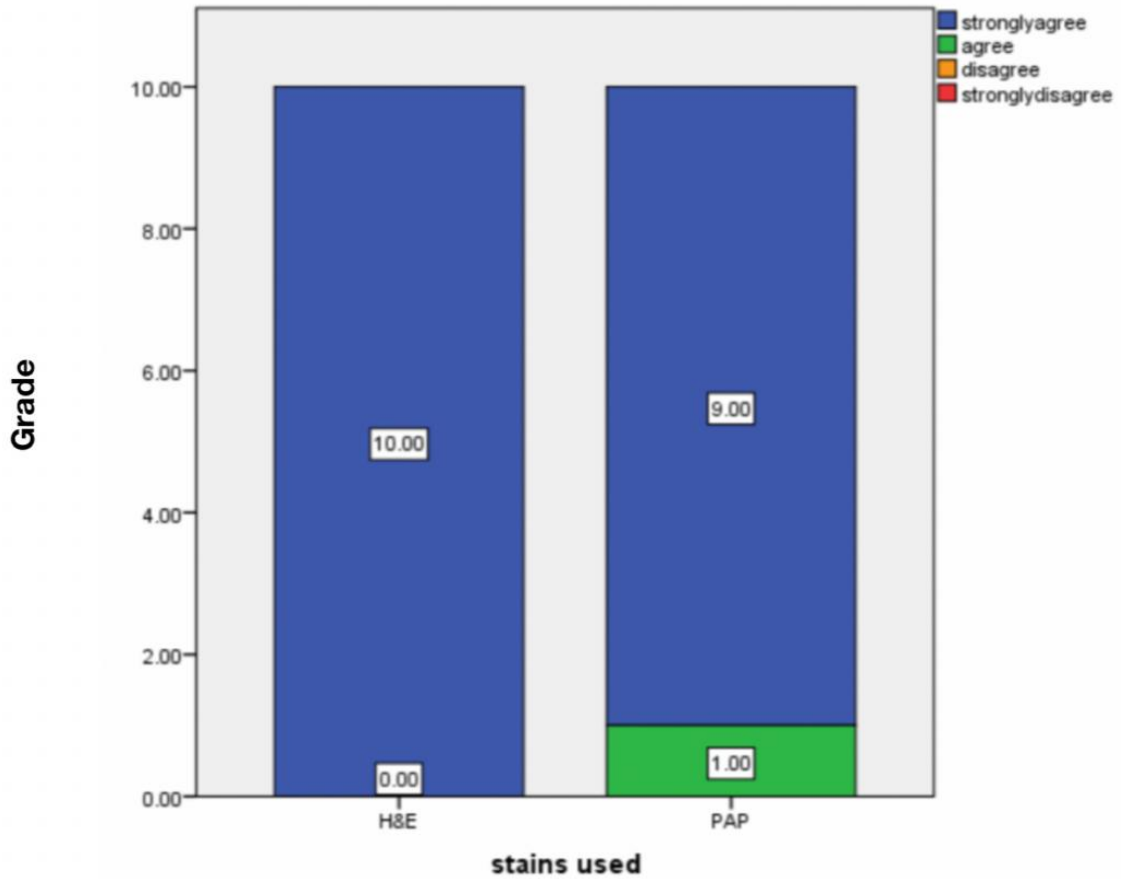


Figure 8: Bar Chart depicts the association between stain used (X-axis) and Grade (Y-axis). In this bar graph it is evident that the Central vein 100% strongly agree for Hematoxylin and eosin staining and 90% Strongly agree in PAP staining and 10% agree in PAP stain.

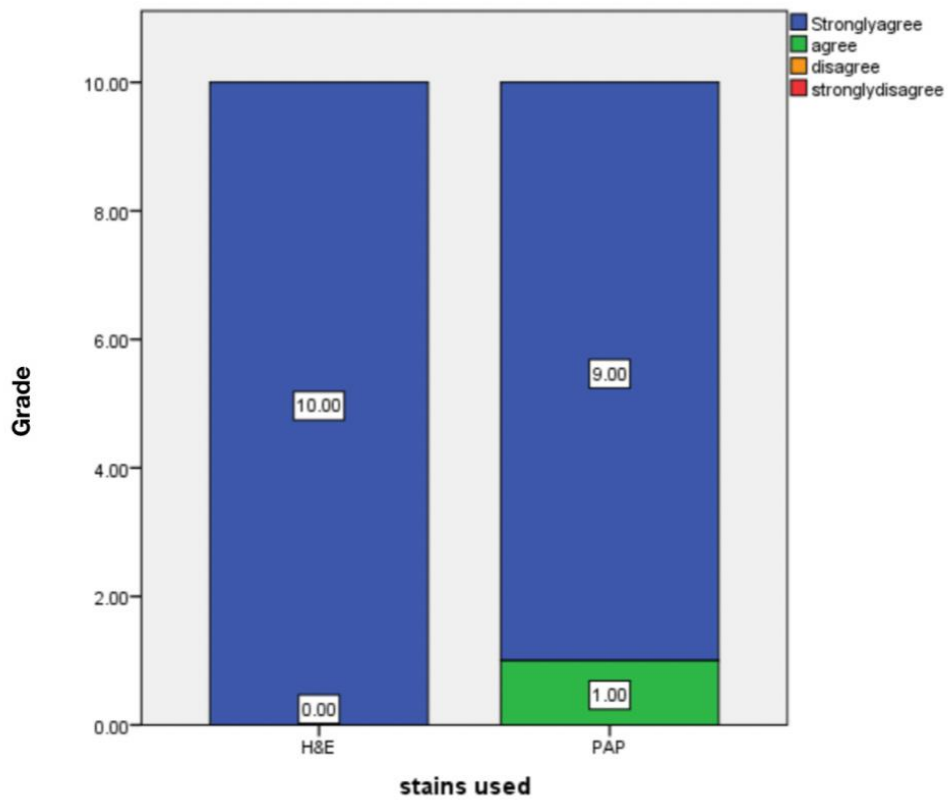


Figure 9: Bar Chart depicts the association between stain used (X-axis) and Grade (Y-axis). In this bar graph it is evident that the Portal vein 100% strongly agree for Hematoxylin and eosin staining and 90% Strongly agree in PAP staining and 10% agree in PAP stain.

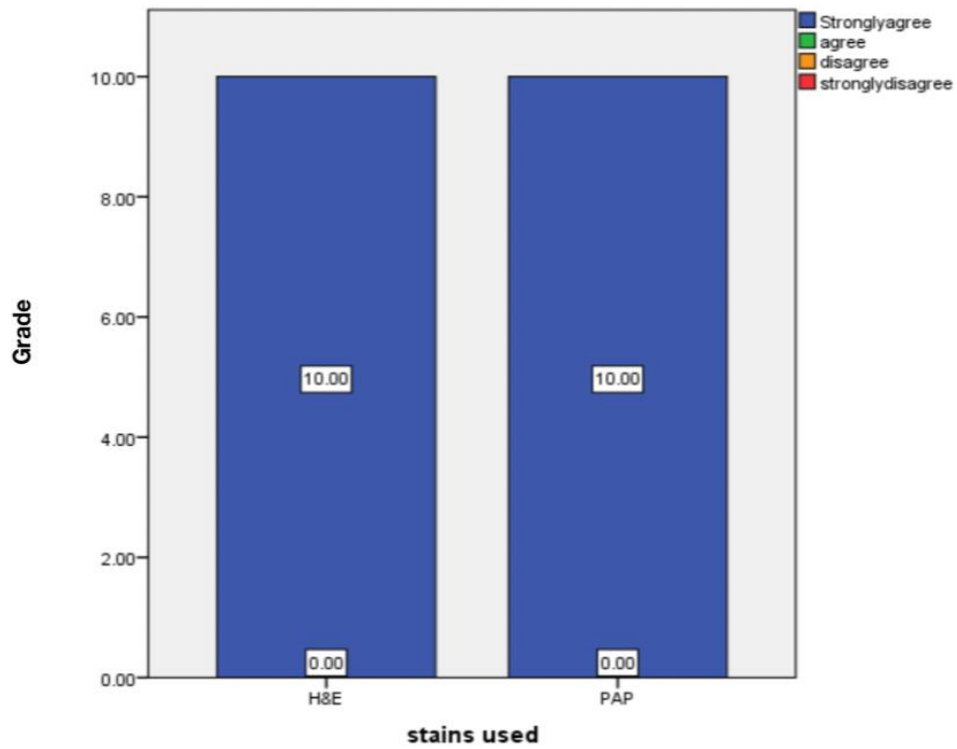


Figure 10: Bar Chart depicts the association between stain used (X-axis) and Grade (Y-axis). In this bar graph it is evident that the Sinusoids 100% strongly agree for Hematoxylin and eosin staining and 100% Strongly agree in PAP staining.

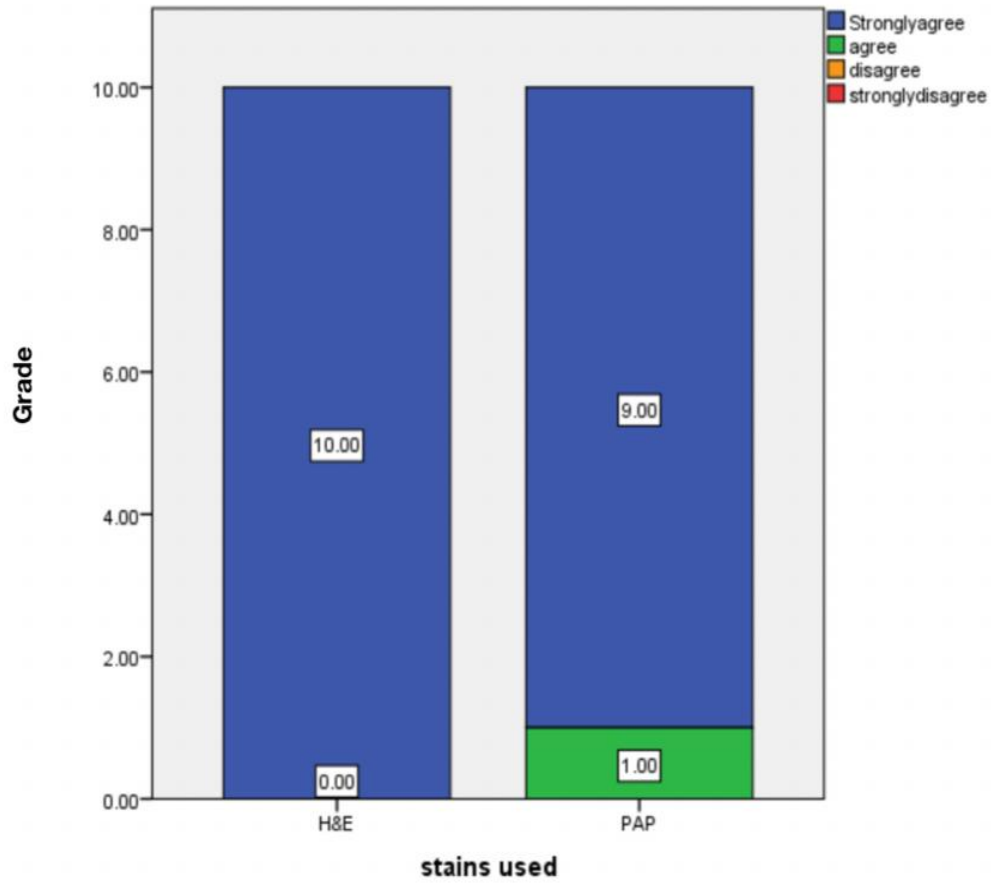


Figure 11: Bar Chart depicts the association between stain used (X-axis) and Grade (Y-axis). In this bar graph it is evident that the Bile duct 100% strongly agree for Hematoxylin and eosin staining and 90% Strongly agree in PAP staining and 10% agree in PAP stain.

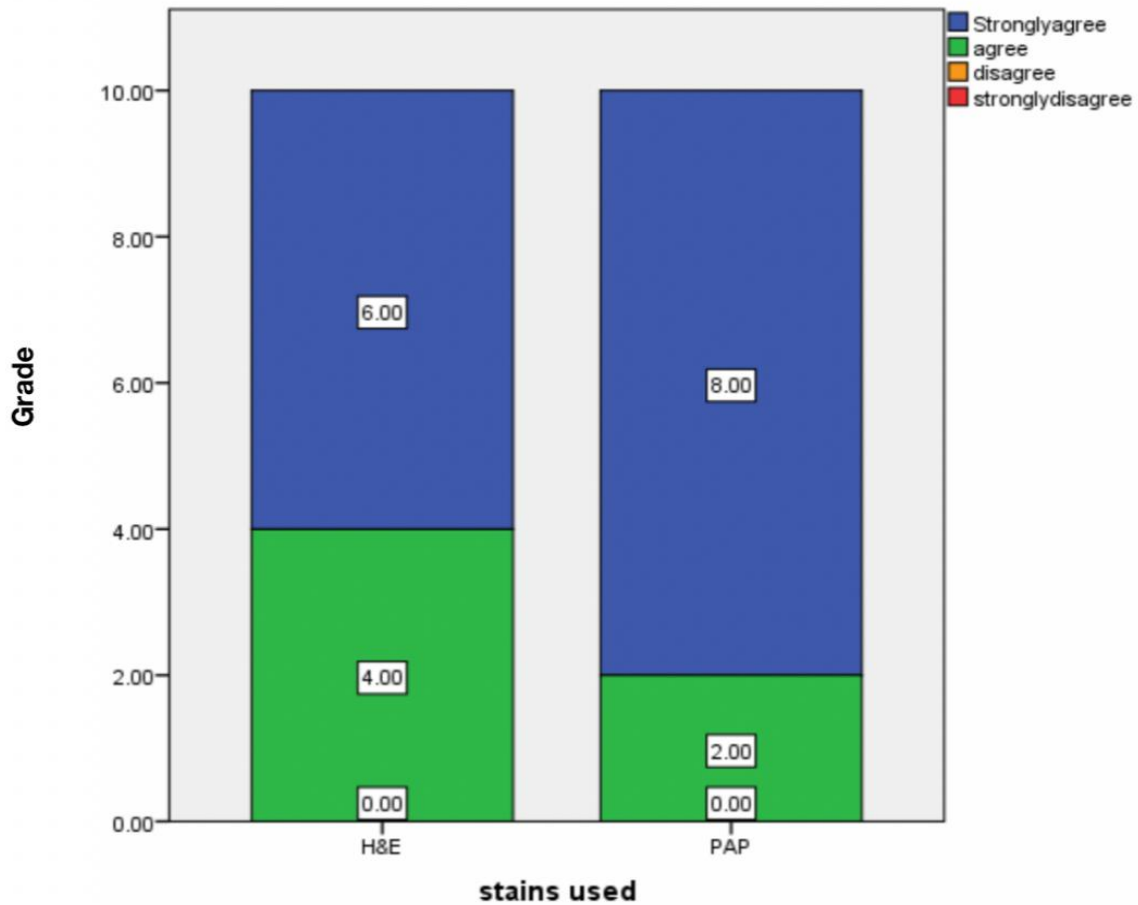


Figure 12: Bar Chart depicts the association between stain used (X-axis) and Grade (Y-axis). In this bar graph it is evident that the Hepatic vein 60% strongly agree for Hematoxylin and eosin staining and 40% agree for Hematoxylin and eosin staining and 80% strongly agree for PAP stain and 20% agree for PAP Staining.

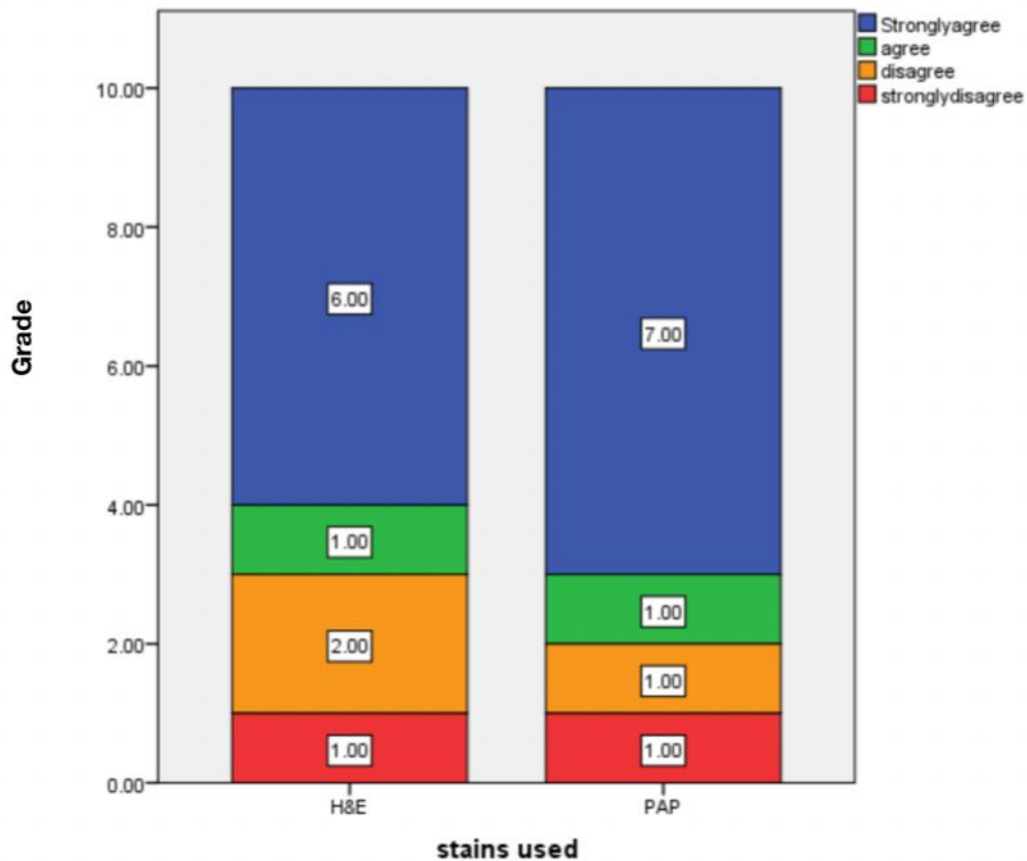


Figure 13: Bar Chart depicts the association between stain used (X-axis) and Grade (Y-axis). In this bar graph it is evident that the Steatosis 60% strongly agree for Hematoxylin and eosin and 10% agree Hematoxylin and eosin and 20% disagree Hematoxylin and eosin and 10% strongly disagree for Hematoxylin and eosin.70% strongly agree for PAP Stain, 10% agree for PAP Stain,10% disagree for PAP Stain and 10% strongly disagree for PAP Stain.

**Discussion:**

In our study, comparison of efficiency of the PAP and H&E in identifying the various changes in liver samples of high fat diet induced rat showed the percentage distribution of Number of microvesicles about 70% represents greater than 30, 10% represents 30-70, 20% represents less than 70 (figure 1). In our study 20% represents the greater than 30, 30% represents the 30-70, 50% represents less than 70 (figure 2). 30% represents mild steatosis, 20% represents moderate steatosis, 50% represents severe steatosis (figure 3). Error graph depicts the number of microvesicles and Grade about 10% represents mild steatosis, 20% represents moderate steatosis, 40% represents severe steatosis with number of microvesicles is  $> 30$ . Number of microvesicles is 30-70 - 10% represents severe steatosis with number of microvesicles is 30-70. 20% represents mild steatosis with the number of microvesicles is  $< 70$  (figure 4). In our study 20% (green colour) represents mild steatosis with number of macrovesicles  $> 30$ . 10% (green colour) represents mild steatosis with number of microvesicles 30-70. 50% (purple colour) represents severe steatosis with number of macrovesicles  $< 70$  (figure 5). In this bar graph it is evident that the Parenchyma 100% strongly agree for Hematoxylin and eosin staining and 80% agree and 20% strongly agree in PAP staining (figure 6). In this bar graph it is evident that the Hepatocytes 100% strongly agree for Hematoxylin and eosin staining and 100% Strongly agree in PAP staining (Figure 7). In this bar graph it is evident that the Central vein 100% strongly agree for Hematoxylin and eosin staining and 90% strongly agree in PAP staining and 10% agree in PAP stain (Figure 8). In this bar graph it is evident that the Portal vein 100% strongly agree for Hematoxylin and eosin staining and 90% strongly agree in PAP staining and 10% agree in PAP stain (Figure 9). In this bar graph it is evident that the sinusoids 100% strongly agree for Hematoxylin and eosin staining and 100% strongly agree in PAP staining (Figure 10). In this bar graph it is evident that the Bile duct 100% strongly agree for Hematoxylin and eosin staining and 90% Strongly agree in PAP staining and 10% agree in PAP stain (Figure 11). In this bar graph it is evident that the Hepatic vein 60% strongly agree for Hematoxylin and eosin staining and 40% agree for Hematoxylin and eosin staining and 80% strongly agree for PAP stain and 20% agree for PAP Staining (Figure 12). In this bar graph it is evident that the Steatosis 60% strongly agree for Hematoxylin and eosin and 10% agree Hematoxylin and eosin and 20% disagree Hematoxylin and eosin and 10% strongly disagree for Hematoxylin and eosin. 70% strongly agree for PAP Stain, 10% agree for PAP Stain, 10% disagree for PAP Stain and 10% strongly disagree for PAP Stain (Figure 13).

Long-term intake of a high-fat diet combined with high fat induced rats results in an energy imbalance, obesity, and an increased risk of liver disorders. The primary cause of metabolic syndrome is high fat diet, which is a major risk factor for the development of HFI. The accumulated lipids induce oxidative stress, resulting in production of cytokines and reactive oxygen species which in turn activate apoptosis thereby initiating a sequence of disease events from steatosis to HFI. To evaluate the longitudinal changes in liver fat content and unsaturation,

on rodents fed with a high-fat diet. HFD is a significant source of fatty acids taken up by the liver. We identified the specific lipid species that are altered in the liver of HFD fed animals due to high fat diet and fatty liver conditions predisposed to high fat induced diet(15).

A number of studies have shown that resistance to a high-fat diet plays a significant role in the development of HFI. Unfortunately, medications that enhance insulin sensitivity have yet to show a significant impact on NAFLD. Octreotide is commonly used in clinical medicine to treat acute pancreatitis and gastrointestinal bleeding(16). In our study, high-fat diet intake causes obesity, hyperinsulinemia, hyperglycemia, hypertension, and liver damage in animals, which is identical to the phenotype seen in rats on the HFD.

A previous study found that octreotide could help rats with HFD-induced obesity lose weight and improve their metabolism and oxidative stress. A prior study in rats with diet-induced obesity corroborated the action of octreotide, including weight reduction, decreased blood glucose and insulin concentrations with enhanced insulin sensitivity(16,17). In the current study, high-fat food intake causes obesity, hyperinsulinemia, hyperglycemia, hypertension and liver damage in animals, which is comparable to the phenotype seen in rats on the HFD.

The results of the previous study showed that ipGTT (Intraperitoneal Glucose Tolerance Test ) and ipITT (Intraperitoneal Insulin Tolerance Test) further demonstrated that octreotide improves insulin sensitivity in HFD-induced obese rats (18).The effect of H&E and PAP Stain efficacy of the high fat diet induced and insulin concentrations was explored in this study, which revealed that a high fat diet increases high fat induced.

The previous study demonstrated that rats with Fat induced by intravenous ALX presented biochemical changes in blood and morphological and ultrastructural lesions in the liver that largely resembled chronic liver disease in humans (19). In the present study Liver changes ranged from the fatty degeneration of liver cells to steatohepatitis and periportal fibrosis. The present study showed mild, moderate and severe steatosis in the error bar graph association between the microvesicles and grade. More consumption of a high-carbohydrate diet and limited physical activity leads to an energy imbalance, followed by obesity and an increased risk of obesity-associated diseases. High fat diet, the critical risk factor for the development of HFI, is the primary cause of metabolic syndrome(20). In our study a high fat diet leads to an increased risk factor of rat livers and leads to liver diseases.

A previous study suggested that octreotide may reduce the weight of rats with HFD-induced obesity and improve metabolism and oxidative stress disorders. An additional previous study confirmed the function of octreotide in rats with diet-induced obesity, including weight loss, decreased blood glucose, insulin concentrations and increased insulin sensitivity(20,21). The

present study investigated the role of high fat intake in rats and obesity, revealing that overweight, altered diabetes and increased insulin sensitivity.

In our study consumption of a high-fat and high-energy diet is considered a major cause of the development of these complications. As shown in the previous study, rats that consumed a high-fat diet developed glucose intolerance, dyslipidemia and oxidative stress in the liver. Moreover, yogurt supplementation prevented the glucose intolerance and decreased plasma lipid levels in high-fat diet-fed rats (22). Yogurt supplementation also prevented oxidative stress and decreased lipid peroxidation in the plasma and liver by restoring the cellular antioxidants.

Rats that consumed a high-fat diet exhibited increased plasma glucose levels and plasma lipid levels, including cholesterol and triglyceride levels. The saturated fats present in the high-fat diet are responsible for the increase in the glucose and lipid profiles. According to previous studies, rat fed a high-fat diet display increased serum glucose concentrations. Rats fed a high-fat diet also developed glucose intolerance and were unable to properly utilize glucose to establish homeostasis after a glucose challenge.(23)

A previous study demonstrated that increased insulin-induced gluconeogenesis and decreased glycogen synthesis are the major factors underlying the development of type 2 diabetes. These studies may explain the association between GSK3 $\beta$  activity, GS mRNA expression, hepatic glycogen synthesis and plasma glucose levels in obese rats (24). The current study may explain the high fat induced diet of the rat liver and major risk factors due to obesity, overweight and altered dietary patterns. Our team has extensive knowledge and research experience that has translate into high quality publications (25).(26–39) ,(40–44) Study was limited to 5 high fat diet induced liver samples of rat further future study on diabetic rat with high fat induced insulin resistance should be included in the study. Based on the amount of food consumed, diabetic rats treated with Alogliptin received about 10–20 mg/kg rat per day.

**Table :2 Table showing the findings obtained in various other studies.**

| Author Name                 | Year | Study  | Observation  |
|-----------------------------|------|--|--|
| Shoumen Lasker et al ., (1) | 2019 | High-fat diet-induced metabolic syndrome and oxidative stress in obese rats are ameliorated by yogurt supplementation            | To determine the effects of yogurt supplementation on fat deposition, oxidative stress, inflammation and fibrosis in the liver of rats with high-fat diet-induced obesity. |
| Xiao-Xia Wang et al.,(4)    | 2017 | Effects of octreotide on hepatic glycogenesis in rats with high fat diet-induced obesity   | octreotide improved hepatic glycogenesis and decreased FPG concentration in rats with HFD-induced obesity.   |
| Jadegoud Yaligar et al.,(9) | 2014 | Evaluation of Dietary Effects on Hepatic Lipids in High Fat and Placebo Diet Fed Rats by <i>In Vivo</i> MRS and LC-MS Techniques | They demonstrated the early changes in saturated and unsaturated lipid composition in fatty liver by <i>in vivo</i> MRS and <i>ex vivo</i> LC-MS.                          |

|                                 |      |  |   |
|---------------------------------|------|--|---|
| Zuhal Altunkaynak et al.,(45)   | 2005 | Effects of high fat diet induced obesity on female rat livers - A histochemical study.                   | It was purposed to examine histological effects of fatty diet induced obesity on liver from female obese rats.  |
| Murali Krishna M.D et al., (11) | 2013 | Role of special stains in diagnostic liver pathology   | Diagnostic evaluation of liver tissue is largely based on a thorough examination of sections stained with hematoxylin and eosin (H&E).  |
| M N Berry et al.,(46)           | 2002 | High-yield preparation of isolated rat liver parenchymal cells: a biochemical and fine structural study. | The present paper describes this method and also describes the fine structure of the cells at several stages during the preparative procedures.   |
| G. GODLEWSKI,et al., (16)       | 1997 | Liver development in the rat and in man during the embryonic period (Carnegie stages 11–23)              | In rats, concerning liver development were somewhat imprecise because the embryonic period was very short and most of the descriptions were established on the observation of a few embryos |

|                          |      |   |   |
|--------------------------|------|---|---|
| Anayt Ulla, et al.,(47)  | 2017 | Supplementation of <i>Syzygium cumini</i> seed powder prevented obesity, glucose intolerance, hyperlipidemia and oxidative stress in high carbohydrate high fat diet induced obese rats | The present study, shows the ameliorative potential of <i>Syzygium cumini</i> seed powder on HFD induced glucose intolerance, dyslipidemia, oxidative stress, inflammation and fibrosis in liver. |
| Chin-Lin Hsu et al.,(48) | 2017 | Effect of gallic acid on high fat diet-induced dyslipidemia, hepatosteatosis and oxidative stress in rats   | These results demonstrate that intake of GA can be beneficial for the suppression of HFD-induced dyslipidemia, hepatosteatosis and oxidative stress in rats.                                      |

|                           |      |   |  |
|---------------------------|------|---|--|
| Panchal, S.K et al., (49) | 2012 | Ellagic acid attenuates high-carbohydrate, high-fat diet-induced metabolic syndrome in rats | This study has investigated the responses to ellagic acid, present in many fruits and nuts, in a diet-induced rat model of metabolic syndrome. |
|---------------------------|------|---|--|

### Conclusion

We demonstrated the comparative efficiency of the PAP and H&E high fat diet induced rat liver by in vivo and conclude that both H&E and PAP stain has equal efficacy and clarity in observing the various minute parameters . Further, the perinuclear lipid accumulation was more appreciable in PAP stained sections. Also we detected important histological features such as microvesicular steatosis, macrovesicular steatosis, sinusoids hepatocytes and portal vein and lipid accumulation in the nucleus. We had the chance to examine the course of liver damage closely.

## COMPETING INTERESTS DISCLAIMER:

Authors have declared that no competing interests exist. The products used for this research are commonly and predominantly use products in our area of research and country. There is absolutely no conflict of interest between the authors and producers of the products because we do not intend to use these products as an avenue for any litigation but for the advancement of knowledge. Also, the research was not funded by the producing company rather it was funded by personal efforts of the authors.

## References

1. Lasker S, Rahman MM, Parvez F, Zamila M, Miah P, Nahar K, et al. High-fat diet-induced metabolic syndrome and oxidative stress in obese rats are ameliorated by yogurt supplementation. *Sci Rep*. 2019 Dec 27;9(1):20026.
2. Lu Y-C, Sudirman S, Mao C-F, Kong Z-L. The Water Extract of *Mytilus edulis* Suppresses Oxidative Stress and Improves Male Reproduction Dysfunction in High-Fat Diet-induced Obese Rats [Internet]. Available from: <http://dx.doi.org/10.20944/preprints201806.0112.v1>
3. Watkins MT. Exercise Reverses Metabolic Syndrome in High-Fat Diet-Induced Obese Rats [Internet]. Vol. 2011, *Yearbook of Vascular Surgery*. 2011. p. 22–3. Available from: <http://dx.doi.org/10.1016/j.yvas.2011.06.032>
4. Wang X-X, Ye T, Li M, Li X, Qiang O, Tang C-W, et al. Effects of octreotide on hepatic glycogenesis in rats with high fat diet-induced obesity [Internet]. Vol. 16, *Molecular Medicine Reports*. 2017. p. 109–18. Available from: <http://dx.doi.org/10.3892/mmr.2017.6586>
5. Kumar V. Antiobesity Activity of Liraglutide on High Fat Diet-Induced Obesity in Wistar Rats [Internet]. Vol. 3, *Current Research in Diabetes & Obesity Journal*. 2017. Available from: <http://dx.doi.org/10.19080/crdoj.2017.03.555602>
6. Goseki-Sone M, Maruyama R, Sogabe N, Hosoi T. Effects of Dietary Lactose on Long-term High-fat-diet-induced Obesity in Rats\*\* [Internet]. Vol. 15, *Obesity*. 2007. p. 2605–13. Available from: <http://dx.doi.org/10.1038/oby.2007.312>
7. Camps J. *Oxidative Stress and Inflammation in Non-communicable Diseases - Molecular Mechanisms and Perspectives in Therapeutics*. Springer; 2014. 223 p.
8. Institute of Medicine, Food and Nutrition Board, Standing Committee on the Scientific Evaluation of Dietary Reference Intakes, Subcommittee on Interpretation and Uses of

Dietary Reference Intakes, Subcommittee on Upper Reference Levels of Nutrients, Panel on the Definition of Dietary Fiber, et al. Dietary Reference Intakes for Energy, Carbohydrate, Fiber, Fat, Fatty Acids, Cholesterol, Protein, and Amino Acids. National Academies Press; 2005. 1358 p.

9. Yaligar J, Gopalan V, Kiat OW, Sugii S, Shui G, Lam BD, et al. Evaluation of dietary effects on hepatic lipids in high fat and placebo diet fed rats by in vivo MRS and LC-MS techniques. *PLoS One*. 2014 Mar 17;9(3):e91436.
10. Farrell GC, George J, de la M. Hall P, McCullough AJ. *Fatty Liver Disease: NASH and Related Disorders*. John Wiley & Sons; 2008. 336 p.
11. Krishna M. Role of special stains in diagnostic liver pathology. *Clin Liver Dis*. 2013 Mar;2(Suppl 1):S8–10.
12. McGahan JP, Bishop J, Webb J, Howell L, Torok N, Lamba R, et al. Role of FNA and Core Biopsy of Primary and Metastatic Liver Disease. *Int J Hepatol*. 2013 Nov 21;2013:174103.
13. Burt AD, Ferrell LD, Hubscher SG, Portmann BC. *MacSween's Pathology of the Liver E-Book*. Elsevier Health Sciences; 2011. 820 p.
14. Vogel H. *Drug Discovery and Evaluation: Pharmacological Assays*. Springer Science & Business Media; 2007. 2068 p.
15. Berry MN, Edwards AM. *The Hepatocyte Review*. Springer Science & Business Media; 2013. 606 p.
16. Godlewski G, Gaubert-Cristol R, Rouy S, Prudhomme M. Liver development in the rat and in man during the embryonic period (Carnegie stages 11-23). *Microsc Res Tech*. 1997 Nov 15;39(4):314–27.
17. Muench MO. *Stem Cells and Progenitors in Liver Development*. Morgan & Claypool Publishers; 2012. 124 p.
18. Telkkä A, Ahlqvist J. SUCCINIC DEHYDROGENASE ACTIVITY AND SULPHYDRYL GROUPS IN CIRRHOSIS OF THE RAT LIVER INDUCED BY A LOW PROTEIN/HIGH FAT DIET [Internet]. Vol. 46, *Acta Pathologica Microbiologica Scandinavica*. 2009. p. 1–10. Available from: <http://dx.doi.org/10.1111/j.1699-0463.1959.tb00309.x>
19. Muriel P. High fat diet and liver damage induced by biliary obstruction in the rat [Internet]. Vol. 15, *Journal of Applied Toxicology*. 1995. p. 125–8. Available from: <http://dx.doi.org/10.1002/jat.2550150211>

20. Alghamdi S. Magnetic resonance characterisation of developing hepatocellular carcinoma in a diet induced model of liver cancer in the rat [Internet]. Available from: <http://dx.doi.org/10.14264/uql.2017.729>
21. Welles J. A Comprehensive Overview of the Effects of Diet on the Hepatic Transcriptome and Translatome in Rat Liver. 2021.
22. Rees AL. Review: Film Art Phenomena \* Review: The Undercut Reader: Critical Writings on Artists' Film and Video \* Review: Experimental Cinema: the Film Reader (In Focus: Routledge Film Readers Series) [Internet]. Vol. 45, Screen. 2004. p. 440–6. Available from: <http://dx.doi.org/10.1093/screen/45.4.440>
23. Misiakiewicz-Has K, Maciejewska-Markiewicz D, Rzeszotek S, Pilutin A, Kolasa A, Szumilas P, et al. The Obscure Effect of Saponins Plus Inulin on Liver Morphology, Liver Fatty Acids, Plasma Glucose, and Lipid Profile in SD Rats with and without Induced Type 2 Diabetes Mellitus. *Int J Mol Sci* [Internet]. 2021 Aug 12;22(16). Available from: <http://dx.doi.org/10.3390/ijms22168680>
24. Hsu C-L, Yen G-C. Effect of gallic acid on high fat diet-induced dyslipidaemia, hepatosteatosis and oxidative stress in rats. *Br J Nutr*. 2007 Oct;98(4):727–35.
25. Anita R, Paramasivam A, Priyadharsini JV, Chitra S. The m6A readers YTHDF1 and YTHDF3 aberrations associated with metastasis and predict poor prognosis in breast cancer patients. *Am J Cancer Res*. 2020 Aug 1;10(8):2546–54.
26. Jayaseelan VP, Paramasivam A. Emerging role of NET inhibitors in cardiovascular diseases. *Hypertens Res*. 2020 Dec;43(12):1459–61.
27. Sivakumar S, Smiline Girija AS, Vijayashree Priyadharsini J. Evaluation of the inhibitory effect of caffeic acid and gallic acid on tetR and tetM efflux pumps mediating tetracycline resistance in *Streptococcus* sp., using computational approach. *Journal of King Saud University - Science*. 2020 Jan 1;32(1):904–9.
28. Smiline Girija AS. Delineating the Immuno-Dominant Antigenic Vaccine Peptides Against gacS-Sensor Kinase in *Acinetobacter baumannii*: An in silico Investigational Approach. *Front Microbiol*. 2020 Sep 8;11:2078.
29. Iswarya Jaisankar A, Smiline Girija AS, Gunasekaran S, Vijayashree Priyadharsini J. Molecular characterisation of csgA gene among ESBL strains of *A. baumannii* and targeting with essential oil compounds from *Azadirachta indica*. *Journal of King Saud University - Science*. 2020 Dec 1;32(8):3380–7.
30. Girija ASS. Fox3+ CD25+ CD4+ T-regulatory cells may transform the nCoV's final destiny

to CNS! J Med Virol [Internet]. 2020 Sep 3; Available from:  
<http://dx.doi.org/10.1002/jmv.26482>

31. Jayaseelan VP, Ramesh A, Arumugam P. Breast cancer and DDT: putative interactions, associated gene alterations, and molecular pathways. *Environ Sci Pollut Res Int*. 2021 Jun;28(21):27162–73.
32. Arumugam P, George R, Jayaseelan VP. Aberrations of m6A regulators are associated with tumorigenesis and metastasis in head and neck squamous cell carcinoma. *Arch Oral Biol*. 2021 Feb;122:105030.
33. Kumar SP, Girija ASS, Priyadharsini JV. Targeting NM23-H1-mediated inhibition of tumour metastasis in viral hepatitis with bioactive compounds from *Ganoderma lucidum*: A computational study. *pharmaceutical-sciences* [Internet]. 2020;82(2). Available from: <https://www.ijpsonline.com/articles/targeting-nm23h1-mediated-inhibition-of-tumour-metastasis-in-viral-hepatitis-with-bioactive-compounds-from-ganoderma-lucidum-a-comp-3883.html>
34. Girija SA, Priyadharsini JV, Paramasivam A. Prevalence of carbapenem-hydrolyzing OXA-type  $\beta$ -lactamases among *Acinetobacter baumannii* in patients with severe urinary tract infection. *Acta Microbiol Immunol Hung*. 2019 Dec 9;67(1):49–55.
35. Priyadharsini JV, Paramasivam A. RNA editors: key regulators of viral response in cancer patients. *Epigenomics*. 2021 Feb;13(3):165–7.
36. Mathivadani V, Smiline AS, Priyadharsini JV. Targeting Epstein-Barr virus nuclear antigen 1 (EBNA-1) with *Murraya koenigii* bio-compounds: An in-silico approach. *Acta Virol*. 2020;64(1):93–9.
37. Girija As S, Priyadharsini J V, A P. Prevalence of Acb and non-Acb complex in elderly population with urinary tract infection (UTI). *Acta Clin Belg*. 2021 Apr;76(2):106–12.
38. Anchana SR, Girija SAS, Gunasekaran S, Priyadharsini VJ. Detection of *csgA* gene in carbapenem-resistant *Acinetobacter baumannii* strains and targeting with *Ocimum sanctum* biocompounds. *Iran J Basic Med Sci*. 2021 May;24(5):690–8.
39. Girija ASS, Shoba G, Priyadharsini JV. Accessing the T-Cell and B-Cell Immuno-Dominant Peptides from *A.baumannii* Biofilm Associated Protein (bap) as Vaccine Candidates: A Computational Approach. *Int J Pept Res Ther*. 2021 Mar 1;27(1):37–45.
40. Arvind P TR, Jain RK. Skeletally anchored forsus fatigue resistant device for correction of Class II malocclusions-A systematic review and meta-analysis. *Orthod Craniofac Res*. 2021 Feb;24(1):52–61.

41. Venugopal A, Vaid N, Bowman SJ. Outstanding, yet redundant? After all, you may be another Choluteca Bridge! *Semin Orthod*. 2021 Mar 1;27(1):53–6.
42. Ramadurai N, Gurunathan D, Samuel AV, Subramanian E, Rodrigues SJL. Effectiveness of 2% Articaine as an anesthetic agent in children: randomized controlled trial. *Clin Oral Investig*. 2019 Sep;23(9):3543–50.
43. Varghese SS, Ramesh A, Veeraiyan DN. Blended Module-Based Teaching in Biostatistics and Research Methodology: A Retrospective Study with Postgraduate Dental Students. *J Dent Educ*. 2019 Apr;83(4):445–50.
44. Mathew MG, Samuel SR, Soni AJ, Roopa KB. Evaluation of adhesion of *Streptococcus mutans*, plaque accumulation on zirconia and stainless steel crowns, and surrounding gingival inflammation in primary molars: randomized controlled trial [Internet]. Vol. 24, *Clinical Oral Investigations*. 2020. p. 3275–80. Available from: <http://dx.doi.org/10.1007/s00784-020-03204-9>
45. Altunkaynak Z. EFFECTS OF HIGH FAT DIET INDUCED OBESITY ON FEMALE RAT LIVERS (A HISTOCHEMICAL STUDY) [Internet]. Vol. 2, *Electronic Journal of General Medicine*. 2005. Available from: <http://dx.doi.org/10.29333/ejgm/82319>
46. Berry MN, Friend DS. High-yield preparation of isolated rat liver parenchymal cells: a biochemical and fine structural study. *J Cell Biol*. 1969 Dec;43(3):506–20.
47. Ulla A, Alam MA, Sikder B, Sumi FA, Rahman MM, Habib ZF, et al. Supplementation of *Syzygium cumini* seed powder prevented obesity, glucose intolerance, hyperlipidemia and oxidative stress in high carbohydrate high fat diet induced obese rats. *BMC Complement Altern Med*. 2017 Jun 2;17(1):289.
48. Marti A, Aguilera CM. *Obesity: Oxidative Stress and Dietary Antioxidants*. Academic Press; 2018. 304 p.
49. Panchal SK, Ward L, Brown L. Ellagic acid attenuates high-carbohydrate, high-fat diet-induced metabolic syndrome in rats. *Eur J Nutr*. 2013 Mar;52(2):559–68.