

A RARE CASE OF SQUAMOUS CELL CARCINOMA PRESENTED WITH MULTIPLE DISCHARGING SINUS OVER THE POSTERIOR ASPECT OF LEFT THIGH

ABSTRACT

Squamous cell carcinoma are the second most common, among the cutaneous malignancy, and chronic exposure to the ultraviolet rays is the most important etiological factor and hence the exposed areas of the body are the most common site of squamous cell carcinoma. It is very uncommon for SCC to occur at unexposed areas of the body, and it is usually associated with long standing ulcers, sinus or immunosuppression. Here we are reporting a rare of Squamous Cell carcinoma which developed from multiple discharging sinus over the posterior aspect of left thigh in a 67 year old male.

Keywords: Squamous cell carcinoma, Wide local excision, flap cover, bilateral inguinal nodes dissection

INTRODUCTION

Squamous cell carcinoma accounts for most non- melanoma skin malignancy related metastatic diseases. It is the second most common cutaneous malignancy, first being the basal cell carcinoma; And it's incidence is increasing worldwide [1]. There are many etiology which can increase the risk of squamous cell carcinoma among which chronic sun exposure is of the utmost importance. Hence, it is more common in individuals who are fair and also on the parts of body which are exposed to sunlight. Squamous cell carcinoma also arises within burns, scars, individual who has had history of chronic ulcers or sinus tract as well as from pre existing lesions like Bowen's disease or immune compromised individuals. In an immunocompetent individual, squamous cell carcinoma occurring on intact skin is a very rare entity. Squamous cell carcinoma from multiple discharging sinus from paranasal sinuses has been reported earlier but SCC arising from

multiple discharging sinus over posterior aspect of left thigh has not been reported.

CASE PRESENTATION

A 67 year old male, presented with multiple discharging sinus over the posterior aspect of left thigh since one and half years; for which conservative antibiotics treatment was taken. Patient then presented to us with ulceroproliferative skin lesion from the sinus over posterior aspect of left thigh for 6 months duration. Prior history of long standing ulcer over the affected area was present. On examination, he had multiple discharging sinus over the posterior aspect of left thigh with cauliflower shaped ulcers largest measuring 4x3 cms having everted edges. He also had multiple, hard palpable nodes in bilateral inguinal region, largest of 2 x 1cm size. Final histopathological examination confirmed the primary tumour as level 4, grade 1 squamous cell carcinoma. All the resection margins were free of tumour, lymphovascular invasion not identified, perineural invasion not identified. On investigations, patient was diagnosed with Squamous cell carcinoma of the posterior aspect of left thigh. And was planned for wide local excision with flap cover with bilateral inguinal lymph nodes dissection.

CASE REPORT

A 67 year old male, known diabetic, hypertensive and CAD, known smoker, presented with multiple discharging sinus over the posterior aspect of left thigh since one and half years; for which conservative antibiotics treatment was taken. Patient then presented to us with ulceroproliferative skin lesion from the sinus over posterior aspect of left thigh for 6 months duration; associated with pain. History of pus discharge present from the ulcer. No other significant history.

Prior history of long standing ulcer over the affected area.

Patient had no history of recent onset of fever, significant weight loss, anorexia, bone pain, recent jaundice, cough with expectoration.

No history of any malignancy in the family.

On examination, patient was conscious, oriented to time

place and person. Vitals stable.

No pallor/ icterus/ generalised lymphadenopathy/ clubbing/ pedal Oedema.

Local Examination:

Left thigh: Multiple discharging sinus present with pus discharge, multiple cauliflower shaped ulcers largest measuring 4*3 cms present over the posterior upper aspect of left thigh, hard in consistency, irregular borders, nodular surface, with active pus discharge. He also had multiple, hard palpable nodes in bilateral inguinal region, largest of 2 x 1cm size.

MRI Left thigh showed an invasive lesion in left gluteal region involving cutaneous, subcutaneous fat and underlying muscle layer with regional lymphadenopathy. PET CT was done which showed Heterogeneous enhancing exophytic soft tissue growth arising from posteroinferior aspect of left gluteal region and nodes involving left external iliac and bilateral inguinal regions.

As patient had infiltration in the underlying gluteal maximum muscle, three dimensional clearance was given, specimen was sent for frozen biopsy and it was reported as all margins were free of tumour with deep marginal clearance. Left ilioinguinal block dissection and right superficial inguinal lymph node dissection was performed. Then patient in prone position, pedicle rotation island flap cover was done. Donor flap site was covered with skin graft. Intra and post-operative period was uneventful. Patient was advised Radiotherapy for tumour bed after oncologist consultation.

Final histopathological examination confirmed the primary tumour as level 4, grade 1 squamous cell carcinoma. All the resection margins were free of tumour, lymphovascular invasion not identified, perineural invasion not identified.

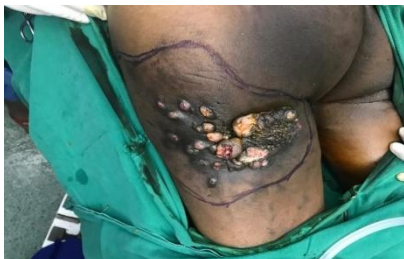

Fig.1- pre op image showing multiple discharging sinus with ulceration.

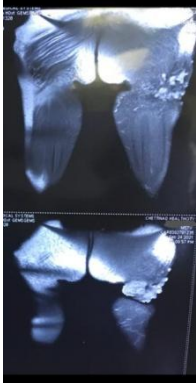


Fig.2- MRI image of left thigh showing invasive lesion in gluteal region involving cutaneous, subcutaneous fat and underlying muscle layer.

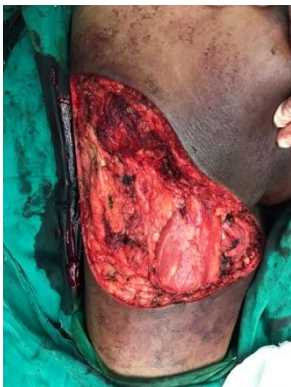

Fig. 3- Intra operative image showing the tumour bed.

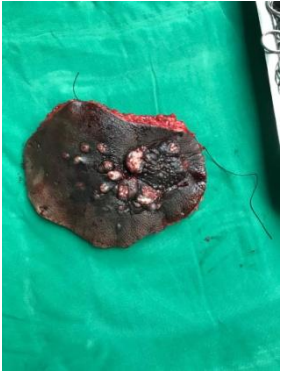

Fig. 4- specimen image.
cover.

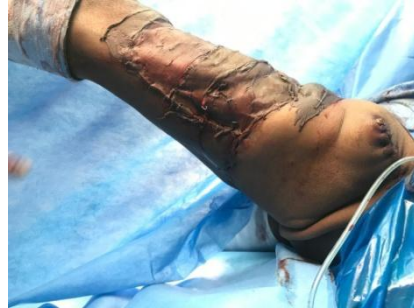

Fig. 5- postoperative image showing the flap

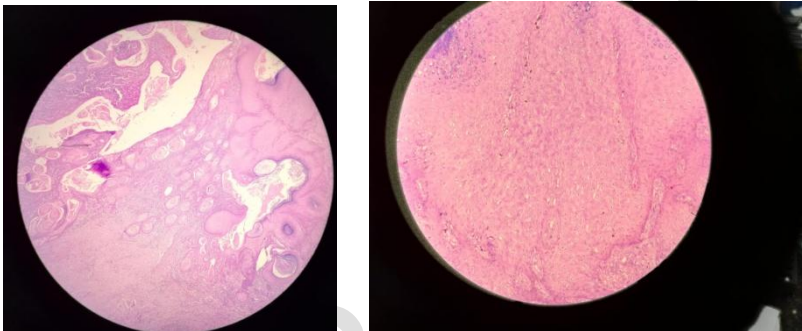


Fig. 6- a and b- microscopic images.

DISCUSSION

Primary SCC being a malignant tumour; arises from keratinising cells of the epidermis. As It is the 2nd most commonly occurring skin malignancy, it accounts for approximately 20 to 25% of cutaneous cancer deaths annually worldwide [1]. The most important risk factor for these malignancies is chronic exposure to the ultraviolet rays. Thereby, people with fair skin, with genetic disorders (albinism and Xeroderma pigmentosum) are particularly at slightly higher risk for developing SCC [2]. In rare occasions, SCC can also arise at areas with long standing ulcers, sinuses, burns or scars [3]. Bowen's disease is considered to be a precursor for the development of SCC. Individuals with impaired immunity as well as those on chronic immunosuppressive drugs at particularly high risk for the development of SCC [4]. SCC usually will present as a non-healing ulcer with indurated, nodular, cauliflower shape, keratinising tumour. It will typically spread to the regional lymph nodes first prior to the development of distant metastases.

Diagnosis is mostly done by an incisional biopsy. Metastatic work up is done which includes Ultrasound examination of the regional nodal basin and chest radiograph to rule out metastasis to lungs. Surgical excision remains the mainstay of treatment for SCC with Tumour free margin of 4-mm is considered appropriate for clinically well-defined, low risk tumours less than 2 cm in diameter. A wider margin that is 6 mm or more is considered for tumours more than 2 cm in diameter, tumours with moderately, poorly differentiated histology and tumours extending into the subcutaneous tissue [5]. Adjuvant radiotherapy is indicated when there is presence of extensive perineural invasion or where margins are not free of tumour cells or when regional nodes show metastatic deposits [6]. Majority of the recurrences develop within first 2 years. Hence it is reasonable to follow up these patients for at-least 2 years and ideally upto 5 years. In our case report, we have 67 year old male, with multiple discharging sinus and ulcer over the posterior aspect of left thigh with regional lymph nodes involvement. Squamous cell carcinoma developing over this site is not reported in literature till now.

REFERENCES

1. Thompson AK, Kelley BF, Prokop LJ, Murad MH, Baum CL (2016) Risk Factors for Cutaneous Squamous Cell Carcinoma Recurrence, Metastasis, and Disease-Specific Death: A Systematic Review and Meta-analysis. *JAMA Dermatol*.
2. Karagas MR, Stannard VA, Mott LA, Slattery MJ, Spencer SK, et al. (2002) Use of tanning devices and risk of basal cell and squamous cell skin cancers. *J Natl Cancer Inst* 94: 224-226.
3. Baldursson B, Sigurgeirsson B, Lindelöf B (1993) Leg ulcers and squamous cell carcinoma. An epidemiological study and a review of the literature. *Acta Derm Venereol* 73: 171-174.
4. Moloney FJ, Comber H, O'Lorcain P, O'Kelly P, Conlon PJ, et al. (2006) A population-based study of skin cancer incidence and prevalence in renal transplant recipients. *Br J Dermatol* 154: 498-504.
5. Brodland DG, Zitelli JA (1992) Surgical margins for excision of primary cutaneous squamous cell carcinoma. *J Am Acad Dermatol* 27: 241-248.
6. Mendenhall WM, Amdur RJ, Hinerman RW, Cognetta AB, Mendenhall NP (2009) Radiotherapy for cutaneous squamous and basal cell carcinomas of the head and neck. *Laryngoscope* 119: 1994-1999.