

A REPORT OF TWO RARE CASES OF PALATAL TREMORS

Abstract

Palatal tremor, also known as palatal myoclonus is a rare neurological phenomenon, hypothesized to occur either due to a lesion in the inferior olivary nucleus, or in an idiopathic manner. Here we present two cases of palatal tremor, who presented to our tertiary care centre for unrelated symptoms. The first case was a 56 year old gentleman, who was incidentally found to have palatal tremor. Further investigation revealed a posterior circulation stroke involving the left cerebellar hemisphere and cerebellar peduncle. The second case, a 35 year old female, presented with an upper respiratory tract infection, and was discovered to have palatal tremor on routine examination. The cause was attributed to her history of surgical removal of a left cerebellar cyst five years ago.

Keywords: *Palatal tremor; olivary nucleus; cerebellar cyst.*

Introduction

Palatal tremor is a very rare neurological disorder characterized by regular, rhythmic contraction of the soft palate, which may be accompanied by myoclonus or tremor in other muscles including those in the face, tongue, and throat. According to etiologic factors, palatal tremor has been classified as two distinct forms: symptomatic palatal tremor that is secondary to identifiable brainstem or cerebellar disease, and essential palatal tremor, which presents in the absence of a brain lesion¹. Cases of isolated palatal tremor are uncommon. Although rare, it is well established that the anatomic structures involved in the pathogenesis of PM are almost always in the inferior olivary nucleus².

Case presentation

Case 1

A 56 year old male presented with sudden onset breathlessness for a period of 3 days, which was aggravated by activity, and relieved by rest without orthopnea, paroxysmal nocturnal dyspnea or wheeze. The past medical history was unremarkable except for diabetes and hypertension, for which the patient was not on regular medication. The patient was a chronic smoker, with a smoking history of 20 pack years, but had stopped smoking four years ago. The review of systems was otherwise unremarkable.

On examination, the patient was found to be anemic, with clubbing. The pulse rate was 78/min, with an elevated blood pressure of 170/100 mm Hg. The rest of the vital parameters were normal. The neurological examination incidentally revealed a palatal tremor, with no other apparent neurological deficit. There were no signs of cerebellar dysfunction. The examination of other systems revealed no clinical abnormality.

The complete blood count revealed hemoglobin of 8 g/dl, with a normal leucocyte and platelet count. The evaluation of renal function revealed an elevated creatinine level of 4.11mg/dL and BUN of 15mg/dL. The fasting and postprandial sugars were 149mg/dL and 249mg/dL respectively. The urine examination revealed albuminuria, sugar in the urine along with a few pus cells. The serum electrolytes showed sodium of 137, potassium of 3.5 and calcium of 7.0 mg/dL. The liver function tests, lipid profile, thyroid function tests were normal.

In view of the finding of palatal tremor, MRI brain was performed. It showed encephalomalacic changes in the right medial temporal, occipital lobe, left cerebellum and inferior cerebellar peduncle with focal flair hyper intensity in left cerebellum, suggestive of Wallerian degeneration. It also revealed

multiple lacunar infarcts in the bilateral ganglio-capsular regions and the centrum semi ovale. There was also evidence of small vessel ischemic changes with cortical atrophy. An ultrasound abdomen was performed which showed increased cortical echoes in both the kidneys. The carotid and vertebral doppler study was normal.

The echocardiogram was suggestive of left ventricular hypertrophy, with a normal ejection fraction. The examination of the ophthalmic fundus revealed moderate non proliferative diabetic retinopathy and grade II hypertensive retinopathy. With the above clinical, laboratory and radiological findings, the patient was diagnosed to have diabetes mellitus, systemic hypertension, cerebrovascular accident, diabetic kidney disease with anemia of chronic disease.

The patient was managed conservatively with fluid restriction, insulin, amlodipine, and erythropoietin. In view of the ischemic changes, aspirin and atorvastatin were added. The patient was discharged with improvement in dyspnea.

After 3 months follow up, patient had persistent palatal tremor without other neurological deficits. His renal function tests were stable over a period of three months.

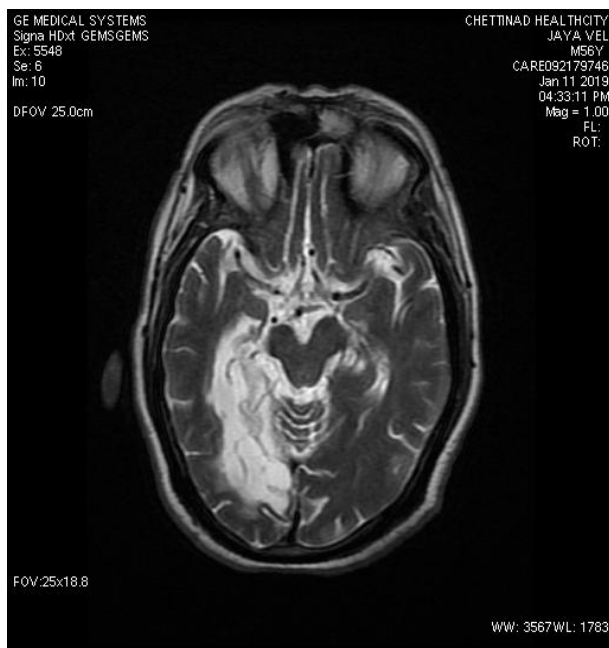

Fig 1: MRI image showing encephalomalacic changes in right medial temporal, occipital lobe, left cerebellum and inferior cerebellar peduncle with focal flair hyper intensity in left cerebellum.

Case 2

A 35 year old lady presented to the general medicine outpatient department with symptoms suggestive of an upper respiratory tract infection. She also mentioned that she often hears a clicking sound in her head that worsens during silence. The patient had a prolific medical history, involving an intracranial surgery five years ago. She had presented to a tertiary care hospital in 2015 with the complaints of severe occipital headache for duration of a month, associated with giddiness and recurrent vomiting. On examination at the time, the patient was found to have a right sided upper motor neuron type of facial palsy. The neurological examination was otherwise normal. The review of other systems revealed no abnormality.

A CT scan of the brain revealed a hypodense lesion in the left cerebellar hemisphere causing mass effect on the adjacent brain parenchyma. This was followed up with a Gadolinium contrast MRI scan, which revealed a well- defined cystic lesion with thin septations and enhancing mural nodule in the left cerebellar hemisphere, causing obstructive hydrocephalus.


The patient was further taken up for surgery and underwent a sub occipital craniotomy with excision of the cystic wall and aspiration of the cystic fluid. The aspirate from the cyst was sent for pathological and microbiological examination, which showed evidence of cerebellar mucormycosis. Post surgery, the patient developed right sided ptosis, with bilateral lateral rectus palsy. This neurological deficit gradually improved over the course of hospitalization. The patient was discharged after 26 days of admission with a prescription of antiepileptics and labyrinthine sedatives.

On presentation to our OPD, the patient had no residual neurological deficit, except for the palatal tremor. The incidentally found PM in this case was attributed to the surgical trauma resulting in injury to the inferior olivary nucleus. As this symptom was not bothersome to the patient, she was not treated for the same. The patient was further lost to follow up.

Discussion

Palatal tremor is a very rare neurological disorder characterized by regular, rhythmic contraction of the palatal soft palate, which may be accompanied by myoclonus or tremors in other muscles including those in the face, tongue, and throat. It is often found incidentally after patients present with a persistent clicking sound in both ears, which are worse during silence. It is often picked up by clinicians by auscultating a click over the mastoid bone. According to etiologic factors, palatal tremor has been classified as two distinct forms: symptomatic palatal myoclonus (SPM), which is a condition that is secondary to identifiable brainstem or cerebellar disease and essential palatal myoclonus (EPM) which presents in the absence of a brain lesion. The most frequent etiology of structural brainstem or cerebellar lesion is vascular and more often hemorrhagic than ischemic³. The other lesions associated with secondary PM are trauma, tumors and demyelinating diseases.

SPM is the more common variant, which predominantly involves the levator veli palatini muscle, whereas EPM predominantly involves the tensor veli palatini muscle. SPM often points towards a medullary lesion, whereas EPM usually does not usually reveal a brain lesion. Patients with symptomatic palatal myoclonus have been shown to have pathological hypertrophic degeneration of the inferior olive and dentate nucleus, which acts as a pacemaker to initiate rhythmic, spontaneous, synchronized discharges within the inferior olive, that results in this clinical finding. In addition, small scale studies have shown that SPM has a partial response to sumatriptan, whereas EPM responds well to clonazepam. Hence, it is suggested to start all patients with PM on a trial of sumatriptan, to differentiate between EPM and SPM⁴.



- May respond to Clonazepam, Carbamazepine, anticholinergics & Sumatriptan (only essential)
- Botulinum toxin injection in selected muscles for ear click relief

Fig 2: Differences between essential and symptomatic palatal myoclonus

Conclusion

Palatal tremor or myoclonus is an uncommon disorder, which can be easily overlooked in the absence of other neurological deficit. Hence, ardent medical examination is warranted for early diagnosis and management of the underlying neurological lesion. Pharmacotherapy may be initiated with benzodiazepenes, barbiturates, 5-hydroxytryptophan or anticonvulsants. Botulinum toxin has also shown efficacy in the treatment of essential palatal myoclonus⁵.

References

1. G Deuschl, C Toro Symptomatic and essential palatal tremor, Clinical, physiological and MRI analysis, Brain, 1994 Aug;117 (Pt 4):775-88.
2. Shakya Bhattacharjee Palatal Tremor – Pathophysiology, Clinical Features, Investigations, Management and Future Challenges, Tremor Other Hyperkinet Mov (N Y). 2020; 10: 40
3. Giorgio Fabian, Helio A.G. Palatal myoclonus report of two cases Arq. Neuro-Psiquiatr. vol.58 n.3B São Paulo Sept. 2000
4. Scott BL, Evans RW, Jankovic J. Treatment of palatal myoclonus with sumatriptan. Movement Disorders : Official Journal of the Movement Disorder Society. 1996 Nov;11(6):748-751
5. Anthony E. Lang, Treatment of Palatal Tremor, Therapy of Movement Disorders, 10.1007/978-3-319-97897-0_41, (179-183), (2019).

UNDER PEER REVIEW