

# INCIDENCE OF ABERRANT RIGHT SUBCLAVIAN ARTERY IN GENERAL POPULATION

## ABSTRACT:

**OBJECTIVE:**The existence of an anomalous right subclavian artery is the most significant aortic arch defect. Dysphagia, wheezing, stridor, and other symptoms may occur if this vessel pressures the neighbouring structures. The goal of this study is to find out how common ARSA is based on CT scans of the thorax and neck (plain and contrast).

**METHOD:**Between January 1st and December 31st, 2020, 1122 patients had CT Thorax/neck scans, and the data were evaluated. The origin of the ARSA, the vessel's path, and the Kommerell diverticulum were all assessed. We looked at the literature to see how important ARSA is in clinical practise.

**RESULTS:**ARSA was found in eight of 1122 patients. All of the ARSAs in these eight individuals began at the posterior part of the aortic arch and travelled via the retroesophageal path to the thoracic outlet. All eight ARSA were found in the front part of the thoracic vertebral bodies, from the first to the fourth.

**CONCLUSION:**Other clinical symptoms such as dysphagia, dyspnea, retrosternal discomfort, cough, and weight loss must be differentiated from compression of surrounding tissues by an abnormal right subclavian artery.

**KEY WORDS:** Right aberrant subclavian artery, dysphagia, CT Thorax/neck.

## INTRODUCTION:

A uncommon anatomical variation of the right subclavian artery's origin is the aberrant right subclavian artery (ARSA). ARSAs generally begin from the aorta's posterior side and go down the oesophagus to the right thoracic outlet. The brachiocephalic trunk (split into the right common carotid and the right subclavian artery); the left common carotid artery; and the left subclavian artery are the three major arteries that originate from the arch of the aorta. The brachiocephalic trunk is missing and four big arteries emerge from the arch of the aorta when an aberrant right subclavian artery variation is present ; the right common carotid artery , the left common carotid artery ,the left subclavian and the right subclavian artery also called as arteria lusoria.

ARSA has been found to have a prevalence of 0.16 percent to 2%. In postmortem investigations, anatomical differences of the aortic arch and major vessels have been widely described. The goal of this study was to investigate the prevalence and course of ARSA in a single institution in Chennai using computed tomography (CT) thorax.

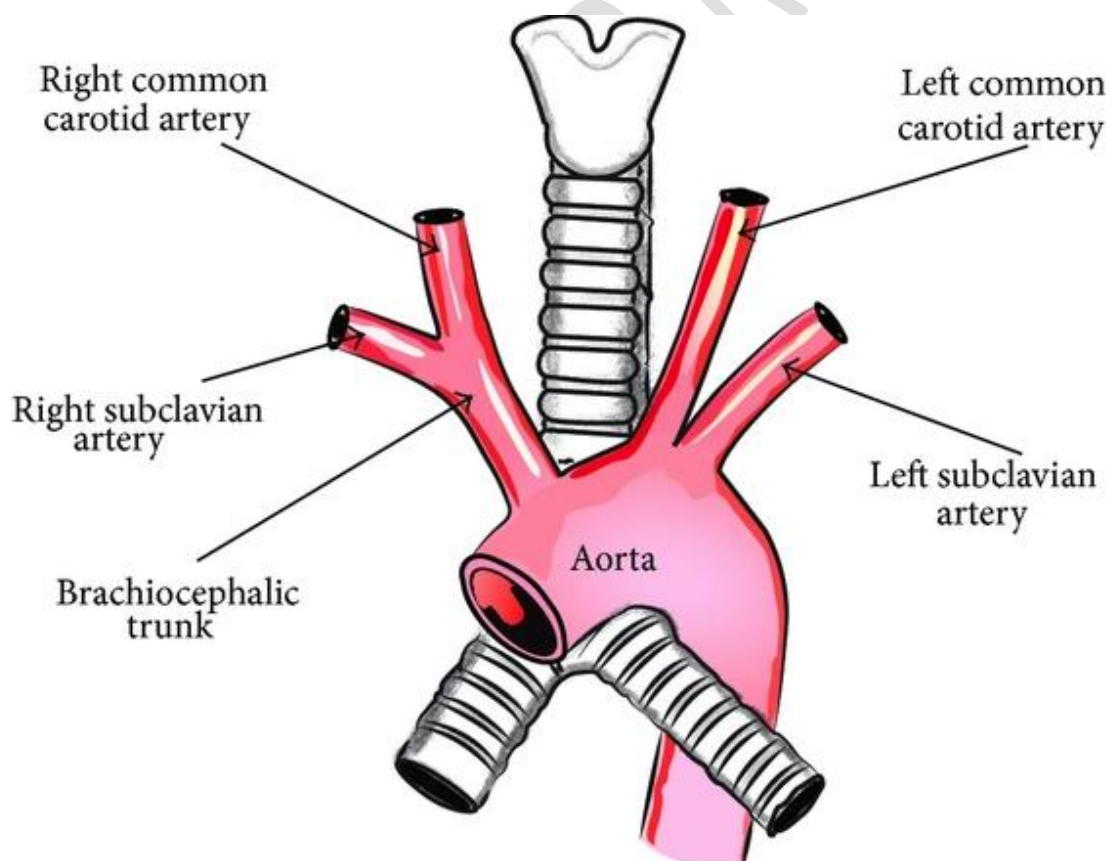
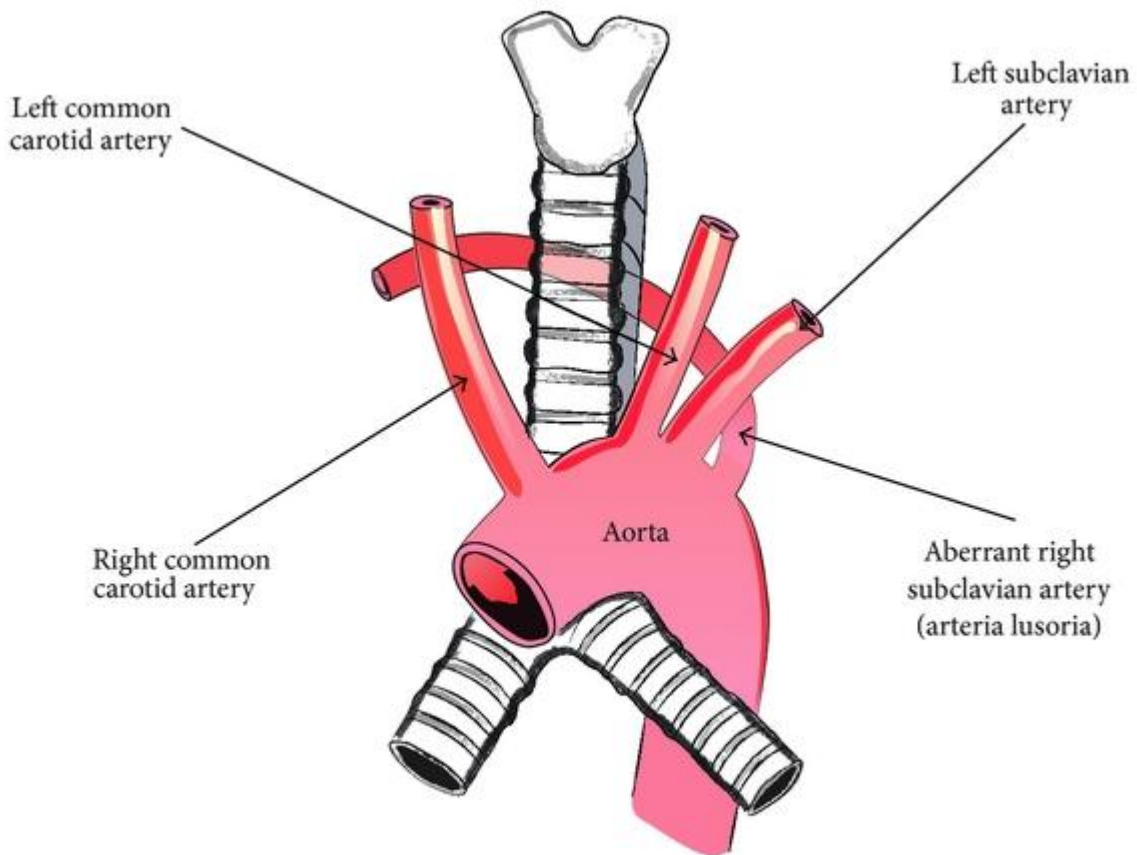


FIGURE1: Schematic representation of the normal anatomy of arch of aorta.



**FIGURE 2: Schematic representation of the presence of ARSA**

#### **MATERIALS AND METHODS:**

The retrospective study received approval and authorization from the Institutional Ethics Committee. The presence of ARSA was determined using CT Thorax/neck images. Between January 1st and December 31st, 2020, 1122 patients had CT Thorax/neck scans, and the data were evaluated.

The CT scans were done for a variety of causes, including symptoms of cerebral ischemia, hemorrhagic contusion, intracerebral haemorrhage, headache, dizziness, sensory changes, and a regular checkup.

CT scans conducted on non-Indian patients or acquired outside of hospitals were excluded. Patients under the age of 18 were not allowed to participate.

Between January 1st and December 31st, 2020, 1122 patients (male - 808, female - 314) had CT Thorax/neck scans, and the data were analysed.

In 1122 patients, a Philips Ingenuity 128-slice CT scanner (Philips Medical Systems, Tokyo, Japan) was used. The CT angiographic acquisition settings were 120 kVp, 225 mA, 220 mm field of view, 64 x 0.6 mm detector collimation, table speed 25.5 mm/rotation, gantry rotation speed 0.75 s/rotation, reconstructed section thickness 1 mm, and reconstruction increment 0.5 mm. The scan ranged from

2 centimetres below the aortic arch to 1 centimetres above the lateral ventricles. The following methods were used to analyse the CT angiography results. A total of 100 mL of Iohexol (Omnipaque 350; GE Pharmaceuticals, Seoul, Korea) was given intravenously through an 18-gauge catheter positioned in a peripheral vein using a power injector at 5.0 mL/s, with the scan delay modified individually using a bolus-tracking approach. First, a single nonenhanced low-dose scan at the level of the upper neck was acquired for bolus tracking. Low-dose monitoring scans were taken every second starting with the introduction of contrast material. The CT angiography was automatically started when the contrast medium was first visible in the arch of the aorta. The pictures were reconstructed in three dimensions (3D) using commercially available software once the data was uploaded to a computer (Intelli space portal version 8.0). A volume-rendering approach was used to recreate 3D CT images from this data.

The origin of the ARSA, the vessel's path, and the Kommerell diverticulum were all assessed. The base of the subclavian artery expanding to >1.5 times the size of the distal subclavian artery was characterised as a Kommerell diverticulum in ARSA.

### RESULTS:

ARSA was found in eight of 1122 patients. ARSAs started from the posterior part of the aortic arch and travelled through the retroesophageal path to the right side in 8 individuals (8/1122=0.71 percent, 4 female, 4 male; age range 36-75 years).

### DISCUSSION:

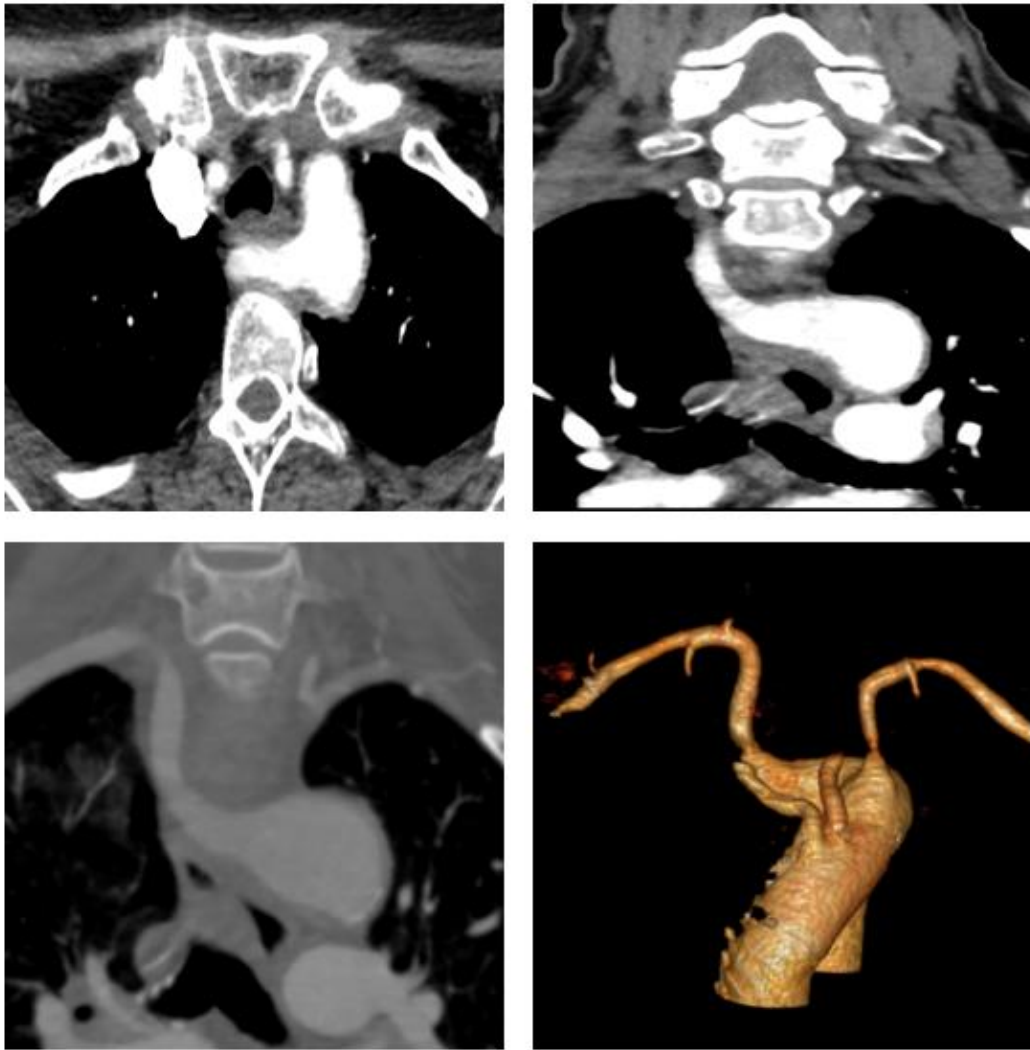The aortic arches first form in the fourth week of embryogenesis. There are normally six pairs of aortic arches. The right subclavian artery develops with the most caudal component of the right dorsal aorta forming the proximal portion and the 7th right intersegmental artery forming the distal portion. The creation of an ARSA is caused by any departure from the normal embryologic developing pattern of the primitive aortas and aortic arches. The 7th intersegmental artery stays connected to the descending aorta, whereas the 4th vascular arch involutes alongside the right dorsal aorta. As a result, the persisting intersegmental artery is transformed into an abnormal right

NUMBER	AGE	SEX	ARSA ORIGIN	VERTEBRAL BODY LEVEL	KOMMERELL DIVERTICULUM	ORIGIN OF BOTH CCA
1	63	F	Postero-inferior	T2 – T3	negative	separate
2	60	M	Postero-superior	T3 – T4	negative	Common stem
3	42	M	Postero-superior	T3 – T4	negative	separate
4	65	F	Postero-superior	T3 – T4	negative	separate
5	75	F	Postero-superior	T2 – T4	negative	separate
6	36	F	Postero-inferior	T2 – T3	negative	separate
7	60	M	Postero-superior	T3 – T4	negative	separate
8	56	M	Postero-superior	T3 – T4	negative	separate

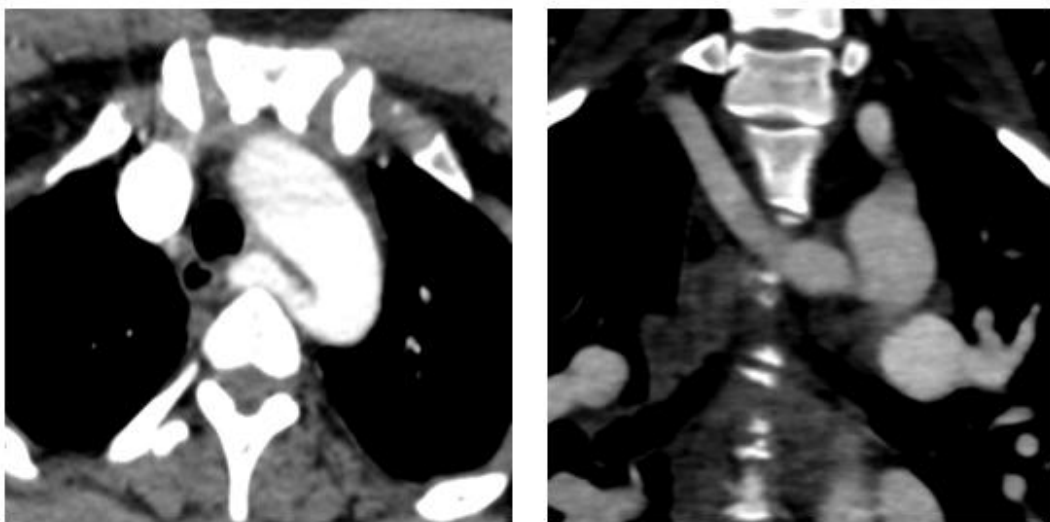
Table 1. Demographic data profile

subclavian artery.

The origin of the ARSA lies only distal to the usual left subclavian artery when the left distal aortic root is shortened. The artery has a wide base in most cases, which is known as a Kommerell diverticulum. Because the root of ARSA is created by the persistent right aortic arch, this is the case. The stem of the aberrant subclavian artery is derived from a portion of the right dorsal aorta, which explains why ARSA frequently travels retroesophageally.



**Fig3: A 65 year old woman with aberrant right subclavian artery with a postero – superior origin showing ARSA located anterior to the thoracic vertebra and posterior to oesophagus.**



**Fig4: A 36 year old woman with aberrant right subclavian artery with a postero – inferior origin showing ARSA located anterior to the thoracic vertebra and posterior to oesophagus.**

One out of every eight ARSA patients had a common stem for both CCAs. The bovine arch is comparable to this variant. The common origin of the left CCA and innominate artery is represented by the bovine arch. The union of the left CCA and innominate artery occurs as a result of delayed development of the ventral aortic roots between the 3rd and 4th aortic arches.

ARSA has been found to have a prevalence of 0.16 percent to 2% in previous research; the current study's rate was 0.71 percent (8 out of 1122). ARSA starts on the left side of the body and travels to the right arm; it crosses the midline posterior to the oesophagus in the majority of cases (85%), and is hence referred to as retroesophageal ARSA. The majority of patients are symptom-free for the rest of their lives.

Coughing, dysphagia, thoracic discomfort, and Horner syndrome are all things that might happen as you become older. Dysphagia in elderly people can occur for a variety of reasons. Several methods have been proposed: 1) extension of the aorta; 2) aneurysm development, especially in the presence of a Kommerell diverticulum; and 3) increased stiffness of the vessel wall or the oesophagus itself.

If the ARSA comes into contact with the trachea, it can induce dyspnea; however, if it is discovered in front of the trachea, it must be identified before tracheostomy. A fistula forming between the oesophagus and an ARSA is a rare occurrence that usually occurs after prolonged nasogastric intubation. The ARSA is likely vulnerable to extrinsic compression and pressure necrosis by indwelling nasogastric or endotracheal tubes due to its inappropriate physical closeness to the oesophagus or trachea. The sequence of events might include blood artery blockage and thrombosis, as well as vessel wall infarction and final wall disintegration. To avoid the potentially fatal effects of an ARSA-esophageal fistula, individuals with an ARSA or other vascular ring abnormality should avoid prolonged nasogastric and endotracheal intubation.

ARSAs follow a path that runs near to the thoracic vertebrae. The region above the aortic arch between the oesophagus and the spine is typically regarded as a safe location for dissection of upper thoracic vertebrae when conducting an anterior approach to the upper thoracic vertebrae. Pedicle screw insertion into a dorsal vertebra through a posterior approach or thoracic vertebral body removal via an anterior approach may result in uncontrolled bleeding if surgeons do not address the ARSA. Accidental puncture of an ARSA during right subclavian vein catheterization is another serious complication that can be deadly. Wherever feasible, ultrasound guided puncture for central venous lines should be performed, and it is especially recommended when an ARSA has been found.

If the guide wire penetrates the descending aorta rather than the ascending aorta during aortography via the right radial artery, ARSA should be considered. Because of the angular path of the ARSA to the ascending aorta, catheterization of the ascending aorta may be difficult or perhaps impossible in this situation. We propose angiography through the left radial artery or a transfemoral technique in these patients.

Several techniques have been proposed for preoperative diagnosis of this anomaly: The abnormality may be predicted by barium swallow, especially in symptomatic individuals. Noninvasive angiography (CT or MRI) can be an excellent confirming modality. Esophagectomy may reveal a pulsatile impression in the posterior wall of the oesophagus, which may be diagnosed with high accuracy using multislice CT.

## **CONCLUSION:**

ARSA is an uncommon mutation of the aorta arch. Clinicians should be aware of the anatomy and clinical significance of an ARSA, particularly to avoid long-term nasogastric tube usage and the potentially fatal implications of an ARSA-esophageal fistula. It is critical to remember ARSA and to identify ARSA prior to surgical approaches to the upper thoracic vertebrae in order to minimise problems and receive correct treatment. A left radial artery or transfemoral route for aortography or cerebral angiography should be suggested in individuals with a known ARSA.

## **REFERENCES:**

1. Babu CS, Sharma V : Two common trunks arising from arch of aorta: case report and literature review of a very rare variation. *J Clin Diagn Res* 9 : AD05-AD07, 2015
2. Backer CL, Ilbawi MN, Idriss FS, DeLeon SY : Vascular anomalies causing tracheoesophageal compression. Review of experience in children. *J Thorac Cardiovasc Surg* 97 : 725-731, 1989
3. Bayford D : An account of singular case of obstructed deglutition. *Mem Med Soc Lond* 2 : 275-286, 1794
4. Berko NS, Jain VR, Godelman A, Stein EG, Ghosh S, Haramati LB : Variants and anomalies of thoracic vasculature on computed tomographic angiography in adults. *J Comput Assist Tomogr* 33 : 523-528, 2009
5. Celikyay ZR, Koner AE, Celikyay F, Deniz C, Acu B, Firat MM : Frequency and imaging findings of variations in human aortic arch anatomy based on multidetector computed tomography data. *Clin Imaging* 37 : 1011- 1019, 2013
6. Chadha NK, Chiti-Batelli S : Tracheostomy reveals a rare aberrant right subclavian artery; a case report. *BMC Ear Nose Throat Disord* 4 : 1, 2004
7. Desvant C, Chevalier D, Mortuaire G : Tracheotomy bleeding from an unusual tracheo-arterial fistula: involvement of an aberrant right subclavian artery. *J Laryngol Otol* 124 : 1333-1336, 2010
8. Gable DS, Stoddard LD : Acute bacterial aortitis resulting in an aortoesophageal fistula. A fatal complication of untreated esophageal carcinoma. *Pathol Res Pract* 184 : 318-324, 1989
9. Heck HA Jr, Moore HV, Lutin WA, Leatherbury L, Truemper EJ, Steinhart CM, et al. : Esophageal-aortic erosion associated with double aortic arch and tracheomalacia. Experience with 2 infants. *Tex Heart Inst J* 20 : 126-129, 1993

10. Hosn MA, Haddad F, El-Merhi F, Safadi B, Hallal A : Repair of an aberrant subclavian arterioesophageal fistula following esophageal stent placement. *World J Gastrointest Surg* 6 : 117-121, 2014
11. Huang IL, Hwang HR, Li SC, Chen CK, Liu CP, Wu MT : Dissection of arteria lusoria by transradial coronary catheterization: a rare complication evaluated by multidetector CT. *J Chin Med Assoc* 72 : 379-381, 2009
12. Ichikawa T, Koizumi J, Tanno K, Okochi T, Nomura T, Shimura S, et al. : Kommerell diverticulum in adults: evaluation of routine CT examinations. *Tokai J Exp Clin Med* 41 : 65-69, 2016
13. Inman JC, Kim P, McHugh R : Retroesophageal subclavian artery- esophageal fistula: a rare complication of a salivary bypass tube. *Head Neck* 30 : 1120-1123, 2008
14. Jahnke T, Schaefer PJ, Heller M, Mueller-Huelsbeck S : Interventional management of massive hemothorax due to inadvertent puncture of an aberrant right subclavian artery. *Cardiovasc Intervent Radiol* 31 : Suppl 2:S124-S127, 2008
15. Jakanani GC, Adair W : Frequency of variations in aortic arch anatomy depicted on multidetector CT. *Clin Radiol* 65 : 481-487, 2010
16. Jalali Kondori B, Asadi MH, Rahimian E, Tahsini MR : Anatomical variations in aortic arch branching pattern. *Arch Iran Med* 19 : 72-74, 2016
17. Janssen M, Baggen MG, Veen HF, Smout AJ, Bekkers JA, JG, et al. : Dysphagia lusoria: clinical aspects, manometric findings, diagnosis, and therapy. *Am J Gastroenterol* 95 : 1411-1416, 2000
18. Jiang XH, Zhu XY : Abnormal origin of the right subclavian artery: a case report. *Chin Med J (Engl)* 130 : 1508-1509, 2017
19. Kiernan PD, Dearani J, Byrne WD, Ehrlich T, Carter W, Krasicky G, et al. : Aneurysm of an aberrant right subclavian artery: case report and review of the literature. *Mayo Clin Proc* 68 : 468-474, 1993
20. Levitt B, Richter JE : Dysphagia lusoria: a comprehensive review. *Dis Esophagus* 20 : 455-460, 2007
21. Malone CD, Urbania TH, Crook SE, Hope MD : Bovine aortic arch: a novel association with thoracic aortic dilation. *Clin Radiol* 67 : 28-31, 2012
22. Maranillo E, Vazquez T, Quer M, Niedenführ MR, Leon X, Viejo F, et al. : Potential structures that could be confused with a nonrecurrent inferior laryngeal nerve: an anatomic study. *Laryngoscope* 118 : 56-60, 2008
23. G. Molz and B. Burri, "Aberrant subclavian artery (*Arteria lusoria*): sex differences in the prevalence of various forms of the malformation. Evaluation of 1378 observations," *Virchows Archiv A: Pathological Anatomy and Histology*, vol. 380, no. 4, pp. 303–315, 1978.
24. P. M. Hunauld, "Examen de quelques parties d'un singe," *Histoire de l'Académie Royale des Sciences*, vol. 2, pp. 516–523, 1735.

25. B. Kommerell, "Verlagerung des Oesophagus durch eine abnorm verlaufende *Arteria subclavia dextra* (Arteria Lusoria)," *Fortschritte auf dem Gebiete der Röntgenstrahlen*, vol. 54, pp. 590–595, 1936.
26. R. Kopp, I. Wizgall, E. Kreuzer et al., "Surgical and endovascular treatment of symptomatic aberrant right subclavian artery (arteria lusoria)," *Vascular*, vol. 15, no. 2, pp. 84–91, 2007.
27. T. G. Delap, S. E. Jones, and D. R. Johnson, "Aneurysm of an aberrant right subclavian artery presenting as dysphagia lusoria," *Annals of Otology, Rhinology and Laryngology*, vol. 109, no. 2, pp. 231–234, 2000.
28. M. D. Kelly, "Endoscopy and the aberrant right subclavian artery," *American Surgeon*, vol. 73, no. 12, pp. 1259–1261, 2007.
29. T. Saito, Y. Tamatsukuri, T. Hitosugi et al., "Three cases of retroesophageal right subclavian artery," *Journal of Nippon Medical School*, vol. 72, no. 6, pp. 375–382, 2005.
30. M. B. Lewin, E. A. Lindsay, V. Jurecic, V. Goytia, J. A. Towbin, and A. Baldini, "A genetic etiology for interruption of the aortic arch type B," *American Journal of Cardiology*, vol. 80, no. 4, pp. 493–497, 1997.
31. J. Schneider, R. Baier, C. Dinges, and F. Unger, "Retroesophageal right subclavian artery (lusoria) as origin of traumatic aortic rupture," *European Journal of Cardio-thoracic Surgery*, vol. 32, no. 2, pp. 385–387, 2007.
32. N. M. Southard, G. R. Seabrook, S. M. Tutton et al., "A unique hybrid approach to the treatment of an aberrant right subclavian artery aneurysm," *Vascular and Endovascular Surgery*, vol. 47, no. 2, pp. 128–130, 2013.