

# Innocuous lesions and not so Innocuous lesions of the Skin and Soft tissue

## ABSTRACT

**Background:** Cystic lesions of the skin and soft tissue are often neglected and thought to be innocuous or harmless. These lesions need to be excised to exclude malignancy. The lesions may present in unusual sites and may also be of infective origin. Thus, there is an urgent need to determine the prevalence and identify the histopathological features of the cystic lesions as the innocuous appearing lesions may actually not be so innocuous. In addition, it is the histopathological features that determine the treatment modality.

**Aim:** To determine the features and prevalence of the types of cysts in skin and soft tissue.

**Material and methods:** A retrospective study of the cystic lesions of the skin and soft tissue was conducted. The records from the Department of Pathology, Saveetha Medical College were retrieved and reviewed for patients with cystic lesions of the skin and soft tissue over a one year period extending between January 2019 and December 2019. The records were examined for the following data : age, sex, type of lesion, clinical and histopathological diagnosis.

**Results:** In all 109 cases with skin and soft tissue swellings were analyzed. Among these 53 were males and 56 were more females reported (51 %) of cystic swellings as compared to males (48%). Cystic lesions were most commonly encountered in the age group of 18 to 40 years, which suggests that there may be a role for trauma or occupation related occurrence. A variety of cysts were encountered such as epidermoid cysts (70%), Trichilemmal cyst (7%), and Ganglion (7%).Phaeohyphomycotic cyst, mucous retention cyst, hemangioma and pilomatrixoma. Epidermal cysts were more frequently encountered in males (54%) than females (46%).Most lesions occurred in the back.

**Conclusion:** Epidermal cysts may frequently be associated certain syndromes, hence it is important to evaluate these cysts. In addition phaeohyphomycotic cysts may be mistaken for Ganglion, so histopathological examination is necessary to initiate appropriate therapy.

*Keywords: Epidermoid cyst, Cystic lesions, Histopathology, Trichilemmal cyst.*

## 1. INTRODUCTION

Skin and soft tissue swellings tend to be often neglected unless they cause cosmetic disfigurement. It is essential that an excision biopsy be done to rule out malignancy such as squamous cell carcinoma or basal cell carcinoma, that may occur in a small proportion of cases.<sup>[1]</sup>The most common skin and soft tissue swelling that is encountered in clinical practice is the epidermoid cyst.<sup>[2]</sup> These cysts may sometimes be found in unusual sites in the body such as sole of foot<sup>[3]</sup>. Certain skin and soft tissue swellings may be associated with certain syndromes such as Gardner or Favre Racouchot syndrome and therefore need to be evaluated<sup>[4]</sup>. An association between drugs such as BRAF inhibitors, imiquimod and cyclosporine and soft tissue swellings has also been described<sup>[5]</sup>. There are few studies that outline the occurrence and

clinicopathological correlation of skin and soft tissues swellings, therefore this was undertaken to determine the prevalence of cystic lesions in the skin and soft tissues based on histopathological examination (HPE), to determine the characteristics of the cystic lesions of skin and soft tissue, to correlate the histopathological features with demographic and clinical presentation of cystic lesions of skin and soft tissue.

## 2. MATERIAL AND METHODS

A study was undertaken on cystic lesions of skin and soft tissue at a tertiary care center from January 2019 to December 2019 in Kancheepuram district of Tamil Nadu. The center caters to semi urban and rural population.

**Study Design:** A retrospective observational descriptive, cross sectional study

*What was analyzed*

Purely and partly cystic lesions of the skin and soft tissue were included.

Solid lesions were excluded.

Cysts of the breast were excluded.

*Definitions:* A cyst is defined as “a pathological cavity having fluid, semi-fluid, or gaseous contents and which is not created by accumulation of pus” [6]

Pseudocyst: “Cyst that are not surrounded by a capsule are known as pseudocyst and usually arise in acne” [6]

*How was it analyzed*

A clinicopathological analysis was undertaken. The records were examined for the following data: age, sex, type of lesion, clinical and histopathological diagnosis and documented in a spreadsheet.

Age and demographic details were analyzed and correlated with the type of cysts.

## 3. RESULTS AND DISCUSSION

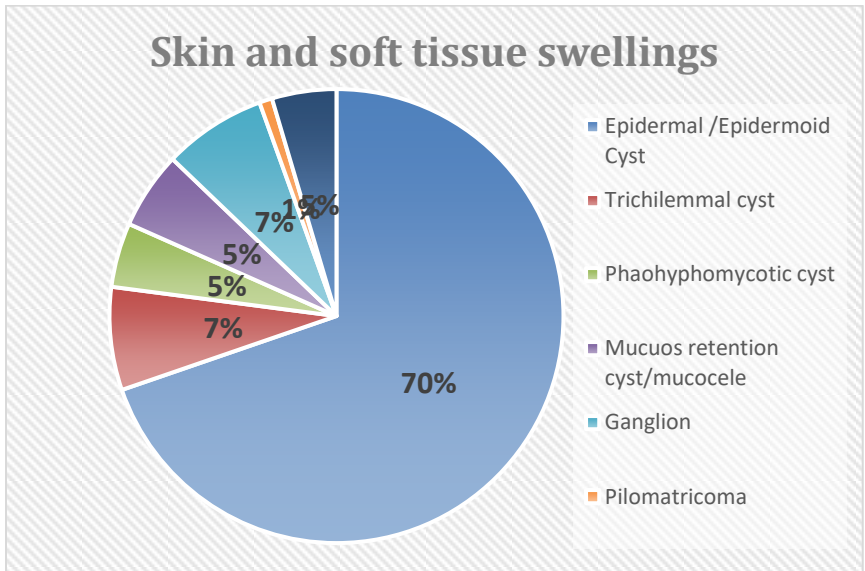
In all 109 cases were analyzed. Among these 53 were males and 56 were females. Thus, females reported (51 %) of cystic swellings as compared to males (48%). The male to female ratio was found to be 1:1. The age distribution ranged from 4 years to 75 years. The analysis based on age and gender is shown in Table 1.

**Table 1. Demographic Details of Study participants**

Age (years)	Male	Female	Total (%)
0-<18	5	4	9 (8.2%)
18-30	18	6	24(22%)
31-40	12	20	32 (29.3%)
41-50	8	11	19 (17.4%)
51-60	7	10	17 (15.5%)
>60	3	5	8( 7.3%)

With increasing age the incidence of the cystic lesions also decreased. Among patients of 60 years of age or above, the incidence was only 7%. The incidence was only 8% in individuals less than 18 years of age. Majority of cases belonged to the age group of 31-40 (29%), followed by 18-30 (22%). Thus in the age group 18-40, it was 51% totally.

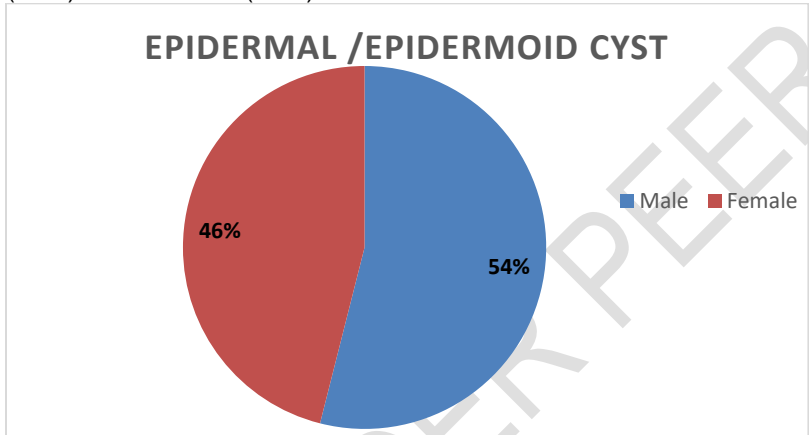
Distribution of skin and soft tissue swellings encountered in the study over a period of one year is shown in Fig 1.



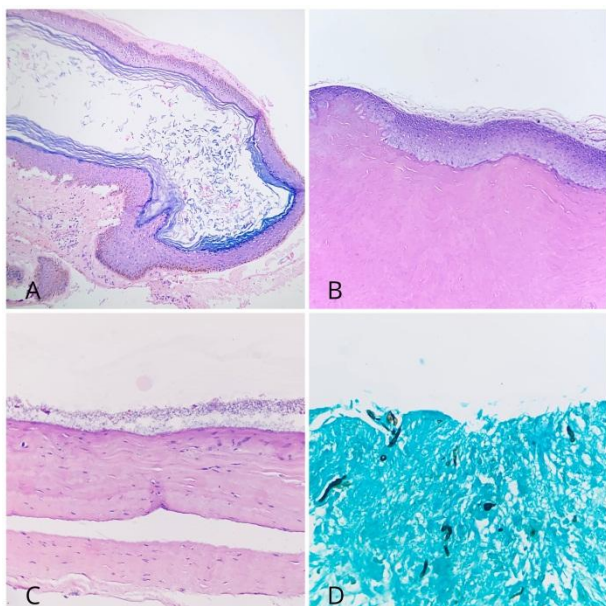
**Figure 1: Distribution of skin and soft tissue swellings encountered in the study over one year.**

Epidermal cysts were the most common, accounting for 70% of the skin and soft tissue swellings. This was followed by Trichilemmal cyst (7%), and Ganglion (7%). Phaeohyphomycotic cyst, mucous retention cyst, hemangioma and pilomatrixoma accounted for the rest. Pilomatrixoma was the least common (1%).

Distribution of epidermal cyst by gender is shown in Fig 2. Epidermal cysts were more frequently encountered in males (54%) than females (46%).



**Fig 2: Distribution of epidermal cyst by gender**



**Fig 3: Microscopic images; A – Epidermal cyst ( H&Estain 10x), B – Pilar/ Trichilemmal cyst ( H&Estain 10x), C – Ganglion ( H&Estain 10x), D - Phaeohyphomycotic cyst ( GMS stain 40x)**

Majority of the skin and soft tissue swellings occurred in the back (41%). Among the skin and soft tissue cysts occurring on the back , epidermal cyst was the most common (95%). The second most common site affected was the extremities (16%) in which ganglion(47%) was the most common lesion encountered followed by phaeohyphomycotic cyst (29%).All trichilemmal cysts encountered in the study were found on the scalp as depicted in Table 2.

Site (n)	Epidermal /Epidermoid Cyst	Trichilemmal cyst	Pheohyphomycotic cyst	Mucous retention cyst/mucocele	Ganglion	Pilomatricoma	Hemangioma
Scalp (n=16)	7	8	-	-	-	-	1
Head & Neck (n=5)	4	-	-	-	-	-	1
Chest(n=13)	12	-	-	-	-	-	1
Scrotum/Inguinal region(n=2)	2		-	-	-	-	-
Axilla (n=2)	2		-	-	-	-	-
Back (n=45)	43		-	-	-	1	1
Gluteal region (n=1)	1	-	-	-	-	-	-
Joints (n=3)	3	-	-	-	-	-	-
Extremities (n=17)	3		5	-	8	-	1
Lowerlip (n=5)	-	-		5	-	-	-

Total	77	8	5	5	8	1	5
-------	----	---	---	---	---	---	---

**Table 2: Distribution of skin and soft tissues swellings by site.**

The sites of the body affected include scalp, frontal, parietal, occipital, auricular region, axilla, anterior/ lateral chest wall, back, wrist, dorsum of hand, gluteal region, thigh, knee, scrotal region and dorsum of foot.

Analysis based on complications revealed evidence of calcification seen in one cyst. Eight epidermoid cysts were found to be infected and four infected epidermal cysts showed evidence of rupture. Foreign body giant cell reaction was observed in two infected / ruptured epidermal cysts and also in one pilar cyst.

### 3.1 DISCUSSION:

Cystic and soft tissue swellings are frequently encountered in clinical practice. Often these lesions are neglected and histopathological examination undertaken for cosmetic purposes or for ruling out malignancy. Cysts may be mistaken for an abscess and treated with antibiotics which will promote antibiotic resistance.<sup>[10]</sup>

Gender distribution of cysts encountered in this study was different from those reported previously. Thus it does not appear that women living in this region had any barriers to seeking medical assistance.

Analysis of age distribution suggests that most cystic lesions occur among those in the age group 21-40. This age group represents the most productive period of life. Possibly the occurrence of the cyst maybe works related. It is well known that cystic lesions may occur due to trauma<sup>[9]</sup>.

Majority of cysts are benign, however the cysts need to be excised to rule out malignancy.

Cysts maybe part of certain syndromes such as Gardner's syndrome. Multiple cysts in a patient were rarely encountered in the duration of the study. It is also important to differentiate cysts from pseudocysts.

Multiple studies have indicated that histopathological examination is required for making the correct diagnosis and for determining the exact type of cyst. Epidermal or epidermoid cyst is the preferred terminology as compared to the use of the term "sebaceous cyst"<sup>[11]</sup>.

Epidermal cyst are most commonly found in the scalp, head and neck, upper trunk. They are also encountered in the genitalia, palmoplantar region. They maybe solitary or multiple epidermal cysts are sometimes associated with Gardner's syndrome<sup>[7]</sup>.

Ganglion cysts are benign soft tissue tumors that predominantly occur in the wrist but which can occur in any joint ganglion to see whether any other joint apart from wrist was affected.

Sometimes cyst can rupture or develop infection, which can leads to complications. *Staphylococcus aureus* is the most common cause of secondary infection. Thus following excision of the cyst a microbiological investigation of the cyst for gram stain and culture must be undertaken to institute appropriate therapy<sup>[8]</sup>.

Often cystic lesions present as clinical dilemmas. In this study a few cystic lesions were clinically diagnosed as ganglion but on histopathological examination were found to be phaeohyphomycotic cyst.<sup>[12]</sup> This reinforces the need for a histopathological examination, as the line of treatment varies. A phaeohyphomycotic lesion will require treatment with antifungal agents while a ganglion will be treated by different modalities. A clinical sebaceous cyst of scalp actually on HPE was found to be hemangioma. Often radiological imaging is resorted to, to identify the type of cyst, however histopathological examination provides the concrete evidence with regard to type of cyst.

### 4. CONCLUSION

Thus, this study clearly highlights the role of histopathology in determining whether a cystic lesion is indeed innocuous or not so innocuous and outlines the need for the initiation of appropriate therapy. As a clinical diagnosis may be misleading, it is important to resort to biopsy to arrive at a correct diagnosis.

### ETHICAL APPROVAL

Ethical clearance- Institutional ethics committee approval was obtained.

### REFERENCES

1. Frank E, Macias D, Hondorp B, Kerstetter J, Inman JC. Incidental squamous cell carcinoma in an epidermal inclusion cyst: a case report and review of the literature. *Case Reports in Dermatology*. 2018;10(1):61-8.
2. Trinh CT, Nguyen CH, Chansomphou V, Tran TT. Overview of epidermoid cyst. *European journal of radiology open*. 2019 Jan 1;6:291-301.
3. Lee KM, Park JH, Min KH, Kim EK. Epidermal cyst on the sole. *Archives of plastic surgery*. 2013 Jul;40(4):475.

4. Nigam JS, Bharti JN, Nair V, Gargade CB, Deshpande AH, Dey B, Singh A. Epidermal cysts: a clinicopathological analysis with emphasis on unusual findings. *International journal of trichology*. 2017 Jul;9(3):108.
5. Welsh SJ, Corrie PG. Management of BRAF and MEK inhibitor toxicities in patients with metastatic melanoma. *Therapeutic advances in medical oncology*. 2015 Mar;7(2):122-36.
6. Dr Amanda Oakley Cutaneous cysts and pseudocysts. *Dermatologist*, Hamilton, New Zealand, 1997. Updated February 2016.
7. Dutta M, Saha J, Biswas G, Chattopadhyay S, Sen I, Sinha R. Epidermoid cysts in head and neck: our experiences, with review of literature. *Indian Journal of Otolaryngology and Head & Neck Surgery*. 2013 Jul 1;65(1):14-21.
8. Prior A, Anania P, Pacetti M, Secci F, Ravegnani M, Pavanello M, Piatelli G, Cama A, Consales A. Dermoid and epidermoid cysts of scalp: case series of 234 consecutive patients. *World neurosurgery*. 2018 Dec 1;120:119-24.
9. Al-Khateeb TH, Al-Masri NM, Al-Zoubi F. Cutaneous cysts of the head and neck. *Journal of oral and maxillofacial surgery*. 2009 Jan 1;67(1):52-7.
10. Dogra V. Testicular epidermoid cysts. *AJR. American journal of roentgenology*. 2002 Oct;179(4):1075-author.
11. Nigam JS, Bharti JN, Nair V, Gargade CB, Deshpande AH, Dey B, Singh A. Epidermal cysts: a clinicopathological analysis with emphasis on unusual findings. *International journal of trichology*. 2017 Jul;9(3):108.
12. Abdolrasouli A, Gonzalo X, Jatan A, McArthur GJ, Francis N, Azadian BS, Borman AM, Johnson EM. Subcutaneous phaeohyphomycotic cyst associated with *Medicopsis romeroi* in an immunocompromised host. *Mycopathologia*. 2016 Oct 1;181(9-10):717-21.

UNDER PEER REVIEW