

A Clinicopathological Study of Malignant Peripheral Nerve Sheath Tumors- At A Tertiary Care Center

ABSTRACT

Aim: To study the clinicopathological profile in Malignant Peripheral Nerve Sheath Tumors (MPNST)

Study design: A retrospective descriptive study

Place and Duration of Study: Department of Pathology, Saveetha medical college and hospital, Chennai, between June 2016 and May 2021.

Methodology: A complete enumerative sampling of all the MPNSTs received at Saveetha Medical College and Hospital over a five-year period was done which included 9 cases (4 men, 5 women; age range (19-66 years). The details were obtained from the records in the Department of Pathology. The demographic parameters, clinical and histomorphological data were tabulated and analysed.

Results: Nine cases of MPNSTs were received in our hospital during the study period. In our study a female preponderance was noted, with late thirties being the median age of presentation. Extremities and trunk were the most common sites. Two rare lesions involving the pancreas and mesentery were reported. 4 cases had underlying Neurofibromatosis (NF1). The average tumour size was 8.8cm, with majority having a tumour size >5cm. Histomorphologically most cases showed hypo and hypercellular areas composed of spindle cells with wavy nuclei arranged in interlacing fascicles with increased mitotic activity and tumour necrosis. Two cases showed epithelioid differentiation and three had heterologous elements in the form of glandular differentiation or rhabdomyoblastic differentiation.

Conclusion: MPNSTs are very rare tumours accounting for 6% of soft tissue sarcomas and have a very aggressive course. Details of the clinical presentation and careful histomorphological typing of these tumours are essential for identifying and treating them.

Keywords: Malignant Peripheral Nerve Sheath Tumors (MPNST), Neurofibromatosis (NF1), Histomorphology, High grade,

1. INTRODUCTION

Malignant peripheral nerve sheath tumors (MPNSTs) are very rare aggressive tumors accounting for 6% of soft tissue sarcomas [1]. Has a global incidence of just 0.001% (1.46/million) as per a SEER analysis [3]. They can occur sporadically in around 40% of the cases, 50% of cases occur in association with neurofibromatosis type 1 (NF1) and remaining 10% as a consequence of previous radiation therapy (RT-induced) [1,2,6] Patients with NF1 have an estimated 8–12% lifetime risk of developing MPNST, mainly derived from a pre-existing plexiform neurofibroma. [6]

Most of the sporadic MPNSTs seen between 40 to 50 years of age, while those cases associated with NF1 present a decade earlier.[6] These tumors are usually located in the extremities, trunk, retroperitoneum, and the head & neck region [1,2,3]. Histologically, MPNSTs are typically composed of spindle cells. Heterologous differentiation is present in up to 10%–15% of MPNSTs [2]. Most MPNSTs are high-grade malignancies, with a 5-year survival rate of 35%–60% [3]. MPNST associated with NF1 are more aggressive than the sporadic ones and they are known to metastasize within 2 years of diagnosis. This is a comprehensive clinicopathological study of MPNSTs with emphasis on the varied morphology of these tumors.

2. MATERIAL AND METHODS

This retrospective descriptive study was conducted in the Department of Pathology, Saveetha Medical College, Thandalam. The study period was five years from June 2016 to May 2021. Details of the cases were obtained from the histopathology registers in the Department of Pathology. Nine histopathologically confirmed cases of MPNST were found. The specimens were either excision biopsies or resected specimens of tumors. Incisional biopsies and all benign neural lesions were excluded from the study. The clinical history, demographic details (age, gender, clinical features and tumor location) and radiological findings were tabulated. The slides were retrieved from the archives of the Pathology department and detailed examination was done under the light microscope. The histological features and grade of the tumor were noted.

As per the latest WHO 2020 soft tissue sarcoma and bone, the grading of MPNSTs according to AJCC and FNCLCC is often a debated subject and World Health Organization (WHO) recommends the usage of a grading system where tumors are divided into high grade and low grade based on the mitotic count and necrosis.

Low grade- mitotic count 3-9/10HPF and no necrosis

High grade- mitotic count >10/10HPF without necrosis or mitotic count 3-9/10HPF and with necrosis.

3. RESULTS AND DISCUSSION

Among the 9 cases of MPNST studied, a wide age range was noted, with the youngest patient being 19 years and the oldest, 66 years. Maximum number of cases (33.37%) was seen in the age group 61-70 years (Table 1). Females (56 %) slightly outnumbered male patients (44%) and the M:F ratio was 1:1.2 (Fig 1).

Age group	Number of cases	Percentage
0-10 years	-	-
11-20 years	1	11%
21-30 years	-	-
31-40 years	2	22%
41-50 years	1	11%
51-60 years	2	22%
61-70 years	3	33%

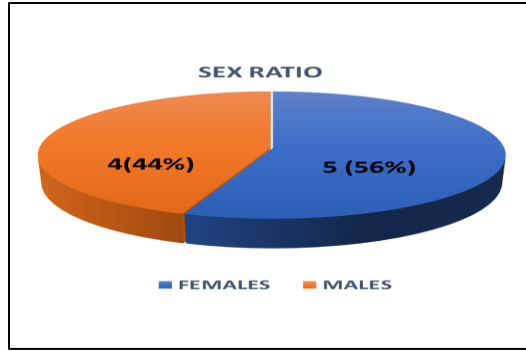


Figure 1: Gender wise distribution of the MPNSTs

NF1 association was seen in 44% of the cases (4/9 cases) and remaining 56% cases did not show any association with NF1.

In our study, 5 cases (56.66%) were superficially located whereas 4 cases were deep seated (44.44%) lesions. Overall, the extremities (44.4%) and trunk (44.4%) were the most common sites of involvement with an equal incidence of 4 cases each. Head and neck involvement was noted in one case (11.1%). Among the extremities, 3 cases were from the thigh and 1 case was from the upper limb (Fig 2). All our truncal lesions were unique sites of presentation, we had reported pancreatic, mesenteric, L5s1 vertebral body MPNST and a presacral MPNST respectively.

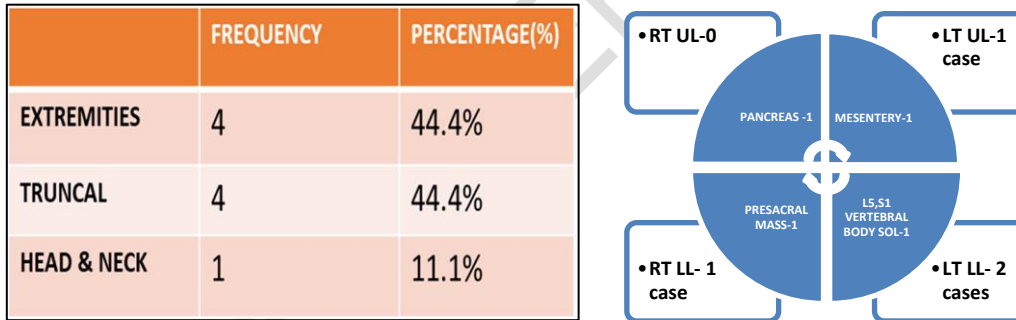


Figure 2: Distribution of the MPNSTs among the various sites

In majority of the cases (77.7%) tumor size was >5 cm and in rest of the cases (22.22%) the size was <5 cm. Histologically, these cases showed the typical histological appearance of MPNST, namely, hypo- and hypercellular areas with a variety of patterns, including fascicles, whorls, focal palisading, sheets (Fig 3). Two cases had epithelioid features, while heterologous differentiation was identified in 3 (33.3%) cases in the form of glandular or "muscle-like" differentiation of which two cases showed rhabdomyoblastic differentiation and one case showed glandular differentiation.

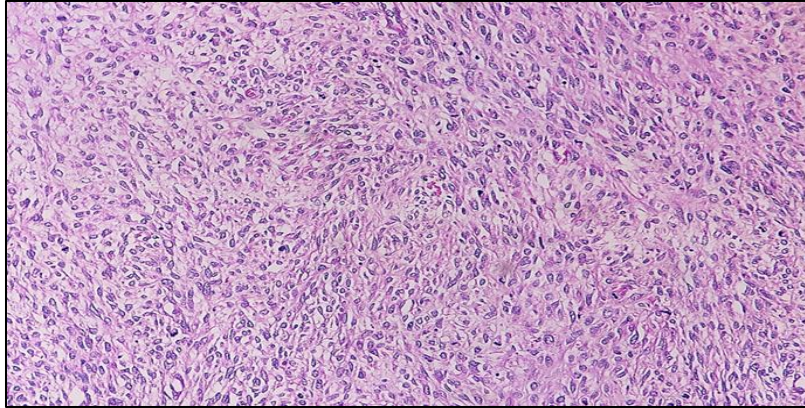


Figure 3: Classical MPNSTs showing fascicular pattern

In the present study, 8 cases (88.8%) were high grade MPNSTs, while only one case was low-grade tumour. Among the high grade MPNSTs, 5 cases had a high mitotic count (mitosis >10/10 HPF) and 3 cases had a low mitotic count (mitosis 3-9/10 HPF). Among the MPNST with mitotic count >10/10HPF, associated necrosis was seen in 4 cases (4/5) and no association with necrosis was demonstrated in one case. (Table 2)

Table 2 : Distribution of MPNSTs among high grade tumors

MITOSIS	NECROSIS PRESENT	NECROSIS ABSENT	TOTAL NO. CASES
3-9/10HPF	3 cases		3 cases (33%)
>10/10HPF	4 cases	1 case	5 cases (55%)

3.1 DISCUSSION

MPNSTs are aggressive tumours that develop from a major or minor peripheral nerve branches or sheath of peripheral nerve fibres and have replaced the previous heterogeneous and often confusing terminologies, such as malignant schwannoma, malignant neurilemmoma and neurofibrosarcoma for tumors of neurogenic origin. Their diagnosis is often challenging because of their cellular origin and histopathological similarities with other spindle cell sarcomas.

MPNSTs commonly occur between the 3rd and 6th decade of life and generally have no gender predilection. In the present study, a total of 9 cases of MPNSTs were studied. A wide age range was seen from 19 to 66 years, majority of cases were seen in the 5th to 4th decade of life and the median age of presentation was 39.3 years which corresponded to a similar mean age at presentation (38.1 years) and wide age range of patients (8 to 75 years) from the study of Rekhi et al.

In the present study females slightly outnumbered male patients with a M : F ratio of 1:1.2, whereas in studies by [6] and [7] males outnumbered females with a M; F ratio of 1.04:1 and 2.7:1 respectively.

NF1-associated tumors represent 37–64% of MPNSTs as was also seen in the present study (44.2%) and few other similar studies[3,4,5]

Most MPNSTs present as deep soft tissue masses and cutaneous tumors are rare. In the study, by Rekhi et al most of the tumors were deep seated (60.3%) and the remaining (39.6%) were superficially located, similarly Yuvan et al demonstrated that deep seated lesion were more common in their studies. However, there was a slight preponderance of a superficial location of these lesions in our study (56.66%).

The common sites of involvement are the extremities, trunk, head and neck as seen in the study by Rekhi et al, and Kar et al. MPNST arising in the extremities most commonly manifest as a painful mass. In contrast, those tumors that arise in the abdomen and retroperitoneum are often clinically silent. Two rare sites, namely, the pancreas and mesentery were reported in our study. MPNST associated with NF1, arising from plexiform neurofibroma of the mesentery in a 34-year-old female who presented with complaints of abdominal pain was one of the rare cases. Only six cases have been reported in literature, in this site till date; of these, three cases were associated with NF1, with one of them having an association with plexiform neurofibroma[8,9,10,11]. Yet another rare case was a 62-year-old gentleman who had presented with a month-long abdominal discomfort and pain and was diagnosed as pancreatic MPNST based on the histopathological sections of pancreatic tissue showing the typical histological appearance of these tumours[12].

Most MPNSTs range in size from 6 to 15 cm with the majority being larger in size [3,4,7]. In our study too, the size of the tumors ranged from 3-14 cm.

As in the present study, majority of MPNSTs have typical histological features of spindle cells arranged in fascicles or whorls or sheets and few cases show varied differentiation like rhabdomyoblastic or glandular differentiation which was noted in other studies as well [3,4,5,7,13]

With reference to grade, most studies have reported the majority of the tumours to be of high grade[3,4,5,7]. This was also noted in the present study (88.8%). Moreover, the four NF 1 associated tumors were high grade MPNSTs which is a finding seen in other studies by Rekhi et al, Yuan et al, Sasi et al

In most MPNSTs mitotic count ranges from 3-9/10HPF - >10/ 10 HPF and generally have a high mitotic count, this was also seen in our study [3,4]

4. CONCLUSION

This study highlights the clinicopathological features of 9 cases of MPNSTs and its association with NF-1. MPNSTs often present with diagnostic challenge as they may mimic other spindle cell lesions. A combination of the clinical history, gross, and detailed microscopic examination will be of great help in diagnosing these tumors. Identifying these tumours and knowledge of their behaviour is imperative for treatment and prognosis.

REFERENCES:

1. Meyer A, Billings SD. What's new in nerve sheath tumors. *VirchowsArchiv*. 2020 Jan;476(1):65-80.
2. Sbaraglia M, Bellan E, Dei Tos AP. The 2020 WHO classification of soft tissue tumours: news and perspectives. *Pathologica*. 2021 Apr;113(2):70.

3. Yuan Z, Xu L, Zhao Z, Xu S, Zhang X, Liu T, Zhang S, Yu S. Clinicopathological features and prognosis of malignant peripheral nerve sheath tumor: a retrospective study of 159 cases from 1999 to 2016. *Oncotarget*. 2017 Dec 1;8(62):104785.
4. Rekhi B, Ingle A, Kumar R, DeSouza MA, Dikshit R, Jambhekar NA. Malignant peripheral nerve sheath tumors: Clinicopathological profile of 63 cases diagnosed at a tertiary cancer referral center in Mumbai, India. *Indian Journal of Pathology and Microbiology*. 2010 Oct 1;53(4):611.
5. Kar M, Deo AV, Shukla NK, Malik A, Gupta SD, Mohanti BK, et al. Malignant peripheral nerve sheath tumors (MPNST) - clinicopathological study and treatment outcome of twenty-four cases. *World J Surg Oncol*. 2006;4:55.
6. Widemann BC. Current status of sporadic and neurofibromatosis type 1-associated malignant peripheral nerve sheath tumors. *Current oncology reports*. 2009 Jul 1;11(4):322-8.
7. Sasidharan SV, Kumar V, Pai RR, Vasudevan S. A clinicopathological and immunohistochemical study of malignant peripheral nerve sheath tumors. *Int J Res Med Sci*. 2014 Oct;2(4):1307-2.
8. Nagao T, Shigenobu M, Teramoto S, Fukuda K, Mizushima M, Nishioka S, et al. A case of malignant schwannoma of the mesentery in a patient with von Recklinghausen's disease. *Gan No Rinsho*1984;30:968-74.
9. Wu CC, Peng HL, Su CT, Lu TN, Lee CC, Chen LK. Mesenteric and retroperitoneal malignant peripheral nerve sheath tumors in a patient with neurofibromatosis type 1. *Chin J Radiol*2003;28:193-8.
10. Goyal V, Thomas S, Pathania OP, Agarwal S. Malignant nerve sheath tumor of the mesentery. *Indian J Cancer* 2010;47:233-4.
11. Bazzoni C, Ongari M, Crespi A, Alleva M, Sguazzini C, Lombardi C, et al. Malignant schwannoma of the mesentery. Presentation of a clinical case and clinical and histopathological considerations. *Minerva Chir*1991;46:413-6.
12. Balineni P, Arcot R, Devygounder K, Rahaman K, Narayansamy B, Prabhu M, Vaitheeswaran S. Malignant peripheral nerve sheath tumor of the pancreas—A case report. *International journal of surgery case reports*. 2019 Jan 1;55:239-42.
13. Ducatman BS, Scheithauer BW, Piepgras DG, Reiman HM, Ilstrup DM. Malignant peripheral nerve sheath tumors. A clinicopathologic study of 120 cases. *Cancer*. 1986 May 15;57(10):2006-21