

## **SPECTRUM OF LESIONS IN THE FALLOPIAN TUBES – A HISTOPATHOLOGICAL STUDY**

### **ABSTRACT**

**Introduction:** The Fallopian tubes are a pair of narrow tubular structures connecting the ovary and the uterus. It is usually the site of fertilization and plays a very important role in the fusion of the sperm and ovary and helps in movement of the fertilized zygote to the uterus. Even though being an organ of very small size the importance of the variety of lesions occurring in the fallopian tubes is often not considered. Biopsies of the fallopian tubes are taken to show the different lesions found in the tubes.

**Aim:** The main aim of the study is to study the spectrum of lesions occurring in the fallopian tubes and correlation of these findings with its clinical parameters.

**Study design:** This is a retrospective descriptive study

**Place and Duration of study:** Department of Pathology, Saveetha Medical College, Saveetha Institute of Medical and Technical Sciences, Thandalam, Chennai between June 2019- December 2019.

**Methodology:** A retrospective study of all the fallopian tube specimens sent for routine histopathological analysis over a period of 6 months was carried out. The different pathological lesions were observed from the relevant clinical data and the correlation with its clinical parameters was done.

**Results:** A sample size of 77 specimens was collected among which the commonest age group which was found to have the highest number of lesions was between 26-30 years. This was found to be in correlation to the reproductive age group of women. The most common form of pathological lesion observed was ectopic pregnancy (about 46% of total pathological lesions), followed by Paratubal cysts (23%), Hydrosalpinx (15%) and Hematosalpinx (8%). Cystadenoma was the only benign tumor observed in this study and constituted 8% of the total pathological lesions.

**Conclusion:** This study shows the importance of histopathological examination of all fallopian tube specimens with or without abnormal findings.

**Keywords:** *Cyst, Ectopic pregnancy, Hematosalpinx, Hydrosalpinx.*

## INTRODUCTION

The Fallopian tubes are a pair of tubes found in the female reproductive system connecting the uterus and ovaries. It is the site of fusion of the sperm and egg to form the zygote.

Many lesions, inflammations and tumors can occur in the fallopian tubes. The fallopian tubes are also the most common site of ectopic pregnancies.

Inflammations are caused due to infections by pyogenic organisms especially gonococcus. Infections caused by chlamydia are quite rare. Inflammations can also be caused due to tuberculosis- Tuberculosis salpingitis. These infections begin in the vestibular and periurethral glands and spreads to the fallopian tubes and tubo- ovary region. It results in acute suppurative salpingitis. The lumen gets filled with purulent exudate containing neutrophils, plasma cells and lymphocytes. This exudate leaks out into the ovary resulting in salpingo-oophoritis. If it remains in the tubes, it forms purulent abscesses (pyosalpinx). This progress over time to form chronic follicular salpingitis- the epithelium adhere with each other to form scarring gland like spaces and blind pouches and hydrosalpinx- accumulation of tubal secretions and leads to tubal distension. Both these conditions block the passage of the oocyte and results in infertility.

Many other conditions such as tubal subtle variations, including tubal diverticula, Morgagni hydatids, accessory fallopian tube, accessory ostium of the fallopian tube, tubal phimosis, agglutination, and sacculation, have been described and cited as making significant contributions to infertility.<sup>[1]</sup>

Most common lesion found in the fallopian tubes is paratubal cysts (Hydatids of Morgagni) which are serous fluid filled cysts. Most lesions of the fallopian tubes are indications of ovarian cancer. Other common lesions found are serous tubal intraepithelial lesion (STIL) and serous tubal intraepithelial carcinoma (STIC) which has found to be a precursor of ovarian cancer.<sup>[2]</sup> High grade serous carcinoma develops in the ovary and fallopian tubes and is the most common type of carcinoma to occur in the fallopian tube. SCOUT, p53 signatures, and STIC were most frequent in the serous carcinomas. p53 signatures and STIC were always seen in the fimbrial end.<sup>[3]</sup>

Tumors also occur in the fallopian tube. Adenomatoid tumors are the most common benign tumor of the fallopian tube. Other common tumors are fibroma, adenoma, mesothelioma, lymphangioma and mesonephroma.<sup>[4]</sup> Some tumors also result from endometriosis, adenomyosis and salpingitis nodosa.

## **AIM**

The principle aim of this study is to study the spectrum of lesions occurring in the fallopian tubes and correlation of these findings with clinical parameters.

## **MATERIALS AND METHODS**

The study was conducted as a retrospective study of all the fallopian tube specimens sent for routine histopathological analysis over a period of 6 months from June 2019- December 2019. Ethical approval was obtained before conducting the study. A detailed gross examination and microscopic examination was carried out at all the parts of the fallopian tube – isthmus, fimbriae and ampulla. The microscopy of the fallopian tube was examined under the Hematoxylin and Eosin stain.

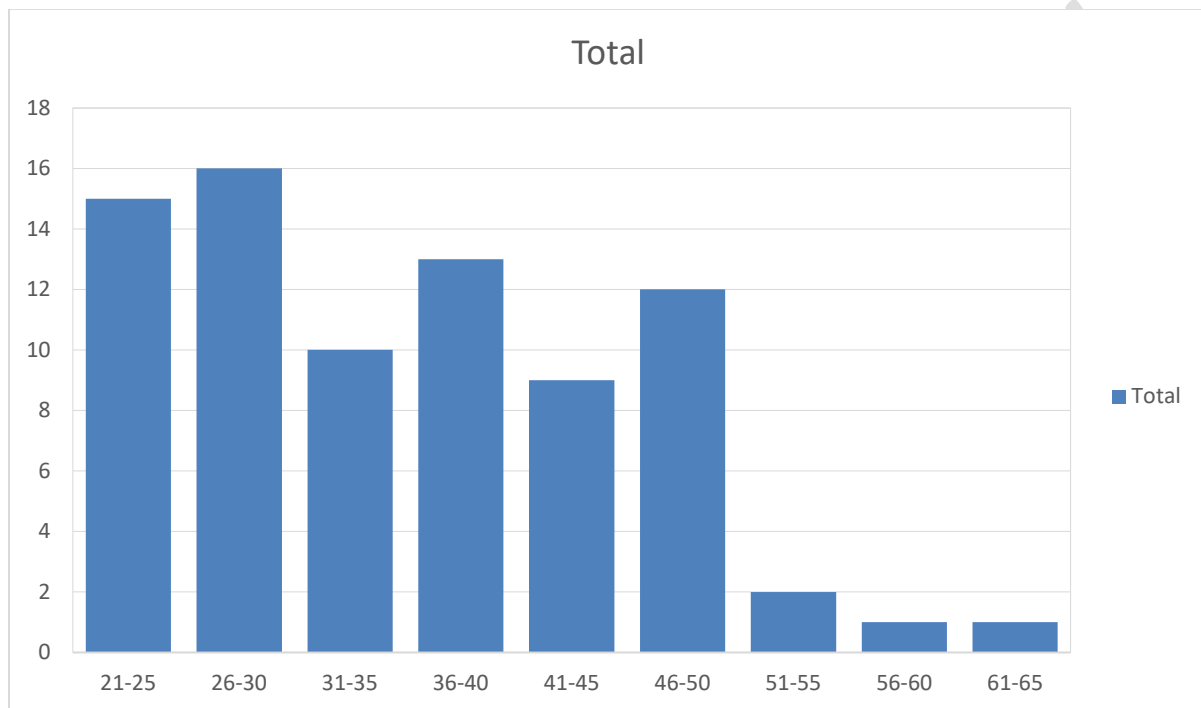
Histopathological analysis was evaluated and correlation of those histopathological diagnoses with other parameters was carried out. The parameters used were age and lesions found in the fallopian tube. The data was represented in the form figures and tables. The data were retrieved from the archives of Pathology and medical records.

## **RESULTS AND DISCUSSION**

A total of 77 specimens were collected over a period of 6 months from June 2019- December 2019. From the Chart 1, we can see specimens were collected mainly from the age group of 26-30 which makes 28.5% of the total pathological slides and constitutes the reproductive age of Indian women. The age group between 61-65 years makes only 7.14% of the total pathological slides. Based on age, the analysis

is depicted using a bar graph and the values were found to be significant. From a study, by Danielle, et.al; it was seen that the majority of the specimens were collected from the age group of 51<sup>[5]</sup>

**CHART 1: Age Distribution**



Most of the specimens collected didn't have specific lesions and were sent for histopathological staining for confirmation, which made 82% of the total specimens collected. The specimens with specific pathology constitute 18% of the total specimens as seen in Table 1.

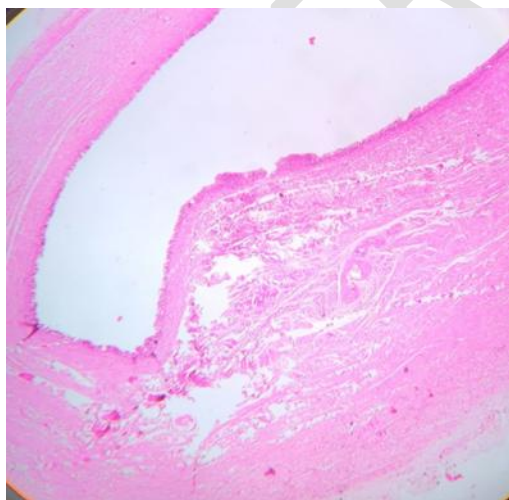
**TABLE 1: Specific Vs Non Specific Pathological Lesions.**

<b>PATHOLOGICAL LESIONS</b>	<b>NUMBER OF CASES (%)</b>
<b>Specific Pathology</b>	14(18%)
<b>Non Specific Pathology</b>	63(82%)

Among specific pathological lesions, the most common lesion was found to be ectopic pregnancy which constitutes about 46% of the total specimens and was mostly seen in the reproductive age group. Based on a study conducted by Ranji, et.al it was seen that many ectopic pregnancy cases were found in the age group of 26-30 <sup>[6]</sup>, which coincides with our data where many cases were found in the same age category as seen in Chart 2.

Para tubal cysts were the second most common lesions detected which constitutes 23% of the total specimens, compared to another study; which showed paratubal cysts in 13% of patients. <sup>[7]</sup>

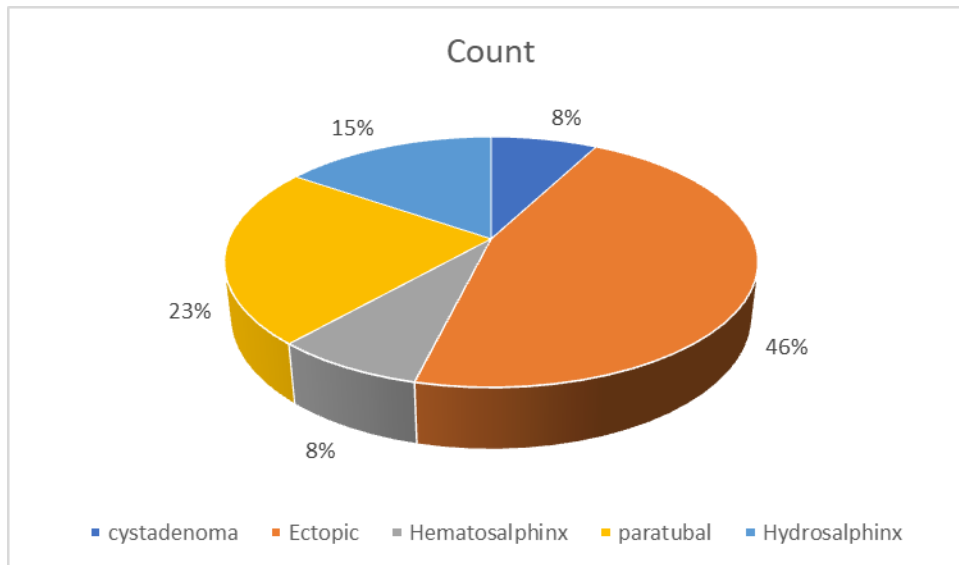
Hydro salpinx (Figure 1) constituted about 15% of the total specimens and all were unilateral (Picture from the pathology archives). Based on another study by Sharyn, et.al showed 18% had hydrosalpinx and were unilateral and very few were bilateral <sup>[8]</sup>. Hematosalpinx was found in about 8% of the specimens.



**FIGURE 1: H & E (10X) HYDROSALPINX- Section shows wall of fallopian tube with dilated lumen and atrophic plicae.**

Cystadenoma, being a benign tumor comprises about 8% of the total specimens and was the only tumor found in our study. Based on a study by, Stein R.J, et.al it was found that cystadenomas occur between the third and eighth decade<sup>[9]</sup> which coincides with our age group at which this lesion was found in the age group of 51-55.

**CHART 2: Spectrum of Pathological Lesions in Fallopian Tubes**



## CONCLUSION

After the study of the histopathological slides, the lesions of the fallopian tubes were found to be quite diverse. Being a small organ in our body, it is quite forgotten about its importance and lesions. But through this study we can observe many of the lesions found in the fallopian tubes. Most specimens were collected for confirmation of fallopian tubes after puerperal sterilization. The common histopathological lesions found were ectopic pregnancy. Cystadenoma was the incidental tumor found in this study. This study shows the importance of histopathological examination of all fallopian tube specimens with or without abnormal findings.

**ETHICAL APPROVAL:**All authors hereby declare that ethical approval was obtained from the Institutional Review Board.

## REFERENCES

1. Guan J, Watrelot A. Fallopian tube subtle pathology. *Best Pract Res ClinObstetGynaecol*. 2019;59:25-40. doi:10.1016/j.bpobgyn.2018.12.012
2. Visvanathan K, Shaw P, May BJ. Fallopian Tube Lesions in Women at High Risk for Ovarian Cancer: A Multicenter Study. *Cancer Prev Res (Phila)*. 2018;11(11):697-706. doi:10.1158/1940-6207.CAPR-18-0009
3. Mittal N, Srinivasan R, Gupta N, Rajwansi A. Secretory cell outgrowths, p53 signatures, and serous tubal intraepithelial carcinoma in the fallopian tubes of patients with sporadic pelvic serous carcinoma. *Indian J PatholMicrobiol* 2016;59:481-8
4. Geetika Goyal, Arati Inamdar , Abraham Loo. Adenomatoid Tumor in the Fallopian Tube - A Rare Case. *International Journal of Pathology and Clinical Research* 2019, 5:096 Volume 5 | Issue 2, DOI: 10.23937/2469-5807/1510096.
5. Vicus D, Finch A, Cass I, Rosen B, Murphy J. Prevalence of BRCA1 and BRCA2 germ line mutations among women with carcinoma of the fallopian tube. *GynecolOncol*. 2010 Sep;118(3):299-302. doi: 10.1016/j.ygyno.2010.05.011. Epub 2010 Jun
6. Ranji GG, Usha Rani G, Varshini S. Ectopic Pregnancy: Risk Factors, Clinical Presentation and Management. *J ObstetGynaecol India*. 2018 Dec;68(6):487-492. doi: 10.1007/s13224-017-1075-3. Epub 2017 Nov 18. PMID: 30416277; PMCID: PMC62075y
7. L Savelli , T Ghi, P De Iaco, M Ceccaroni, S Venturoli, B Cacciatore. Paraovarian/paratubal cysts: comparison of transvaginal sonographic and pathological findings to establish diagnostic criteria. *Ultrasound Obstet Gynecol*. 2006 Sep;28(3):330-4. doi: 10.1002/uog.2829
8. Katz SI, Ramchandani P, Torigian DA, Siegelman ES. Hydrosalpinx in patients with hysterectomy without salpingo-oophorectomy referred for pelvic magnetic resonance imaging. *Clin Imaging*. 2019 May-Jun;55:95-99. doi: 10.1016/j.clinimag.2018.12.008. Epub 2019 Jan 11. PMID: 30798017.

9. Stein, RG,Diessner, J, Hönig, A, Wischhusen, J, Dietl, J. Fallopian tube tumors: an overview Atlas Genet CytogenetOncolHaematol. 2013;17(11):773-787.

UNDER PEER REVIEW