

# INCIDENCE OF BENIGN AND MALIGNANT LESIONS OF BREAST

## **Abstract**

**BACKGROUND :** Breast carcinoma is second most common carcinoma in India . Breast carcinoma can have good prognosis when detected in an early stage , distinguishing and staging the disease can facilitate the opportunity of giving the best and appropriate treatment ultimately reducing the morbidity and mortality. The purpose of the study is analyzing the incidence of histopathological spectrum of breast lesion including both benign and malignant lesions of breast .

**AIM :** This research is aimed to assess the incidence of histopathological features of benign and malignant lesions of breast.

**METHOD :** It is a retrospective study of histopathological features of benign and malignant lesions of breast over the past two years in Saveetha medical college .The specimens were received in the pathology department's histopathology section. Fixation, comprehensive sampling, and tissue processing were performed after a complete physical evaluation of the specimens. The different lesions were evaluated and analysed . Neoplastic lesions were classified according to WHO categorization.

**RESULTS:** In our analysis, unilateral lesions were far more common (98%) than bilateral lesions. 144 (43.07 percent) of the 334 cases we received throughout the study period were benign, with fibro adenoma accounting for 75 (22.4 percent) of all instances and fibrocystic lesion accounting for the remaining cases of 24 (7.18%). Invasive ductal carcinoma, which accounted for 140 instances of malignancy, was the most prevalent (41.9 percent ).The range

of age of cases are from 14 years to 77 years .The prevalence of benign lesions was highest in the 15–30 year age group. Among 334 cases , 315 were females and 19 were male .

**CONCLUSION:** Differentiating benign from malignant tumours relies heavily on histopathology. It is critical to conduct breast cancer awareness studies, screening programmes, and basic training and incentive for women to seek medical attention as soon as a breast lump is palpated, as this can lower the morbidity and mortality associated with breast tumours.

**KEYWORDS:** Breast , fibroadenoma , invasive ductal carcinoma .

#### **BACKGROUND :**

The breast is a modified sweat gland made up of epithelial and connective tissue components. As a result, breast neoplasms must be classified independently. <sup>1</sup> Breast cancer is the second most frequent cancer among women. The prevalence ranges from 19 to 34 percent. The average age is 47 years old. It's more common around middle age, but it can happen to anyone over the age of 20. Breast cancer usually manifests as a firm, painless lump in the breast that is at least 1cm clinically palpable. The second most common symptom is nipple discharge , some cases can present with ulceration , fungation , axillary lymph node enlargement , chest pain , hemoptysis ,bone pain and tenderness. Breast neoplasms are diverse. Breast cancer is less common than benign tumours. Breast benign lesions typically appear in the second decade of life. Fibroadenoma, phyllodes tumour, lactating adenoma, and

tubular adenoma are all common benign breast lesions. Fibrocystic disease, inflammatory lesions such as breast abscess, and granulomatous mastitis are all examples of benign proliferative lesions. Ductal carcinoma, lobular carcinoma, colloid carcinoma, mucinous carcinoma, and medullary carcinoma are cancerous lesions. Early diagnosis is very important and it includes mammography, ultrasound of breast, fine needle aspiration cytology, corecut/truecut/frozen section/excision biopsy/edge biopsy, MRI and PET scan. The risk of conversion of benign tumour into malignant should always be kept in mind and never forgotten. The very first thing is to exclude or rule out malignancy when a woman presents with signs of breast lesion. In the investigations histopathology plays a very important role. The study's goal is to determine the histological spectrum and prevalence of breast lesions, as well as to analyse, highlight, and identify them.

#### METHODS:

A retrospective study was conducted in the department of Pathology, Saveetha Medical College, Chennai on 334 cases in the last two years (2019 and 2020). The sample size was taken based on the convenience of the study. All mastectomy specimens and wide local excision specimens which were received for histopathological examination suspected for neoplastic and non-neoplastic lesions of the breast during the study period were included in the study. Among the 334 specimens, majority of the specimens were those of lumpectomy specimens and a few specimens were mastectomy specimens. All the specimens of breast which were received in Pathology department in different forms such as excisional biopsy, lumpectomy and mastectomy were processed by standard protocol and formalin fixed paraffin embedded tissue sections stained with haematoxylin and eosin were studied and

assessed. The histopathological features were noted, and the tumours were diagnosed on the basis of WHO classification.<sup>2</sup>

## RESULTS:

The range of age of cases are from 14 years to 77 years . The benign lesions were seen to be highest in the age groups of 15 – 30 years .Among 334 cases , 315 were females and 19 were male (chart 1) . In our research, unilateral lesions were far more common (98 percent) than bilateral lesions. 144 (43.07 percent) of the 334 cases received during the research period were benign, with fibro adenoma accounting for 75 (22.4 percent) of all cases and fibrocystic lesion accounting for 24. (7.18 percent) . Invasive ductal carcinoma, accounting for 140 of the 190 malignant cases, was the most prevalent (41.9 percent )(chart 2).

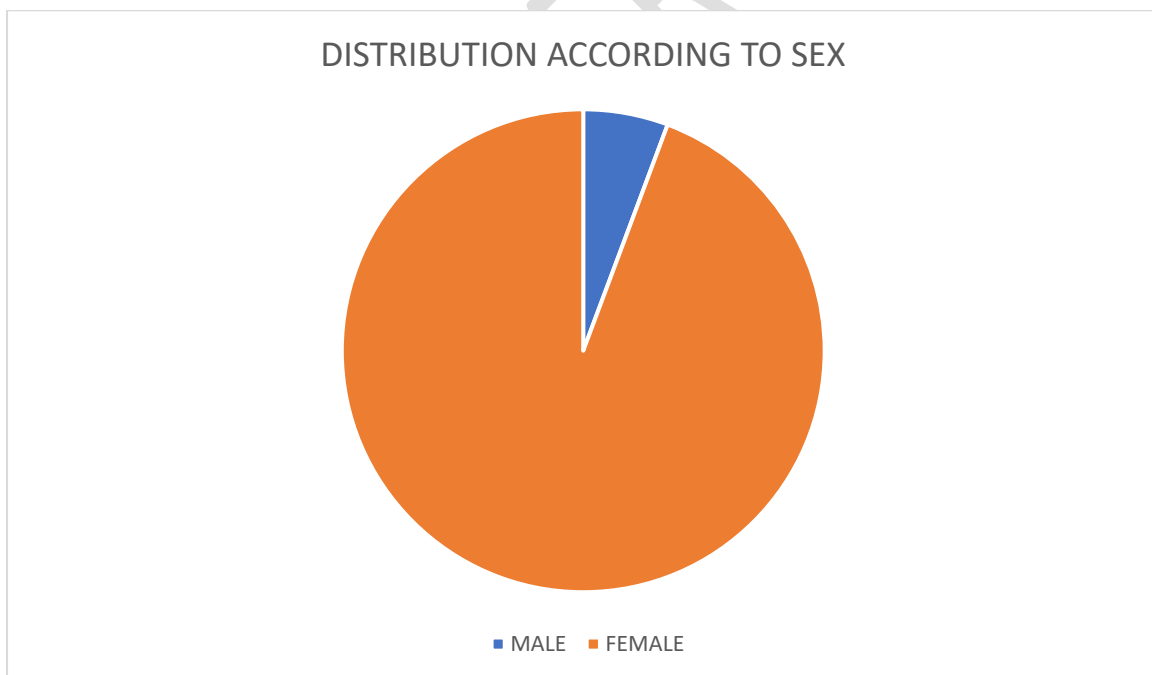


CHART 1 DISTRIBUTION ACCORDING TO SEX

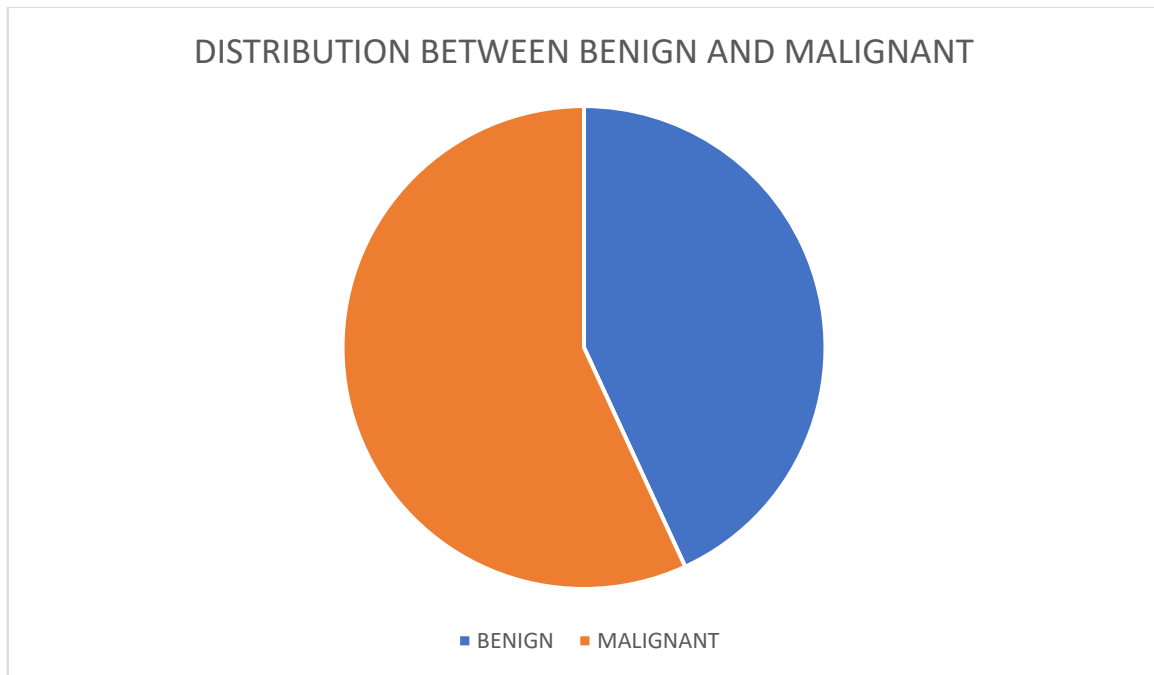


CHART 2 DISTRIBUTION BETWEEN BENIGN AND MALIGNANT

The most prevalent benign case was fibro adenoma, which accounted for 75 (22.4 percent) of the 144 benign cases. The majority of the patients were seen in the 15-30 year old age group and presented as a unilateral breast lump. The second common was fibrocystic lesion accounting for 24 (7.18%) followed by granulomatous mastitis accounting for 19 (5.68%) .Breast abscess accounting for 14 cases (4.19%) , followed by fibroadenosis 9 cases (2.69%) . Phylloides tumour and Epidermal cyst accounting for 6 (1.79%) . 5 cases (1.49%) of ductal hyperplasia was seen , 3 cases (0.89%) of epithelial hyperplasia , 2 cases (0.59%) of galactocele and 4 cases (1.19%) of hamartoma. And 1 case (0.29%) in each of fat necrosis , fibroepithelial polyp, lactating adenoma and ductal ectasia . And we could also see 9 cases of gynecomastia accounting for (2.69%) among which one was a bilateral lesion.(table 1)

Among 190 neoplastic cases ,Invasive ductal carcinoma is the most frequent, accounting for 140 cases (41.9 percent ).Followed by mucinous carcinoma accounting for 2 (0.59%) . 1 case (0.29%) in each of invasive papillary carcinoma and liposarcoma .. Invasive ductal carcinoma was the most prevalent malignant lesion in the breast.(table 2)

BENIGN	NO OF CASES
Fibroadenoma	75 (22.4%)
Fibrocystic disease	24 (7.18%)
Granulomatous mastitis	19 (5.68%)
Breast abscess	14 (4.19%)
Inflammatory lesion	10 (2.99%)
Gynaecomastia	9 (2.69%)
Fibroadenosis	9 (2.69%)
Epidermal cyst	6 (1.79%)
Phylloidstumour	6 (1.79%)
Ductal hyperplasia	5 (1.49%)
Hamartoma	4 (1.19%)
Epithelial hyperplasia	3 (0.89%)
Galactocele	2 (0.59%)
Fat necrosis	1 (0.29%)
Ductal ectasia	1 (0.29%)
Fibroepithelial polyp	1 (0.29%)
Lactating adenoma	1 (0.29%)

Table 1 Gynaecomastia accounting

MALIGNANT	NO OF CASES
Invasive ductal carcinoma	140 (41.9%)
Mucinous carcinoma	2 (0.59%)
Invasive papillary carcinoma	1 (0.29%)
Liposarcoma	1 (0.29%)

Table 2 Invasive ductal carcinoma

DISCUSSION :

The breast tissue is made up of a unique epithelium and stroma that can transform into benign or malignant diseases.<sup>3</sup>

In our present study , among 334 specimens the incidence of females is higher than male and similar results were seen in Smitapudale et al and Bhavani et al.<sup>4,5</sup>

By conducting research, Smitapudale et al and Sasank et al correlated with findings in our study in which unilateral lesions had higher incidence than bilateral lesions .<sup>4,6</sup>

Out of 144 benign cases in our study ,the most prevalent was fibro adenoma, which accounted for 75 cases (22.4 percent), with the majority of cases occurring in the 15-30 year old age group and presenting with unilateral breast lump. Fibroadenoma was the commonest benign lesion in many other studies .<sup>2,3,4,1,7</sup>

The second most common benign lesion in our study is fibrocystic disease , when compared with other studies similar result was observed in Letha padmom et al , Smitapudale et al, Bhavani et al and Mir Attaullah Khan et al.<sup>2,4,5,7</sup> Mir Attaullah Khan et al has given explanation for its importance due to its high frequency and mimicking, the clinical and radiographic appearance of carcinoma by some of its sub types.

According to SmitaPudale et al ,Galactocele is a condition that primarily affects women of reproductive age. All of the girls in this study were between the ages of 20 and 30, and they were all lactating. Galactocele is caused by inspissated milk in women who have started lactation and then abruptly stopped.<sup>4</sup>

In this research, we looked into the incidence of phylloidstumour accounted for 1.79% , similar incidence was seen in studies of Yogalakshmi et al and Sahil i. Panjvani et al .<sup>3,8</sup>

In general, phyllodes tumour accounts for 2–3% of all fibroepithelial breast disorders, with a peak incidence in perimenopausal age or before the age of 20. The lesion exhibits a

pathognomonic intraductal development of intralobular stroma with leaf-like projections (phyllodes leaf).<sup>3</sup>

In this investigation, gynaecomastia was found to be 2.69 percent. Smitapudale et al also studied gynaecomastia in their study and the incidence was 2% similar to the present study. And also Bhavani et al studied gynaecomastia and the incidence was 4.3%.<sup>4,5</sup>

Smitapudale et al also studied a case of hamartoma and the incidence was 0.18% and on comparing with the present study hamartoma has a higher incidence accounting to 1.19%. Microscopically, Hamartoma was a mass of mammary ducts and lobules with varying amounts of fibrous and adipose tissue that was well circumscribed. There were additional patches of smooth muscle and myxoid.<sup>4</sup>

All other benign lesions have an incidence less than 1% similar to that of Letha Padmom et al.<sup>2</sup>

Invasive ductal carcinoma is the most frequent neoplasm, accounting for 140 (41.9%) of the 190 cases. In studies by Letha Padmom et al and Nazmun Nahar et al, invasive ductal carcinoma was likewise the most prevalent malignant lesion.<sup>2,9</sup> It has a significant mortality rate due to its localised invasion, lymph node dissemination, and distant metastases.

Carcinoma of the invasive form is frequently associated with a poor prognosis.<sup>2</sup>

In the present study, Papillary and Mucinous carcinoma was also studied and had an incidence of 0.29% and 0.59% respectively. Nishita M Ghodasara et al also studied papillary and mucinous carcinoma the results were similar to the current research.

Sahil i. Panjvani et al also looked into a case of sarcoma and incidence was 0.45% comparable to the present study with an incidence of 0.29%.

Epithelial hyperplasia studied in Dr. Shailendra Yadav et al has an incidence of 0.6% nearly close to the incidence of the present study.<sup>10</sup>

## CONCLUSION:

The most prevalent benign lesion in this study is fibro adenoma, with the majority of occurrences occurring in people between the ages of 15 and 30 and presenting with unilateral breast lump. The second common was fibrocystic lesion . Invasive ductal carcinoma was the most prevalent type of malignancy. Among 334 cases , 315 were females and 19 were male . In our analysis, unilateral lesions were far more common (98%) than bilateral lesions.

Along with mammography, MRI, and FNAC findings, histopathology plays a significant role in the diagnosis and treatment of breast illness.<sup>11</sup> All cases of breast lesions should be thoroughly investigated to rule out the risk of breast cancer at an early and treatable stage .<sup>7</sup>

Staging of the malignant lesions is helping in assessing the patient's risk and appropriate management can be provided in each case which includes local , regional and systemic management .<sup>6</sup>

As a result, it is critical to perform breast cancer awareness studies, screening programmes<sup>12</sup>, and basic training and motivation for women to report any breast lump discovered on palpation to a doctor as soon as possible, in order to prevent the morbidity and mortality associated with breast tumours.<sup>13</sup>

## REFERENCE :

1. Nishita M Ghodasara, Chetan Dharaiya, Jignasa Bhalodia . Histopathological study of distribution of non-neoplastic and neoplastic lesions in breast 2019;4(3):259-264.
2. Letha Padmom, Kiran Sapru, Devi Beena . Histopathological Spectrum of Breast Lesions - A Study Done in a Tertiary Care Hospital 2020;9(17): 2278-4748.

3. S. Yogalakshmi, M. Kavitha . A Study of Histopathological Spectrum of Breast Lesions 2019 ;7(1):1-5.
4. SmitaPudale, Sachin Digambar TonapeSmitaPudale,Sachin Digambar Tonape . A histopathological study of non-malignant breast lesions 2015 Oct;3(10):2672-2676.
5. Dr. C Bhavani, Dr. M Neeraja and Dr. P Sravani . A study of histopathological spectrum of breast lesions in a tertiary care hospital 2019; 2(2): 356-360.
6. R. Sasank, Annapurna Parvatala. A Histopathological Study of Malignant Lesions of the Breast In a tertiary Care Centre 2018; 5(07): 3955-3958.
7. Mir Attaullah Khan, Hamidullah Shah, Khalid Javed.Histopathological pattern of 230 benign female breast lesions at a tertiary care hospital of Peshawar 2016;9(1):128-131.
8. Sahil i. Panjvani, Biren j. Parikh, Swati B. Parikh, Bhawana r. Chaudhari, kazoomi k. Patel, Garima S. GuPta, aShka h. kodnani, Garima m. anandani . Utility of Fine Needle Aspiration Cytology in the Evaluation of Breast Lesions 2013 Dec, Vol-7(12): 2777-2779.
9. Nazmun Nahar, Mohammed Iqbal, Kazi Md. Shahidur Rahman, Md. Abdullah Yusuf, Shahed Iqbal, Shahana Hossain . Histopathological Study of Malignant Neoplasm of Breast of Different Age and Sex Groups In a Tertiary Care Hospital 2018;5(2):42-44.
10. Dr. Shailendra Yadav and Dr. YashikaJaiswal . A clinicopathological study of non-neoplastic and neoplastic lesions of breast in rural hospital y 2020; 3(1): 25-29.
11. Kavita Sharma, S. P. Vyas, Subhash Dhayal.Clinical and histopathological correlation of breast lesions 2018 Apr;6(4):1348-1355.
12. GogoiGeetanjali ,BorgohainDiganta . Histopathological spectrum of breast lesions 2015;2(1):73-78.

13. Arunima mukhopadhyay, Suklanaskar, ramprasaddey, keyabasu . Female Breast Lesions – A Five Year Study in a Tertiary Care Centre 2017 Jan;Vol-6(1):SO10-SO1410  
Arunima mukhopadhyay, Suklanaskar, ramprasaddey, keyabasu . Female Breast Lesions – A Five Year Study in a Tertiary Care Centre 2017 Jan;Vol-6(1):SO10-SO1410.

UNDER PEER REVIEW