

Study Protocol

Broadening the scope and utility of frontal sinus morphology for predicting the growth pattern and skeletal malocclusion in Cleft Lip and Palate cases.

Abstract:

- Introduction - The three dimensionally affected growth and development of craniofacial structures in CLCP leads to problems dealing with facial appearance, skeletal and dental malocclusion, feeding, airway, hearing, and speech.
- Objectives - Evaluation and utilisation of fs morphology as a forecast of future growth for growth pattern and skeletal malocclusion in CLCP cases.
- Methodology–A 30 Cases from Skeletal Class I, III and CLCP will be selected from Department of Orthodontics. Dimensions and area of frontal sinus is evaluated using 3DVT. Parameters are evaluated in sagittal and coronal section. The measurement's dependability will be determined using a reliability test (Cronbach alpha test). Chisquare Test, One Way ANOVA, and Multiple Comparison will be used to do descriptive and analytical statistics. The Tukey Test is a statistical test that is used.
- Expected Results - Frontal sinus dimensions when observed for Class III will be found greater. Average dimensions will be observed for skeletal Class I cases. Based on the dimensions of frontal sinus observed in cleft lip and palate, we can predict the skeletal malocclusion and growth pattern.
- Conclusion - The morphology of the fs is evaluated in cleft cases for the upcoming growth pattern and skeletal malocclusion if is known during formulating a treatment plan for the three dimensionally affected jaw bases and craniofacial structure the requirement for later surgical intervention can be prevented.
- Keywords – CLCP, FS, Skeletal Class III and Growth pattern.

Introduction -

Cleft lip and palate (CLCP) is a common congenital defect anomaly of craniofacial structure and 2nd most common after club foot. The three dimensionally affected growth and development of craniofacial structures in CLCP leads to problems dealing with facial appearance, skeletal and dental malocclusion, feeding, airway, hearing, and speech.

Early prediction of upcoming growth and development is very crucial in cases with CLCP, as the orthodontic and surgical treatment is extensive, which begins at infancy and lasts until the craniofacial skeletal growth is completed in adulthood. In terms of team management, with the goal of comprehensive case rehabilitation, the Orthodontist's role in timing and sequencing of therapy is critical to improvise treatment outcome with minimal interventions and long term retention for which it is important to predict the growth in cases with CLCP.⁽¹⁾

Researchers have spent many years trying to uncover several markers / growth predictors that can predict future skeletal growth in children. Malgorzata(2) employed classic growth predictors such height, weight, menarche, chronological age, dental age, and skeletal maturity indicators. Amongst these, skeletal maturity has gained attention of many researcher as being a reliable indicator. The ossification of the hand and wrist bones, the maturation of the cervical vertebrae, and the assessment of the phalanges are all part of skeletal maturity of middle finger with additional radiographic exposure in growing cases along with all the essential diagnostic aids. In order to avoid this additional radiation exposure, Lamparski(3-6) (7) suggested, lateral cephalogram is mandatory for craniofacial evaluation as a pre-orthodontic treatment record, the cervical vertebrae should be considered over other to evaluate and correlate the skeletal maturation. Very few parameters like maxillary sinus, frontal sinus, Torg's ratio⁽⁸⁾, etc are available to predict the upcoming skeletal malocclusion and the growth pattern. Amongst these the frontal sinus is easily visible on the lateral cephalograph.⁽⁹⁾ Therefore, Frontal sinus was observed on lateral cephalogram for cleft lip and palate cases. With this rationale a hypothesis was planned to evaluate and utilize the association of Frontal Sinus with upcoming skeletal malocclusion and growth pattern in cleft cases, so as to plan the treatment accordingly.

Frontal sinus morphology can be reliable and useful parameter in predicting the growth pattern and skeletal malocclusion in CLCP cases to plan the treatment accordingly.

RESEARCH QUESTION – PICOT FORMAT

Can we use frontal sinus morphology to predict growth pattern and skeletal malocclusion in cleft lip and palate cases?

- P – CLCP cases
- C – Non CLCP cases
- O – Evaluation of fs morphology to predict growth pattern and skeletal malocclusion.
- T- 1 year

Aim

The purpose of this study was to see if frontal sinus morphology could be used as a predictor of growth pattern and skeletal malocclusion in CLCP patients.

Objectives –

1. To assess the anatomy of the fs in cleft lip and palate patients.
2. To assess the anatomy of the fs in Skeletal Class III malocclusion cases.
3. To assess the fs morphology in patients with Skeletal Class I malocclusion.
4. To examine the anatomy of the fs and growth pattern in patients with cleft lip and palate Skeletal Class III malocclusion against Skeletal Class I malocclusion.

Material and Methods

After receiving approval from the Institutional Research Ethics Committee of DattaMeghe Institute of Medical Sciences, Deemed University, the study will be conducted at Sharad Pawar Dental College in collaboration with the Department of Radiology at Acharya VinobhaBhave Rural Hospital (AVBRH), DMIMS, Sawangi (M), Wardha.

Sample size calculation

$$n_2 = \frac{(K * \sigma_1^2 + \sigma_2^2)(Z_{1-\alpha/2} + Z_{1-\beta})^2}{\Delta^2}$$

The notation for the formulae are:

n_1 = sample size of Group 1

n_2 = sample size of Group 2

σ_1 = standard deviation of Group 1

σ_2 = standard deviation of Group 2

Δ = difference in group means

K = ratio = n_2/n_1

$Z_{1-\alpha/2}$ = two-sided Z value (eg. Z=1.96 for 95% confidence interval).

$Z_{1-\beta}$ = power

The sample size formulae used are as follows:

$$n_1 = \frac{(\sigma_1^2 + \sigma_2^2 / K)(Z_{1-\alpha/2} + Z_{1-\beta})^2}{\Delta^2}$$

The average size of the FS in group A2 = 264.1

The average size of the FS in group A4 = 356.6

σ_1 = SD of area of FS in group A2 = 70.1

σ^2 =SD of area of FS in group A4=73.2

For detecting mean difference of 1 $\Delta=356.6 - 264.1 = 92.5$

$N=(70.1*70.1 + 73.2*73.2)(1.96+0.84)^2/(92.5*92.5)$

= 9.41 = 10 cases required in each group.

Reference :RakeshNathani et al

Power of the test: 80%

Confidence Interval: 95%

Side of the test: Two-sided

Statistical Test: Chisquare Test, One way ANOVA and Multiple Comparison: Tukey Test

Software used: SPSS 24.0 version and GraphPad Prism 7.0 version

Formula Reference: Dr Sanjay Zpdpey et al, Sample size considerations in medical research, GMC, Nagpur, August 20-22,1999.

The estimated samples necessary per group were 10 to obtain statistical differences between the groups with 95% confidence (alpha 80%), power of the test, and two-sided hypothesis (means are different across groups).

The cases which have visited in the departmental OPD and smile train unit will be selected based on the inclusion criteria and segregate in three groups accordingly.

Group 1 -10 cases with skeletal class I malocclusion.

Group 2 -10 cases with cleft deformity.

Group 3 -10 cases with skeletal class III malocclusion.

Inclusion criteria -

1. Data available of CLCP cases examined will be in the range of 10-16 yrs.
2. Skeletal class I and Class III cases with maxillary deficiency.

Exclusion criteria -

1. Cleft cases whose orthodontic intervention has been done.

2. Syndromic cases.

Method

Digital volume tomography images which are already obtained will be selected for the study. Three dimensional (3D) images, as well as, multiplanar reconstruction (MPR) images will be sectioned (slice thickness 3mm) using 3D RA software at the computer work station.

For each case, 2 parameters were evaluated.

1. Sagittal section evaluation of frontal sinus morphology ,Both the 3DVT and the lateral cephalogram are used.
2. Coronal section evaluation of frontal sinus morphology.

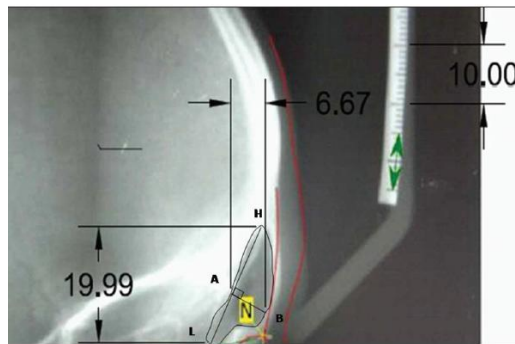


Figure No. 1 – anatomy of the FS in sagittal section.

The FS peripheral border will be carefully traced.

S – Indication of Sagittal section.

C - Indication of coronal section.

Boundaries of frontal Sinus –

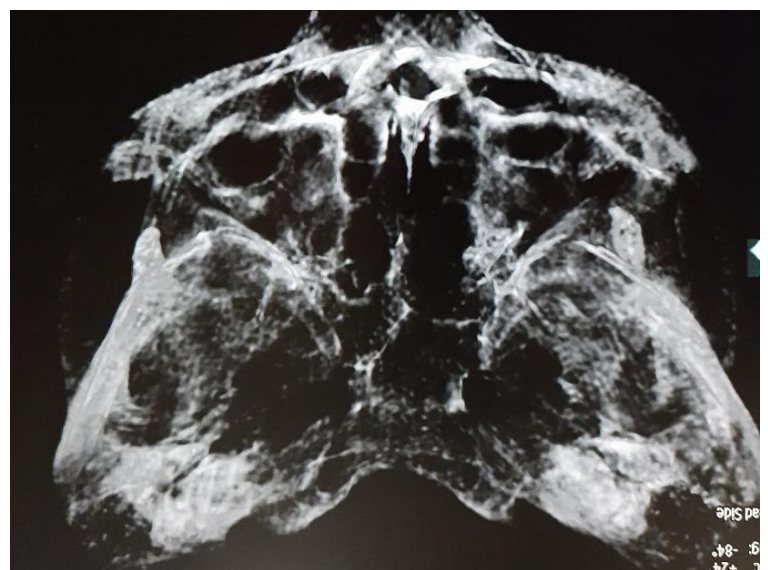
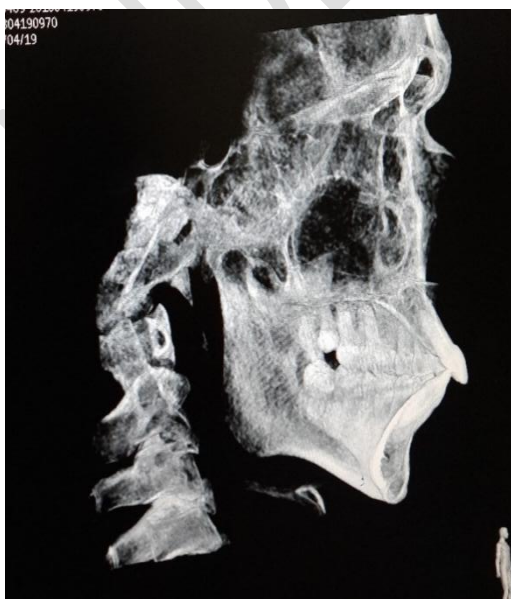
Figure No. 2 – In a sagittal section, the anatomy of the FS is examined. (section 3DVT)

Figure No. 3– In a coronal section, the morphology of the FS is examined. (section 3DVT)

The peripheral border of frontal sinus will be traced and following points will be marked.

H - The height of the FS will be measured from the highest point of sinus extension.

L – The height of the FS will be measured from the lowest point of sinus extension.

HL - Draw a perpendicular line to the height of the sinus.

MW - Maximum width of the frontal sinus.

A - The FS are located here. Multiplying the frontal sinus's height and width ($HL \times MW$). This will be calculated in sagittal and coronal section. To analyse the sections, Digital volume Tomography will be used.

Same method will be followed for lateral cephalogram to determine the size of the FS in sagittal section. Same marking points will be used as used in Digital volume Tomography.

To reduce measurement error and provide an unbiased assessment will be done by the same examiner every two weeks. Mean of the observation of three readings will be taken for further analysis. The measurements will be done in millimetres. These readings will then be entered on Microsoft Excel sheet (version 2019 16.0.6742.2048).

The measurement's dependability will be determined using a reliability test (Cronbach alpha test). Chisquare Test, One Way ANOVA, and Multiple Comparison: Tukey Test will be used to do descriptive and analytical statistics.

Study design – Study design is cross-sectional and observational. (Retrospective)
Expected Results/ Outcomes –

As the growth in CLCP is retarded, therefore this hampers growth of FS. Therefore, dimensions of cleft lip and palate are reduced in comparison to skeletal Class III and Class I. As in Class III cases, it is found that mandible is prognathic and maxilla is retrognathic. But, skeletal Class III cases with maxillary deficiency will be observed. FS dimensions when observed for Class III will be found greater. Average dimensions will be observed for skeletal Class I cases. Based on the dimensions of frontal sinus observed in CLCP, we can predict the skeletal malocclusion and growth pattern.

Discussion –

The FS are anterior ethmoidal cells that evaginate directly from the frontal recess to the frontal bone. These are two irregular spaces between the two tables of the skull that extend backward, upward, and laterally for a variable distance; they are separated from one another by a thin bone septum. They aren't present at birth, but they emerge as the child grows older.⁽¹⁰⁾

In the second year, the FS begins to spread vertically and laterally to the orbital roof. It is discovered during the fifth year of life and is visible on radiographs by the age of eight. Tanner proposed that annual increments in children's height growth hit a plateau at 16 years for boys and 14 years for girls, and that expansion of the frontal sinuses stopped at this age.. By the age of 20, the development of the frontal sinus is complete, and the chambers stay stable until bone remodelling causes further growth of the chambers. (10)

The FS, which is evident on a lateral cephalogram, was examined and validated by Ruf and Pancherz(11). Somatic maturity is linked to the development of the FS. The frontal sinus can also be employed as a diagnostic indication, allowing the Orthodontist to make more precise skeletal connection predictions. Furthermore, Rossouw et al.(12) indicated that the frontal sinus on a lateral cephalogram is a useful sign for determining the direction of mandibular growth, implying skeletal malocclusion and growth pattern. Nathani et al.(13) found a substantial difference in the morphology of the frontal sinus among various development patterns and concluded that the frontal sinus can be a good predictor for growth pattern assessment.

If the individual is having any with skeletal malocclusion and if it can be diagnosed early, the further complication with skeletal malocclusion can be avoided. Moreover, surgical treatment can be circumvented and severity of malocclusion can be reduced, which can further benefits cases in financial and psychological aspect.

As the maxilla is affected in three dimensional planes in the CLCP cases the mandible sets free to grow towards a concave profile with anterior divergence suggesting class III feature with retrognathic maxilla, a prognathic mandible, or a combination of both. Skeletal class III is mostly because of prognathic mandible but this may not always be true for cleft cases, as in cleft, the maxilla is deficient and affected with consequent effects seen in the mandible.⁽¹⁴⁾

The etiology of a skeletal class III in general and skeletal class III in CLCP cases is totally different. There are numerous confounding factors that develops a skeletal Class III

pattern in CLCP cases. The growth pattern may not correlate with the skeletal malocclusion in CLCP as it does with the skeletal Class III cases.

As a result, a study was designed that would use frontal sinus morphology to predict CLCP growth and malocclusion.

Conclusion -

The morphology of the FS is evaluated in cleft cases for the upcoming growth pattern and skeletal malocclusion if it is known during formulating a treatment plan for the three dimensionally affected jaw bases and craniofacial structure the requirement for later surgical intervention can be prevented, this will further improve patients esthetics which is financially and psychologically advantageous for the patients.

Biobibliography –

1. Vig KW, Mercado AM. Overview of orthodontic care for children with cleft lip and palate, 1915-2015. *American journal of orthodontics and dentofacialorthopedics*. 2015 Oct 1;148(4):543-56.
2. Malgorzata M, Tiziano B. Duration of pubertal peak in skeletal Class I and Class III subjects. *Angle Orthod* 2010; 80: 54-57.
3. Cavanese F, Charles YP, Dimeglio A. Skeletal age assessment from elbow radiographs Review of the literature. *Chi OrganiMov* 2008; 92:1-6.
4. Chen LL, Min-Xu T, Jiang JH, Zhang XZ, Lin JX. Quantitative cervical vertebral maturation assessment in adolescents with normal occlusion: a mixed longitudinal study. *Am J OrthodDentofacialOrthop* 2008; 134(6):720.e1-720.e7.
5. Grave KC, Brown T. Skeletal ossification and the adolescent growth spurt. *Am J Orthod* 1976; 69: 611- 619.
6. Brown WA, Molleson TI, Chinn S. Enlargement of the frontal sinus. *Ann Hum Biol* 1984; 11: 222-226.
7. Lamparski D. Skeletal age assessment utilizing cervical vertebrae. University of Pittsburgh, Pennsylvania 1972.
8. Pavlov H, Torg JS, Robie B, Jahre C. Cervical spinal stenosis: determination with vertebral body ratio method. *Radiology*. 1987 Sep;164(3):771-5.
9. Rossouw PE, Lombard CJ, Harris AM. The frontal sinus and mandibular growth prediction. *American Journal of Orthodontics and DentofacialOrthopedics*. 1991 Dec 1;100(6):542-6. Nathani R, Diagavane P, Shrivastav S, Kamble R, Gupta D, Korde S.

Evaluation of frontal sinus as a growth predictor in horizontal, vertical, and average growth pattern in children from 8 to 11 years: A cephalometric study. *J Indian OrthodSoc* 2016;50:101-5.

10. Maresh MM. Paranasal sinuses from birth to late adolescence. *Am. J. Dis. Child.* 1940;60:55-78.
11. Ruf S, Pancherz H. Development of the frontal sinus in relation to somatic and skeletal maturity. A cephalometric roentgenographic study at puberty. *Eur J Orthod* 1996;18: 491-497.
12. Rossouw PE, Lombard CJ, Harris AMP. The frontal sinus and mandibular growth prediction. *Am J OrthodDentofacial Orthop.*1991; 100: 542-546.
13. Nathani R, Diagavane P, Shrivastav S, Kamble R, Gupta D, Korde S. Evaluation of frontal sinus as a growth predictor in horizontal, vertical, and average growth pattern in children from 8 to 11years: A cephalometric study. *J Indian OrthodSoc* 2016;50:101-5.
14. Valverde Y, Watanabe N, Yamaki M, Saito I. The frontal sinus enlargement as an indicator of growth maturity in class III patients-A pilot study. *Int J Med Sci Public Health.* 2013 Apr 1;2:451-5.

Figure No. 1 – In a sagittal section, the anatomy of the frontal sinuses is examined.

Figure No. 2 – In a sagittal section, the anatomy of the frontal sinuses is examined. (section 3DVT)

Figure No. 3– In sagittal section, the morphology of the frontal sinuses is evaluated. (3DVT Section)