

# Original Research Article

## Ameliorating Effects of *Solanum anomalum* Thonn. Ex. Schumach Fruit Extracts on Paracetamol-induced Kidney Injuries and Haemato-biochemical Indices in Rats.

### ABSTRACT

Paracetamol (acetaminophen) is a widely used non-opioid analgesic and antipyretic drug that is safe at therapeutic doses but toxic to the liver and kidneys in overdose. Although the risk of paracetamol-induced liver injury is much higher than in the kidneys, incidents of kidney damage by paracetamol should not be ignored, given the enormous cost of treating kidney diseases, particularly in resource-challenged developing nations. In an onerous quest for a cheaper and readily available antidote, this study examined the effect of *Solanum anomalum* fruit extract on paracetamol-induced kidney injuries and haemato-biochemical indices in rats. Twenty-five mature albino rats of both sexes were used, divided into five groups of five rats per group. Group 1 (normal control) rats were given distilled water (10ml/kg) for 8 days, group 2 (negative control) given distilled water (10 ml/kg) for 8 days, group 3 (positive control) given 100 mg/kg Silymarin for 8 days, group 4 given 452 mg/kg of *S. anomalum* fruit extract for 8 days, and group 5 given 678 mg/kg of *S. anomalum* fruit extract for 8 days. Thereafter, 2.0 g/kg of paracetamol was administered to groups 2-5 orally on the 8th day. Rats in group 2 showed significant increases in urea, creatinine, sodium ion, total WBCs, PCV, Hb concentration and RBCs. Administration of *Solanum anomalum* fruit extract significantly reversed most of these biomarkers. Histopathology of the kidneys also points to the mitigating effect of *Solanum anomalum* fruit against paracetamol-induced nephrotoxicity.

**Keywords:** Paracetamol, acetaminophen, kidney, *Solanum anomalum*, hepatotoxicity.

### 1. INTRODUCTION

Paracetamol (Acetaminophen or N-acetyl-para-aminophenol) is a widely used analgesic and antipyretic drug that is safe at therapeutic doses [1]. However, in overdose, it is associated with kidney and liver injuries [2-4]. Paracetamol overdose results in the formation of a toxic intermediate metabolite known as N-acetyl p-benzoquinone imine, NAPQI [5]. This toxic metabolite forms covalent adducts with cellular proteins of the kidney, leading to the production of reactive oxygen species (ROS). NAPQI also

interacts with sulfhydryl groups in the glutathione (GSH) molecule, leading to depletion of cellular stores of glutathione [6-7]. The resultant oxidative stress enhances apoptosis, including renal necrosis [8-10]. In addition, some amounts of NAPQI cause lipid peroxidation which may ultimately result in acute renal failure [11-13].

Several medicinal herbs are known to alleviate kidney injuries [14]. Hence, natural compounds with antioxidant activity potential may be employed as alternative treatments for paracetamol poisoning [15]. The plant, *Solanum anomalum* Thonn. Ex. Schumach, also known as Children's tomatoes about 2 meters in height, having prickles on stem, branches and midrib of the leaves. The fruit of *Solanum anomalum* is a ball-shaped berry, shiny red when mature and green when young [16]. *Solanum anomalum* fruit extract has been reported to have anti-diabetic activity [16], mitigate lead-induced testicular injury [17], and show protection against lead-induced liver and kidney injuries [18]. *Solanum anomalum* fruit contains phytochemicals such as alkaloids, saponins, cardiac glycosides, terpenes, flavonoids, tannins and anthraquinones [16]. In this study, we examined the effects of *Solanum anomalum* fruit extract on paracetamol-induced kidney injuries and haemato-biochemical indices in rats.

## **2. METHODS**

### **2.1 Collection and Identification of Plant Material**

Fresh fruits of *Solanum anomalum* were obtained from a farmland in Obot Ndom Itumbonuso village, Ini Local Government Area of Akwa Ibom State, Nigeria. The plant was identified and authenticated by Professor Margaret E. Bassey, a plant taxonomist in the Department of Botany and Ecological Studies, University of Uyo. Plant specimen with voucher number UUH: No 75(a) was deposited in the Herbarium of the Department of Pharmacognosy and Natural Medicine, Faculty of Pharmacy, University of Uyo, Nigeria.

### **2.2 Preparation and Extraction**

The fruits were separated from the stalk, air dried under room temperature for 3 weeks, and then powdered using pestle and mortar. The extract was prepared by maceration of

the air-dried, powdered fruits of *S. anomalum* using 60% ethanol in distilled water (v/v) in an extracting jar. The set up was allowed to stand for 72 hours with occasional shaking. The extract was filtered, concentrated until constant weights were achieved, then stored in a refrigerator at 2-8°C. The procedure was repeated 3 times for maximal extraction.

### **2.3 Experimental Animals**

A total of 25 rats of both sexes, weighing (131-189 g) were obtained from the animal house of the Department of Pharmacology and Toxicology, Faculty of Pharmacy, University of Uyo. They were maintained on standard animal pellets and water *ad libitum*, housed in cages to acclimatize to the animal house, and maintained under standard conditions (25- 28 °C) with 12h dark/12h light cycles.

### **2.4 Experimental Designs**

The experimental rats were divided into six groups consisting of five rats per group. Rats of each group were orally pre-treated as follows:

Group 1 (normal control): Given distilled water (10ml/kg) for 8 days

Group 2(negative control): Also given distilled water of 10 mL/kg for 8 days

Group 3 (positive control): Given 100 mg/kg Silymarin (standard drug) for 8 days.

Group 4: Given 452 mg/kg of *S. anomalum* fruit extract for 8 days.

Group 5: Given 678mg/kg of *S. anomalum* fruit extract for 8 days.

Thereafter, 2.0g/kg of paracetamol was administered to groups 2-5 orally on the 8th day.

Oral administration was carried out using a rubber cannula attached to a calibrated syringe. Twenty-four hours after paracetamol administration, blood samples were collected for biochemical and haematological analyses. The chosen doses were obtained from previous work carried out by Offor and Ubengama [16].

### **2.5 Necropsy**

Blood was collected by orbital technique, which involves retro orbital sinus puncture to obtain blood from the retro-bulbar plexus of the medial canthus of the rat's eye [19]. Each blood sample was divided into two portions. The first one was mixed well with the anticoagulant, dipotassium EDTA by shaking and used for hematological screening. The second portion (without anticoagulant) was kept at room temperature for 30 min to clot. Afterward, the clotted blood sample was centrifuged at 3,000 rpm for 10 min. The clear serum supernatant was then carefully aspirated and stored in a clean sample bottle for the determination of some biochemical parameters. Animals were euthanized by cervical dislocation under chloroform anaesthesia. The kidneys were excised, weighed, rinsed in saline, and preserved in 10% formalin for histopathological study.

## **2.6 Hematological Screening**

Total White Blood Cell Counts (TWBC), Packed Cell Volume (PCV), Red blood cell (RBC) count, Lymphocytes % (L%) and Neutrophils % (N%) were determined using the Hemocytometer method [20]. Hemoglobin (Hb) concentration was determined by the Cyanmethemoglobin method [21].

## **2.7 Biochemical Analysis**

The following biochemical parameters were assessed as markers of kidney function using diagnostic kits at the Chemical Pathology Department of the University of Uyo Teaching Hospital. They include creatinine, blood urea, and electrolytes (Na, K, Cl, HCO<sub>3</sub>) levels.

## **2.8 Statistical Analysis**

Results were expressed as mean  $\pm$  standard error of mean, S.E.M. Statistical analysis was carried out with one way analysis of variance (ANOVA) followed by Tukey's HSD post hoc test. Values of  $p < 0.05$  were considered to be significant.

# **3. RESULTS**

## **3.1 Effect of *Solanum anomalum* fruit extract on the Haematological Parameters of Rats with Paracetamol-induced Hepatotoxicity**

The effect on haematological parameters is as shown in Table 1. Administration of 2g/kg of paracetamol to rats in group 2 caused significant ( $p < 0.05$ ) decreased in Packed cell volume (PCV), Haemoglobin (Hb) concentration and red blood cell (RBC) count when compared to those in the normal control group. Most of these parameters were increased significantly ( $p < 0.05$ ) in group 3 animals treated with the standard drug silymarin, and in rats group treated with the two doses of the extract (groups 3 and 4) when compared to the untreated paracetamol group (group 2). The reduction in red blood cell (RBC) produced by the lower dose of the extract (452 mg/kg) was however, not significantly different ( $p > 0.05$ ) when compared to the untreated paracetamol group. Rats in group 2 (untreated paracetamol group) also showed significant increase ( $p < 0.05$ ) in total white blood count (WBC) when compared to rats in the normal control group, while the total WBC in the rats treated with higher dose of the extract (678 mg/kg) and those given the standard drug showed significant ( $p < 0.05$ ) decreases. However, there was no effect on lymphocyte and neutrophil percentages.

**Table 1: Effect of SA extract on the haematological parameters of PCM-induced kidney injury in rats**

Group	Treatment	Packed cell volume, PCV (%)	Haemoglobin, Hb concentration (g/dl)	Red blood cell count, RBC ( $10^6/\mu\text{L}$ )	Total WBC count ( $10^3/\mu\text{L}$ )	Lymphocyte (%)	Neutrophil (%)
1 (normal control)	Distilled water only	41.82 $\pm$ 1.21	17.00 $\pm$ 0.81	7.71 $\pm$ 0.12	20.01 $\pm$ 2.00	73.00 $\pm$ 3.12	29.12 $\pm$ 2.33
2 (negative control)	Distilled water + PCM	20.65 $\pm$ 1.01 <sup>a</sup>	11.25 $\pm$ 0.88 <sup>a</sup>	4.12 $\pm$ 0.11 <sup>a</sup>	28.71 $\pm$ 2.10 <sup>a</sup>	79.12 $\pm$ 3.00	31.42 $\pm$ 2.49
3 (positive control)	Silymarin + PCM	43.71 $\pm$ 1.07 <sup>b</sup>	15.82 $\pm$ 0.13 <sup>b</sup>	6.90 $\pm$ 0.34 <sup>b</sup>	22.33 $\pm$ 1.02 <sup>b</sup>	76.00 $\pm$ 2.11	28.00 $\pm$ 2.13
4	Ext. 452 mg + PCM	46.21 $\pm$ 2.02 <sup>b</sup>	16.11 $\pm$ 0.71 <sup>b</sup>	4.83 $\pm$ 0.14 <sup>a</sup>	27.21 $\pm$ 2.50 <sup>a</sup>	79.35 $\pm$ 3.11	28.11 $\pm$ 3.01
5	Ext. 678 mg + PCM	43.82 $\pm$ 1.08 <sup>b</sup>	15.93 $\pm$ 0.25 <sup>b</sup>	6.07 $\pm$ 0.81 <sup>b</sup>	23.00 $\pm$ 1.25 <sup>b</sup>	77.42 $\pm$ 3.00	30.49 $\pm$ 2.07

Data were expressed as mean  $\pm$  SEM.

**a:** significantly different when compared to the normal control group ( $p < 0.05$ )

**b:** significantly different when compared to the untreated paracetamol group ( $p < 0.05$ ) ( $n=5$ )

### 3.2 Effect of *Solanum anomalum* fruit extract on the Biochemical Parameters of PCM-induced kidney injury

The effects of *Solanum anomalum* fruit extract on the biochemical parameters of PCM-induced kidney injury is shown in table 2. Treatment of rats with paracetamol (2 g/kg) in group 2 caused significant ( $p < 0.05$ ) elevation of serum urea and creatinine levels when compared to the normal control. However, the elevated serum urea and creatinine levels were significantly ( $p < 0.05$ ) reduced in rats group pretreated with silymarin (100 mg/kg) and the higher dose (678 mg/kg) of the fruit extract. The lower dose of the extract (452 mg/kg) also decreased the serum level of these two parameters, but the effects were statistically insignificant ( $p > 0.05$ ) relative to the untreated paracetamol group. Administration of 2g/kg of paracetamol to rats in group 2 also resulted in elevated levels of electrolytes ( $\text{HCO}_3^-$ ,  $\text{Na}^+$ ,  $\text{K}^+$ ,  $\text{HCO}_3^-$  and  $\text{Cl}^-$ ), although the increase level was only significant ( $p < 0.05$ ) in sodium ions when compared to the normal control group. Also, pretreatment with the standard drug silymarin and the two doses of the extract had no significant ( $p > 0.05$ ) effect on the levels of most of the electrolytes with the exception of  $\text{Na}^+$ , when compared to the untreated paracetamol group.

**Table 2: Effect of *Solanum anomalum* fruit extract on Biochemical Parameters of PCM-induced kidney injury**

Group	Treatment	Creatinine (mg/dl)	Urea (mmol/L)	Bicarbonate (mmol/L)	Sodium ion (mmol/L)	Potassium (mmol/L)	Chloride (mmol/L)
1 (normal control)	Distilled water only	0.52±0.07	18.00±2.00	36.00±2.57	145.3±2.88	7.12±0.03	105.30±4.27
2 (negative control)	Distilled water + PCM	1.07±0.05 <sup>a</sup>	28.00±2.50 <sup>a</sup>	38.00±2.11	159.00±3.01 <sup>a</sup>	8.31±0.13	120.10±6.00
3 (positive control)	Silymarin + PCM	0.67±0.0 <sup>b</sup>	19.25±1.10 <sup>b</sup>	37.50±3.66	147.02±2.17 <sup>b</sup>	7.32±0.14	104.13±2.57
4	Ext. 452 mg + PCM	0.99±0.04 <sup>a</sup>	26.75±2.25 <sup>a</sup>	38.50±1.10	149.00±2.18 <sup>b</sup>	7.61±0.22	102.00±2.06
5	Ext. 678 mg + PCM	0.69±0.01 <sup>b</sup>	21.23±1.30 <sup>b</sup>	37.77±1.14	146.00±3.12 <sup>b</sup>	7.11±0.00	106.71±3.07

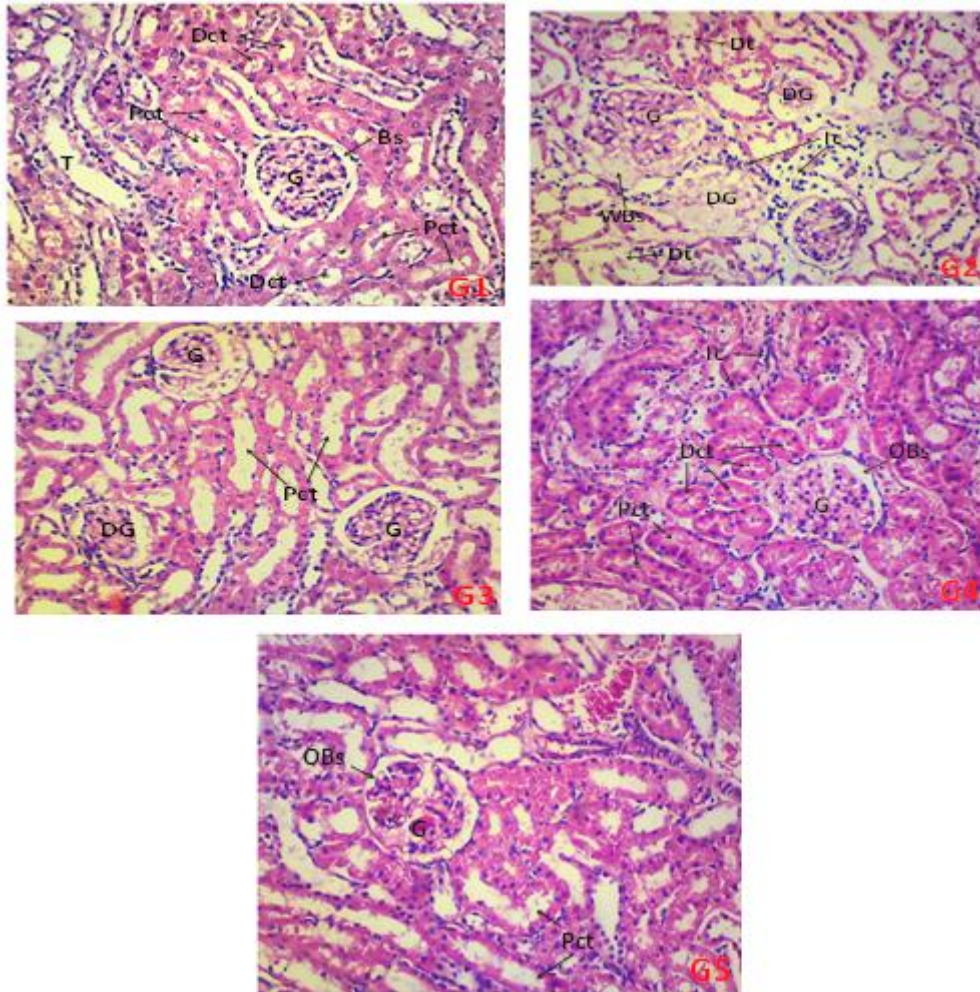
Data were expressed as mean ± SEM.

**a:** significantly different when compared to the normal control group (p<0.05)

**b:** significantly different when compared to the untreated paracetamol group (p<0.05) (n=5)

### 3.3 Histopathology of the Kidneys

The histological photomicrographs of the effect of ethanol fruit extract of *Solanum anomalum* (SA) on kidneys of rats with paracetamol-induced injuries stained with H&E techniques are shown in figure 1. The normal control group given Distilled water 10 ml/kg(G1) displayed a standard architectural presentation. Thus, there was normal spaced Bowman's capsule (Bs), numerous proximal convoluted tubules (Pct) and distal convoluted tubules (Dct) within the renal cortical matrix. Rats given paracetamol 2.0 g/kg (G2) displayed gross damages and degeneration of renal cells. Hence, there were degenerated glomeruli (DG), widened Bowman's spaces (WBs), degenerating tubular cells and infiltration of mononuclear inflammatory cells. Tissue sections from the kidneys of rats given the standard drug, silymarin 100mg/kg and paracetamol 2.0 g/kg (G3) showed fewer degenerating glomeruli (DG), degeneration of glomerular vascular cells as well as numerous proximal and distal convoluted tubules within the renal cortical matrix. Rats given 452 mg/kg *Solanum anomalum* extract and paracetamol (G4), displayed renal cortex containing hyperplastic glomerulus with occluding bowman's space (OBs), wide infiltration of mononuclear inflammatory cells within connective tissue spaces, numerous proximal and distal convoluted tubules within the renal cortical matrix. Tissue sections from the kidneys of rats given 678 mg/kg *Solanum anomalum* extract and paracetamol (G5) showed the renal cortex containing hyperplastic glomerulus with occluding bowman's space (OBs), and numerous renal tubules within the renal cortical matrix.



**Fig. 1.** Histological photomicrographs of kidneys of rats treated with Distilled water 10 ml/kg (**G1**), Paracetamol 2.0 g/kg (**G2**), Silymarin 100mg/kg and paracetamol 2.0 g/kg (**G3**), SA452 mg/kg and Paracetamol (**G4**), SA678 mg/kg and paracetamol 2.0G/kg (**G5**) at magnification (x100) stained with H&E technique. **Keys:** Proximal convoluted tubules (**PCT**), Distal convoluted tubules (**DCT**), Normal-spaced Bowman's capsule (**Bs**), Glomerulus (**G**), Degenerated glomerulus (**DG**), Widened Bowman's spaces (**WBS**), Occluding Bowman's space (**OBs**), Inflammatory cells (**Ic**), Tubular cells (**T**).

#### 4. DISCUSSION

Paracetamol has both nephrotoxic and hepatotoxic effects [22-23]. However, paracetamol-related liver damage is more recognized than kidney damage [24]. Although the risk of paracetamol hepatotoxicity is much higher than that of nephrotoxicity, it may lead to acute renal inefficiency at a rate of 1–2%, and even fatal at higher doses [25]. Paracetamol toxicity may cause acute tubular necrosis, which is one of the major causes of acute renal failure [26]. In most cases, paracetamol-induced kidney injury becomes evident after hepatic injury, but incidents of renal tubular damage and acute renal failure, even in the absence of hepatotoxicity should not be ignored [25]. Currently, N-Acetyl-cysteine (NAC) is the antidote clinically used for treatment of paracetamol toxicity [27-28]. N-Acetyl-cysteine is metabolized to cysteine, a precursor of glutathione, and therefore increases the intracellular glutathione level, resulting in safe detoxification of the toxic metabolite, N-acetyl-p-benzoquinone imine, NAPQI [29-31]. Although N-Acetyl-cysteine is used in the treatment of paracetamol-induced hepatotoxicity, its role in preventing or treatment of paracetamol-induced nephrotoxicity is controversial, based primarily on retrospective studies and case reports, and lacking large-scale randomized clinical trials [30].

In this study, we demonstrated that *Solanum anomalum* ethanol extract plays an important role in mitigating paracetamol-induced nephrotoxicity. In diagnosis of kidney injury, serum levels of urea and creatinine should be determined, as they serve as useful biomarkers in the assessment of kidney diseases. These two parameters may be indicators of acute tubular necrosis in paracetamol-induced toxicity [26, 28]. In our study, administration of high dose of paracetamol (2.0 g/kg) increased serum urea and creatinine levels, as well as increase in the levels of electrolytes, indicating nephrotoxicity. These results are in agreement with those observed in previous studies [28, 32-34]. Administration of *Solanum anomalum* decreased these altered levels of urea and creatinine, and particularly sodium ion among the electrolytes. These results have shown that *Solanum anomalum* ameliorates the nephrotoxic effects of paracetamol. The nephroprotective properties of *Solanum anomalum* may be related to its positive effects on the antioxidant system. Our previous studies suggesting potential antioxidant capacity of *Solanum anomalum* extracts support our findings [17]. Thus, *Solanum anomalum* extract may reduce oxidative stress through direct antioxidant

effect of its ingredients as well as induction of endogenous antioxidant enzymes leading to its mitigation of paracetamol-induced nephrotoxicity.

Findings from this study also show that paracetamol caused significant decreases in haematological parameters such as Packed cell volume (PCV), Haemoglobin (Hb) concentration and red blood cell (RBC) count when compared to those in the normal control group. This indicates the destruction of red blood cells and a change in the rate of their production (erythropoiesis). Hence, paracetamol can induce anaemia and does not have the potential to induce erythropoietin release from the kidneys, which is the humoral regulator of RBC production [32,35]. Paracetamol also caused significant increase in total white blood count (WBC) when compared to those in the normal control group. The increase may be an immunological response by the body defense system to repair paracetamol-induced injury on the rat organ [36]. Administration of *Solanum anomalum* extracts, particularly the higher dose caused significant increases in PCV, Hb and RBC as well as significant decrease in WBC. In addition, kidneys of rats treated with *Solanum anomalum* fruit extract showed marked improvement in their histoarchitecture and with less pathological changes in comparison to the untreated paracetamol group. The protective effect of *Solanum anomalum* on the kidneys of rats may be attributable to some of the bioactive ingredients contained in the fruits such as flavonoids, terpenes, saponins, tannins and alkaloids.

## **5. CONCLUSION**

The results of this study show that *Solanum anomalum* may improve paracetamol-induced kidney injury which may be due to the activities of its phytochemical constituents. Further studies should be carried out to elucidate the precise mechanism(s) of action.

## **DISCLAIMER**

The products used for this research are commonly and predominantly used products in our area of research and country. There is absolutely no conflict of interest between the

authors and producers of the products because we do not intend to use these products as an avenue for any litigation but for the advancement of knowledge. Also, the research was not funded by the producing company rather it was funded by personal efforts of the authors.

## CONSENT

It is not applicable.

## ETHICAL APPROVAL

The procedures were performed according to the guidelines on the use of animals and approved by the Institutional Animal Ethical Committee of the Faculty of Pharmacy, University of Uyo, Nigeria (Ethical Approval No: FPharm/EC/003) dated March 13, 2021.

## REFERENCES

1. Kandemir FM, Kucukler S, Eldutar E, Caglayan C, Gülçin I. Chrysin Protects Rat Kidney from Paracetamol-Induced Oxidative Stress, Inflammation, Apoptosis, and Autophagy: A Multi-Biomarker Approach. *Sci Pharm.* 2017; 85(1): 4.
2. Faddaa L, Ali HM, Aldrees GA, Alquraishida NM. Nano ubiquinone: Promising candidate for treatment of renal toxicity induced by over dose of paracetamol. *Toxicology Reports.* 2019; 6: 712–17
3. Coresh J, Selvin E, Stevens LA, Manzi J, Kusek JW, Eggers P, Van F, Lente PV, Levey AS. Prevalence of chronic kidney disease in the United States. *JAMA.* 2007; 298(17): 2038–47.
4. Baleni R, Bekker Z, Walubo A, Du Plessis JB. Co-administration of fresh grapefruit juice (GFJ) and bergamottin prevented paracetamol induced hepatotoxicity after paracetamol overdose in rats. *Toxicol. Rep.* 2015; 2: 677–84.
5. Bessems JG, Vermeulen NP. Paracetamol (acetaminophen)-induced toxicity: molecular and biochemical mechanisms, analogues and protective approaches. *Crit Rev Toxicol.* 2001; 31(1):55–138
6. Gamal El-Din AM, Mostafa AM, Othman A, Al-Shabanah OA, Al-Bekairi AM, Nagi MN. Protective effect of Arabic gum against acetaminophen-induced hepatotoxicity in mice. *Pharmacol. Res.* 2003; 48:631–35.
7. Abdel-Zaher AO, Abdel-Hady RH, Mahmoud MM, Farrag MM. The potential protective role of alpha-lipoic acid against acetaminophen-induced hepatic and renal damage. *Toxicology.* 2008; 243:261–70.

8. Ko JW, Shin JY, Kim JW, Park SH, Shin NR, Lee IC, Shin IS, Moon C, Kim SH. Protective effects of diallyl disulfide against acetaminophen-induced nephrotoxicity: a possible role of CYP2E1 and NF- $\kappa$ B. *Food Chem Toxicol.* 2017; 102:156–65
9. Haidara MA, Al-Ani B, Eid RA, Mohammed ME, Al-Hashem F, Dallak M. Acetaminophen induces alterations to the renal tubular ultrastructure in a rat model of acute nephrotoxicity protected by resveratrol and quercetin. *Int J Morphol.* 2020; 38(3):585–91
10. Orji BO, Obi FO, Modo EU, Osibemhe M, Otitolaiye CA. Amelioration of paracetamol-induced nephrotoxicity in mice by aqueous extract from the calyx of *Hibiscus sabdariffa* Linn. *Biokemistri.* 2020; 32(1): 23–34
11. Krumschnabel G, Manzl C, Berger C, Hofer B. Oxidative stress, mitochondrial permeability transition, and cell death in Cu-exposed trout hepatocytes. *Toxicol. Appl. Pharmacol.* 2005; 209 (1): 62–73
12. Das J, Ghosh J, Manna P, Sil PC. Taurine protects rat testes against doxorubicin-induced oxidative stress as well as p53, Fas and caspase 12-mediated apoptosis. *Amino Acids.* 2012; 42:1839–55.
13. El-Shafey MM, Abd-Allah GM, Mohamadin AM, Harisa GI, Mariee AD. Quercetin protects against acetaminophen-induced hepatorenal toxicity by reducing reactive oxygen and nitrogen species. *Pathophysiology.* 2015; 22:49–55.
14. Neelima S, Dwarakanadha RP, Kothapalli BCS. Nephroprotective activity of *Annona squamosa* leaves against paracetamol-induced nephrotoxicity in rats: in vitro and in vivo experiments. *Futur J Pharm Sci.* 2020; 6:131.
15. Canayakin D, Bayir Y, Baygutalp NK, Karaoglan ES, Atmaca HT, Ozgeris FBKC, Keles MS, Halici Z. Paracetamol-induced nephrotoxicity and oxidative stress in rats: the protective role of *Nigella sativa*, *Pharmaceutical Biology.* 2016; 54(10): 2082-89
16. Offor SJ, Ubengama EE. Phytochemical and antidiabetic studies of ethanolic extracts and fractions of the fruits of *Solanum anomalum*. *International Journal of Scientific Research and Education.* 2015; 3: 4343-4350.
17. Offor SJ, Mbagwu HOC, Orisakwe OE. Improvement of lead acetate-induced testicular injury and sperm quality deterioration by *Solanum anomalum* Thonn. Ex. Schumach fruit extracts in albino Rats. *J Fam Reprod Health.* 2019; 13(2): 98-108.
18. Offor SJ, Nwokocha C, Mbagwu HOC, Orisakwe OE. Hepato-Renal Effect of *Solanum anomalum* Thonn. Ex. Schumach Fruit Extracts on Lead-Exposed Albino Rats. *Discovery Phytomedicine.* 2021; 8(2): 56-66
19. Stone SH. Method for obtaining venous blood from the orbital sinus of a rat or mouse. *Science.* 1954; 119: 100 –102.
20. Thrall MA, Weiser MG. Hematology in Laboratory Procedures for Veterinary Technicians, 4th Edn, ed. C. M. Hendrix (Saint Louis: MO: Mosby). 2002; pp. 29–74
21. Higgins T, Beutler E, Dumas BT. Measurement of haemoglobin in blood, in *Tietz Fundamentals of Clinical Chemistry*, 6th Edn, eds C. A. Burtis, E. R. Ashwood, and D. E. Bruns (Saint Louis: MO: Sanders Elsevier). 2008; 524–25.

22. Karthivashan G, Kura AU, Arulselvan P, Md Isa N, Fakurazi S. The modulatory effect of *Moringa oleifera* leaf extract on endogenous antioxidant systems and inflammatory markers in an acetaminophen-induced nephrotoxic mice model. *Peer J*. 2016;7: e2127.
23. Aksun S, Gökcimen A, Kahyaoglu F, Demirci B. The effect of Paracetamol exposure on hepatic and renal tissues during statin usage. *Turkish Journal of Biochemistry*. 2019; 44(1): 113-20.
24. Boutis K, Shannon M. Nephrotoxicity after acute severe acetaminophen poisoning in adolescents. *Clin Toxicol*. 2001; 39:41–45.
25. Eguia L, Materson BJ. Acetaminophen related acute renal failure without fulminant liver failure. *Pharmacotherapy*. 1997; 17:363–70.
26. Blantz RC. Acetaminophen: acute and chronic effects on renal function. *Am J Kidney Dis*. 1996; 28: S3–S6.
27. Flanagan RJ, Meredith TJ. Use of *N*-acetylcysteine in clinical toxicology. *Am J Med*. 1991; 91:131S–39S.
28. Canayakin D, Bayir Y, Baygutalp NK, Karaoglan, ES, Atmaca HT, Ozgeris FBK, Keles, MS, Halici Z. Paracetamol-induced nephrotoxicity and oxidative stress in rats: the protective role of *Nigella sativa*. *Pharmaceutical Biology*. 2016; 54:10,2082-91
29. Dilger RN, Baker DH. Oral *N*-acetyl-L-cysteine is a safe and effective precursor of cysteine. *J Anim Sci*. 2007; 85:1712–18.
30. Mazer M, Perone J. Acetaminophen-induced Nephrotoxicity: Pathophysiology, Clinical Manifestations, and Management. *Journal of Medical Toxicology*. 2008; 4(1): 1-6
31. Ferner RE, Dear JW, Bateman DN. Management of paracetamol poisoning. *BMJ*. 2011; 342: d2218
32. Okokon JE, Udobang JA, Basseyy AI, Edem UA, Agu EC. Hepatoprotective and nephroprotective activities of husk extract of *Zea mays* against paracetamol-induced liver and kidney injuries in rats. *Trop J Nat Prod Res*. 2020; 4(3): 67-76
33. Anthony OE, Mbuh AF, Emmanuel MP. Phytochemical screening, and assessment of ameliorating effect of aqueous and ethanolic extracts of *Gmelina arborea* on drug induced hepatic and renal insufficiency in rats. *Pak J Pharm Sci*. 2012; 25:457–61.
34. Saxena M, Shakya AK, Sharma N, Shrivastava S, Shukla S. Therapeutic efficacy of *Rosa damascena* Mill. On acetaminophen-induced oxidative stress in albino rats. *J Environ Pathol Toxicol Oncol*. 2012; 31:193–201.
35. Polenakovic M, Sikole A. Is erythropoietin a survival factor for red blood cells? *J Am Soc Nephrol*. 1996;7(8):1178-82
36. Soetan KO, Akinrinde AS, Ajibade TO. Preliminary studies on haematological parameters of cockerels fed raw and processed guinea corn (*Sorghum bicolor*). *Proceeding of 38th Annual conference of Nigerian society for Animal production*. 2013; 49-52.