

A CASE REPORT OF MANAGEMENT OF MULTIPLE PERI-ORBITAL CYSTS (ECCRINE HIDROCYSTOMA) IN A 35-YEAR OLD WOMAN

Abstract

Background: Hidrocystoma is a rare benign swelling (tumour) of sweat glands also known as the cystic form of hidroadenoma, cystadenomas, sudoriferous cysts, and Moll's gland. It has no racial or sex predilection. Its rarity and site of occurrence makes its management challenging due to limitation in knowledge of making diagnosis, treatment, availability of drugs and interventions and aesthetic concerns.

Aim: To report a case of a rare benign tumour and the challenges in management.

Presentation of case: A 35 year old Nigerian woman from the Igbo ethnic group with tertiary level of education who presented to the dermatology outpatient clinic with a 10 year history of recurrent peri-orbital swelling associated with occasional pruritus. There was no history of similar lesion in any family member. Patient had resorted to self-medication and consulted different doctors prior to being referred to the dermatologist. Her physical examination was normal. She was also counselled about the disease and management options. She subsequently received seven sessions of the chemo-ablation using trichloroacetic acid (TCA) with remarkable improvement and has had no recurrence of lesions for the past 1 year.

Conclusion: Hidrocystomas can be successfully treated in our environment.

Keywords: Cysts, hidrocystoma, multiple, peri-orbital

AIM: The aim of this case presentation is to report a case of a rare benign tumour, briefly describe the management instituted and its outcome and to also discuss the challenges in diagnosis and management.

PRESENTATION OF CASE: A 35 year old Nigerian woman from the Igbo ethnic group with tertiary level of education who resides in Port Harcourt, Nigeria presented to our dermatology outpatient clinic (DOPC) on account of recurrent peri-orbital swelling of 10 years duration. Patient was in her usual state of health until about 10 years prior to presentation when she developed swelling around her eyes. It started off as a single soft papule with regular borders on her left eyelid which became multiple involving both eyes and progressively increased in size and number. They were not significantly worse during hot weather. There was a history of occasional pruritus; however, there was no history of blurring of vision, no tearing, no jaundice, no mucopurulent discharge from the eyes. There was also no associated fever, alopecia, weight loss, myalgia, heat intolerance, or cold intolerance. There is no family history of similar lesions. The patient initially punctured the lesions with needles, self-medicated on several topical creams. She also consulted other physicians intermittently who placed her on antibiotics and later she was subsequently referred to an ophthalmologist who thought she had nodulocystic acne and

she was then referred to our DOPC. She has not been known to suffer from any chronic skin disorder prior to this condition. She is also not a known hypertensive, epileptic, asthmatic, diabetic or sickle cell patient. She has not had any surgery in the past. She had no drug allergy or atopy. She had a regular menstrual cycle. There was no known family history of chronic illnesses. She did not use alcoholic beverages, tobacco products or abuse hard drugs. Multiple hyper pigmented and skin coloured peri-orbital papular and nodular lesions with sizes ranging from 0.5 to 1cm. Lesions were dome-shaped, soft with regular borders. Other systems were essentially normal. The diagnosis of eccrine hidrocystoma was made clinically because the lesions were multiple as against apocrine hidrocystoma that are noted to be single. Other possible differentials were nodulocystic acne, melanocytic naevi, papilloma. On presentation to the DOPC, she was counseled about her disease condition. She was asked to do HBsAg, HCVAb, retroviral screening (RVS) which were seronegative. A skin biopsy and histology was requested however patient declined these investigations due to the location of the lesions. She was also counseled on her treatment options for her condition of which chemo-ablation with trichloroacetic acid (TCA) was the most feasible as at the time of presentation, although there was delay in getting it because he had to be imported on special order due to its unavailability in pharmacies in the city and was relatively expensive. 1ml of 20% TCA diluted in 4 mls of sterile injection water was constituted. Using 1 ml insulin syringe ((IS)-100IU). The solution was injected into the lesions after cleaning site and use of topical lignocaine. It was left for 1 minute and withdrawn with another 1 ml IS. She subsequently received 7 sessions of the chemo-ablation over a period of 10 weeks with remarkable improvement. She is currently on 3-monthly follow up visits at the clinic. She has had no recurrence of lesions for the past 1 year.

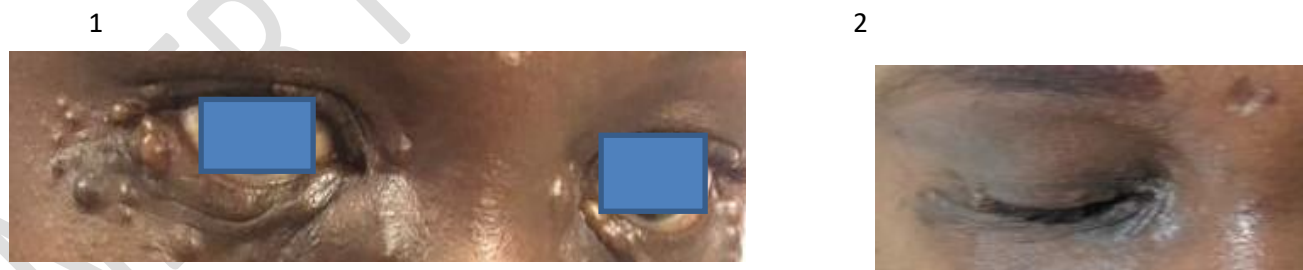


Figure 1 & 2: The patient's face before procedure and after.

DISCUSSION

Hidrocystoma is a rare benign swelling(tumour) of sweat glands also known as the cystic form of hidroadenoma, cystadenomas, sudoriferous cysts, and Moll's gland. It has no racial or sex predilection. Occur in all age groups(noted to be more in 30-70 years old) It is seen more in humid environment.¹ The city of Port Harcourt Rivers State is known to be humid particularly in the month of August.² Hidrocystomas have rarely been reported in Nigeria and hardly were

there cases of eccrine hidrocystomas in medical literature even in Africa. The few cases reported were mainly apocrine hidrocystomas.³⁻⁶ A case report of a patient of same sex and age group showed lesions to be at the malar area.⁷ The clinical differences between apocrine and eccrine hidrocystomas are not so reliable since varying reports show them to both occur on the face and there have been reports of eccrine hidrocystomas occurring as a single lesion and cases of apocrine gland occurring as multiple lesions with varying sizes.^{3-6, 8-9} The cause of hidrocystoma is not known. Eccrine hidrocystoma is due to the obstruction of the eccrine sweat gland which causes the retention of secretions and the appearance of a dilated cystic structure. Apocrine hidrocystoma is currently considered to be a cystic proliferation of apocrine glands, rather than a simple retention cyst. Apocrine hidrocystoma is believed to be an adenoma of the coil structure of the apocrine sweat gland.^{1, 8} The dermoscopic findings in apocrine hidrocystoma shows a homogenous area that occupies the whole lesion and that may be accompanied by arborizing vessels. The color of the homogenous area can be skin colored, yellow, or blue.¹⁰ Eccrine hidrocystomas have a molluscoid appearing clear cysts, with a hypopyon-like appearance in darker lesion.¹¹ Histologic diagnosis seems to be the most reliable as few studies have been done to establish dermoscopic findings. The key differences between eccrine and apocrine hidrocystoma which is the closest differential can be appreciated histological by the use of special stains and histologic morphology. Decapitation secretions, papillary projections and positive Periodic Acid Schiff (PAS) granules are present in apocrine hidrocystomas but absent in eccrine hidrocystomas.^{1, 8, 12} Our patient declined skin biopsy because of the possible scar that would be left on her face following healing of biopsy wound and the fear of harming her eyes. Goltz-Gorlin syndrome, Grave's disease, sarcoidosis and Schopf-Schulz-Passarge syndrome have been reported in cases of multiple eccrine hidrocystomas but none of this was established in our patient.^{1, 7, 8, 12}

There various modalities of medical treatment such as use of botulinum toxin A injection, topical atropine cream, topical scopolamine cream, intracystic hypertonic glucose, topical and oral anticholinergics, aluminium chloride and trichloroacetic acid just as it was used in this patient. **Figure 1 shows the patient with the lesion during her initial presentation and Figure 2 shows her appearance after 10 weeks of the procedure.** Surgical treatment have also been mentioned in literature such as electrosurgical destruction, excision, incision and drainage, laser therapy (carbon dioxide laser vaporization, pulsed-dye laser, 1450nm diode laser and 595nm long-pulsed laser treatments) and needle puncture with varying degree of success with needle puncture and incision and drainage having the highest frequency of recurrence; while surgical excision appears to be more commonly used.^{1, 5, 7-13} Trichloroacetic acid is regarded as a relatively strong acid hence our decision to dilute it while using around the eyes. The mechanism of action is noted to cause instability of proteins including the DNA and RNA thus causing tissue destruction.^{14, 15} The adverse effects include skin burning, hypersensitivity and the possibility of cancers hence the avoidance on hypersensitive skin and premalignant lesions. TCA use in pregnancy is not advised.¹⁵ It is important to note that hidrocystomas can persist indefinitely and there is need for more studies to be done to establish why and if there is any relation to genetics or environment.¹⁶

The choice of treatment is dependent on the availability of therapy, the dermatologist's expertise and the patient's preferred choice bearing in mind the cost, effectiveness and side effect of each modality of treatment as it was experienced in this case.^{1, 8, 13}

CONCLUSION

Hidrocystomas are rare benign tumour that commonly occurs on the face particularly around the eyes. Distinguishing eccrine from apocrine clinically can be challenging. Patient's decision can affect modality of management however their decision and choices must be respected and taken into consideration. Hidrocystomas can be successfully treated in our environment with a wide range of therapies to choose from.

REFERENCES

- 1) Sarabi, K. Khachemoune, A. *Hidrocystomas - A Brief Review*, Available at https://www.medscape.com/viewarticle/541982_7, Accessed 20th May 2022
- 2) Weather and Climate 'Average Humidity in Port Harcourt' Available at <https://weather-and-climate.com/average-monthly-Humidity-perc.port-harcourt,Nigeria>, Accessed 19th June 2022
- 3) Adeloye, A, Aghadiuno, PU, Adesina, MA, Ogunniyi, J. *A Large Apocrine Hidrocystoma Located over the Thoracic Spine in a Nigerian*, Central African Journal Of Medicine, 33(3): 74-76
- 4) Solomon R, Yusuf I, Ochicha O. Skin adnexal tumours in Kano, Northern Nigeria. Niger J Basic Clin Sci [serial online] 2015 [cited 2021 Nov 29]; 12:51-4
- 5) T. Rodallec, S. Abada, J. Nordmann [*Atypical giant hidrocystoma of the eyelid*]. Journal francais d'ophtalmologie, 2006
- 6) Inoh MI, Kudamnya IJ, Eziagu UB, Inoh EE. 'A 10-year review of the clinicopathological patterns and prevalence of head and neck lesions in a tertiary health facility in Uyo, South-South Nigeria.' Calabar J Health Sci 2021;5:66-74
- 7) Singh V, Dhawan M, Narang T, Kaur R. 'Multiple eccrine hidrocystomas in a patient of sarcoidosis.' Indian J Dermatol. 2012;57(6):504. doi:10.4103/0019-5154.103084
- 8) Sarabi K, Khachemoune A. Hidrocystomas--a brief review. MedGenMed. 2006;8(3):57. Published 2006 Sep 6.
- 9) Antonio Russo, Cannarozzo G, Sannino M2 and De Luca G 'Multiple Apocrine Hidrocystomas of the Eyelids: A Case Successfully Treated Using Ultrapulsed Carbon Dioxide Laser and Literature Review' Journal of Clinical & Experimental Dermatology Research ; 2019: 10(5)
- 10) Zaballos P, Bañuls J, Medina C, Salsench E, Serrano P, Guionnet N. *Dermoscopy of apocrine hidrocystomas: a morphological study*. J Eur Acad Dermatol Venereol. 2014 Mar;28(3):378-81.

- 11) Khurana, Ananta et al. “*Dermoscopy of Eccrine Hidrocystomas.*” Indian dermatology online journal vol. 9,4 (2018): 288-289.
- 12) Ferenczi, K. Elenitsas, R., ‘*Hidrocystoma (Apocrine and Eccrine Hidrocystoma),*’ Available at <https://www.dermatologyadvisor.com/home/decision-support-in-medicine/dermatology/hidrocystoma-apocrine-and-eccrine-hidrocystoma/>, Accessed 30th May 2022
- 13) Trischman T, Scott JF. Comparative Efficacy of Hidrocystoma Treatments: A Systematic Review. *Journal of Cutaneous Medicine and Surgery.* 2020;24(5):474-480.
- 14) Sivaraman T, Kumar TK, Jayaraman G, Yu C. ‘*The mechanism of 2,2,2-trichloroacetic acid-induced protein precipitation.*’ *J Protein Chem.* 1997 May;16(4):291-7
- 15) Medscape ‘*Trichloroacetic acid topical (Rx)*’ Available at <https://reference.medscape.com/drug/tri-chlor-trichloroacetic-acid-topical-999550>, Accessed 19th June 2022
- 16) Jakobiec, F.A, Fouad R.Zakka ‘*A Reappraisal of Eyelid Eccrine and Apocrine Hidrocystomas: Microanatomic and Immunohistochemical Studies of 40 Lesions*’ *Am J Ophthalmol.* 2011 Feb;151 (2):358-74.e2.