

A CASE OF PSEUDOPREGNANCY IN A BITCH

Abstract

A case of pseudopregnancy was presented to Veterinary Teaching Hospital, Michael Okpara University of Agriculture, Umudike. Eighteen (18) months old female dog weighing 15kg was presented with pseudopregnancy, which was observed weeks after the dog came on heat (estrus). The clinical signs were restlessness, anorexia, aggression, nesting behaviour and licking of mammary gland. On clinical evaluation it was seen that bitch had enlarged mammary and milk secretion. The physiological parameters were found to be within the normal range. Abdominal palpation, ultrasonography and vagina cytology were carried out to rule out pregnancy. It was concluded to be a case of pseudopregnancy due to absence of foetuses on abdominal palpation, ultrasonography and scanty epithelial cells

Key words: Pseudopregnancy, Ultrasonography, Vagina cytology, Estrus, Bitch.

INTRODUCTION

Pseudo-pregnancy is one of the most frequent clinical features observed in the non pregnant domestic bitch [1, 2, 3]. The female dog has several unique reproductive features in comparison to other domestic and laboratory species [4]. The term pseudopregnancy was previously used to describe an abnormally long luteal phase of the estrual cycle observed in the rabbit. It is characterized by clinical signs similar to those seen in late pregnancy or the early post-partum period [5]. Pseudopregnancy mimics signs of parturition and lactation in the pregnant bitch. Clinical signs usually begin 6 to 12 weeks after estrus [6, 7]. Different

studies have reported a wide range of physical and behavioural changes in a pseudo-pregnant bitch such as restlessness, anorexia, decreased activity, aggression, licking of the abdomen [8, 9], nesting, mothering inanimate objects, adopting other bitches puppies [10, 11], weight gain, mammary enlargement, milk secretion, and sometimes abdominal contractions [6, 4]. The major differential diagnosis is pregnancy, which can be generally ruled out by abdominal palpation, ultrasonography or radiography late in diestrus when signs of pseudo-pregnancy are exhibited [4].

The exact cause of pseudo-pregnancy is poorly understood, although it is normally suggested that certain hormonal changes might play an essential role in the development and maintenance of pseudo-pregnancy [12]. Exposure and decline of plasma progesterone, high plasma prolactin concentrations, increased tissue sensitivity to prolactin, or the existence of molecular variants of prolactin with varying bioactivities has been linked with pseudo-pregnancy [13, 14, 15, 16]. The incidence of pseudopregnancy in most breeds is estimated to be as high as 50-75% in certain breeds [17, 18]. The incidence of pseudo pregnancy has been reported in various part of the world [16, 19], with associated economic losses on dog owners and breeders. This case report therefore, presents a confirmed case of pseudo pregnancy in a bitch presented to Veterinary Teaching Hospital, Michael Okpara University of Agriculture, Umudike.

CASE HISTORY

Eighteen (18) months old female dog weighing 15kg was presented to Veterinary Teaching Hospital, Michael Okpara University of Agriculture, Umudike with signs suspected to be pseudopregnancy. The owner observed abnormal signs; weeks after the dog came on heat (estrus) which included restlessness, anorexia, aggression, nesting behaviour and licking of mammary gland. On clinical evaluation it was seen that bitch had enlarged mammary and

milk secretion. After expected gestation period, the bitch did not whelp and was presented to the clinic for evaluation. The physiological parameters were found to be within the normal range. Abdominal palpation, vaginal cytology and ultrasonography were carried out to rule out pregnancy.

RESULTS AND DISCUSSION

Pseudopregnancy was suspected based on the history and clinical signs exhibited by the bitch [4]. The observed physical signs were weight gain, mammary enlargement, milk secretion and signs that mimics parturition, which was previously reported [20, 21]. The physiological mechanism of pseudopregnancy is poorly understood, but it is assumed that as the duration of metestrus, luteal or proestrus phase of the cycle is more or less same with the duration of pregnancy (8-9 weeks) in bitch and the characteristic signs of pregnancy are also observed in pseudopregnancy [22]. In this study ultrasonography revealed the absence of fetuses (figure 1), which agrees with [5, 22], who stated false pregnancy or pseudopregnancy are generally ruled out by abdominal palpation and ultrasonography or radiography. Ultrasound is a common veterinary tool in the diagnosis of pregnancy among domestic and zoo animals.

Vaginal cytology also revealed that the animal has gone into anestrus phase of the estrous cycle and as shown by the characteristic appearance of predominantly basal cells in the vaginal epithelium (Figure 2). The result is consistent with the findings of previous workers [2016], who reported an anoestrus in dogs to consist of nucleated basal and intermediate cells of the stratified squamous epithelium together with few neutrophils. Returning to anoestrus phase of the estrous cycle without whelping is an evidence of pseudopregnancy which was observed in the bitch.

Pseudopregnancy has been linked with the exposure and decline of plasma progesterone, high plasma prolactin concentrations. Increased tissue sensitivity to prolactin, or the existence of

molecular variants of prolactin with varying bioactivities are known to be associated with pseudopregnancy [14, 11]. Pseudopregnancy is typically self-limiting and treatment usually not considered in mild cases with maternal behaviour highly discouraged in the bitch. However, placing Elizabethan collars to prevent licking of the mammary glands is recommended as they are potential stimuli for lactation and need to be avoided. Water removal overnight for 5 to 7 nights promotes fluid conservation and also helps to terminate lactation [9].

In some cases with repeated episodes of pseudopregnancy with significant behavioural changes mild tranquilization with non-phenothiazine drugs can be useful to prevent the development of mammary tumours (Verstegen 1999; Razzaque *et al.*, 2008). Sex steroid therapy such as Veterinary preparation of androgen including testosterone and synthetic androgen can suppress lactation. Side effects can include clitoris hypertrophy, other form of virilisation, and epiphora [6]. Prolactin-suppression therapy involving the use of bromocriptine and carbergolin administered in high doses [25, 26]. In bitches with repeated cases and not intended for breeding ovariectomy or spaying, preferably done during anoestrus phase is the only permanent solution [27, 19]. Cases of false or pseudopregnancy are present in all breeds of dogs and has huge socio economic impacts on dog breeders and owners.

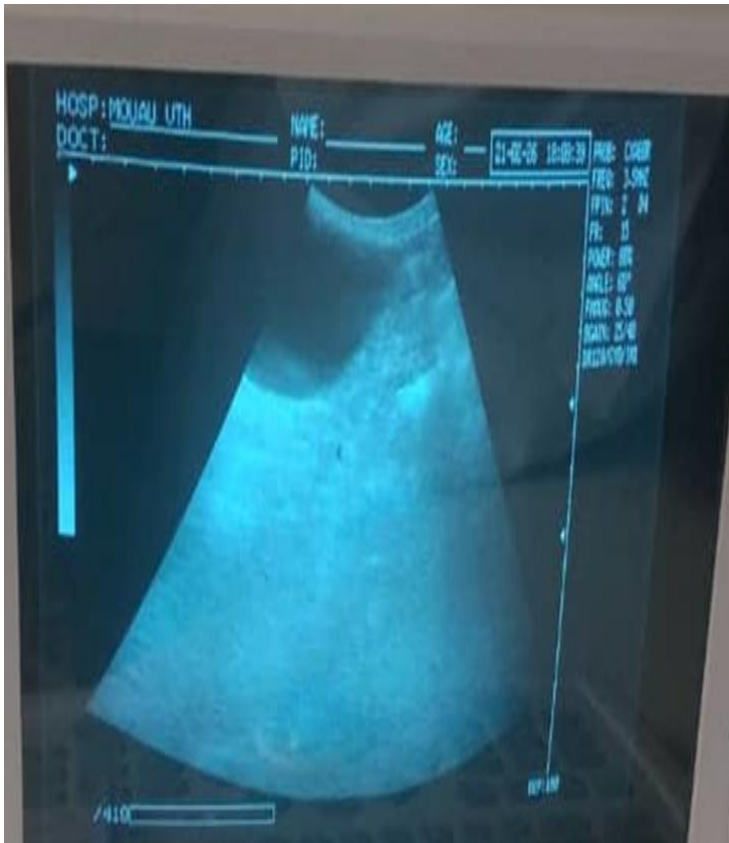

Figure 1: Showing ultrasonography of non pregnant uterus of the bitch

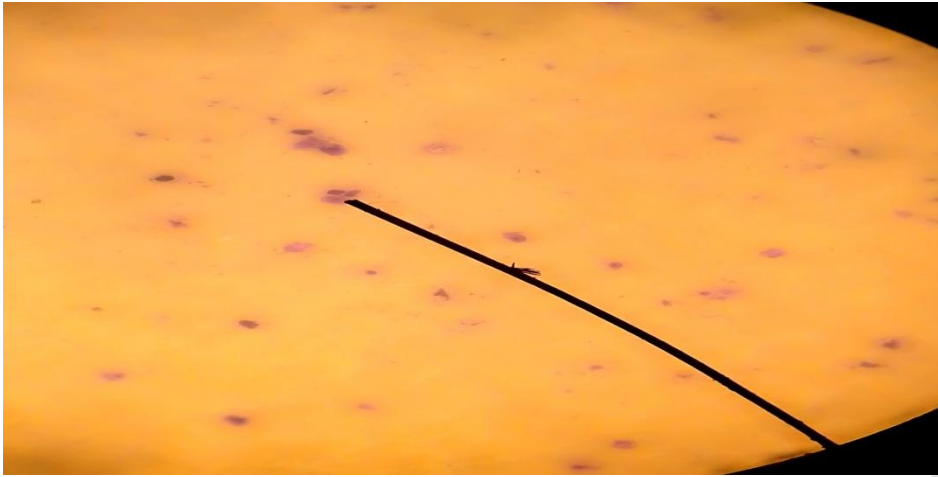


Figure 2: Showing scanty distribution of vaginal epithelial cells

UNDER PEER REVIEW

References

- [1]. Fatjo J, Ruiz-De-La-Torre JL, Manteca X. 2006. The epidemiology of behavioural problems in dogs and cats: a survey of veterinary practitioners. *Animal Welfare-Potters Bar Wheathampstead*, 2006, 15:179
- [2]. England GC, Heimendahl AV. *BSAVA manual of canine and feline reproduction and neonatology* 2nd edition. Cheltenham: British Small Animal Veterinary Association; 2010
- [3]. Landsberg GM, Hunthausen WL, Ackerman LJ. *Behavior problems of the dog and cat: Canine aggression*. 3rd edition. Edinburgh: Elsevier Health Sciences, 2012, 385–426.
- [5]. Feldman EC, Nelson RW. *Canine and Feline Endocrinology, Reproduction*, 2nd edn. WB Saunders, Philadelphia, USA, 1996.
- [6]. Gobelb C, Cocannon PW, Vestegen, J. Canine pseudopregnancy: A Review. *International Veterinary information service*, USA 2001a.
- [7]. Tsutsui T, Kirihara N, Hori T, Concannon PW. 2007. Plasma progesterone and prolactin concentrations in overtly pseudopregnant bitches: a clinical study. *Theriogenology*, 2007, 67:1032–8.
- [8]. Bevers MM., Schaefers Okkens AC. Pseudopregnancy in the dog. *Tijdschrift voor diergeneeskunde*, 1991, 116:700.
- [9]. Gobello C, Concannon PW, Verstegen J. Canine pseudopregnancy: A review. *Recent advances in Small animal reproduction*, 2001b,
- [10]. Romagnol S. An Update on Pseudopregnancy. *World small animal veterinary association world congress proceedings*. *Theriogenology*, 2nd edn. WB Saunders, Philadelphia, USA, 2009, 490-491
- [11]. Gobello C, Concannon PW, Verstegen J. Canine pseudopregnancy: A Review. *Recent advances in Small animal reproduction*. Edited by: Concannon PW, England G, Verstegen J, Ithaca, New York USA Retrieved: International Veterinary Information Services, 2011. (www.ivis.org).
- [12]. Grunau B, Nolte I, Hoppen HO. Investigation on the treatment of pseudopregnancy in the bitch with the prolactin inhibitors metergoline and bromocryptine. *Tierarztl Prax*, 1996, 24:149-155.
- [13]. England GCW, Complications of treating presumed pseudopregnancy in pregnant bitches. *Veterinary Record*, 1998, 142:369–71
- [14]. Harvey MJ, Dale MJ, Lindley S, Waterston MM. A study of the aetiology of pseudopregnancy in the bitch and the effect of cabergoline therapy. *Veterinary Record*, 1999, 144:433–6.

- [15]. Lee WM, Kooistra HS, Mol, JA, Dieleman SJ, Schaefer-Okkens AC. Ovariectomy during the luteal phase influences secretion of prolactin, growth hormone, and insulin-like growth factor-I in the bitch. *Theriogenology*, 2006, 66:484–90.
- [16]. Root AL, Parkin TM, Hutchison P, Warnes C, Yam PS. 2018. Canine pseudopregnancy: an evaluation of prevalence and current treatment protocols in the UK. *Veterinary Research*, 2018, 14:170
- [17]. Johnston SD. False pregnancy in the bitch, *Current Veterinary Theriogenology* 2nd ed. Philadelphia: WB Saunders Co; 1980. p. 623–4.
- [18]. Jöchle W. Prolactin in canine and feline reproduction. *Reproduction Domestic Animal*, 1997, 32:183–93
- [19]. Ndumari W, Se-embe AD, Oluwatosin A, Mhoh I H. Incidence of Clinical False Pregnancy among Breeds of Dogs at the Veterinary Teaching Hospital University of Agriculture Makurdi Benue State Nigeria. *Current trends in biomedical Engineering and Biosciences*, 2019, 18 (2):26-28.
- [20]. Jochle W, Ballabio R, Disalle E. Inhibition of lactation in the Beagle bitch with the prolactin inhibitor cabergoline (FCE 21336): Dose response and aspects of long-term safety. *Theriogenology*, 1987, 27(5):799- 810
- [21]. Lawler DF, Johnston SD, Keltner DG, Ballam JM, Kealy RD, Bunte T, Lust G, Mantz SL, Nie, RL. *American Journal Veterinary Research*, 1999, 60: 820-825.
- [22]. Razzaque WAA, Husain K, Agarwal S, Sudarshan Kuma S. False pregnancy in bitch. *Veterinary World*, 2008, 1(3): 92-95.
- [23]. SharMa M, SharMa N. *Vaginal Cytology: An Historical Perspective on its Diagnostic Use. Advances in Animal and Veterinary Sciences*. 4(6): 283-288. 2nd edition. Cheltenham: British Small Animal Veterinary Association, 2010.
- [24]. Verstegen JP, Onclin K, Silva LD, Concannon PW. *Theriogenology*, 1999, 51(3): 597-611.
- [25]. Grunau B, *Zarbehandlung Von prolaktinbei pseudograviditat der Hundin. Inaugural Dissertation. Tierarz tliche Hochschule Hannover, Germany. 1994.*
- [26]. Arbeiter K, Brass W, Balhbio R. Treatment of pseudopregnancy in bitch with cabergoline an ergoline deriotative. *Journal of small animals practice*, 1998, 29(12): 781-788.
- [27]. Allen W E. The current view on ethology and treatment. *Journal of small animal practices*, 1986; 27: 419-424.