

Original Research Article

Prevalence and Determinants of Punctal Occlusion at Ophthalmology Outpatient Clinic at Tanta University Hospital

Abstract

Background: Along with canalicular or nasolacrimal duct blockage, punctum stenosis is one of the most common causes of epiphora. The purpose of the study was to investigate the prevalence of punctal occlusion outlining their presentation varieties and etiological factors.

Methods: This cross-section observational study conducted on 50 patient suffering from epiphora. Patients were divided into two groups: single cause(N=19) and combination of causes (N=31). Every patient underwent: taking of the history, examination (examination of the eyelids, lid closure and lagophthalmos), evaluation of the punctum (by usage slit light for visibility, appearance and the occurrence of inflammation or oedema). Schirmer, I test used for ocular surface examination.

Results: occlusion was significantly higher in single cause than combination of causes while stenosis was significantly lower in single cause than combination of causes groups. Grades of stenosis were significantly different between the two groups. Schirmer test, lower tear meniscus height, and side of lesion were insignificantly different between study groups.

Conclusions: Punctal stenosis was an extremely frequent finding in individuals suffering from epiphora. Age tended to augment the prevalence of punctal stenosis, and many patients accompanied by post-cataract surgery combined with blepharitis then topical anti-glaucoma eye drops with recurrent conjunctivitis were most common association with punctal stenosis patients who had combination of causes.

Keywords: Punctal occlusion, Epiphora, lacrimal punctum, Punctal stenosis, lacrimal drainage system

Introduction:

Epiphora is a frequent problem observed by ophthalmologists, having a diverse differential diagnosis. Stenosis of the external lacrimal punctum is among the least discussed causes of epiphora. Tearing is the most prevalent symptom, however patients may also appear with nonspecific symptoms of eye pain ^[1].

Punctal agenesis is the term for the complete congenital blockage of the external punctum. External lacrimal punctum stenosis may be associated with common canalicular or canalicular duct stenosis, both which might complicate therapy ^[2].

Diagnosis of patients was done developed on the classification of their epiphora history by Kashkouli et al ^[1].

Acquired punctal stenosis may have several causes. Various microbial and iatrogenic substances are associated with blockage and topical medicines (latanoprost, timolol, betaxolol, echothiophate iodide, dipivefrin hydrochloride, pilocarpine .Post cataract surgery, Systemic drugs related with acquired punctual stenosis comprise: 5-fluoro-uracil, paclitaxel, S-1 and docetaxel ^[3-5].

Infectious factors have been combined with punctal stenosis (actinomyces, chlamydia, human papillomavirus), The external punctum chronic inflammation causes slow fibrotic alterations in the ostium, which are accompanied with aggressive blockage of the duct. Dry eye syndrome may be caused by persistent blepharitis ^[3].

The fibrosis and inflammation of the lacrimal drainage system result in significant fibrous adhesions that block the canaliculi and lacrimal sac. Non preservative free drugs may lead to mucosal lining damage, may occasionally result in irreversible damage to the lacrimal

system, so in this case, we recommend topical steroids free of preservative eye drops in the management of inflammatory punctal stenosis [6].

Creating an appropriate aperture while keeping the location of the punctum against the lacrimal lake and preserving lacrimal pump function are the fundamental concepts of surgical therapy for punctal stenosis [6, 7]. The purpose of this study was to study the prevalence of punctal occlusion outlining their presentation varieties and aetiological factors.

Patients and Methods:

This cross-section observational study enrolled 50 patients suffering from epiphora as examined by slit lamp with symptoms suggesting occlusion of punctum among patients who had complaining of epiphora. All patients provided written consent based on their knowledge. The study was done after approval from the Ethical Committee Tanta University Hospitals.

Exclusion criteria were patients with patent punctum, other lacrimal pathology as acute and chronic dacryocystitis, other ocular surface pathology causing epiphora and patients with active lid infection.

Patients were divided into two groups: single cause (N=19) and combination of causes (N=31).

All patients were subjected to: history taking (personal history, medical history, past history, detailed history, other risk factors and asking patient about frequency of tearing to detect the degree of epiphora)

Examination

Detailed examination (examination of the eyelids, lid closure and lagophthalmos and slit-lamp examination of eyelids for blepharitis, ectropion, entropion, trichiasis, for punctal patency and position and also the conjunctiva around the punctum.

Punctum assessment (Punctal stenosis was identified based on epiphora symptoms and a reduction of the diameter of the punctum to less than 0.2 mm, as assessed by slit lamp inspection for visibility, morphology, as well as the occurrence of edoema or inflammation)

Special tests for ocular surface examination

Schirmer, I test (It was performed using schirmer paper (paper strips measuring 35 mm long, 5 mm wide). One end of the filter paper was folded 5 mm inward and hooked over the lower lid margin at junction between middle third and the lower lid outer third, without anesthetic use, avoiding contact with the cornea and eyelashes. The patient was instructed to shut his eyes softly. The filter paper was detached after 5 minutes, and its degree of wetness was determined and we considered wetting of less than 10 mm of the shirmer strip after 5 minutes abnormal value). Figure 1

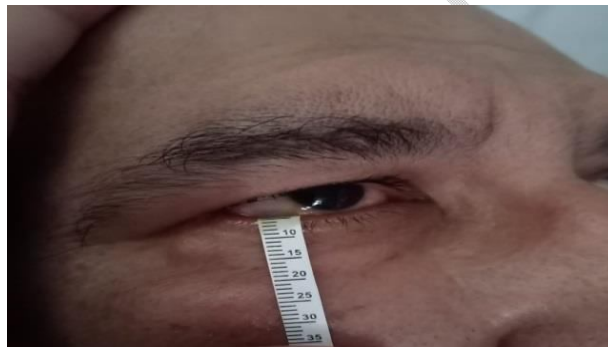

Figure 1: Schirmer test

Lower tear meniscus height (Tear Meniscus height (TMH) was determined midway down the lower eyelid right below the pupil's centre. Lower TMH was described as the difference between the top margin of the lower eyelid and the visible junction of the cornea and the lower tear meniscus. The TMH was determined between 0 and 1 mm using a 1-mm slit beam on a slit lamp biomicroscope).

Ocular surface staining (Rose Bengal staining, Fluorescein staining and Lissamine green staining). Figure 2

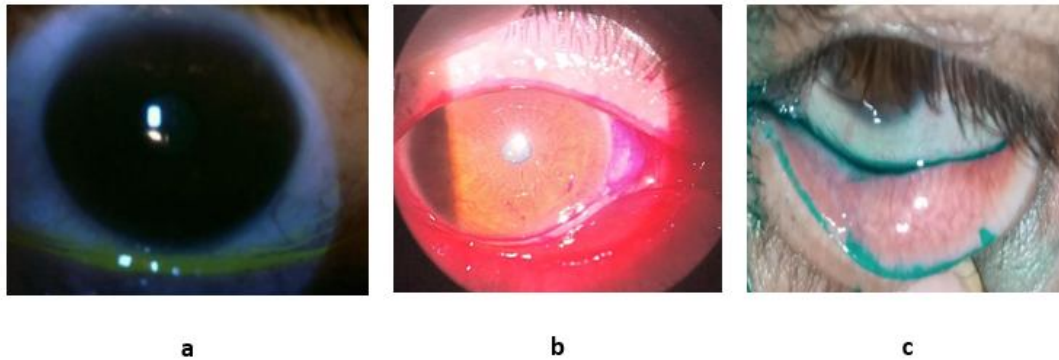


Figure 2: Fluorescein staining (a), Rose Bengal staining (b) and Lissamine green staining (c) of the ocular surface

Scoring systems (we used Van Bijsterveld system method to grade ocular surface staining (A grading system dividing the ocular surface into three zones: cornea, temporal bulbar conjunctiva and nasal bulbar conjunctiva. Each zone was rated on a scale from 0 to 3, with 0 suggesting no staining and 3 representing confluent staining; the maximum score achievable with this approach is 9))

Statistical analysis

Data were entered into the computer and analysed using version 20.0 of the IBM SPSS software suite. (Armonk, New York: IBM Corporation). Number and percent were utilized for representing qualitative data. The Kolmogorov-Smirnov test was performed to determine the distribution's normality. The range (minimum and maximum), mean, standard deviation, median, and interquartile range were used to characterise quantitative data (IQR). At the 5 % significant threshold, the acquired findings were deemed significant. A two tailed P value < 0.05 was considered significant. The used tests were paired t-test (for normally distributed quantitative variables, to compare between two periods, Friedman test (for abnormally distributed quantitative variables, to compare between more than two periods or stages and Post Hoc Test (Dunn's) for pairwise comparisons and Pearson coefficient (to correlate between two normally distributed quantitative variables).

Results:

Error! Not a valid bookmark self-reference. shows age, sex and causes of occlusion in the study patients.

Table 1: Age, sex and causes of occlusion in the study patients

		n=50
Age		50.10 ± 17.60
Sex	Males	24(48%)
	Females	26(52%)
Cause	Single cause	19(38%)
	combination of causes	31(62%)

Data are presented as mean ± SD or frequency (%).

Table 2 shows single, and combination causes of occlusion in the study patients

Table 2: Single and combination causes of occlusion in the study patients

		n=19
Single cause	Topical Anti-glaucoma ED	6 (31.6%)
	Congenital occlusion	4 (21.1%)
	Blepharitis	3 (15.8%)
	Irradiation	2(10.5%)
	lid malposition (punctal ectropion)	2(10.5%)
	5-fluorouracil	1(5.3%)
	Topical combined antibiotic-steroid ED	1(5.3%)
		n=31
combination of causes	post cataract surgery with blepharitis	11(35.5%)
	Anti-glaucoma and recurrent conjunctivitis	9 (29%)
	Infection +prolong use of mixed ED	5(16.1%)
	Dry eye syndrome + blepharitis	4 (12.9%)
	Trauma + lid malposition “ectropion”	2 (6.5%)

Data are presented as frequency (%).

Table 3 shows side of occlusion, punctum type and shape, grade of stenosis, Munk scale of, lower tear meniscus height and Schirmer test of the study patients.

Table 3: Side of occlusion, punctum type and shape, grade of stenosis, Munk scale, lower tear meniscus height and Schirmer test of the study patients:

		n=50
Side of occlusion	Unilateral	25 (50%)
	Bilateral	25 (50%)
Type	Occlusion	10(20%)
	Stenosis	40(80%)
Shape	Pinpoint	18(36%)
	Horseshoe	13(26%)
	Membranous	11(22%)
	Slit	8 (16%)
Grade of stenosis	Grade 0	10(20%)
	Grade 1	11(22%)
	Grade 2	29(58%)
Munk scale	Grade 1	5(10%)
	Grade 2	7(14%)
	Grade 3	12(24%)
	Grade 4	26(52%)
Lower tear meniscus height	< 0.1	5(10%)
	0.1	5(10%)
	0.2	5(10%)
	0.3	6(12%)
	0.4	1(2%)
	> 0.4	28(56%)
Schirmer	14.24 ± 6.7	

Data are presented as mean ± SD or frequency (%).

Age, sex, shape of occlusion and Munk scale were insignificant different between study groups. occlusion was significantly higher in single cause than combination of causes while stenosis was significantly lower in single cause than combination of causes groups. Grades of stenosis were significantly different between the two groups. **Table 4**

Table 4: Age, sex, type, and shape of occlusion between study groups

	Single cause	Combination of causes	P
	N=19	N=31	

Age		44.21 ± 22.43	53.71 ± 12.97	0.063
Sex	Males	9 (47.4%)	15(48.4%)	0.944
	Females	10 (52.6%)	16 (51.6%)	
Type	Occlusion	7 (36.8%)	3 (9.7%)	0.020*
	Stenosis	12 (63.2%)	28 (90.3%)	
Shape	Horseshoe	5 (26.3%)	8 (25.8%)	0.190
	Membranous	2 (10.5%)	9 (29.0%)	
	Pinpoint	10 (52.6%)	8 (25.8%)	
	Slit	2(10.5%)	6 (19.4%)	
Grade of stenosis	Grade 0	8 (42%)	2(6.5%)	0.007*
	Grade 1	2 (5.3%)	9(29%)	
	Grade 2	9 (47.4%)	20(64.5%)	
Munk scale	Grade 1	2(10.5%)	3(9.7%)	0.248
	Grade 2	1(5.3%)	6(19.4%)	
	Grade 3	3(15.8%)	9(29%)	
	Grade 4	13(68.4%)	13(41.9%)	

Data are presented as mean ± SD or frequency (%), *: significant as p value < 0.05

Schirmer test, lower tear meniscus height, and side of lesion were insignificantly different between study groups. **Table 5**

Table 5: Schirmer test, lower tear meniscus height, and side of lesion between study groups

		Single cause N=19	combination of causes N=31	P
Schirmer test		15.2 ± 5.60	13.68 ± 5.88	0.343
Lower tear meniscus height	< 0.1	3(15.8%)	2(6.5%)	0.135
	0.1	13(68.4%)	15(48.4%)	
	0.2	0 (0.0%)	5(16.1%)	
	0.3	1(5.3%)	4(12.9%)	
	0.4	1(5.3%)	5(16.1%)	
	> 0.4	1(5.3%)	0(0.0%)	
Side	Unilateral	11(57.9%)	14(45.2%)	0.382
	Bilateral	8 (42.1%)	17(54.8%)	

Data are presented as mean ± SD or frequency (%)

Discussion

Along with canalicular or nasolacrimal duct blockage, punctum stenosis is one of the most common reasons of epiphora. It can be acquired or inherited. Acquired punctum stenosis may be caused by inflammatory or infectious eye illness, toxicity from systemic or topical medicine and lid malposition, various types of trauma or age-related alterations^[3].

We noticed association between punctual ectropion and punctual stenosis as shown in studies of Kashkouli et al.^[1], Ulusoy et al.^[8] and Bukhari et al.^[9] who revealed that a strong relationship between lid malposition and punctual stenosis.

We also assessed the relationship between punctual stenosis and blepharitis with dry eye. We found 12.9% of cases had dry eye accompanied with blepharitis disease, but we did not find any significant relationship between dry eye and punctum stenosis. We found blepharitis associated with other conditions predisposed to punctual stenosis.

Chronic lid inflammation, particularly chronic blepharitis, continues to be a common cause of acquired punctal stenosis. Chronic inflammation of the external punctum is hypothesised to lead to gradual fibrotic alterations in the ostium, accompanied with progressive blockage of the duct. Dry eye syndrome, that may be a consequence of persistent blepharitis, has also been proposed as a causal cause^[9].

Our findings were the same as Ulusoy et al.^[8] and Kim et al.^[10] who reported that chronic blepharitis predisposes individuals to external punctual stenosis on the basis of the inflammatory and cicatricial changes.

As well, Hur et al.^[11] reported that blepharitis was accounted for 41.8% of cases while Kashkouli et al.^[1] found 41.7% to 97% of patients with punctal stenosis were accompanied by blepharitis

On other hand, Viso et al. ^[12] revealed that there were there was no relationship with blepharitis, meibomian gland dysfunction, or pseudoexfoliation. There was no relationship with dry eye symptoms, including epiphora.

We also noticed Schirmer I tests of all the patients was from 4 mm to 24 mm with no statistically significant.

While Liu et al. ^[13] on their study in treatment of punctum stenosis, found that the range of their Schirmer I tests of all the cases was from 3 mm to 12 mm preoperatively with wide interpersonal variation.

As well, the study of Viso et al. ^[12] revealed that no relationship with dry eye symptoms, including epiphora and with any dry eye tests except the Schirmer test = 5 mm, which were not statistically significant.

Moreover, tear meniscus height was elevated > 0.4 mm in most of our studied cases. Our findings were the same as Hur et al. ^[11] and Kim et al., ^[10] tear meniscus was higher in patients with punctual stenosis.

Nevertheless, correlation of the tear meniscus height and Schirmer test with causes of the punctum stenosis was insignificant which was like the study of Hur et al. ^[11]

Age-related and atrophy-related alterations can produce thick fibrous structures in the punctum to become less robust and the adjacent orbicularis fibres to be atonic, leading to punctal stenosis ^[14].

We did a correlation between the previous causes and age; we noted that multiple causes of punctual occlusion related to aging.

Kristan et al. ^[14] and Kashkouli et al. ^[1] also demonstrated that punctual stenosis was significantly correlated with increasing age.

In this investigation, individuals were identified as having a stenotic punctum on the basis of the shapes observed using a slit light. The distribution of the four forms of puncta is 36 %,

with the pinpoint type being the majority followed by Horseshoe type 26%, membranous type 22% and slit type 16%.

Hur et al. ^[11] categorized punctal stenosis into four types: pinpoint type (32.9%), horseshoe type (31.6%), membranous type (21.5%) and slit type (13.9%).

According to grades of stenosis, the majority of cases in our series 58% had grade 2 stenosed puncta, followed by 22% of grade 1 and 20% with grade 0. By using Munk scale, the most relevant grade was grade 4 represent 52% grade 3 was 24%, grade 2 was 14% and grade 1 was 10% of the studied subjects

On the other hand, Ozgur et al. ^[15] had 77.8% with covered papilla with a membrane (grade 1) and 22.2 % of eyes exhibited smaller-than-average puncta (grade 2).

While Mandour et al. ^[16] study enrolled 24 eyes of 18 cases' management of acquired severe lower punctal stenosis. All individuals had grade 0 punctal stenosis. Grade 3 preoperative epiphora was in 37.5% and grade 4 in 62.5%.

In addition, the results of Tamer et al. ^[17] revealed that 46 eyes (57.5%) had Grade 1 punctal stenosis, and 34 eyes (42.5%) had Grade 2. Twenty-four eyes (30%) had epiphora Grade 3 and 56 eyes (70%) had epiphora Grade 4.

Conclusions:

Punctal stenosis was a very common finding among patients visiting the oculoplastic clinic suffering from epiphora as examined by slit lamp. Age tended to augment the prevalence of punctal stenosis, and many patients accompanied by post-cataract surgery combined with blepharitis then topical Anti-glaucoma eye drops with recurrent conjunctivitis were most common association with Punctal stenosis patients who had combination of causes. Also, we found that topical anti glaucomatous drops were most common association with Punctal stenosis patients who had single cause.

References:

1. Kashkouli MB, Beigi B, Murthy R, Astbury N. Acquired external punctal stenosis: etiology and associated findings. *Am J Ophthalmol.* 2003;136:1079-84.
2. Kashkouli MB, Beigi B, Astbury N. Acquired external punctal stenosis: surgical management and long-term follow-up. *Orbit.* 2005;24:73-8.
3. Soiberman U, Kakizaki H, Selva D, Leibovitch I. Punctal stenosis: definition, diagnosis, and treatment. *Clin Ophthalmol.* 2012;6:1011-8.
4. Mansur C, Pfeiffer ML, Esmaeli B. Evaluation and Management of Chemotherapy-Induced Epiphora, Punctal and Canalicular Stenosis, and Nasolacrimal Duct Obstruction. *Ophthalmic Plast Reconstr Surg.* 2017;33:9-12.
5. Esmaeli B, Golio D, Lubecki L, Ajani J. Canalicular and nasolacrimal duct blockage: an ocular side effect associated with the antineoplastic drug S-1. *Am J Ophthalmol.* 2005;140:325-7.
6. Ma'luf RN, Hamush NG, Awwad ST, Nouredin BN. Mitomycin C as adjunct therapy in correcting punctal stenosis. *Ophthalmic Plast Reconstr Surg.* 2002;18:285-8.
7. Konuk O, Urgancioglu B, Unal M. Long-term success rate of perforated punctal plugs in the management of acquired punctal stenosis. *Ophthalmic Plast Reconstr Surg.* 2008;24:399-402.
8. Schmid KE, Kornek GV, Scheithauer W, Binder S. Update on ocular complications of systemic cancer chemotherapy. *Surv Ophthalmol.* 2006;51:19-40.
9. Bukhari A. Prevalence of punctal stenosis among ophthalmology patients. *Middle East Afr J Ophthalmol.* 2009;16:85-7.
10. Kim SE, Lee SJ, Lee SY, Yoon JS. Outcomes of 4-snip punctoplasty for severe punctal stenosis: measurement of tear meniscus height by optical coherence tomography. *Am J Ophthalmol.* 2012;153:769-73.

11. Hur MC, Jin SW, Roh MS, Jeong WJ, Ryu WY, Kwon YH, et al. Classification of Lacrimal Punctal Stenosis and Its Related Histopathological Feature in Patients with Epiphora. *Korean J Ophthalmol.* 2017;31:375-82.
12. Viso E, Rodríguez-Ares MT, Gude F. Prevalence and associations of external punctal stenosis in a general population in Spain. *Cornea.* 2012;31:1240-5.
13. Liu D, Sadhan Y. Surgical punctal occlusion: a prospective study. *Br J Ophthalmol.* 2002;86:1031-4.
14. Kristan RW. Treatment of lacrimal punctal stenosis with a one-snip canaliculotomy and temporary punctal plugs. *Arch Ophthalmol.* 1988;106:878-9.
15. Ozgur OR, Akcay L, Tutas N, Karadag O. Management of acquired punctal stenosis with perforated punctal plugs. *Saudi J Ophthalmol.* 2015;29:205-9.
16. Mandour SS, Said-Ahmed KE, Khairy HA, Elsayy MF, Zaky MA. A simple surgical approach for the management of acquired severe lower punctal stenosis. *J Ophthalmol.* 2019;2019:853-7.
17. Tamer SS, Abdelghany AA, Elshafei AM, Abdelrahman Abdallah RM. Three-snip punctoplasty versus perforated plugs for management of lacrimal punctal stenosis. *Eur J Ophthalmol.* 2021;31:796-803.