

Original Research Article

Outcome of Minimally invasive plate osteosynthesis for Comminuted Diaphyseal Humeral fractures

ABSTRACT

Aims: To examine the clinical outcomes of the minimally invasive plate osteosynthesis technique for comminuted diaphyseal humeral fractures based on clinical and radiologic records.

Study design: Prospective study.

Place and Duration of Study: This study was carried on twenty-one adult patients with comminuted humeral shaft fracture treated with MIPO between February 2020 to February 2021 were included in this study.

Methods: Patients with pathological fracture, Gustilo and Anderson type 2 or 3, intra-articular fracture and preoperative radial nerve palsy were excluded. The surgery time, blood loss and time of union were noted. Clinical outcome was assessed by Q-DASH score.

Results: We had thirteen cases of 12-B type and eight cases of 12-C type of fracture. According to Q-DASH score, eighteen cases had satisfactory results. The mean radiological fracture union time was 13.85 weeks. Mean elbow flexion was 125⁰, mean extension range was -2.14⁰. out of all cases, two cases had superficial wound infection. One patient had iatrogenic radial nerve palsy. One patient had non-union.

Conclusion: Although technically demanding, MIPO technically should be considered one of the management options in the treatment of complex humeral diaphyseal fractures as it adheres to biological fixation principles with minimal soft tissue dissection, preserving fracture hematoma and periosteal blood supply.

Keywords: humeral shaft fracture, minimally invasive plate osteosynthesis, outcomes.

1. INTRODUCTION

Humeral Shaft fractures account for roughly 3% of all long-bone fractures [1]. The treatment of humeral shaft fractures ranged from closed methods, external fixation, antegrade and retrograde intramedullary nailing and plating, to minimally invasive osteosynthesis [2].

The use of a functional brace as a non-surgical treatment results in a high rate of union and good function. The unavoidable long immobilization time, malunion, elbow stiffness, and possible radial nerve injury during closed reduction appear to be the disadvantages [2,3].

The surgical treatment of these fractures with open reduction and internal fixation (ORIF) provides stable fixation for early elbow range of motion (ROM) [4,5].

Even though posterior and lateral surgical approaches are more commonly used, nerve manipulation, extensive soft tissue stripping, and a long incision scar pose a risk of iatrogenic radial nerve injury. MIPO (minimally invasive plate osteosynthesis) has grown in popularity in recent years as a result of positive clinical outcomes in the treatment of middle diaphyseal humerus fractures [6,7].

Compared to open surgical procedures, MIPO has fewer soft tissue dissections, lower nonunion rates, and a lower risk of iatrogenic radial nerve palsy. It also allows for earlier functional treatment and increased postoperative ROM in neighboring joints [8].

2. MATERIAL AND METHODS

The study included twenty-one patients with comminuted humeral shaft fractures during the period from February 2020 to February 2021.

	Age			Sex		Dominant hand		Smoking		Mechanism of injury		AO classification		Medical condition	
	18-40	>40-60	>60	Male	Female	Non dominant	Dominant	Non smoker	Smoker	Indirect trauma	Direct trauma	12-B	12-C	Null	Present
No.	12	7	2	17	4	12	9	12	9	15	6	13	8	14	7
%	57.14	33.33	9.52	81.0	19.0	57.1	42.9	57.1	42.9	71.4	28.6	61.9	38.1	66.7	33.3

There is no risk to the participants of the study at all and ethical committee approval number 33760/3/20 from Tanta University was obtained. The study was conducted under the tenets of the Declaration of Helsinki and the guidelines of good clinical practice. Full counseling of the participants in this research about the nature of the study was obtained and informed consent was taken. The patients had provided informed consent for the case details and any accompanying images to be published.

Patients aged greater than 18 years old with comminuted closed and first-degree open fractures were included in this study. The exclusion criteria were humeral shaft fractures with primary radial nerve palsy, second and third-degree open fracture, Intra-articular fracture, and Pathological fracture. Sociodemographic data of the patients are presented in Table (1). The preoperative neurologic status was documented for all patients.

Table 1. Characteristics of the studied cases as regards age, sex, hand dominance, smoking, mechanism of injury, AO classification and medical condition

2.1 Operative Technique

The patient was placed in a supine position with his arm resting on a radiolucent table, the elbow was slightly flexed with a supinated forearm during the operation. An image intensifier (C-Arm) coming from the side of the injured limb.

The proximal incision is the lower portion of the deltopectoral approach, it exposes the proximal diaphysis just lateral to the bicipital tendon, using the biceps groove and pectoralis tendon as landmarks. The distal incision begins one to two cm proximal to the antecubital crease and extends few centimeters proximally in the midline Fig. (1-A). The biceps and brachialis are identified, and the biceps is retracted medially. Also, the lateral antebrachial cutaneous nerve is identified and protected.

Through the distal incision, the radial nerve is exposed between the brachialis and brachioradialis muscles Fig. (1-B).

The brachialis is then bluntly dissected longitudinally to the bone, with retractors or dissection limited laterally to avoid the radial nerve at this level. The forearm must be kept supinated throughout the procedure to protect the radial nerve Fig. (1-C).

The lateral antebrachial nerve was retracted together with the medial half of the brachialis, while the lateral half served as a cushion to protect the radial nerve. Then an extra periosteal sub brachialis tunnel is then created touching and passed along the anterior or slightly anteromedial aspect of the humerus. Fig. (1-D)

Manual traction is used to restore length and correct varus or valgus angulation and rotation, this was done gently to avoid radial nerve stretch. Reduction and plate position is checked under image intensification, Kirschner wires were used to temporarily secure the plate to the bone, followed by locking screw fixation. Finally, skin closure without a suction drain Fig. (1-E)

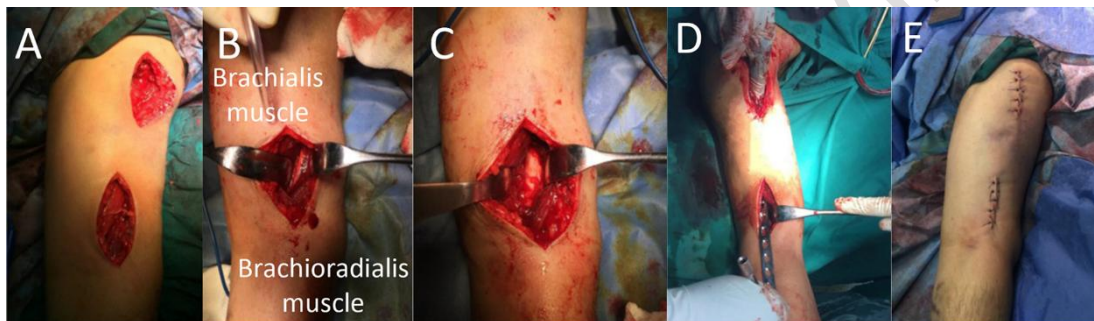


Fig. 1. A) proximal and distal incisions were made. B) Distal incision showing radial nerve between biceps and brachialis muscles. C) Splitting of brachialis muscle D) Extra periosteal sub brachialis tunnel. E) closure of skin without suction deain.

2.2 Postoperative Management

A pouch arm sling was used to support the arm. As soon as the patient's comfort allowed, gentle passive motions were started. Forceful arm use was discouraged, but gently assisted active ROM for the shoulder and elbow was quickly added.

All follow-up visits include clinical evaluations to determine the recovery of elbow and shoulder movements, as well as radiographic evaluations.

2.3 Evaluation and Follow-up

The surgery time, blood loss, complications, shoulder and elbow functions were recorded. Control radiographs were done immediately after the operation and in 4 weeks intervals to evaluate fixation and signs of radiological healing, which is by a callus bridging at least three cortices of the fracture fragments.

The functional outcome was evaluated by Quick Disabilities of the Arm, Shoulder and Hand (Q-DASH) score.

2.4 Statistical Analysis

Data were fed to the computer and analyzed using IBM SPSS software package version 20.0. (Armonk, NY: IBM Corp) Qualitative data were described using numbers and percentages. The Kolmogorov-Smirnov test was used to verify the normality of distribution Quantitative data were described using range (minimum and maximum), mean, standard deviation, median and interquartile range (IQR). The significance of the obtained results was judged at the 5% level.

3. RESULTS

In this study, we had treated 21 cases of closed humeral shaft fractures by minimally invasive plate osteosynthesis technique. Table (1) illustrates the sociodemographic pattern of patients with humeral shaft fractures who had been admitted during the period of the study and treated with MIPO. The average operative time was 60 (range 40–95) min, and the average intraoperative blood loss was 160 (range 80–250) ml. At the end of the follow-up, twenty patients were healed completely, one case had non-union. Thirteen patients had a solid union less than 14 weeks, seven patients in more than 14 weeks and one case had non-union 24 weeks post-operatively. Table (2) and Fig. (2)

Table 2. Distribution of the studied cases according to union (n=21)

	No.	%
Non Union	1	4.8
Union	20	95.2
Time of Union		
≤14 weeks	13	61.9
>14 weeks	7	33.3
Min. – Max.	12.0 – 20.0	
Mean ± SD.	13.85 ± 2.25	
Median (IQR)	13.0(12.0 – 16.0)	

IQR: Interquartile range

SD: Standard deviation

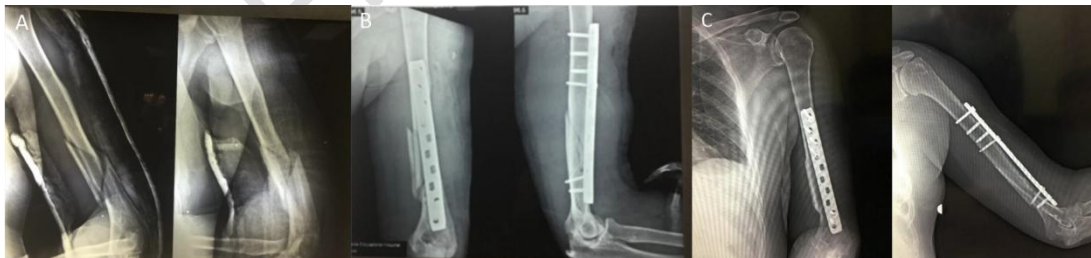

Fig. 2. A) X-ray of a patient with humeral shaft fractures preoperatively. B) X-ray of a patient with humeral shaft fractures postoperatively. C) X-ray films showed fractures united four months postoperatively.

According to Q-DASH score for the studied cases, eighteen cases had satisfactory results. On the other hand, three patients had unsatisfactory results. Table (3). And according to elbow ROM, flexion

ranged from (100 - 1300) with a mean of 1250, extension ranged from (-10 – 00) with a mean of -2.140 Fig. (3)

Table 3. Distribution of the studied cases according to Q-DASH score (n=21)

Q-DASH score	No.	%
Satisfactory	18	85.7
Excellent	14	66.7
Good	4	19.0
Unsatisfactory	3	14.3
Fair	2	9.5
Poor	1	4.8
Min. – Max.	3.0 – 35.0	
Mean ± SD.	10.81 ± 8.69	
Median (IQR)	9.0 (4.0 – 15.0)	

IQR: Inter quartile range

SD: Standard deviation

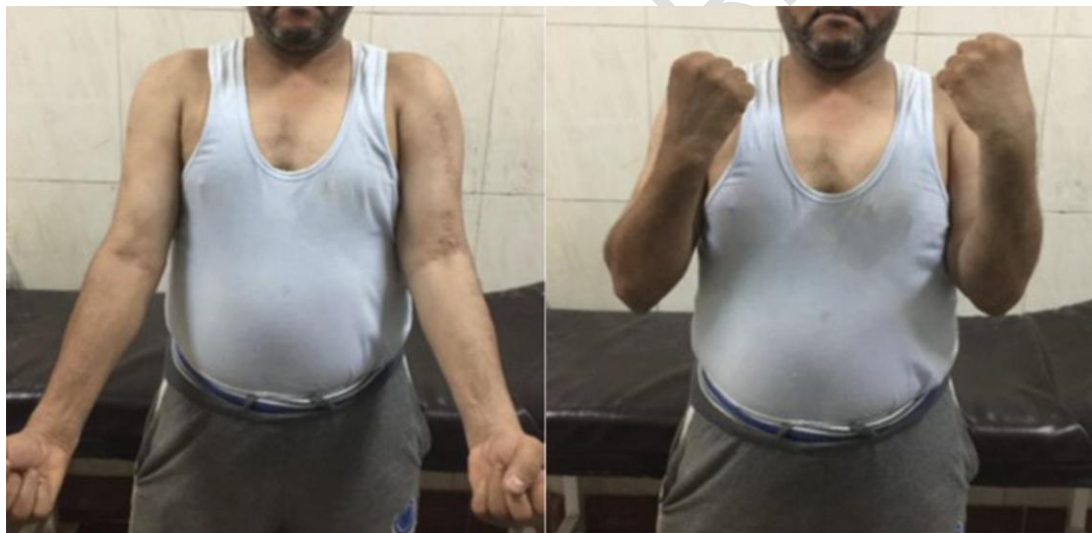

Fig. 3. The post-operative functional outcomes.

Healing time was found to have a statistically significant effect on the end results with the highest incidence of satisfactory results was found in patients with healing time less than 14 weeks (P = 0.025). Table (4)

Table 4. Relation between union and Q-DASH score (n=21)

Q-DASH score	Union (weeks)				Non-Union [#]		Total	
	≤14 week		>14 week		No.	%	No.	%
	No.	%	No.	%				
Excellent	11	84.6	3	42.9	0	0.0	14	66.7

Good	1	7.7	3	42.9	0	0.0	4	19.0
Fair	1	7.7	1	14.3	0	0.0	2	9.5
Poor	0	0.0	0	0.0	1	100.0	1	4.8
Total	13	100.0	7	100.0	1	100.0	21	100.0
χ^2 (^{MC} p)	5.640 (0.056)							
Min. – Max.	3.0 – 25.0		3.0 – 25.0				3.0 – 35.0	
Mean ± SD.	7.54 ± 6.25		13.43 ± 6.68		35.0		10.81 ± 8.69	
Median	5.0		15.0				9.0	
Total	13		7		1		21	
U (p)	21.0 (0.025*)							

χ^2 : Chi square test MC: Monte Carlo U: Mann Whitney test

p: p value for comparing between the union groups

*: Statistically significant at $p \leq 0.05$

#: considered >14 week in the comparison

Complications were encountered in four patients, two cases had superficial wound infection that was managed by a continuation of oral antibiotics and frequent dressing, one patient had iatrogenic radial nerve palsy due to tractional injury at the distal incision and one patient had non-union after 8 months from surgery. The presence of complications had a significant effect on the clinical outcomes ($P < 0.001$) Table (5)

Table 5. Relation between Q-DASH score and post-operative complication (n=21)

Post-operative complication	Q-DASH score								Total	
	Excellent		Good		Fair		Poor			
	No.	%	No.	%	No.	%	No.	%	No.	%
Null	14	100.0	3	75.0	0	0.0	0	0.0	17	81.0
Nonunion	0	0.0	0	0.0	0	0.0	1	100.0	1	4.8
Radial nerve palsy	0	0.0	1	25.0	0	0.0	0	0.0	1	4.8
Superficial wound infection	0	0.0	0	0.0	2	100.0	0	0.0	2	9.5
Total	14	100.0	4	100.0	2	100.0	1	100.0	21	100.0
χ^2 (^{MC} p)	23.984* (<0.001*)									

χ^2 : Chi square test

MC: Monte Carlo

p: p value for comparing between the DASH score groups

*: Statistically significant at $p \leq 0.05$

4. DISCUSSION

Although non-operative treatment of humeral shaft fracture results in satisfactory clinical and functional outcomes in the majority of cases, it causes varus deformity and limits shoulder and elbow motion in some patients [9]. This option is not ideal for young active people (athletes and manual workers) who need to start their activities as soon as possible [10].

IMN has produced positive results due to its strength and load-sharing characteristics, minimal soft tissue dissection, and lower risk of radial nerve damage [11]. However, this treatment also has its

limitations [2]. Furthermore, nail insertion from the humeral head or olecranon fossa can result in shoulder impingement or elbow fracture [12,13].

Humeral plating has been accepted as the standard technique for humeral shaft fracture fixation. The technique has several benefits, including a lower reoperation rate, a high union rate, anatomical reduction, and fewer shoulder and elbow morbidities [9].

MIPO is a new procedure for treating humeral shaft fractures that require close attention to the periosteum, muscles, and nerves. This technique is commonly used for shaft fractures and metaphyseal fractures associated with osteoporosis that can be treated with indirect reduction as anatomical reduction is not required, as well as comminuted fractures that can be treated with bridging plate fixation and achieve good results [12,14].

This technique has the advantage of requiring less soft tissue dissection and avoiding the need to expose the radial nerve, resulting in a lower risk of iatrogenic radial nerve palsies and deep infection [15]. Risks of nerve injury are much greater in conventional plating [16]. Furthermore, the rotator cuff is not damaged, preventing major shoulder pathology later on, as is the case with humeral nailing [10].

In our study, 21 cases of comminuted fracture shaft humerus were surgically treated by minimally invasive plate osteosynthesis. The mean operative time was 101.9 minutes (range 90 - 120 minutes), which was calculated from skin incision to wound closure. Our mean intraoperative blood loss was 90.95 cc (range of 70-120 cc). Our findings are similar to those found in the literature [12,17–20]. and slightly longer than some literature [15,21–23]. It was possibly attributed to our learning curve and the different surgical experiences of surgeons who performed the operation.

In a study held by Lian et al. [20], 24 patients with mid-distal humeral shaft fracture in the MIPO group, the mean surgical time was 95 minutes, the mean blood loss is 147 ml, which were significantly lower than those of IMN group. Also, Hadhoud et al. [15], in a study of 15 patients with humeral shaft fractures treated with MIPO, the mean operative time was 80.7 minutes (range of 70–90 minutes) and the mean intraoperative blood loss was 92 ml (range of 70–120 ml) which were significantly lower than that of ORIF group with operative time 125.3 min (range 110–140 min) and 366 ml (range 300–450 ml) intraoperative blood loss.

In this study, twenty cases achieved complete bony union (95.2%), with an average union time of 13.85 weeks \pm 2.25 SD. Only one case had nonunion (4.8%); which was a comminuted fracture of middle shaft humerus, probably due to malrotation with forearm pronation, indicating that it may be difficult to indirectly reduce all fractures accurately without a fracture gap and maintain the reduction during the MIPO procedure. These findings stand side by side to those found in the literature [9,12,25–27,15,17–20,22–24].

In a study held by Oh et al. [12], the union was achieved in 90.5% of the cases treated with MIPO technique with an average union time of 17.3 weeks, which was similar to 87% of the cases treated with ORIF with an average union time of 16.7 weeks. In this study, there was no significant difference in union between the two groups although union rate was higher in MIPO group. Nonunion after MIPO was a comminuted fracture of the distal shaft, with inappropriate fixation and poor stability.

In the present study, the type of the fracture had a significant effect on the functional outcome of the elbow according to Q-DASH score but not on the radiological outcome, with the highest incidence of satisfactory results (radiological and clinical) in less comminuted fractures. our result was consistent with that found in the literature [12]. This is explained as displaced and comminuted fractures

frequently result in delayed healing. The avascular fragments of splintered bone require resorption, a more extensive inflammatory and callus phase and more time to remodel [28,29].

In the present study, 18 (85.7%) cases had satisfactory Q-DASH score and 3 (14.3%) cases had unsatisfactory Q-DASH score, 2 cases who had superficial wound infection and medical comorbidities had fair outcomes and one case who had nonunion had a poor outcome. The mean Q-DASH score was 10.81 ± 8.69 SD. Which agrees with those in literature [17,18,22,26]. Also, several studies reported similar functional outcomes for MIPO and ORIF techniques [9,12].

Randell et al. [30], reported a favorable functional outcome score in the MIPO group with a mean DASH score of 17.0 ± 18.0 . in contrast to the ORIF group with 24.9 ± 19.5 , however, that was not significantly different from that of the MIPO group.

In the present study, elbow ROM after 6 months follow up ranged from (1000-1300) in flexion with mean (1250 ± 7.250) SD, (-100 – 00) and mean (-2.140 ± 4.050) in extension. One case had elbow flexion 1000, this reduced ROM occurred after nonunion. Our result agrees with Zhao et al. [24], in which elbow function was evaluated postoperatively at three months, and the average ROM was 135.18° (SD ± 10.76), ranging from 110° to 150° .

In comparison with IMN, Lian et al. [20], reported that the fractures healed with simultaneous shoulder abduction and elbow flexion limitations due to nail impingement. When compared to the uninjured side, these patients had a decrease in shoulder or elbow joint ROM of approximately 25° to 45° . Furthermore, they required more time for functional recovery of the shoulder and elbow than those who underwent minimally invasive plating osteosynthesis. They underwent nail extraction once fracture union occurred.

To avoid plate impingement and allow the operated limb to be used for daily activities as soon as possible, the distance between the distal fracture line and the upper edge of the coronoid fossa should be greater than 6 cm to accept three screws in the distal fragment [20]. In the present study, only 2 screws could be used distally in cases with distal one-third fractures, and there was no implant failure or loss of fixation. We believe that union occurs before the implant can become loose because of the preserved good vascularity of fragments [31].

When using MIPO, iatrogenic injury may harm the blood supply of the fractured part. One of the most frequently damaged nerves in long bone fractures appears to be the radial nerve [21]. In the present study, there was a lower complication rate that was comparable to previous literature [17,18,22,23,25,32] compared to ORIF [12,15,30].

The danger zone for the radial nerve is located 36.35–59.2 percent of the humeral length away from the lateral epicondyle, i.e., primarily in the middle third of the humeral shaft [18]. When using the anterior approach, no screws are inserted into the part of the shaft where the radial nerve runs along the spiral groove, which is critical for radial nerve preservation [20].

There was only one case of postoperative radial nerve palsy in the present study probably from careless traction to achieve distal exposure. A revision fixation was done after a week through posterior approach with an exploration of the radial nerve which was found intact along its course and reapplication of the plate posteriorly. The nerve recovered completely after 6 months. This complication may be avoided by having a well-prepared team, with knowledge of the local anatomy and training in the surgical technique proposed. The division of the brachial muscle is necessary to protect the radial nerve, allowing the surgical technique to be performed without viewing and dissecting this nerve. Our result stands side to side with those in previous studies [12,21,22,26,31,33], with a lower risk of radial nerve injury in comparison to other techniques [15,20,34,35].

According to the demographic data of the patients, there was a significant correlation between age and the healing time, the older the age, the longer the healing time. As with increasing age, Variations in fracture healing have been linked to age-related dysfunction of the bone vascular system and its ability to regenerate during healing. In general, the skeleton's vascular perfusion decreases with age [36]. Whereas the patient's gender, hand dominance, associated injuries, type and site of fracture had an insignificant correlation to the bone healing.

In the present study, we found that the lifestyle of the patients clinically affects them according to the Q-DASH score. There was a significant correlation between smoking and healing time and subsequently the functional outcome. Bones are nourished by blood much like the other organs and tissues in our body. Smoking raises the levels of nicotine in the blood, causing blood vessels to constrict to about 25% of their normal diameter. Reduced nutrient levels are supplied to the bones as a result of vessel constriction. This is thought to be the cause of the effect on bone healing [37]. According to Wang et al. [34], a comparative study, 2 out of 3 cases of nonunion (2 cases from ORIF group and a case from MIPO group) were heavy smokers.

Also, we found that there was a significant effect of the other comorbidities on bone healing. We had two diabetic patients, three hypertensive patients and two diabetic-hypertensive patients, affected directly by the radiological and functional follow-up.

These diseases cause systemic disturbances that are linked to bone loss and secondary osteoporosis, as well as increased fracture risk. Many of the pro-inflammatory cytokines abundant in these diseases (interleukin-I, interleukin-6, tumor necrosis factor) strongly affect both osteoblasts and osteoclasts, resulting in increased osteoclasts and decreased numbers of osteoblasts and bone formation, disrupting the balance between bone resorption and formation, with higher complication rates, including non-unions and disrupting the remodeling process [38].

Our study has some limitations such as a small sample size, and we did not have a control group for comparison. A larger multicenter study with control groups will help us to arrive at a definitive conclusion. Secondly, the malrotation of the humerus after union could not be accurately calculated as no postoperative computed tomography scans were done. So, the humeral retroversion angle was not evaluated. However, there was no case of severe rotational restriction in our patients; implying that any major rotational malalignment was unlikely.

5. CONCLUSION

In conclusion, the current study's findings show that, despite being technically demanding, the anterior MIPO technique appears to be a safe and effective method for treating comminuted humeral shaft fractures. It adheres to biological fixation principles with minimal soft tissue dissection, preserving fracture hematoma and periosteal blood supply. However, when performing the distal incision, the radial nerve must be carefully addressed. These findings confirm that MIPO can achieve functional and clinical outcomes that are highly comparable to routine ORIF while posing a significantly lower risk of postoperative complications. Radiation exposure from the image intensifier is a source of concern.

Data Availability: The datasets used and analyzed during this study are available from the corresponding author on reasonable request.

CONSENT

Informed consent was obtained from all patients before their participation. Every patient was given a code number and his anonymity was preserved (his personal data was omitted).

ETHICAL APPROVAL

All procedures performed were following the ethical standards of our institutional ethical committee and with the 1964 Helsinki declaration and its later amendments or comparable ethical standards. Informed consent was obtained from all patients before their participation. Every patient was given a code number and his anonymity was preserved (his personal data was omitted). The study was approved by the ethical research committee of the faculty of medicine - Tanta University under the code: 33760/3/20

COMPETING INTERESTS DISCLAIMER:

Authors have declared that no competing interests exist. The products used for this research are commonly and predominantly use products in our area of research and country. There is absolutely no conflict of interest between the authors and producers of the products because we do not intend to use these products as an avenue for any litigation but for the advancement of knowledge. Also, the research was not funded by the producing company rather it was funded by personal efforts of the authors.

REFERENCES

1. Updegrave GF, Mourad W, Abboud JA. Humeral shaft fractures. *J shoulder Elb Surg.* 2018;27(4):e87-e97. doi:10.1016/j.jse.2017.10.028
2. Gallusser N, Barimani B, Vauclair F. Humeral shaft fractures. Stannard JP, Schmidt AH, eds. *EFORT open Rev.* 2021;6(1):24-34. doi:10.1302/2058-5241.6.200033
3. Jawa A, McCarty P, Doornberg J, Harris M, Ring D. Extra-articular distal-third diaphyseal fractures of the humerus. A comparison of functional bracing and plate fixation. *J Bone Joint Surg Am.* 2006;88(11):2343-2347. doi:10.2106/JBJS.F.00334
4. Capo JT, Debkowska MP, Liporace F, Beutel BG, Melamed E. Outcomes of distal humerus diaphyseal injuries fixed with a single-column anatomic plate. *Int Orthop.* 2014;38(5):1037-1043. doi:10.1007/s00264-013-2213-x
5. Prasarn ML, Ahn J, Paul O, et al. Dual plating for fractures of the distal third of the humeral shaft. *J Orthop Trauma.* 2011;25(1):57-63. doi:10.1097/BOT.0b013e3181df96a7
6. Livani B, Belangero WD, Castro de Medeiros R. Fractures of the distal third of the humerus with palsy of the radial nerve: management using minimally-invasive percutaneous plate osteosynthesis. *J Bone Joint Surg Br.* 2006;88(12):1625-1628. doi:10.1302/0301-620X.88B12.17924
7. Zhiquan A, Bingfang Z, Yeming W, Chi Z, Peiyan H. Minimally invasive plating osteosynthesis (MIPO) of middle and distal third humeral shaft fractures. *J Orthop Trauma.* 2007;21(9):628-633. doi:10.1097/BOT.0b013e31815928c2

8. Huri G, Biçer ÖS, Öztürk H, Deveci MA, Tan I. Functional outcomes of minimal invasive percutaneous plate osteosynthesis (MIPPO) in humerus shaft fractures: a clinical study. *Acta Orthop Traumatol Turc.* 2014;48(4):406-412. doi:10.3944/AOTT.2014.13.0009
9. Esmailiejah AA, Abbasian MR, Safdari F, Ashoori K. Treatment of Humeral Shaft Fractures: Minimally Invasive Plate Osteosynthesis Versus Open Reduction and Internal Fixation. *Trauma Mon.* 2015;20(3):2-7. doi:10.5812/traumamon.26271v2
10. Mahajan AS, Kim YG, Kim JH, et al. Is Anterior Bridge Plating for Mid-Shaft Humeral Fractures a Suitable Option for Patients Predominantly Involved in Overhead Activities? A Functional Outcome Study in Athletes and Manual Laborers. *Clin Orthop Surg.* 2016;8(4):358-366. doi:10.4055/cios.2016.8.4.358
11. Putti AB, Uppin RB, Putti BB. Locked intramedullary nailing versus dynamic compression plating for humeral shaft fractures. *J Orthop Surg (Hong Kong).* 2009;17(2):139-141. doi:10.1177/230949900901700202
12. Oh CW, Byun YS, Oh JK, et al. Plating of humeral shaft fractures: comparison of standard conventional plating versus minimally invasive plating. *Orthop Traumatol Surg Res.* 2012;98(1):54-60. doi:10.1016/j.otsr.2011.09.016
13. Sharma GM, Bhardwaj AR, Shah S. Antegrade versus retrograde nailing in humeral shaft fractures: A prospective study. *J Clin Orthop trauma.* 2020;11(Suppl 1):S37-S41. doi:10.1016/j.jcot.2019.04.020
14. Ko SHH, Cha JRR, Lee CC, Joo YT, Eom KS. Minimally Invasive Plate Osteosynthesis Using a Screw Compression Method for Treatment of Humeral Shaft Fractures. *Clin Orthop Surg.* 2017;9(4):506-513. doi:10.4055/cios.2017.9.4.506
15. Hadhoud M, Darwish A, Mesriga MK. Minimally invasive plate osteosynthesis versus open reduction and plate fixation of humeral shaft fractures. *Menoufia Med J.* 2015;28(1):154. doi:10.4103/1110-2098.155974
16. Claessen FMAP, Peters RM, Verbeek DO, Helfet DL, Ring D. Factors associated with radial nerve palsy after operative treatment of diaphyseal humeral shaft fractures. *J shoulder Elb Surg.* 2015;24(11):e307-e311. doi:10.1016/j.jse.2015.07.012
17. Luthra M, Verma M. Role of Minimal Invasive Plate Osteosynthesis in Complex humeral Shaft Fractures. *IOSR J Dent Med Sci.* 2015;14:68-71. doi:10.9790/0853-14676871
18. Shetty MS, Kumar MA, Sujay KT, Kini AR, Kanthi KG. Minimally invasive plate osteosynthesis for humerus diaphyseal fractures. *Indian J Orthop.* 2011;45(6):520-526. doi:10.4103/0019-5413.87123
19. An Z, He X, Jiang C, Zhang C. Treatment of middle third humeral shaft fractures: Minimal invasive plate osteosynthesis versus expandable nailing. *Eur J Orthop Surg Traumatol.* 2012;22(3):193-199. doi:10.1007/s00590-011-0827-5

20. Lian K, Wang L, Lin D, Chen Z. Minimally invasive plating osteosynthesis for mid-distal third humeral shaft fractures. *Orthopedics*. 2013;36(8):1025-1032. doi:10.3928/01477447-20130724-18
21. Chen H, Hu X, Yang G, Xiang M. Clinic research on the treatment for humeral shaft fracture with minimal invasive plate osteosynthesis: a retrospective study of 128 cases. *Eur J Trauma Emerg Surg*. 2017;43(2):215-219. doi:10.1007/s00068-015-0616-7
22. Malhan S, Thomas S, Srivastav S, et al. Minimally invasive plate osteosynthesis using a locking compression plate for diaphyseal humeral fractures. *J Orthop Surg (Hong Kong)*. 2012;20(3):292-296. doi:10.1177/230949901202000305
23. Sharma J, Jain A, Jain PG, Upadhyaya P. Anterior Bridge Plating with Mini Incision MIPO Technique for Humerus Diaphyseal Fractures. *Indian J Orthop Surg*. 2015;1(3):171. doi:10.5958/2395-1362.2015.00022.5
24. Zhao W, Qu W, Fu C, Jiang H, Liu S, Cheng C. Antero-lateral minimally invasive plate osteosynthesis (MIPO) with the radial nerve exploration for extra-articular distal-third diaphyseal fractures of the humerus. *Int Orthop*. 2017;41(9):1757-1762. doi:10.1007/s00264-017-3514-2
25. Concha JM, Sandoval A, Streubel PN. Minimally invasive plate osteosynthesis for humeral shaft fractures: Are results reproducible? *Int Orthop*. 2010;34(8):1297-1305. doi:10.1007/s00264-009-0893-z
26. Deepak S, Holagundi L. Minimally invasive percutaneous plate osteosynthesis by anterior approach for fracture shaft of humerus. 2016;2(October 2013):22-26.
27. Shin SJ, Sohn HS, Do NH. Minimally invasive plate osteosynthesis of humeral shaft fractures: a technique to aid fracture reduction and minimize complications. *J Orthop Trauma*. 2012;26(10):585-589. doi:10.1097/BOT.0b013e318254895f
28. Wraight PJ, Scammell BE. Principles of fracture healing. *Found Years*. 2007;3(6):243-251. doi:10.1016/j.mpfou.2007.09.005
29. Nyary T, Scammell BE. Principles of bone and joint injuries and their healing. *Surg (United Kingdom)*. 2018;36(1):7-14. doi:10.1016/j.mpsur.2017.10.005
30. Randell M, Glatt V, Stabler A, et al. Anterior Minimally Invasive Plate Osteosynthesis for Humeral Shaft Fractures Is Safer Than Open Reduction Internal Fixation: A Matched Case-Controlled Comparison. *J Orthop Trauma*. 2021;35(8):424-429. doi:10.1097/BOT.0000000000002021
31. Pospula W, Abu Noor T. Percutaneous fixation of comminuted fractures of the humerus: initial experience at Al Razi hospital, Kuwait. *Med Princ Pract*. 2006;15(6):423-426. doi:10.1159/000095487
32. Apivatthakakul T, Phornphutkul C, Laohapoonrungrsee A, Sirirungruangarn Y. Less invasive

- plate osteosynthesis in humeral shaft fractures. *Oper Orthop Traumatol*. 2009;21(6):602-613. doi:10.1007/s00064-009-2008-9
33. Livani B, Belangero WD. Bridging plate osteosynthesis of humeral shaft fractures. *Injury*. 2004;35(6):587-595. doi:10.1016/j.injury.2003.12.003
 34. Wang C, Li J, Li Y, Dai G, Wang M. Is minimally invasive plating osteosynthesis for humeral shaft fracture advantageous compared with the conventional open technique? *J Shoulder Elb Surg*. 2015;24(11):1741-1748. doi:10.1016/j.jse.2015.07.032
 35. An Z, He X, Zeng B. A comparative study on open reduction and plating osteosynthesis and minimal invasive plating osteosynthesis in treating mid-distal humeral shaft fractures. *Chinese J Reparative Reconstr Surg*. 2009;23(1):41-44.
 36. Clark D, Nakamura M, Miclau T, Marcucio R. Effects of Aging on Fracture Healing. *Curr Osteoporos Rep*. 2017;15(6):601-608. doi:10.1007/s11914-017-0413-9
 37. Sloan A, Hussain I, Maqsood M, Eremin O, El-Sheemy M. The effects of smoking on fracture healing. *Surgeon*. 2010;8(2):111-116. doi:10.1016/j.surge.2009.10.014
 38. Claes L, Recknagel S, Ignatius A. Fracture healing under healthy and inflammatory conditions. *Nat Rev Rheumatol*. 2012;8(3):133-143. doi:10.1038/nrrheum.2012.1

ABBREVIATIONS

Open reduction and internal fixation (ORIF)

Range of motion (ROM)

Minimally invasive plate osteosynthesis (MIPO)

Quick Disabilities of the Arm, Shoulder and Hand (Q-DASH) score.