

Case study

CASE REPORTS ON TRACHEO - BRONCHIAL STENOSIS - CONSERVATIVE VS SURGICAL APPROACH

ABSTRACT

Stenosis of bronchial tree can occur in tuberculosis, malignancy and post- intubation.

Tracheal and airway stenosis remains a challenging area for pulmonologists and require interventions to cure the patients. In most cases, patients will present with breathlessness, stridor, hoarseness of voice, unable to expectorate. In some cases, patient will require emergency intubation and securement of airway before the treatment of stenosis. Stenosis of bronchial tree can occur in tuberculosis,malignancy,post intubation. Stenosis can present with breathlessness,cough and stridor.

Intubation may cause mucosal damage and inflammation, granulation tissue formation, cartilage destruction, tracheomalacia and tracheal stenosis. Among these, post intubation tracheal stenosis has worst outcome and require interventions. Early diagnosis of this complication may change the natural history of the disease. If early diagnosis can be established , then bronchoscopy and balloon dilatation, stenting can be done , otherwise patient might have to undergo tracheostomy.

KEY WORDS: Tracheal stenosis, post intubation airway stenosis, endobronchial tubercular stenosis,, stricture of trachea, balloon dilatation, silicone stenting

INTRODUCTION

Patients with tracheobronchial stenosis due to tuberculosis (TSTB) have a variable clinical course and response to treatment including airway intervention. There are no clear guidelines on the best approach to manage such patients. Airway stenosis is a technically challenging pathology to deal with and there are various aetiologies which can lead to the stenosis , trauma, mostly related to intubation, is the commonest reason for tracheal stenosis ⁽¹⁾.

Tracheobronchial tuberculosis (TBTB) is reported in approximately 10% to 39% of the patients with pulmonary tuberculosis. Bronchoscopy is the most definite method of diagnosis which provides adequate specimens for microbiological and histopathological diagnosis. Tracheobronchial stenosis is one of the most common long term complications of TBTB resulting in significant morbidity⁽²⁾.

CASE 1

24 year old male, got admitted in intensive care unit in an outside hospital with encephalopathy and got intubated in view of respiratory distress. Post intubation, there was difficult weaning and patient got tracheostomised. After 6 months, patient got removed of tracheostomy, post tracheostomy closure, patient was sent home. After 1 week, patient presented to our emergency department with severe stridor and respiratory distress. Patient was admitted in intensive care, attempted Montgomery T tube insertion by ENT surgeon, respiratory distress persisted. Hence patient was intubated again. Then bronchoscopy had been performed, subglottic stenosis visualised.(Figure 1)

Then patient was given 2 options, surgical resection and anastomoses or silicone stenting. The relatives opted for silicone stenting. Repeat check bronchoscopy performed, stenosed segment is 13 mm. Then performed rigid bronchoscopy and put silicone stenting in the stenosed subglottic segment(Figure 2).

Post silicone stenting, patient's stridor resolved, respiration became stable. Patient is on regular follow up and position of stent had been confirmed after one month. Patient is having stent in situ for last 1.5 years, and check bronchoscopies performed serially ruled out infection.

CASE 2

17 year old male, admitted with stridor and respiratory distress. He had a history of consuming organo phosphorous poisoning one month back, and was intubated then.

On examination, his pulse rate was 124 beats per minute, blood pressure 120/70 mmhg, respiratory rate 24 breaths per minute, and spo2 90 % room air. He was given emergency nebulisations and taken up for bronchoscopy. There was multiple level tracheal strictures seen starting from around 2-3 cm below the vocal cords, and extending for 6-7 cm below the vocal cord, and extending for 6-7 cm length upto mid trachea, bronchoscope was not passing below the level of obstruction (figure 3). APC done under vision, followed by balloon dilatation (figure 4), and tracheal lumen increased upto 50 % of total diameter. Bronchoscope could be passed distally. Distal trachea was normal. We advised silicone stenting of airway as a permanent solution, which they were not willing. Then patient was admitted one month later with similar complaints, and balloon dilatation was done to relieve symptoms, however patient and relatives were not keen on doing stenting.

CASE 3

33 year old female, presented to pulmonology opd with complaints of breathlessness on exertion ,MMRC grade 3. She also gives history of pulmonary tuberculosis 5 years back, for which 6 months complete treatment taken. On examination, her vitals were stable. Patient's spirometry showed moderate to severe obstruction with no reversibility. Her chest radiograph showed complete collapse of left lung (figure 6). HRCT thorax showed complete collapse of left lung with compensatory hyper inflation of right lung (figure 7).

We did bronchoscopy and found that left main bronchus is completely obstructed with a small mucosal pit. (figure 8).

Guide wire had been passed initially, then cauterisation done followed by balloon dilatation. Bronchus opened up (figure 9), post procedure chest radiograph showed that the lungs are opened (figure 10) and patient became symptomatically better.

CASE 4

78 year old female came to pulmonology out patient department with history of breathlessness on exertion for 2 months, MMRC grade 2. Patient gives history of childhood tuberculosis for which complete treatment had been taken.

Patient had similar history 8 months for which she was evaluated.

She was sputum gene expert positive with rifampicin sensitive. She had taken 6 months course of anti tubercular treatment and stopped 2 months back.

She also have history of diabetes, hypertension and ischemic heart disease.

On examination, she was vitally stable.

Her chest radiograph showed complete collapse of left lung (figure 12) while her chest radiograph 6 months back were normal (figure 13).

In HRCT , left lung is completely collapsed and right lung is hyper inflated (figure 14)

Bronchoscopy done and visualised complete obstruction of left main bronchus.

Considering her age , comorbidities and symptomatology, and autopneumectomy, patient didn't underwent dilatation and cauterisation. She is stable on follow up.

DISCUSSION

CLINICAL DISCUSSION

Tracheo bronchial stenosis can occur congenitally or acquired. Most cases of tracheal stenosis develop as a result of prolonged breathing assistance known as intubation or from a surgical tracheostomy. The symptoms include wheezing, stridor, chest congestion, recurrent pneumonia ⁽³⁾.

IMAGING DISCUSSION

Eccentric or concentric soft tissue thickening internal to normal-appearing tracheal cartilage may be visible. The outer tracheal wall has a normal appearance without evidence of deformity or narrowing. Expiratory CT shows little change in tracheal diameter ⁽⁴⁾.

MANAGEMENT

The tracheal stenosis can be managed by surgical resection and anastomosis, tracheal laser surgery, tracheal dilatation and tracheal stent ⁽⁵⁾. the short term treatment options are laser surgery and dilatation, while surgical resection and anastomosis the promising long term treatment option ⁽³⁾. Patients who require more than one session of balloon dilatation may need more definitive treatment such as stenting or ablative procedures ^(6,7).

REVIEW OF LITERATURE

The trauma related to intubation is most common cause of tracheal stenosis ⁽¹⁾. Intubation-related trauma is the commonest one ^(1,8), and the incidence of glottic stenosis related to intubation trauma varies from 4% to 14% ^(1,9). Mucosal injuries

during intubation at the level of glottis commonly occur at the medial surface of vocal process of arytenoids and interarytenoid region ^(1,10).

In endobronchial tuberculosis, Left bronchial involvement is seen more frequently than right bronchial or tracheal involvement ^(2,11). It is postulated that the left mainstem bronchus is anatomically compressed by the aortic arch and the left mediastinal lymph nodes tend to get infected faster than the right sided lymph nodes, resulting in increased vulnerability of the left main stem bronchus to endobronchial infection in TBTB.

The treatment for airway stenosis due to tuberculosis is to control infection if there is active disease, steroids, medical management and bronchoscopic methods like APC, balloon dilatation and stenting ⁽²⁾.

From our experience of managing the airway stenosis, there should be a personalised approach for each patient. The 2 cases of post tubercular bronchial stenosis was treated in 2 different ways where elderly lady with co - morbidities was given an option of medical management while young lady was treated with APC and balloon dilatation. The 2 cases of post intubation tracheal stenosis was managed separately where one case managed with silicone stenting and second case managed with balloon dilatation and cauterisation.

CONCLUSION

The management of airway stenosis is complicated and it requires categorising the patient according to their co-morbidities, activities in daily living and personalise the approach.

FIGURES

Figure 1) Subglottic stenosis

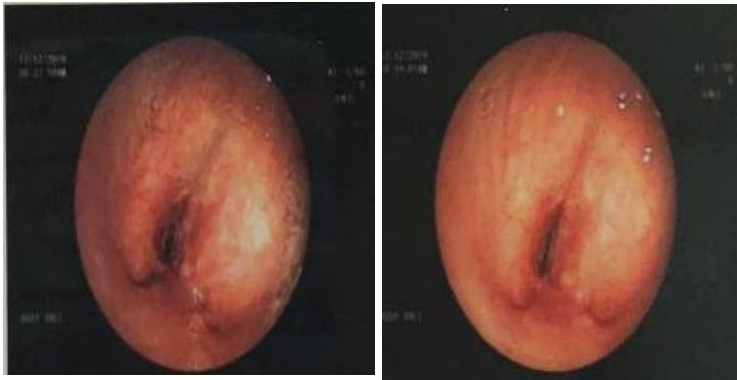


Figure 2) Silicone Stenting

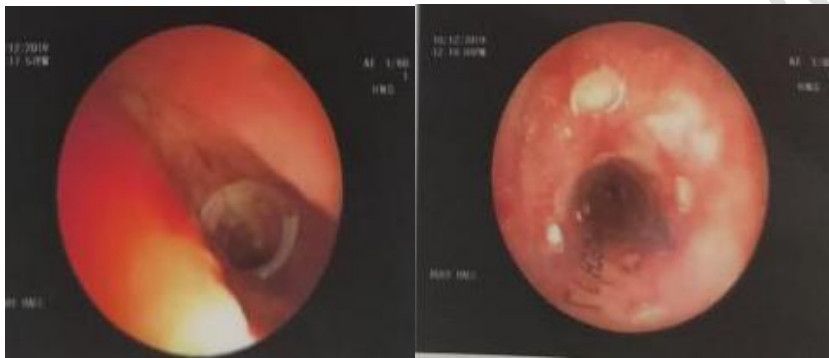


Figure 3) The subglottic stenosis visualised by bronchoscopy

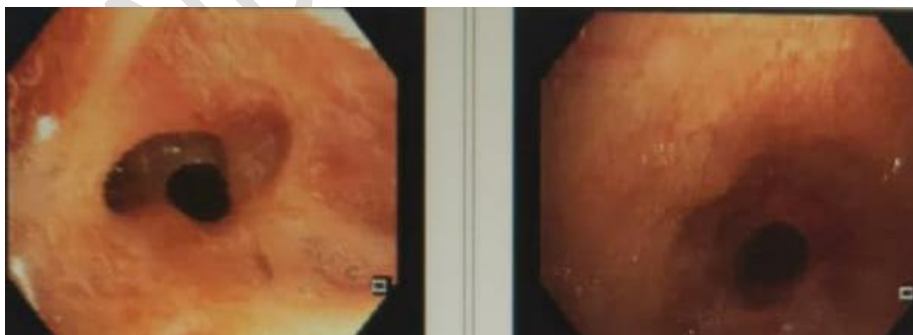


Figure 4) Balloon dilatation and APC cautery done

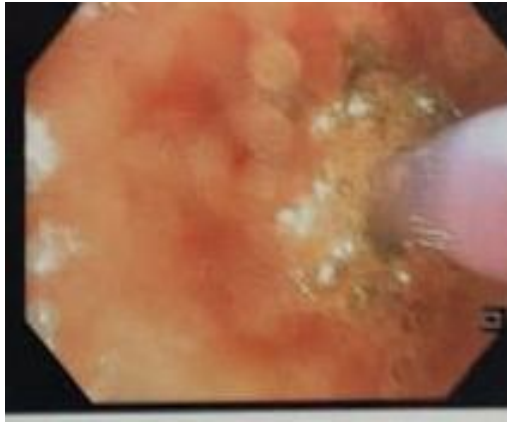


Figure 5) The dilated airway after dilatation and APC cautery

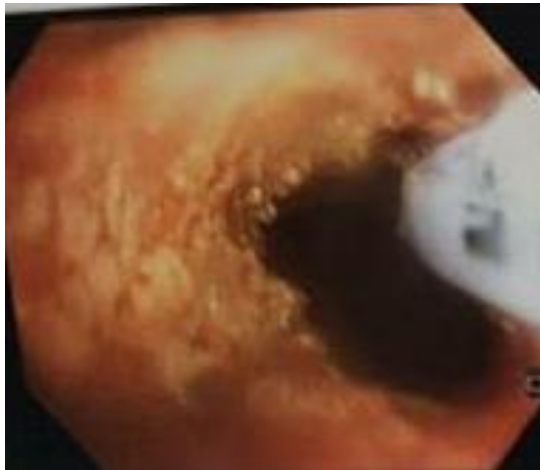


Figure 6) Chest radiograph showing complete collapse of left lung

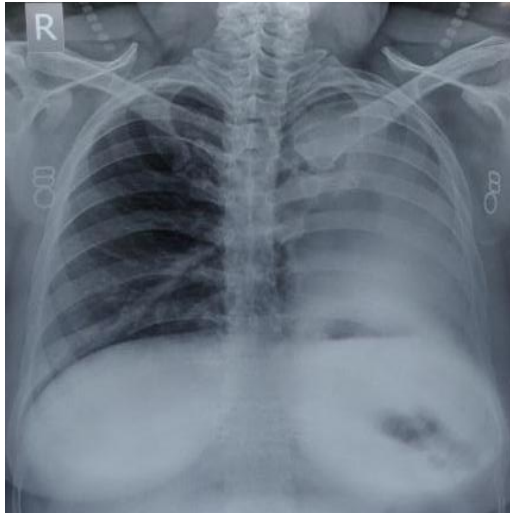

Figure 7) HRCT thorax showed complete collapse of left lung with compensatory hyper inflation of right lung

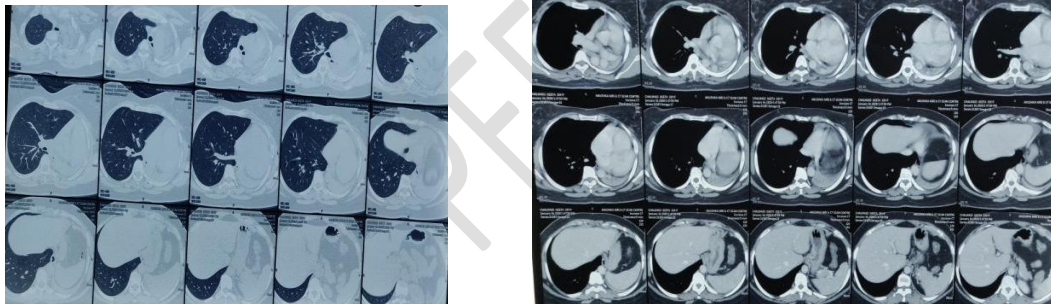


Figure 8) Bronchoscopy showing the completely obstructed left main bronchus.

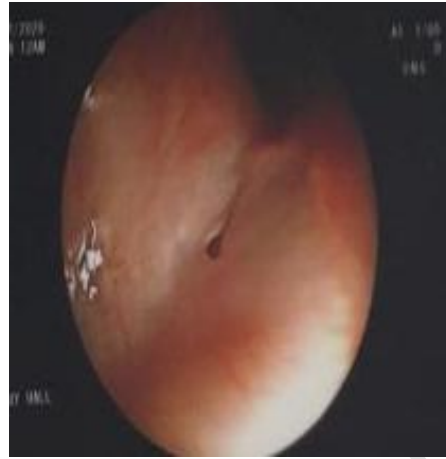
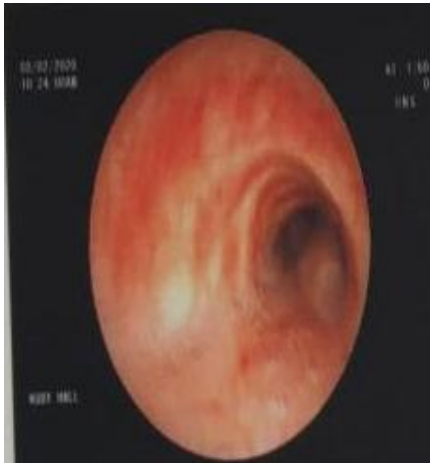


Figure 9) Guide wire passed through the mucosal pit.

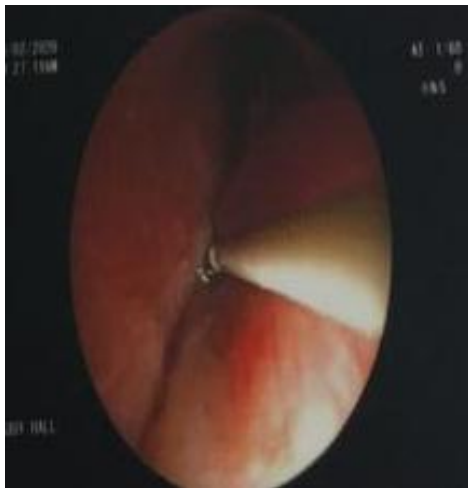

Figure 10) The bronchus open up on the left side post dilatation.

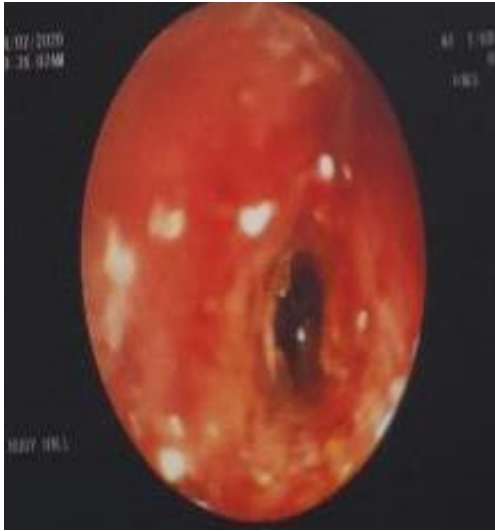


Figure 11) The chest radiograph post procedure shows the expanding lung.

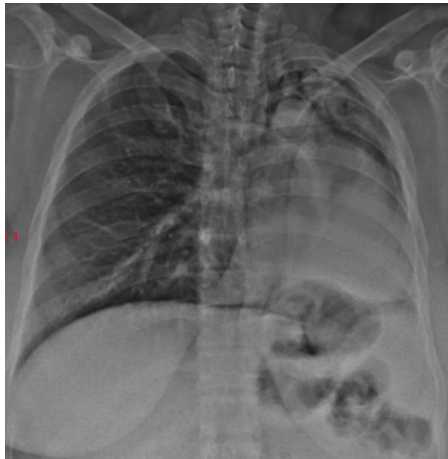

Figure 12) chest radiograph showing left lung collapse.

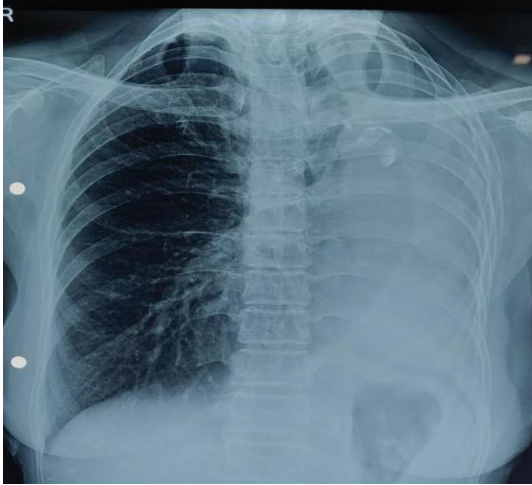


Figure 13) chest radiograph 6 months earlier

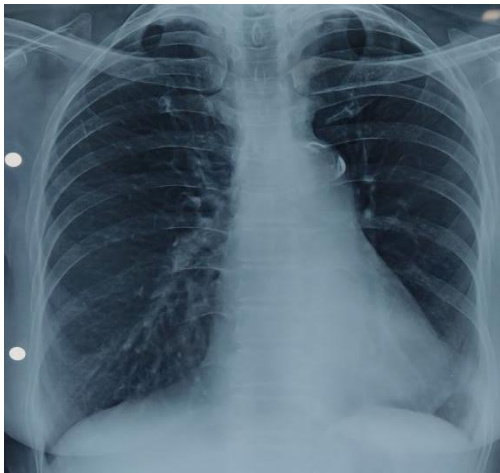
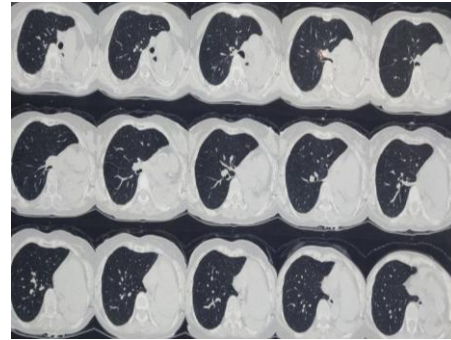
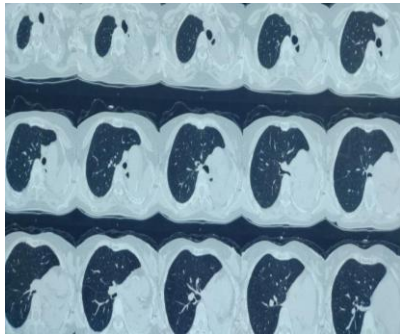


Figure 14) HRCT thorax showing left lung collapse with compensatory hyperinflation on left



REFERENCES

- 1) Gyawali BR, Pradhananga RB, Acharya K, Dutta H, Neupane Y, Baskota DK, et al. Aetiopathogenesis of laryngotracheal stenosis: A retrospective review. *Int J Otolaryngol* [Internet]. 2020;2020:1–6. Available from: <http://dx.doi.org/10.1155/2020/1941046>
- 2) Pathak V, Shepherd RW, Shojaee S. Tracheobronchial tuberculosis. *J Thorac Dis* [Internet]. 2016;8(12):3818–25. Available from: <http://dx.doi.org/10.21037/jtd.2016.12.75>
- 3) *Tracheal stenosis*. (n.d.). Cedars-Sinai. Retrieved January 13, 2022, from <https://www.cedars-sinai.org/health-library/diseases-and-conditions/t/tracheal-stenosis.html>
- 4) The Radswiki. (n.d.). *Tracheal stenosis*. Radiopaedia. Retrieved January 13, 2022, from <https://radiopaedia.org/articles/tracheal-stenosis>
- 5) *Tracheal Stenosis*. (n.d.). Mount Sinai Health System. Retrieved January 13, 2022, from <https://www.mountsinai.org/care/ent/services/tracheal-surgery/tracheal-stenosis>
- 6) Shitrit, D., Kuchuk, M., Zismanov, V., Rahman, N. A., Amital, A., & Kramer, M. R. (2010). Bronchoscopic balloon dilatation of tracheobronchial stenosis: long-term follow-up. *European Journal of Cardio-Thoracic Surgery: Official Journal of the European Association for Cardio-Thoracic Surgery*, 38(2), 198–202. <https://doi.org/10.1016/j.ejcts.2009.11.056>
- 7) Faisal, M., Harun, H., Hassan, T. M., Ban, A. Y. L., Chotirmall, S. H., & Abdul Rahaman, J. A. (2016). Treatment of multiple-level tracheobronchial stenosis secondary to endobronchial tuberculosis using bronchoscopic balloon dilatation with topical mitomycin-C. *BMC Pulmonary Medicine*, 16(1), 53. <https://doi.org/10.1186/s12890-016-0209-1>
- 8) K. A. Stephenson and M. E. Wyatt, “Glottic stenosis,” *Seminars in Pediatric Surgery*, vol. 25, no. 3, pp. 132–137, 2016.
- 9) Howard, N. S., Shiba, T. L., Pesce, J. E., & Chhetri, D. K. (2015). Photodocumentation of the development of type I posterior glottic stenosis after intubation injury. *Case Reports in Surgery*, 2015, 504791. <https://doi.org/10.1155/2015/504791>
- 10) Benjamin, B., & Holinger, L. D. (2008). Laryngeal complications of endotracheal intubation, ” *Annals of Otolaryngology, Rhinology & Laryngology*, 117(9), 1–20.

11) Lee, J. H., Park, S. S., Lee, D. H., Shin, D. H., Yang, S. C., & Yoo, B. M. (1992). Endobronchial tuberculosis. Clinical and bronchoscopic features in 121 cases. *Chest*, *102*(4), 990–994. <https://doi.org/10.1378/chest.102.4.990>.

UNDER PEER REVIEW