

## **Triceps Reflection Versus Olecranon Osteotomy Approach in Supracondylar Intercondylar Distal Humeral Fractures Managed by Open Reduction and Internal Fixation in Adults**

### **Abstract:**

**Background:** Intercondylar fracture humerus needs early treatment consequently, the surgical approach becomes very crucial. Many approaches have been described for this fracture type. Approaches such as triceps-reflecting and olecranon osteotomy are frequently used.

**Aim of Work:** is to assess the functional and radiological outcomes of olecranon osteotomy and triceps reflection in adults with supracondylar intercondylar distal humerus fractures treated with double plating.

**Patients and Methods:** To achieve the study's goal, a non-randomized controlled clinical trial was used. Patients with supracondylar intercondylar humerus fractures were admitted to Tanta University's orthopedic department and Cairo's El-Helal hospital.. Total number of cases (21 patients) included in the study as a thorough sample during the research period (6 months). The medical records and radiographs of 13 male and 8 female patients, all above the age of 18, were prospectively evaluated after a 6-month follow-up period. Triceps reflection was performed on 52.4 percent of patients, while olecranon osteotomy was performed on 47.6 percent. The results of treatment were evaluated using a modified version of Mayo-Elbow performance score (MEPS).

**Results:** All of the patients were assessed both before and after surgery. In the triceps-reflection group, 9 patients regarded good, 1 got excellent, and 1 got fair MEPS, whereas in the olecranon-osteotomy group, 7 patients got good, 1 got fair, and 2 got excellent MEPS. The olecranon-osteotomy technique gives greater control over the elbow joint and better visualization, especially if with C3 type. The functional results of distal humerus fractures disclosed by the triceps-reflection and olecranon-osteotomy approaches were comparable.

**Conclusion:** In C3 type, the olecranon-osteotomy technique offers more control over the elbow joint and better visualization, whereas in other types, the triceps-reflection and olecranon-osteotomy approaches, in treatment of supracondylar intercondylar distal humerus fractures with triceps-reflection and olecranon-osteotomy both methods are safe.

**Key Words:** Triceps; Sparing; Olecranon

**Background:**

Intra-articular and comminuted fractures of the distal humerus intercondylar (DHIF) are invariably accompanied with soft tissue injury <sup>(1)</sup>. The complexity of anatomy causes additional treatment challenges for DHIF. Patients with DHIF are currently treated with a surgical procedure that involves parallel or orthogonal plate fixation of the medial and lateral columns. The disadvantages of soft tissue dissection, subsequent scarring, and non-union, however, remain obstacles for DHIF <sup>(2,3)</sup>.

Because it can reveal articular discrepancies, olecranon osteotomy is now regarded the gold standard procedure before open reduction and internal fixation. For comminuted fractures, a para-tricipital incision might anatomically minimize and fix DHIF <sup>(4)</sup>. The locking compression plate and distal humerus plate system were linked to high-quality reconstructions and stability, allowing patients with DHIF to fast recovery. Despite advancements in implant, surgical, and fixation procedures, DHIF still has several complications. Whether the treatment effectiveness of olecranon osteotomy is superior than triceps-sparing approach for DHIF patients remains debated <sup>(4)</sup>.

**Aim of Work:** is to assess the functional and radiological outcomes of olecranon osteotomy and triceps reflection in adults with supracondylar intercondylar distal humerus fractures treated with double plating approach.

**Patients and Methods:**

To achieve the study's goal, a non-randomized controlled clinical trial was used. Patients with supracondylar intercondylar humerus fractures were admitted to Tanta University's orthopedic department and Cairo's El-helal hospital.. Total number of cases (21 patients) included in the study as a comprehensive trials during the research period (6 months). The medical records and radiographs of 13 male and 8

female patients, all above the age of 18, were prospectively evaluated after a 6-month follow-up period. **Study Population:**

Patients hospitalized to the Orthopedic Department with a distal humerus fracture were included in the research. **Inclusion Criteria:**

- Skeletally mature patients.
- Age: above 18 years

**Exclusion Criteria:**

- Skeletally Immature patients.
- Open fractures.
- Pathological fractures.
- Periprosthetic fractures.

Patient of with hepatic comorbidity were excluded to take part in this study.

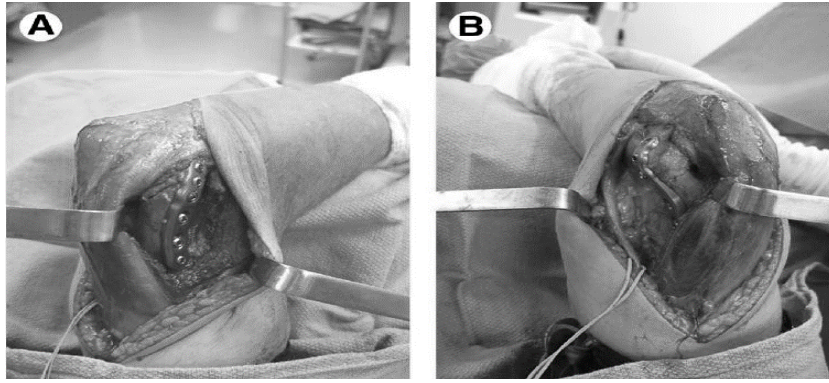
**Operational Design:**

The clinical data of the patients was recorded. The patient's medical history was obtained, which included the date of the injury and the specifics of the original and subsequent therapy. . The general examination, local examination, and associated sections of the physical examination were all reported. An antero-posterior (AP) view of the elbow and a lateral view of the affected humerus are used in radiographic examination. Computed tomography (CT).

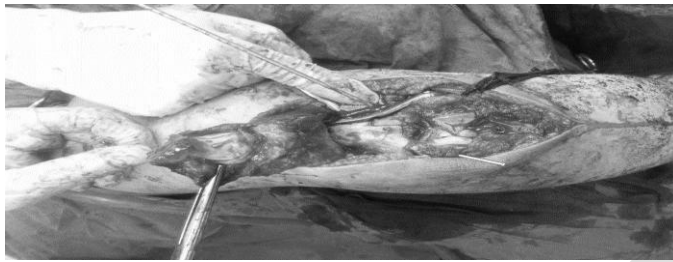Laboratory investigations: The patients had the following pre-operative routine lab investigation as follows: complete blood count, fasting and random blood glucose levels, bleeding profile, Liver function tests and kidney function tests.

**Management plan:**

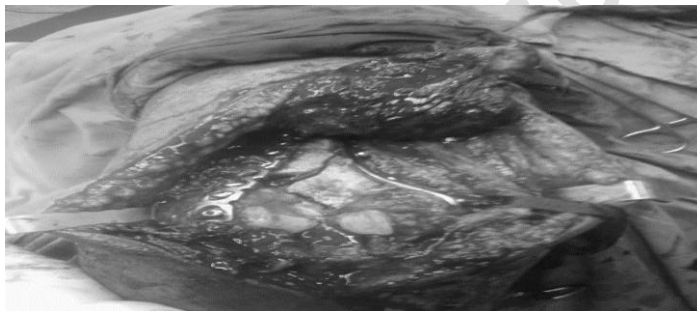
The following characteristics were observed in all patients with supracondylar intercondylar humerus fractures in this study: **Preoperative plan:** A complete history was gathered, as well as the examination, laboratory, and radiological investigation outlined earlier. **Intra operative management:** 52.4 % of patients had triceps reflection (fig1), and 47.6 % had olecranon osteotomy after surgery (fig2)..



**Figure (1): Triceps- Reflection approach (A, B).**



(A)



(B)

**Figure (2): Olecranon osteotomy approach in two different patients, (A,B)**

- **Post-operative treatment:** In our study, we used to give 3rd generation cephalosporins like (cefoperazone or ceftriaxone), penicillin and its derivatives like cloxacillin for two weeks until the stitches were removed, as well as strong analgesics and antiedematous drugs for the same time period, and daily dressing until the stitches were removed.
- **Rehabilitation and Outcome:** To avoid the formation of intra-articular adhesions and peri-articular fibrosis, which would render the elbow stiff,

early postoperative physiotherapy was performed. The starting point of physiotherapy was the most crucial indicator of the ultimate result. .

- **Follow up:** For at least six months, all of the patients were followed up on. The following data were collected at the end of the follow-up period: :

**Clinically:** Physical examination, neurovascular examination, axial alignment evaluation, and functional analysis were all part of the clinical evaluation. . Functional recovery was assessed using Mayo-Elbow performance score. Mayo-Elbow performance score of 90 to 100 points was considered excellent; 75-89 points, good; 60-74 points, fair; and less than 60, poor.

**Radiologically:** The following characteristics help us distinguish between neutral and poor alignment and reduction: The levels of unity, the distal and proximal pieces are aligned and infection symptoms (figs 3 and 4).

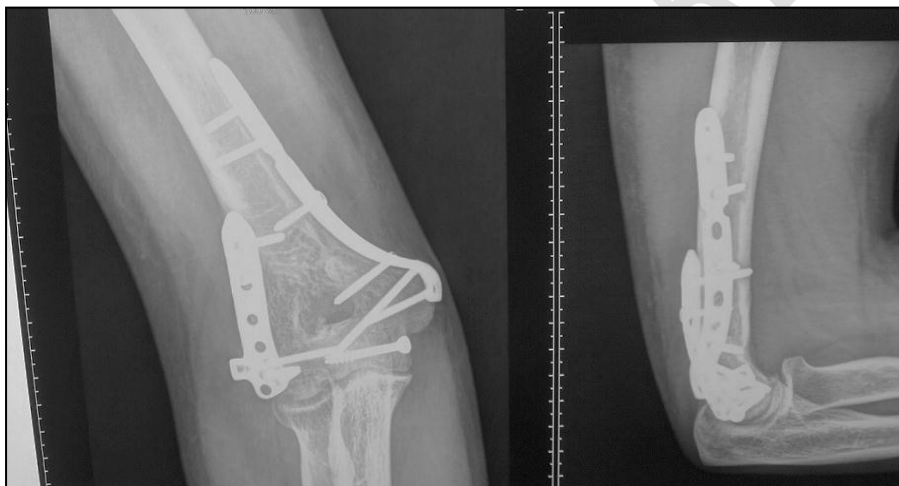

Figure3. Case 1- 39 years old male. MBA.RT distal humeral fracture. Fracture pattern: C2. Associated fractures: none. Time till surgery: 4 days. Approach: triceps reflecting, follow up X-rays at 24 months. complete union. ROM: flexion-extension 5°-120°. MEPS 100

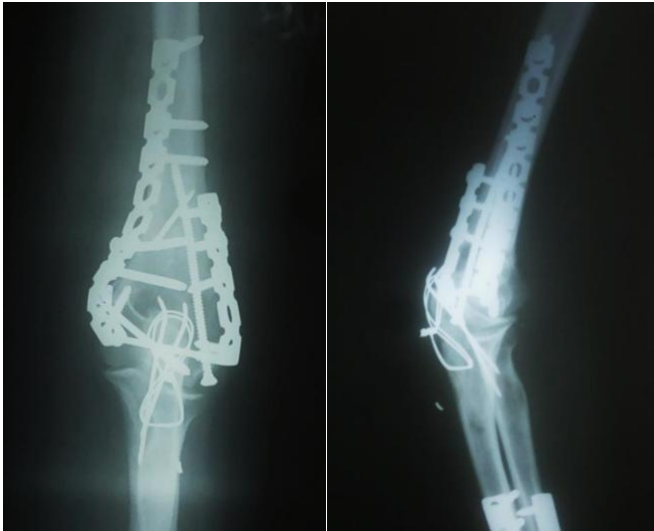


Figure4. Case 2-29 yr. old female. MOT: RTA. Type and side: LT distal humeral fracture. Fracture pattern: C3. Associated fractures: none. Time till surgery: 5 days. Approach: Olecranon osteotomy. Follow up X-ray at 6 months. complete union .ROM: flexion-extension 10°-130°. MEPS 100 points.

### **Statistical Analysis of the Data**

The obtained results were statistically analyzed using IBM SPSS software package version 20.0. (Armonk, NY: IBM Corp). Qualitative data were described using numbers and percent. The Kolmogorov-Smirnov test was used to verify the normality of distribution. Quantitative data were described using range (minimum and maximum), mean, standard deviation, median and interquartile range (IQR). Significance of the obtained results was judged at the 5% level.

### **Result:**

Regarding occupation, the average age of the 21 patients was 25.43, with 38.1 % of females and 61.9 % percent of men. Sedentary work accounted for 76.2 %, while heavy manual works accounted for 23.8 %. The most common AO type of fractures was C2, which accounted for 57.1 % of cases, to lesser extent of other types with average values of 28.6% and 14.3% for C1 and C3, respectively. However, values

recorded 38.1 % and 33.3% of low T shape and high T shape, respectively. The Y shape pattern was observed in 23.8% and only 4.8% recorded comminuted fracture. The etiology of trauma was either a fall down the stairs, a road traffic accident (28.6%), a motorcycle accident (23.8%), or a vehicle accident (19%). There were no associated diseases in 71.4 % of patients, 19 % were diabetic, and 9.5 % were hypertensive. Associated fractures were observed in 85.7 % of patients, ipsilateral proximal ulna fractures were recorded in 9.5 % of patients, and metacarpal fractures were seen in 4.8 % of cases. The average time from the start of the trauma to admission was 30.62 hours. 76.2 % of postoperative alignment was neutral, whereas 23.8 % was suboptimal, according to postoperative data. The average ROM after surgery was 112.48. The mean MPES was 81.9, with the majority of cases having good MEPS (76.2%), excellent 14.3%, and fair 9.5 percent (table1). Overall, 95.2 % of patients having united fractures and 4.8 % having delayed union. When comparing two techniques and various parameters, it was discovered that there were no significant differences between the two procedures in terms of preoperative data and result (tables 2 and 3) In all approaches, there was no significant relationship between Mayo elbow performance score and other factors. Complications occurred in three patients, including delayed union in one olecranon-osteotomy patient (10%) and superficial infection in one olecranon-osteotomy patient (10%). The debridement was done, because it was a superficial infection, the implant did not need to be removed, although there was a delay in union. Many factors influence union and functional outcomes; for example, some elderly patients experienced delayed union and took longer to return to work. Younger age groups, on the other hand, achieved good functional and union results in a short period of time. Diabetes mellitus (DM) was not shown to be substantially linked to union, although it did necessitate meticulous wound care. Long operational time, suboptimal alignment, and limited ROM were all unfavorable prognostic markers for fracture type C3. Early good ROM was difficult for some cases because of the suboptimal alignment and necessitating a physiotherapy treatment.

**Table1. Distribution of the studied cases according to mayo elbow performance score (n=21)**

Mayo Elbow Performance Score	No.	%
Fair	2	9.5
Good	16	76.2
Excellent	3	14.3
Min. – Max.	69.0 – 93.0	
Mean ± SD.	81.90 ± 7.16	
Median (IQR)	80.0(76.0 – 88.0)	

**Table2. Relation between approaches and different parameters**

	Approaches				Test of Sig.	p
	Triceps reflection		Olecranon osteotomy			
	No.	%	No.	%		
<b>Gender</b>						
Male	7	63.6	6	60.0	$\chi^2 = 0.029$	<sup>FE</sup> p= 1.000
Female	4	36.4	4	40.0		
<b>Age (years)</b>						
Min. – Max.	17.0 – 47.0		17.0 – 50.0		U= 52.500	0.863
Mean ± SD.	25.27 ± 10.04		25.60 ± 9.92			
Median	19.0		23.50			
<b>Occupation</b>						
Sedentary work	9	81.8	7	70.0	$\chi^2 = 0.403$	<sup>FE</sup> p=0.635
Heavy manual workers	2	18.2	3	30.0		
<b>Etiology</b>						
Fall down stairs	4	36.4	2	20.0	$\chi^2 = 2.454$	<sup>MC</sup> p=0.572
Road traffic accident	4	36.4	2	20.0		
Motor bike accident	2	18.2	3	30.0		
Motor car accident	1	9.1	3	30.0		
<b>Associated diseases</b>						
None	8	72.7	7	70.0	$\chi^2 = 0.396$	<sup>MC</sup> p=1.000
DM	2	18.2	2	20.0		
HTN	1	9.1	1	10.0		
<b>Associate fractures</b>						
None	10	90.9	8	80.0	$\chi^2 = 2.736$	<sup>MC</sup> p=0.344
Fracture ipsilateral proximal ulna	0	0.0	2	20.0		
Metacarpal fractures	1	9.1	0	0.0		
<b>Dominant side</b>						
Right	5	45.5	7	70.0	$\chi^2 = 1.289$	<sup>FE</sup> p= 0.387
Left	6	54.5	3	30.0		
<b>Fracture pattern</b>						
Low T shape	4	36.4	4	40.0	$\chi^2 = 1.396$	<sup>MC</sup> p=1.000

	Approaches				Test of Sig.	p
	Triceps reflection		Olecranon osteotomy			
	No.	%	No.	%		
High T shape	4	36.4	3	30.0		
Y shape	3	27.3	2	20.0		
Comminuted	0	0.0	1	10.0		
<b>Time between the onset of the</b>					U= 41.500	0.349
Min. – Max.	24.0 – 48.0		24.0 – 48.0			
Mean ± SD.	29.45 ± 7.80		31.90 ± 7.92			
Median	24.0		33.0			

**Table3. Relation between approaches and outcome**

	Approaches				Test of Sig.	p
	Triceps		Olecranon			
	No.	%	No.	%		
<b>Fracture AO/type</b>					$\chi^2 = 3.552$	<sup>MC</sup> p=0.199
C1	4	36.4	2	20.0		
C2	7	63.6	5	50.0		
C3	0	0.0	3	30.0		
<b>Post-operative alignment</b>					$\chi^2 = 2.759$	<sup>FE</sup> p= 0.149
Neutral	10	90.9	6	60.0		
Suboptimal	1	9.1	4	40.0		
<b>Mayo Elbow Performance Score</b>					$\chi^2 = 0.855$	<sup>MC</sup> p=0.781
Fair	1	9.1	1	10.0		
Good	9	81.8	7	70.0		
Excellent	1	9.1	2	20.0		
Min. – Max.	70.0 – 93.0		69.0 – 92.0		t= 0.361	0.722
Mean ± SD.	82.45 ± 6.92		81.30 ± 7.75			
Median	83.0		80.0			
<b>ROM</b>					t= 0.541	0.595
Min. – Max.	100.0 – 122.0		100.0 – 122.0			
Mean ± SD.	113.45 ± 8.39		111.40 ± 9.0			
Median	112.0		111.0			
<b>Union</b>					$\chi^2 = 1.155$	<sup>FE</sup> p= 0.476
United	11	100.0	9	90.0		
Delayed union	0	0.0	1	10.0		
<b>Infection</b>					$\chi^2 = 1.155$	<sup>FE</sup> p= 0.476
No	11	100.0	9	90.0		
Yes	0	0.0	1	10.0		

## Discussion

The medical records and radiographs of 13 male and 8 female patients, all above the age of 18, were prospectively evaluated after a 6-month follow-up period. The

functional outcomes of intercondylar distal humerus fractures treated with ORIF via the triceps-reflection approach or olecranon osteotomy were assessed using flexion, extension, arc of flexion/extension, pronation, supination, arc of pronation/supination, and the Mayo Elbow Performance Score (MEPS). There were 6 cases of C1, 12 cases of C2, and 3 cases of C3 fractures, according to the AO foundation (AO) classification was observed. Twenty cases had joined at the time of evaluation, and only one case had developed delayed union. In the triceps-reflection group, 9 patients got good, 1 got excellent, and 1 got fair MEPS, whereas in the olecranon-osteotomy group, 7 patients got good, 1 got fair, and 2 got excellent MEPS. Gender, age, associated chronic diseases and fractures, and other factors also influence union and functional outcomes. In terms of numbers, the time between the onset of the trauma and admission was insignificant, but there were substantial differences in clinical follow-up. Some elderly patients' unions were delayed, causing them to take longer to return to work. Younger age groups, on the other hand, achieved good functional and union results in a short period of time. Diabetes mellitus (DM) was not shown to be substantially linked to union, although it did necessitate meticulous wound care. Long operational duration, inadequate alignment, and restricted ROM were all unfavorable prognostic factors for fracture type C3. In some patients, early good ROM was difficult because of suboptimal alignment, and need physiotherapy program.

Zhang and Zhong,<sup>(5)</sup> Performed a clinical study with both the triceps-reflection technique and olecranon osteotomy to expose type C distal humeral fractures for ORIF in elderly patients..

Although open reduction and internal fixation (ORIF) are common fracture treatments, experts disagree about the best manner to expose a fracture before ORIF. They examined the functional results of ORIF-treated type C distal humerus fractures in older persons using two exposure methods: the triceps-reflection technique and olecranon osteotomy. 75 senior patients with type C distal humerus fractures were treated with ORIF from January 2006 to January 2011, and their medical records, radiographs, and follow-up charts were evaluated retrospectively to identify any problems. At their last clinic appointment, patients' Mayo Elbow Performance Score (MEPS) and range of motion were determined. The last visit was attended by 67 patients (89 %). Thirty-six cases had olecranon osteotomy and 31 cases had triceps-

reflection surgery. They found that the triceps-reflection technique reduced operation durations, blood loss, complication rates, and MEPS outcomes in patients with type C1 and C2 fractures (all P 0.01) when compared to olecranon osteotomy. Except for MEPS outcomes, all of these approach-related improvements for type C3 fractures, which were statistically significant (all P 0.01).). In our series, they found no occurrences of fracture nonunion, implantation breakage or loosening, or elbow stiffness.

They discovered that type C1 and C2 distal humerus fractures revealed utilizing the triceps-reflection method rather than olecranon osteotomy had superior functional results. Even with the most complicated form of fracture, C3 fractures, both approaches resulted in equivalent improvements in elbow function. El Madag et al. (6) planned to analyze and compare the functional results of two approaches for the treatment of intra-articular distal humeral fractures: olecranon osteotomy and triceps-reflection. The results of that study demonstrate a series of 54 intra-articular distal humeral fractures treated with open reduction and internal fixation with anatomic plating. In the olecranon-osteotomy group, lateral plating was performed in 10 (45.5%) patients, while medial and lateral parallel plating was performed in 12 (54.5%) patients. In the triceps-reflection group, lateral plating was performed in 8 (25%) patients, and medial and lateral parallel plating was performed in 24 (75%) patients. The olecranon-osteotomy group had a mean follow-up of 38.3 months, whereas the triceps-reflection group had a mean follow-up of 41.4 months. The olecranon osteotomy group had substantially improved functional outcomes based on MAYO elbow score and extension-flexion motion arc values (p 0.05). The olecranon osteotomy method yielded superior functional outcomes than the triceps-reflection approach. Furthermore, intra-articular distal humerus fractures can be safely treated with olecranon osteotomy, which allows for greater vision and control of the elbow joint, as well as early postoperative rehabilitation. Chen et al. (7) studied triceps-reflection versus olecranon osteotomy for ORIF, and they have analyzed 67 cases of intercondylar fractures of the distal humerus. The main goal of their study was to compare the effects of the triceps-reflection approach and olecranon osteotomy on the functional outcomes of intercondylar distal humerus fractures treated with open reduction and internal fixation (ORIF) by reviewing 67 cases of intercondylar distal humerus fractures treated with either approach between 2001 and 2009. The medical

records and radiographs of 30 male and 37 female patients were retrospectively evaluated, with a mean age of 44.5 years (range, 16-77) and a mean follow-up duration of 34.3 months (range, 6-89). The functional outcomes of intercondylar distal humerus fractures treated with ORIF via the triceps-reflection approach or olecranon osteotomy were assessed using flexion, extension, arc of flexion/extension, pronation, supination, arc of pronation/supination, and the Mayo Elbow Performance Score (MEPS). There were 10 cases of C1, 28 cases of C2, and 29 cases of C3 fractures, according to the AO Foundation (AO) classification. All fractures had recovered at the time of the review. Although there was no overall statistically significant difference in the average flexion, extension, arc of flexion/extension, pronation, supination and arc of pronation/supination between the triceps-reflection group (n=34) and the olecranon osteotomy group (n=33), patients above 60 years of age had more extension loss (mean 22.9°, range 0 - 55°) after ORIF via the triceps-reflection approach, compared with any other surgical approach/age combination group. Although only 37.5 % of patients over the age of 60 received excellent/good MEPS in the triceps-reflection group, the rate improved to 100 % in patients under the age of 40 ( $P < 0.05$ ). In contrast, in all age groups of patients treated with ORIF by olecranon osteotomy, the incidence of excellent/good MEPS remained over 80%. Finally, ORIF using the triceps-reflection technique results in poor functional outcomes for intercondylar distal humerus fractures in cases over 60 years old, for whom the olecranon osteotomy technique may be a preferable option. However, for patients under the age of 60, particularly those under the age of 40, any treatment produces a satisfactory outcomes.

**Conclusion:**

It could be concluded that, in C3 type, the olecranon-osteotomy approach provides more control over the elbow joint and better visualization, whereas in the treatment of supracondylar intercondylar distal humerus fractures, both the triceps-reflection and olecranon-osteotomy techniques are safe.

**COMPETING INTERESTS DISCLAIMER:**

Authors have declared that no competing interests exist. The products used for this research are commonly and predominantly use products in our area of research and country. There is absolutely no conflict of interest between the authors and producers of the products because

we do not intend to use these products as an avenue for any litigation but for the advancement of knowledge. Also, the research was not funded by the producing company rather it was funded by personal efforts of the authors.

## References

1. **Bhayana H, Pandey R, Dhammi IK**, et al. Comparative study for assessment of functional outcome of intraarticular AO type C distal humerus fractures treated by parallel plating. *Indian J Orthop* 2019; 53:190–195.
2. **Yadav R, Nayak M, Maredupaka S**, et al. Combined olecranon osteotomy and the posterior minimal invasive plate osteosynthesis approach for a concomitant injury of the humeral shaft and a distal intraarticular humerus fracture. *Cureus* 2019; 11:e5966.
3. **Munde SL, Bhatti MJ, Siwach RC**, et al. . Double tension band osteosynthesis in inter-condylar humeral fractures. *J Clin Diagn Res* 2015; 9:RC08–RC11.
4. **Lu S, Zha YJ, Gong MQ**, et al. Olecranon osteotomy vs. triceps-sparing for open reduction and internal fixation in treatment of distal humerus intercondylar fracture: a systematic review and meta-analysis. *Chin Med J (Engl)*. 2021;134(4):390-397.
5. **Zhang C, Zhong B, Luo CF**. Study comparing approaches to expose type C fractures of the distal humerus for ORIF in elderly patients: six years clinical experience with both the triceps-reflection approach and olecranon osteotomy, 2014.
6. **Elmadag M, Erdil M, Bilsel K**, et al. The functional outcomes of two approaches: approach with olecranon osteotomy and triceps-reflection approach for the treatment of intra- articular distal humeral fractures, 2014.
7. **Chen G, Liao Q, Luo W**, et al. Triceps-reflection versus olecranon osteotomy for ORIF: analysis of 67 cases of intercondylar fractures of the distal humerus, 2011 Apr; 42(4)