

## Case report

# Foreign Body in the Anterior Chamber Presenting as Inflammatory Mass on the Iris

### ABSTRACT

A 40-year-old male factory worker presented to our eye clinic with left eye pain, redness and blurring of vision, with history of an injury sustained while hammering a nail into the wall two days ago. He was asymptomatic at the onset of the injury. Slit lamp examination of left eye showed a small, self-sealed laceration wound at the temporal limbus and a smooth, well defined, oval mass in the anterior chamber in the lower temporal quadrant. Rest of the anterior segment and fundus were normal. X-ray orbits showed no intraocular foreign body in the left eye. In view of clinical suspicion, we proceeded with a CT scan of orbits which showed the presence of a small metallic foreign body in the anterior chamber of left eye. After giving topical antibiotic, cycloplegic, corticosteroid eye drops and systemic antibiotics for three days, we planned surgical removal of the mass in the anterior chamber. After the mass was removed, we noted a small metallic foreign body embedded within the fibrin mass. The same treatment was continued postoperatively. The left eye became white and quiet, and vision improved to 6/6 with above treatment. The key learning point presented is that when the history is suggestive of intraocular foreign body, even though the X-ray orbits does not show the foreign body one has to get CT scan of orbits done to rule out its presence, especially when there is inflammatory mass in the anterior chamber as seen in our case.

**Keywords:** Metallic foreign body, anterior chamber, inflammatory mass, CT scan orbits.

### 1. INTRODUCTION

Ocular injuries predominantly affect the anterior segment of the eye. Among the intraocular foreign bodies (IOFB), they are uncommonly seen in the anterior chamber when compared to vitreous and retina. They can cause perforating or penetrating open globe injuries. IOFB injuries vary in presentation, outcome, and prognosis depending upon various factors. The visual prognosis depends on the location of injury, type and size of foreign body and the subsequent complications. Increased awareness about eye protection, improved surgical techniques, and advancements in bioengineering are responsible for an improved outcome in injuries with IOFB [1].

The foreign bodies in the eye are common amongst laborers who do not wear protective eyewear; 94% of patients presenting with IOFBs are male laborers aged between 30 and 40 years. The foreign bodies in the eye are common amongst laborers who do not wear protective eyewear; 94% of patients presenting with intraocular foreign bodies (IOFB) are male laborers aged between 30 and 40 years. An IOFB can be categorized as organic or inorganic (non-metallic and metallic). Most post traumatic IOFBs reside in the posterior segment (58%–88%), while the others are in the anterior chamber (10–15%) or the lens (2–8%). Metallic IOFBs, if left untreated, can result in direct mechanical damage and subsequent metallosis, such as ocular siderosis and chalcosis. However, the most serious complication is infectious endophthalmitis [2].

In a study of 64 perforating eye injuries with IOFBs treated over ten years were Lai [3] from Malaysia reported that population at risk were patients under 35 years (70%), males (95.3%) and work related (86%). Forty one (41) were seen in the posterior segment and 23 in the anterior segment. The most common cause of IOFB were hand hammer (64.1 %) followed by grass cutting (20.3%), machining (3.1%)

and others (12.5). Greven et al[4] in their study of 59 patients undergoing removal of IOFB in USA, reported that hammering accounts for the majority (60–80%) of IOFBs, followed by power equipment or machinery (18–25%) and weapon-related injuries (19%).

It is imperative to perform a gonioscopic examination in all suspected patients of intraocular foreign bodies, as they can be challenging to detect them [5]. All cases of IOFBs should be treated on emergency basis in view of potential danger endophthalmitis. Long-term retained or misdiagnosed IOFBs may occur when patients do not pay attention or do not have access to medical care, but most patients will suffer from partial vision impairment or endophthalmitis.

We report a case of a small metallic foreign body in the anterior chamber presenting as an oval yellowish mass in a factory worker following an injury to his left eye, highlighting the need to consider intra ocular foreign body despite atypical appearance.

## 2. CASE REPORT

A 40-year-old Bangladeshi factory worker presented with a two days history of a painful, watery left red eye, associated with blurring of vision. On further questioning, three days prior, he was hammering a nail and felt something entering into his left eye with speed. His symptoms initially were mild, improved after consulting a general practitioner who prescribed antibiotic eye drops. However, pain became severe with loss of vision the following day.

On examination Left eye: vision was 6/36, improving to 6/18 with pinhole. Slit-lamp examination revealed a self-sealed laceration wound (1.5 x 2 mm) at the temporal limbus with minimal surrounding corneal edema. A smooth, well defined, oval yellow mass (2.5 x 2.5 mm) was seen in the anterior chamber (4-5 o'clock position). It appeared to be on the surface of the iris, almost mimicking the appearance of an inflammatory mass (Fig. 1). There was aqueous flare and 3+ cells in the anterior chamber. Pupil was sluggish and mid-dilated with no relative afferent pupillary defect. The lens was clear. IOP was 14 mmHg. Dilated pupil fundus examination was normal. Siedel's test was negative. Gonioscopy of left eye did not reveal any foreign body in the angle of anterior chamber.

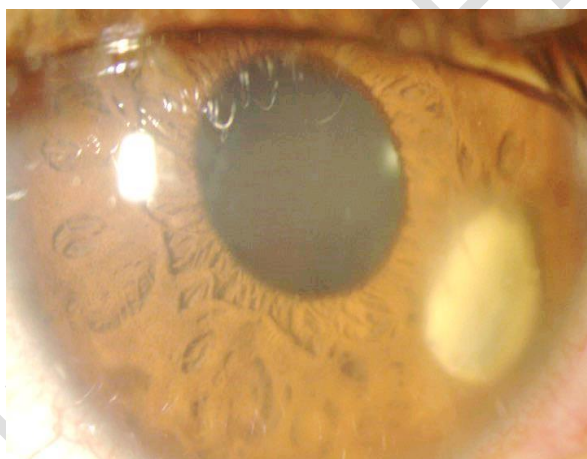


Fig.1 showing the smooth, well defined, yellowish mass on the surface of iris, in the anterior chamber of the left eye.

Examination of the right eye: vision, anterior segment, fundus and intraocular pressure were normal. As the history indicated the possibility of a foreign body entering the left eye, a skull x-ray and B-scan were performed. However, no intraocular foreign body was visualized on the x-ray. B scan revealed no vitritis.

The presence of flare and cells in the anterior chamber indicates inflammation in the eye. Therefore, the patient was started on Gutt. homatropine 2% three times, Guttpredforte 1% four hourly daily in the left eye, under the cover of Gutt. moxifloxacin 0.5% one hourly and Gutt. fortified ceftazidime 5% one hourly.

Intravenous Ciprofloxacin 400 mg two times daily was given in view of a yellowish mass in the anterior chamber over the iris.

This atypical appearance of a mass in the anterior chamber, in combination with no intraocular foreign body seen on X-ray, proved to be diagnostically challenging. A CT scan of orbits was subsequently performed, which showed a small hyper dense radio-opaque area in the left anterior chamber (Fig. 2) suggestive of foreign body. The globe appeared intact. A final diagnosis of a metallic foreign body in the left anterior chamber was made.

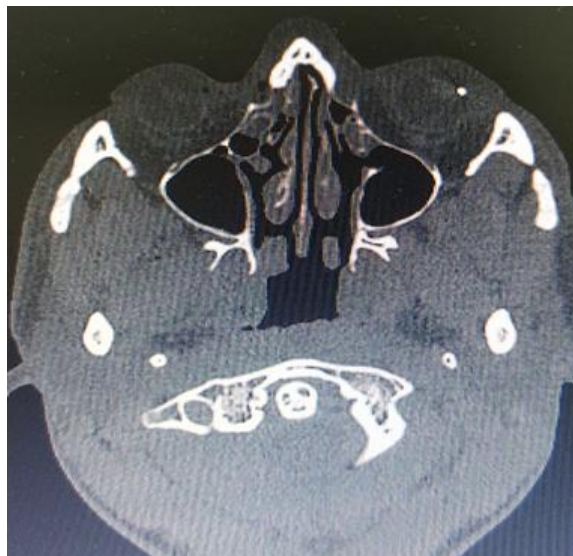

Fig. 2 Axial CT scan of orbits showing the hyper dense area (foreign body) in the anterior chamber of the left eye.

Three days after the treatment, surgical removal of the mass was planned. Under subtenon's xylocaine 2% anaesthesia, a corneal incision was made on the inner side of limbus from 3 - 4.30 clock position. Viscoelastic was injected into anterior chamber and the soft fibrin mass on the surface of iris was separated. It was removed using Kelman's forceps. The viscoelastic was washed and anterior chamber was formed with saline. The corneal wound was closed with 10-0 nylon suture. Sub conjunctival injection of gentamicin 20 mg and dexamethasone 2 mg was given before patching the left eye. On opening the yellow mass, a small metallic foreign body (2 x 1 mm) was detected wrapped within the fibrin material (Fig. 3).



Fig.3 showing the removed metallic foreign body from the anterior chamber of the left eye.

Post-operatively, Gutt. moxifloxacin and Gutt. fortified ceftazidime were reduced to two hourly; Gutt. homatropine, and Gutt. predforte were continued. Cap. ciprofloxacin was given orally 500 mg twice daily for another four days. Vision on day one post-operatively improved to 6/9, with 2+ cells in the anterior chamber. One week after admission, vision remained stable in the left eye, with 1+ cells in the anterior chamber. Patient did not have any pain in the eye. The patient was discharged on Gutt. moxifloxacin 4 hourly, Gutt. predforte 4 hourly, Gutt. homatropine once daily in the left eye.

In the follow up after one week, vision improved to 6/6 in the left eye. Slit lamp examination showed no flare and cells in the anterior chamber (Fig. 4). Guttmoxifloxacin and Guttpredforte were reduced to q.i.d in the left eye for one week followed by t.d.s. for one week. Gutt. fortifiedceftazidime and Gutt. homatropine were stopped. He was advised to come after two weeks for checkup.

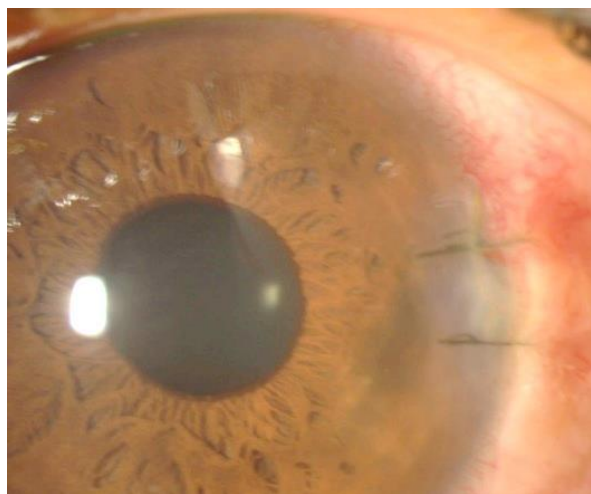


Fig. 4 showing post-operative appearance of the left eye one week after discharge from the hospital.

In the follow up examination, sutures at the limbus in the left eye were removed. Vision was maintained 6/6. Anterior segment, intraocular pressure and fundus were normal in the left eye. Guttmoxifloxacin and Guttpredforte were reduced to once daily in the left eye for another one week only. Patient was advised to come for follow up if there is any problem in the left eye.

### 3. DISCUSSION

The anterior chamber foreign body should be removed through a surgical incision depending on the location and size of the foreign body. Usually a shelved incision slightly bigger than the size of the foreign body is created either in clear cornea or sclera to facilitate its easy removal. A 20-gauge rare earth magnet may retrieve the object through the surgical incision if it is metallic and small. Nonmagnetic objects or large magnetic objects are best managed with intraocular forceps. Use of viscoelastic will protect the tissues in the anterior chamber. Care should be taken while removing the foreign bodies to avoid any injury to surrounding tissue [1].

In the spectrum of ocular trauma, intraocular foreign bodies represent a potentially vision-threatening entity. The extent of injury often depends on four factors: the size and composition of the foreign body; the force at which the foreign body enters the eye; the location of the entrance wound; and the final resting place of the foreign body [5]. A retained anterior chamber foreign body can cause severe corneal endothelium injury, corneal oedema, or even corneal decompensation because of long-term friction and can also stimulate pigmentation and uveitis [6].

Wen and Si [7] in their study of 165 patients of foreign bodies in the anterior chamber treated in 23 year in China, reported nonmetallic foreign bodies in 109 eyes, metallic foreign bodies (iron) in 55 eyes (33.3%) and unknown nature foreign bodies in 3 eyes. The foreign bodies were located on the surface of iris in 97 cases (58.8%) and at the anterior chamber angle in 40 cases. He suggested that in these patients, whenever combined procedures are required, it is better to remove the foreign bodies first and then perform the operation for complications.

A 31-year-old female with an asymptomatic metallic anterior chamber foreign body that was discovered 15 years after undiagnosed penetrating ocular trauma was reported by He and Lv [8]. Asymptomatic anterior chamber foreign body has caused corneal endothelial injury and ocular siderosis, and that is why the metal particle embedded in the iris root in the lower part was removed in their patient.

In our case, the metallic foreign particle on the surface of iris surrounded by fibrin may have resulted due to severe inflammation in the anterior chamber causing an accelerated deposition of fibrin within a few days, resulting in diagnostic challenge due to atypical appearance of a foreign body. It was considered as an inflammatory mass in view of its position over the surface of iris and it was yellow looking. In addition, the X-ray of orbits did not reveal the metallic foreign body in the left eye. An iris cyst was another differential, hypothesised to be the result of a metallic foreign body penetrating the iris, without retention of the foreign body, but the colour of the mass and anterior chamber reaction were not in favour of it. However, in view of the self-sealed corneal laceration, and the patient's history, a CT scan of the orbits was subsequently performed which showed a metallic foreign body in the left eye. This diagnostic difficulty was also reported by Watts et.al [9], wherein a detached iris cyst was mistakenly believed to be a foreign body on the iris.

As seen in this patient, the advantage of performing a CT scan is that it precisely helped to localize the site of the foreign body with its surrounding relationships [10]. However, as reported by Yeniad et al [11], even in the absence of intraocular foreign body noted on X-ray and CT scan, a diagnosis of intraocular foreign body should not be ruled out in the presence of ocular trauma with evidence of inflammation. In our patient, the presentation of the thick fibrin seen gave a strong suspicion that there was a presence of intraocular retained foreign body, which encouraged us to proceed with a CT scan orbits to confirm it.

The foreign body was removed with forceps rather than magnet as the presence of thick fibrin material would have rendered the magnet ineffective. A newer method using encapsulation by an intraocular lens injector as proposed by Ishii et al [12] might have also been ineffective due to the presence of thick fibrin.

#### **4. CONCLUSION**

This case highlights that the presenting clinical features of a foreign body in the anterior chamber can be varied and cannot be effectively ruled out until appropriate imaging is performed. In patients who present with a history suggestive of a penetrating trauma, a full workup and detailed imaging should always be considered even if the clinical features and initial X-ray imaging do not support an intraocular foreign body. These patients should be promptly diagnosed and appropriately managed for regaining of normal vision, as seen in our patient.

#### **5. CONSENT**

The patient was admitted in the eye ward. Informed consent was taken for investigations and operation, if required.

#### **6. ETHICAL APPROVAL**

It is not applicable. Written informed consent was obtained from the patient for the publication of the case report and accompanying photos.

#### **8. REFERENCES**

[1] Kamjoo S, Chhablani J. Intraocular Foreign Bodies (IOFB). Eye Wiki. [https://eyewiki.org/Intraocular\\_Foreign\\_Bodies\\_\(IOFB\)](https://eyewiki.org/Intraocular_Foreign_Bodies_(IOFB)). (accessed on October 16, 2021)

[2] Lai YK. Perforating eye injuries due to intra ocular foreign bodies. Med J Malaysia. 1992;47(3): 212-19.

- [3] Loporchio D, Mukkamala L, Gorukanti K, et al. Intraocular foreign bodies: a review. *SurvOphthalmol* 2016;61:582–96.
- [4] Greven CM, Engelbrecht NE, Slusher MM, et al. Intraocular foreign bodies: Management, prognostic factors, and visual outcomes. *Ophthalmology*. 2000;107(3): 608–12.
- [5] Graffi S, Tiosano B, Cnaan RB et.al. Foreign Body Embedded in Anterior Chamber Angle. Case reports in ophthalmol medicine. 2012. Article ID 631728. doi.10.1155/ 2012/631728.
- [6] Jastaneiah SS. Long-term corneal complication of retained anterior chamber angle foreign body. *Saudi J Ophthalmol* 2010;24:105–8.
- [7] Wen Z, Si M. The analysis of foreign bodies in the anterior chamber in 165 cases. *Yan KeXueBao*. 1990;6(3-4):108-10. (article in Chinese)
- [8] He N, Lv Z. A rare asymptomatic metallic intraocular foreign body retained in the anterior chamber for 15 years: A case report. *Medicine (Baltimore)*. 2021;100(25): e26470. doi:10.1097/MD.00000000000026470
- [9] Watts MT, Rennie IG. Detached iris cyst presenting as an intraocular foreign body. *J Royal Soc Medicine* 1991; 84: 172-173
- [10] Pokhraj P S, Jigar J P, Mehta C, Narottam A P. Intraocular metallic foreign body: role of computed tomography. *J ClinDiag Res*.2014;8(12):RD01-3. DOI: 10.7860/jcdr/2014/9949.5271.
- [11] Yeniad B, Beginoglu M, Ozgun C. Missed intraocular foreign body masquerading as intraocular inflammation: two cases. *International Ophthalmology* 2010; 30 (6); 713-716
- [12] Ishii K, Nakanishi M, Akimoto M. Removal of intracamerall metallic foreign body by encapsulation with an intraocular lens injector. *J Cataract Refractive Surg* 2015;41: 2605-2608.