

Duration dependent impact of aspartame and *Sacoglottis gabonensis* on the liver of swiss mice

Abstract

Aim: this study aimed at evaluating the duration dependent impact of aspartame and *Sacoglottis gabonensis* on the liver of swiss mice.

Location and Duration of study: The study was carried out in the green house of the Department of Animal and Environmental Biology, Rivers State University, Nkpolu-Oroworukwo, Port Harcourt, Nigeria (Coordinates 4°48'14"N 6°59'12"E). The experiment lasted for Ninety days.

Experimental design: A completely randomized experimental design employing relevant statistical tools for analysis and interpretation.

Methodology: Ninety mice were assigned to six groups (A-F) of fifteen mice each. Group A was the negative control and so they were not given any treatment, but pellet and clean tap water. Group B was the positive control and received 50mg/kg/bw/day of aspartame alone. Group C received 50mg/kg/bw/day of aspartame and 250mg/kg/bw/day of ethanolic extract of *Sacoglottis gabonensis* leaf. Group D received 50mg/kg/bw/day of aspartame and 250mg/kg/bw/day of ethanolic extract of *S. gabonensis* bark. Group E received 50mg/kg/bw/day of aspartame and 250mg/kg/bw/day of a combination of bark and leaf extract. Group F received 50mg/kg/bw/day of aspartame and 500mg/kg/bw/day of a combination of bark and leaf extract. All the groups were exposed to their treatment by oral gavage for 30, 60 and 90days. Feed was withdrawn from the animals 24hours before the termination of experiment. For Biochemical analysis, blood samples were collected by ocular puncture into sterile tubes and serum separated by centrifugation at 2500 g for 10 mins and stored for determination of some liver biomarkers using their respective kits. For histopathological analysis, 0.5g of Liver was fixed in 10% neutral formalin and sectioned with a digital microtome (AO Spencer, No. 820) at 5 µm thick. Histological sections mounted on slides were stained

with Haematoxylin and Eosin (H&E). Photomicrographs were generated at X40 magnification and interpreted.

Result: There was significant ($p < 0.05$) increase in Malondialdehyde (MDA), alanine aminotransferase (ALT), aspartate aminotransferase (AST) and alkaline phosphatase (ALP) in the group B administered aspartame only when compared with the groups co-administered extracts of leaf, bark and combination of *Sacoglottis gabonensis*. Also, a significant ($p < 0.05$) decrease in the concentrations of superoxide dismutase (SOD), glutathione (GSH) and catalase (CAT) was recorded in group B when compared to other groups across the experimental period. Histopathological analysis shows the liver epithelium of the negative control group being filled with healthy normal hepatocytes, while liver exposed to aspartame alone (positive control) showed degenerated hepatocytes, multiple necrotic and apoptotic cells. The liver epithelium exposed to aspartame and the extracts of *S. gabonensis* showed regenerating hepatocytes with many binucleated cells seen, few necrotic and apoptotic bodies also seen.

Conclusion

The extracts of *S. gabonensis* co-administered with aspartame in the other experimental groups ameliorated the effects of aspartame as seen in the increased concentrations of liver injury biomarkers in group administered aspartame alone and the increased number of hepatocytes captured in the liver epithelium of animals co-administered *S. gabonensis*. Conclusively, *Sacoglottis gabonensis* has a novel antioxidant potential especially its bark extract.

Keywords: antioxidant, aspartame, binucleated, biomarkers, hepatocytes

1.INTRODUCTION

The world's population is on the increase and ever-increasing number of people all over the world are constantly been afflicted with one form of neurodegenerative disease or the other. Contributory factors to physical and general health status of the ever-increasing world population can be attributed to lifestyle. In modern affluent societies, the diseases exacting the greatest mortality and morbidity are degenerative diseases. They can be attributed to environmental factors such as occupational hazard exposure, smoking, alcohol intake, diet as well as genetic pre-disposition of individuals play causal role [1].

Aspartame is an artificial (non-nutritive) sweetener used to replace sugar in food and drinks. Nutritive sweeteners are naturally occurring sweeteners such as sucrose and fructose. On the other hand, non-nutritive sweeteners are synthesized in the laboratory such as aspartame, stevia and sucralose. Non-nutritive sweeteners, also referred to as high intensity sweeteners, are typically used in small amounts to reduce the caloric intake while sustaining the desired taste in many food products [2]. The non-nutritive sweeteners, better known as artificial sweeteners, include substances from several different chemical classes that interact with taste receptors and typically exceed the sweetness of sucrose by a factor of 30 to 13,000 times [3].

All over the world, plants have been used as a source of medicine through ages and have continued to serve as the basis for many pharmaceutical products used today. They provide a valuable source of therapeutic compounds because of their enormous biosynthetic capacity. Natural plant products are been used in Nigeria in local medicine practice and formulations but very little of such substances have been subjected to scientific verification.

S. gabonensis stem bark extract has been in use in the rainforest belt of southern Nigeria (Cross River, Akwa Ibom, Rivers, Abia, Imo, Delta and Bayelsa State) among the peasant communities as an additive to palm wine. When used in palm wine as an additive, it reduces foaming, prolongs the shelf life [4] and tempers the sweet sugary taste by imparting a bitter taste making it more acceptable. It is also used as a spice for its heating effect in pregnant and nursing mothers among the Ngwa people of Abia State of Nigeria [5,6].

Sacoglottis gabonensis stem bark extract is a traditional palm wine additive commonly used in many communities of tropical rain forest belt of Nigeria [6].

Infusion of *Sacoglottis gabonensis* stem bark in palm-wine or gin prevents fever and eradicates body pain. In southern Nigeria, the stem bark is used to prolong the shelf life of palm wine, add potency, reduce foaming, impart a bitter taste and treat arthritis in old people. It is also believed to have aphrodisiac properties [7,8,9]. In Sierra Leone, the bark decoction is used to treat stomach-ache and as spices in food to induce lactation in nursing mothers [7,8,9]. There is a growing concern about the attributed effects of artificial sweetener such as aspartame, its long-time accumulation and the fate of the

general population since they are found in ready to use consumables and the potentials of *S. gabonensis* an indigenous plant as an available antioxidant

2. MATERIALS AND METHODS

2.1 Experimental Location

The study was carried out in the green house of the Department of Animal and Environmental Biology, Rivers State University, Nkpolu Oroworukwo, Port Harcourt, Nigeria (Coordinates 4°48'14"N 6°59'12"E).. The experiment was conducted from January to April, 2021.

2.2 Experimental Animal and Management

A total of Ninety (90) mice (mean weight $18.57 \pm 3.35g$) were used for the study. The mice were housed in rubber case under standard condition and acclimatized for two weeks. All animals were fed with standard rodent pellet and cool clean water ad libitum. All experiments were conducted according to the institutional animal care protocols at the Rivers State University, Nigeria and followed approved guidelines for the ethical treatment of the experimental animals.

2.3 Experimental Design and Procedure:

Ninety mice were assigned to six groups (A-F) of fifteen mice each. Group A was the negative control and so they were not given any treatment, but pellet and clean tap water. Group B was the positive control and received 50mg/kg/bw/day of aspartame. Group C receive 50mg/kg/bw/day of aspartame and 250mg/kg/bw/day of ethanolic extract of *Saboglottis gabonensis* leaf. Group D received 50mg/kg/bw/day of aspartame and 250mg/kg/bw/day of ethanolic extract of *S. gabonensis* bark. Group E received 50mg/kg/bw/day of aspartame and 250mg/kg/bw/day of a combination of bark and leaf extract. Group F received 50mg/kg/bw/day of aspartame and 500mg/kg/bw/day of a combination of bark and leaf extract. All the groups were exposed to their treatment by oral gavage for 30, 60 and 90days. Feed was withdrawn from the animals 24hours before the termination of experiment.

2.4 Blood Collection

At the end of each experimental period (30days, 60days and 90days), five mice per group were euthanized with chloroform and blood samples were collected by ocular puncture and placed in plain

sample bottles. Thereafter the samples were centrifuge at 3000g for 10minutes kinetic test kits produced by Cypress diagnostics. Alanine aminotransferase (ALT), Aspartate transferase (AST) activities were determined according to the method of Reitman and Frankel [10]. Alkaline phosphatase (ALP) tests were carried out using Belfield and Goldberg's method. [11], Catalase, Superoxide dismutase, Malondialdehyde and GSH were determined by the methods of Clairbobrne, Ohkawa and Ohishi and Ellman respectively [12,13,14].

2.5 Histopathological Analysis of the Liver

Immediately after dissection of each animal, 0.5g of liver was fixed in 10% neutral formalin and sectioned with a digital Rotatory Microtome (AO spencer No. 820) at 5µm. Histological sections mounted on slides was stained with haematoxylin and counter-stained with eosin (H&E). Photomicrographs were generated with a digital microscope Biosphere Miller B with an image processor DN2 – microscopy image processing software at x40 magnification.

2.6 Statistical analysis

Data management and statistical analyses were conducted using Statistical Analyses System SAS 9.4 (SAS Institute, Cary, North Carolina, USA). Graphical representations and data visualizations were carried out using the JMP statistical discovery™ software version 14.3.

3. RESULTS

3.1 Effect of aspartame and *S. gabonensis* on the endogenous biomarkers of swiss mice

The influence of treatment with aspartame and *Sacoglottis gabonensis* on monthly interaction on endogenous biomarkers in Swiss mice is presented in figure 1. There was a significant difference in GSH across the experimental period. The highest GSH value was recorded at 30 days in the group E, administered bark + leaf low dose, while the lowest peak is at 60 days for group B, the positive control. There was also a significant difference in SOD across experimental duration. The highest peak was at 90 days for positive control, while the lowest peak is at 30 days in group C administered the leaf extract. There is significant difference in CATA across experimental duration. The highest peak is at 30 days for positive control, while the lowest is at 90 days for combination of bark + leaf at 250mg/kg/bw (low dose).

There was a significant difference in MDA across experimental duration. The highest peak was at 60 days for positive control (group B), while the lowest as at 90 days for bark (group D).

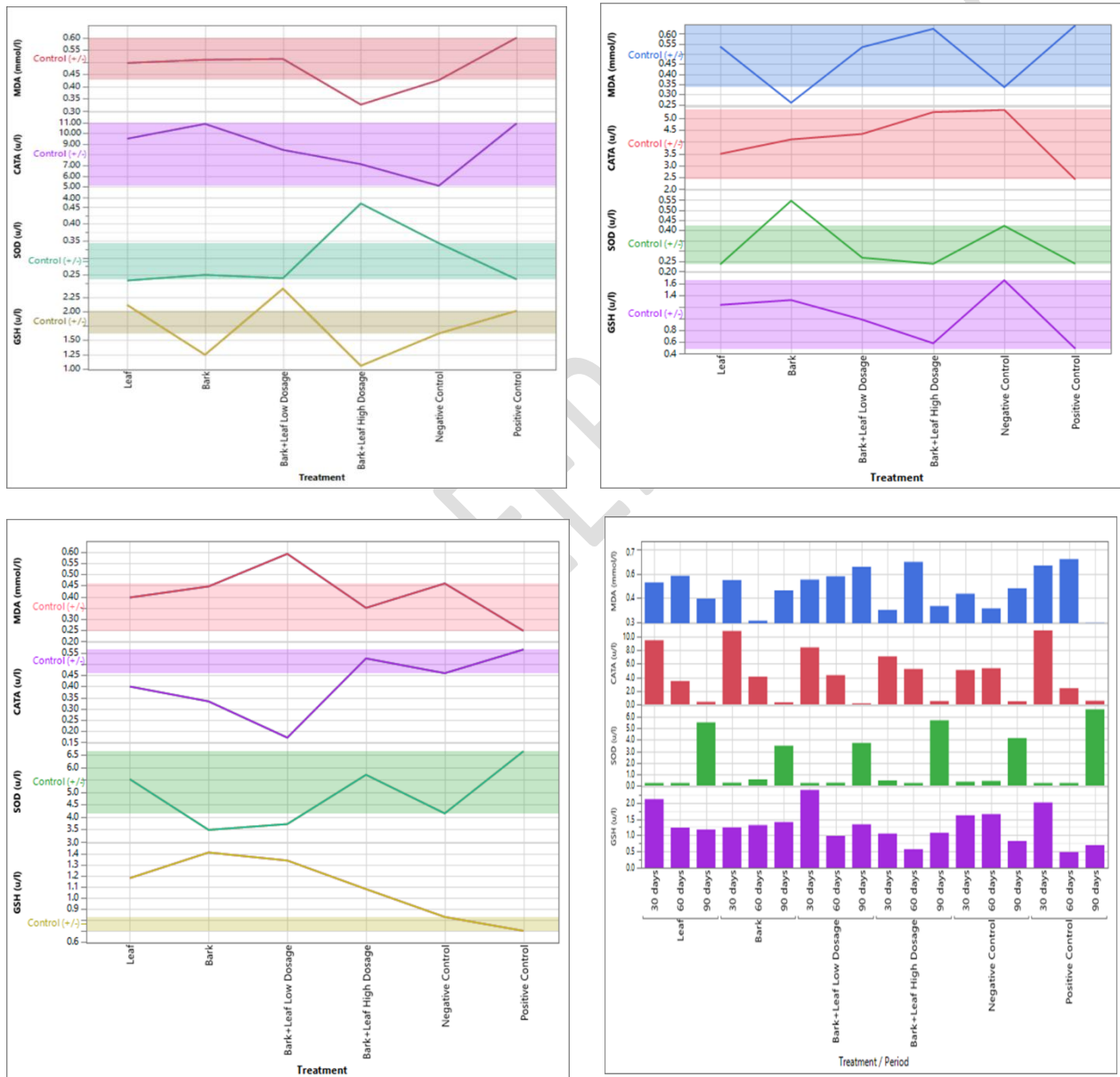


Fig 1: Effect of aspartame and *S.gabonensis* on endogenous biomarkers in swiss mice

a) Endogenous biomarkers in mice after treatment with aspartame and *S. gabonensis* for 30days

(b)Endogenous biomarkers in mice after treatment with aspartame and *S. gabonensis* for 60days

- (c) Endogenous biomarkers in mice after treatment with aspartame and *S. gabonensis* for 90days
(d) Comparison of Endogenous biomarkers in mice after treatment with aspartame and *S. gabonensis* for 30,60 and 90days

3.2 Effect of aspartame and *S. gabonensis* on the exogenous biomarkers in swiss mice

The results for the influence of treatment with aspartame and *Sacoglottis gabonensis* on monthly interaction on exogenous biomarkers in Swiss mice is presented in figure 2. There was a significant difference in AST across experimental duration. The highest peak was at 60 days for bark and positive control (group B) while the lowest peak was at 90 days for bark + leaf low dose and negative control. There was a significant difference in ALT across experimental duration. The highest peak was recorded at 60 days for positive control, while the lowest peak was seen at 90 days for group D administered (bark of *S. gabonensis*). There was significant difference in ALP across experimental duration. The highest peak was at 90 days for group B and C, while the lowest peak was at 30days for bark + leaf low dose. There was significant difference in GLU across experimental duration. The highest peak was at 60 days for positive control, while the lowest peak was at 60 days for bark + leaf high dose. There was significant difference for TC across experimental duration. The highest peak was at 90 days for leaf, while the lowest was at 60 days for bark +leaf high dose.

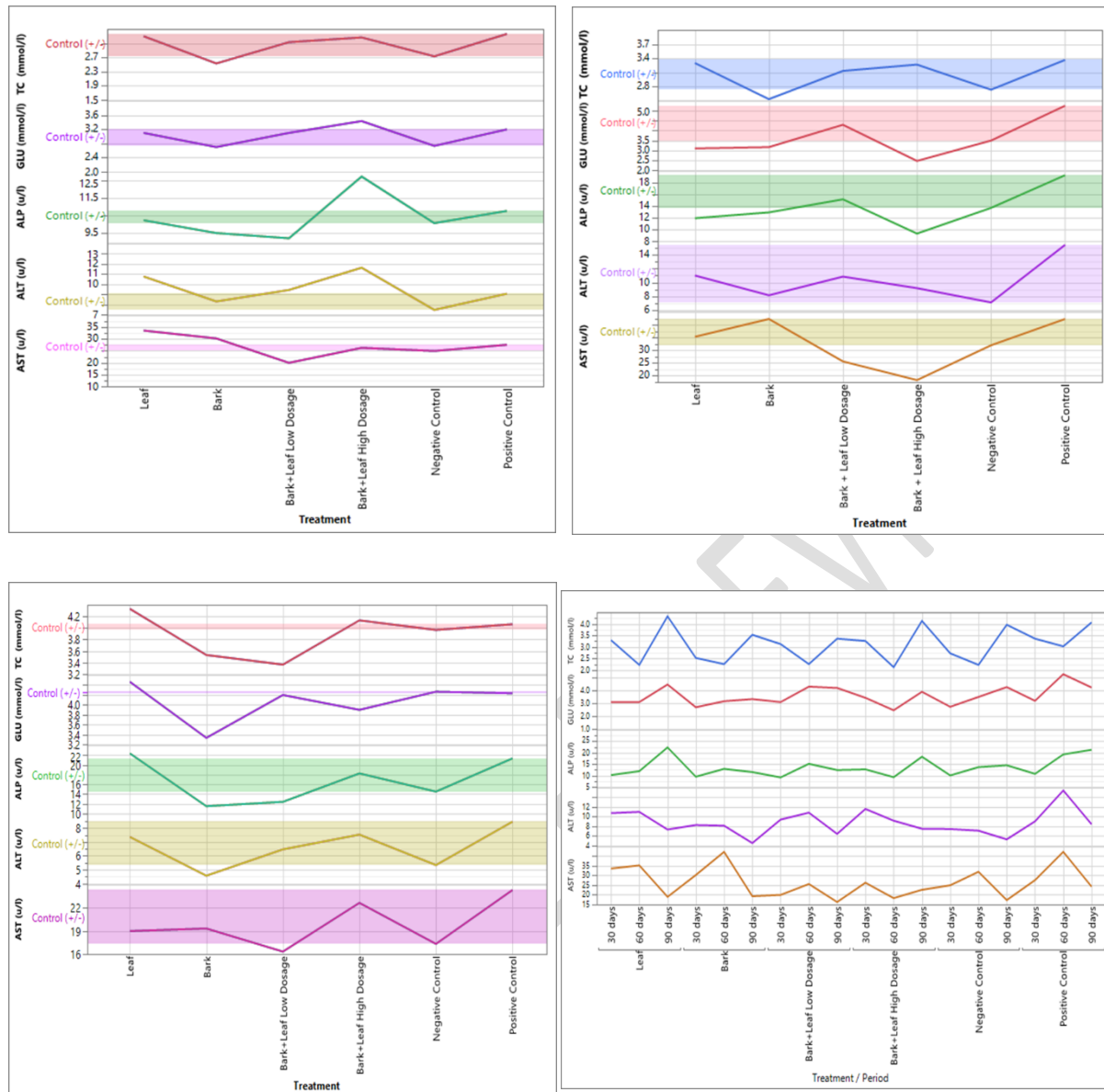
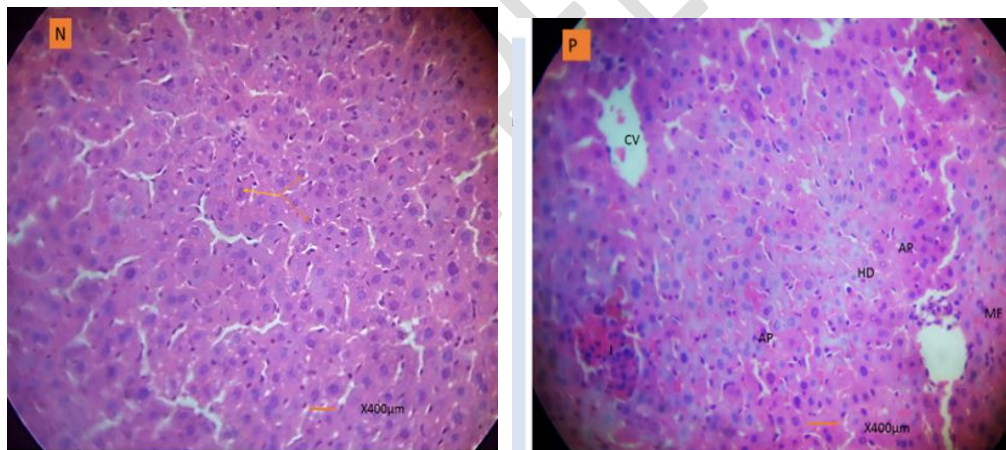


Fig 2: Effect of aspartame and *Sacoglottis gabonensis* on exogenous biomarkers of swiss mice

- Exogenous biomarkers in mice after treatment with aspartame and *S. gabonensis* for 30days
- Exogenous biomarkers in mice after treatment with aspartame and *S. gabonensis* for 60days
- Exogenous biomarkers in mice after treatment with aspartame and *S. gabonensis* for 90days
- Comparison of Exogenous biomarkers in mice after treatment with aspartame and *S. gabonensis* for 30,60 and 90days

3.3 Histological examination of liver sections of mice exposed to aspartame and *Sacoglottis gabonensis* for 30days

The result for histological examination of haematoxylin and eosin section of the liver of experimental mice exposed to aspartame and *Sacoglottis gabonensis* for 30days exposure period examined at X40 magnification is presented in fig 3. fig 3a which is the negative control group shows liver epithelium of Swiss mice normal architecture with healthy hepatocytes populates. fig 3b shows liver section of Swiss mice administered aspartame alone for 30 days. There were visible numerous spaces from the central vein, apoptotic cells, mitotic figures, necrotic cells and hepatocytes degeneration. fig 3c-e show mice liver exposed to aspartame and the extracts of *S. gabonensis*. There is visible hepatocytes regeneration as indicated by several mitotic figures in the group that received the leaf extract of *S. gabonensis*, also regeneration of hepatocytes is visible with mitotic figures, binucleated cells, mitotic telophase and few necrotic cells in the group that received the bark extract of *S. gabonensis*. Hepatocytes regeneration and necrotic cells is also seen in the group that received the combination of bark + leaf extract of *S. gabonensis*



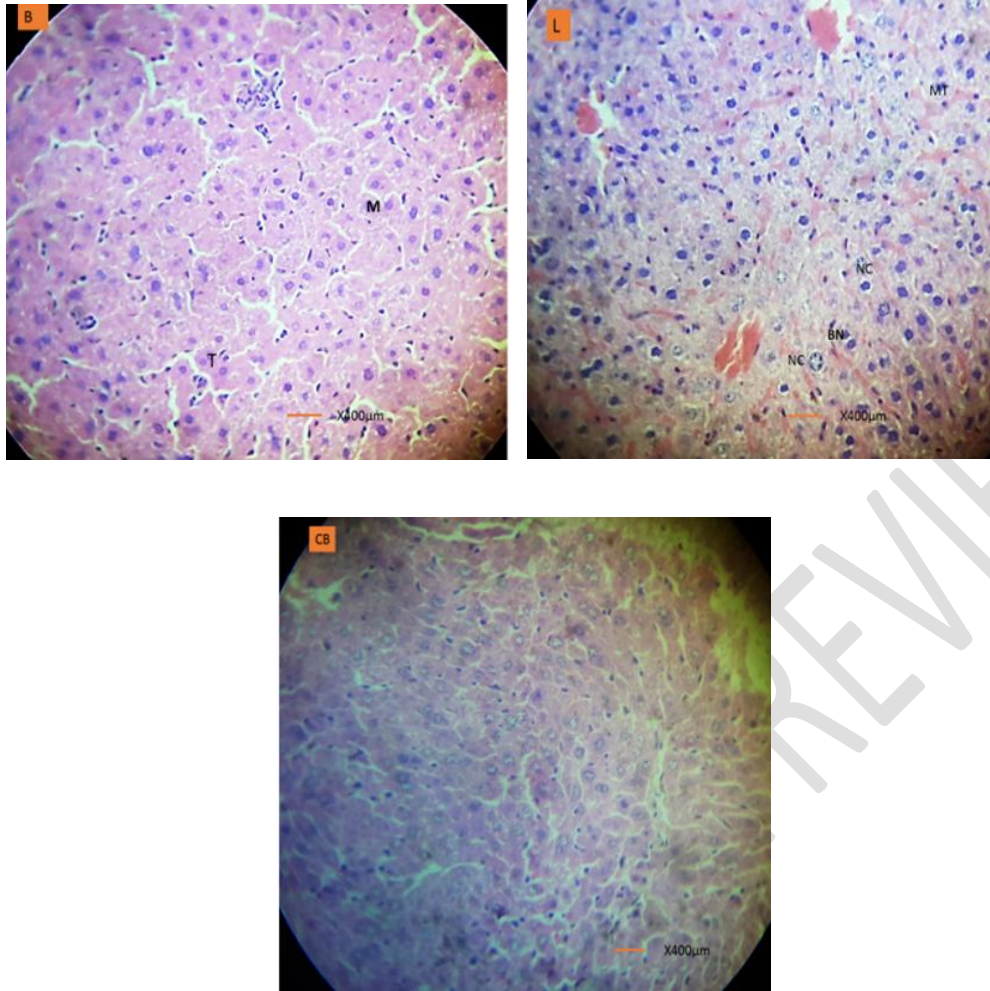


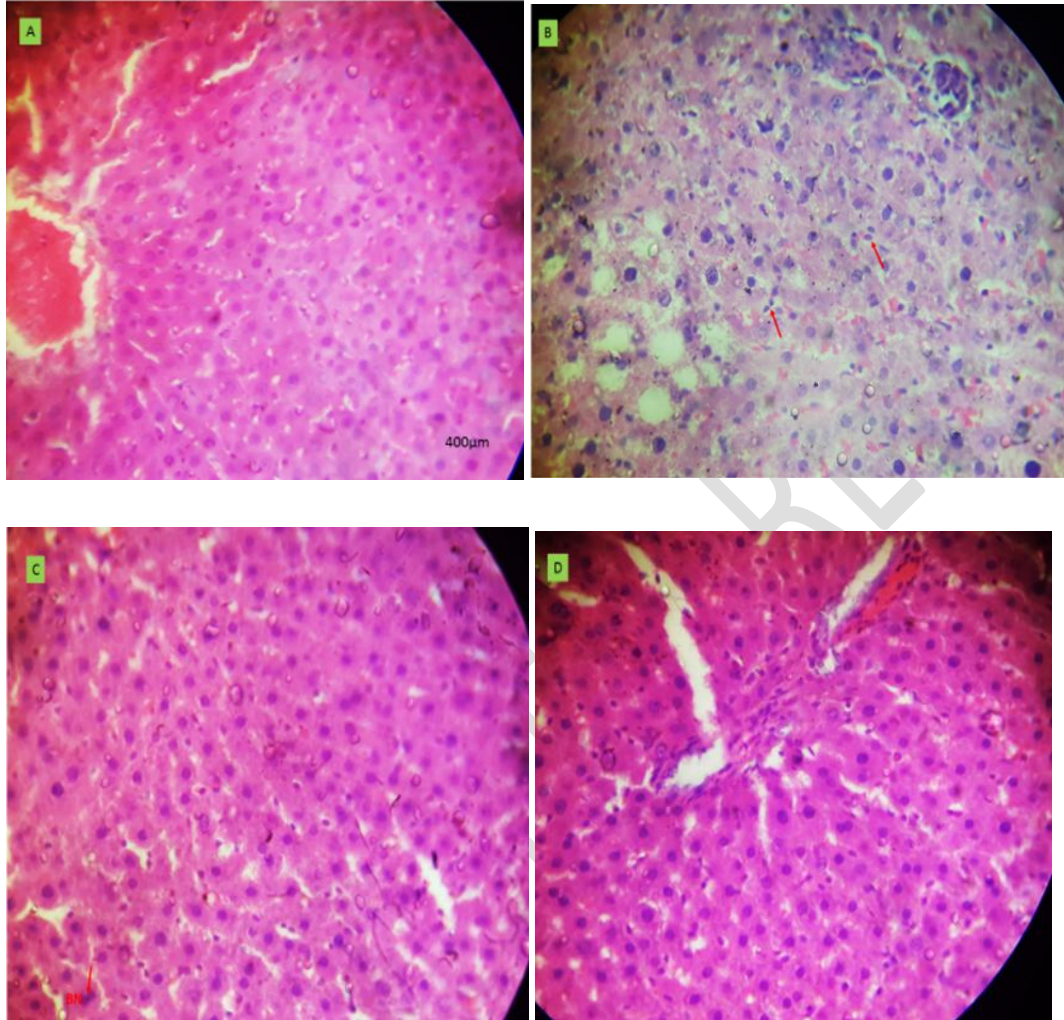
Fig.3: Micrograph sections of liver after 30days treatment

a Micrograph of mouse liver in negative control for 30 days (b) Micrograph of mouse liver exposed to aspartame for 30 days.(c) Micrograph of mouse liver exposed to aspartame and bark of *Sacoglottis gabonensis* for 30 days.(d) Micrograph of mouse liver exposed to aspartame and the leaf of *Sacoglottis gabonensis* for 30 days.(e) Micrograph of mouse liver exposed to aspartame and the combination of bark and leaf of *Sacoglottis gabonensis* for 30 days.

3.4 Histological examination of liver sections of mice exposed to aspartame and *Sacoglottis gabonensis* for 60days

The result for the histopathological examination of haematoxylin and eosin section of the liver of mice exposed to aspartame and *Sacoglottis gabonensis* for 60 days exposure period examined at X40 magnification is presented in fig 4. Fig 4a shows mouse liver for negative control. The entire epithelium of the liver is filled with normal hepatocytes. fig 4b shows mouse liver exposed to aspartame (positive control). Micrograph showed multiple necrotic, apoptotic and degenerated hepatocytes and vacuolated

epithelium. Fig 4c-e show mice liver exposed to aspartame and the extracts of *S. gabonensis*. The micrographs showed gradual regeneration of hepatocytes with few necrotic and apoptotic cells.



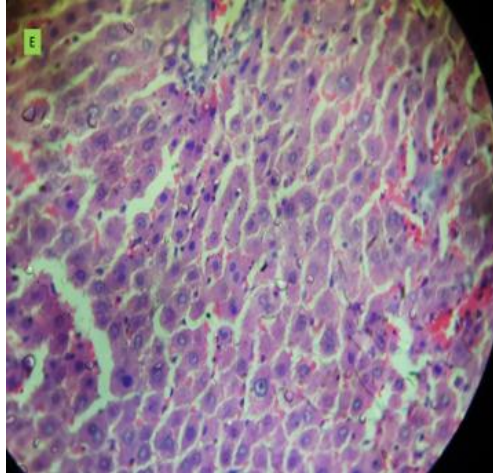


Fig 4: Histological examination of liver sections of mice exposed to aspartame and *Sacoglottis gabonensis* for 60days

(a)Micrograph of mouse liver in negative control for 60 days (b) Micrograph of mouse liver exposed to aspartame alone for 60 days (c) Micrograph of mouse liver exposed to aspartame and bark of *Sacoglottis gabonensis* for 60 days.(d) Micrograph of mouse liver exposed to aspartame and the leaf of *Sacoglottis gabonensis* for 60 days.(e) Micrograph of mouse liver exposed to aspartame and the combination of bark and leaf of *Sacoglottis gabonensis* for 60 days.

3.5: Histological examination of liver sections of mice exposed to aspartame and *Sacoglottis gabonensis* for 90days

The result for the histopathological examination of haematoxylin and eosin section of the liver of mice exposed to aspartame and *Sacoglottis gabonensis* 90 days exposure period examined at X40 magnification is presented in fig 5. fig 3.5a shows mouse liver for negative control. Liver epithelium is lled with healthy normal hepatocytes. fig 5b shows mouse liver exposed to aspartame alone (positive control). Liver epithelium showing degenerated hepatocytes, multiple necrotic and apoptotic cells. Fig 5c-e show mice liver exposed to aspartame and the extracts of *S. gabonensis*. Regenerating hepatocytes with many binucleated cells seen, few necrotic and apoptotic bodies also seen.

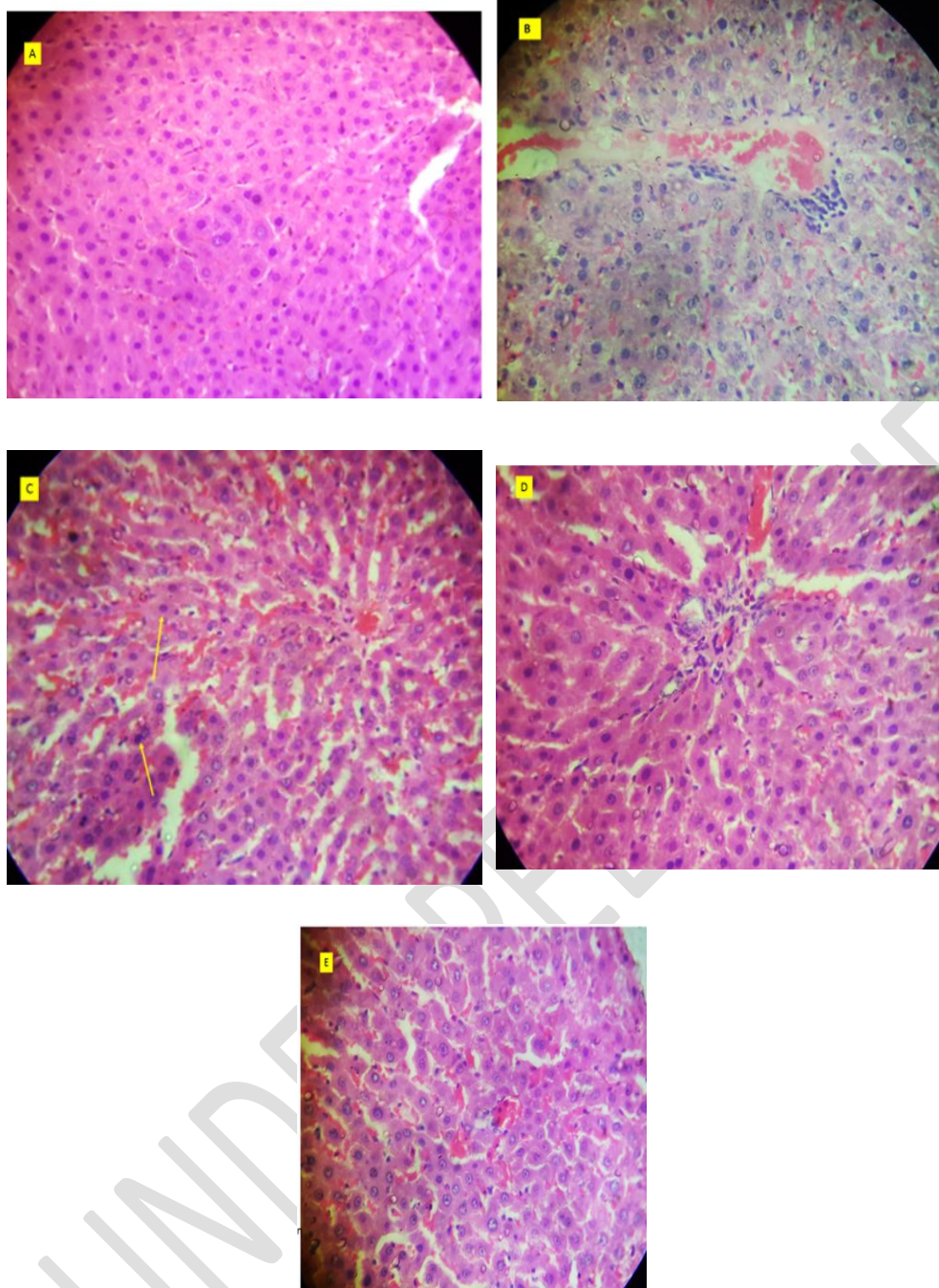


Fig 5. Histological examination of liver sections of mice exposed to aspartame and *Sacoglottis gabonensis* for 90days

Micrograph of mouse liver in negative control for 90 days (b) Micrograph of mouse liver exposed to aspartame for 90 days (c) Micrograph of mouse liver exposed to aspartame and bark of *Sacoglottis gabonensis* for 90 days.(d) Micrograph of mouse liver exposed to aspartame and the leaf of *Sacoglottis gabonensis* for 90 days.(e) Micrograph of mouse liver exposed to aspartame and the combination of bark and leaf of *Sacoglottis gabonensis* for 90 days.

4.0 Discussion

The liver is a critical organ that is responsible for an array of functions that help support metabolism, immunity, digestion, detoxification, vitamin storage among other functions. In this study, there was a significant increase in malondialdehyde (MDA) concentration in the positive control group (group B), bark + leaf high and low doses and the group that received the leaf extracts of *S. gabonensis*. [15] reported increase in nitric oxide and MDA in experimental animals that received aspartame. The negative control and the group that received the bark extract of *S. gabonensis* have decrease concentrations of MDA. Malondialdehyde is one of the final products of polyunsaturated fatty acids peroxidation in cells. The observed increase in MDA that is found in the positive control group, bark + leaf high and low doses, leaf groups suggest an increase in the production of free radical molecules which was also reported by [16,17]. Malondialdehyde level is a well-known biological marker of oxidative stress and the oxidant status in cancerous cells. The low concentration of MDA observed in the group that received the bark extract of *S. gabonensis*, implies that the bark extract of *S. gabonensis* is a potent scavenger of pro oxidant molecules in the experimental animals when compared with the other treatment groups.

There was a significant difference in *catalase* production from the different experimental groups. The positive control group have decreased blood *catalase* concentration when compared with the other experimental groups. The observed significant decreased concentration of *catalase* in the positive control group suggest an inhibition or low production of *catalase* due to the administration of aspartame. Catalase protects the cells from oxidative damage induced by reacting oxygen species (ROS). The increase in *catalase* production from the other experimental groups further validates the potentials of *S. gabonensis* as a potent antioxidant against oxidative stress molecules.

There was a significant decrease in SOD in the positive control group, group that received bark + leaf extracts of *S. gabonensis* high and low doses and the group that received the leaf extract of *S. gabonensis*. However, [18] reported significant increase in SOD, CAT, GPX, LPO in experimental animals treated with aspartame.

The positive control group and the bark + leaf high dose have decreased GSH concentrations. This result is in line with the results of [18,19] who reported decrease in GSH in experimental animals that received aspartame. Glutathione is an important antioxidant molecule that is responsible for combating free radicals when produced in the body. The high GSH concentrations in the negative control, leaf, bark and

bark + leaf low dose groups implies that the experimental animals from these groups experienced protection from pro oxidant molecules, while the positive control and the bark + leaf high dose group may likely experience low antioxidant impact because some of the key antioxidant molecules are in low concentration throughout this exposure period.

The extracts of *S. gabonensis* especially the group D that received the bark showed significant decrease total cholesterol content. The body needs some cholesterol to make cell membrane, hormones, and vitamin D and digestive fluids. When cholesterol is in excess as it is observed in the positive control group, it builds up in the walls of the arteries, stiffening and narrowing of the arteries, restricting the blood flow to the heart, brain and the rest of the body. The bark extract of *S. gabonensis* have shown great efficacy in the reduction of the concentration of total cholesterol concentration despite it been co-administered with aspartame that triggered the high concentration of total cholesterol when administered alone in experimental mice.

Glucose serves as a biological fuel for the body therefore, the significant increase in blood glucose concentration in the positive control group compared to the other treatment groups might be the cause of the restlessness observed in group B animals during the experimental period. [16,20] reported neurobehavioral health outcomes due to the consumption of aspartame by experimental animals.

The significant increase of ALP, ALT, AST in the positive control group further validates liver injury, inflammation or disease state induced due to the consumption of aspartame. The increase in the number of hepatocytes captured in liver epithelium of animals co-administered *S. gabonensis* showed the remarkable capacity of the liver to regenerate following injuries by undergoing rapid mitotic division as observed in group that received aspartame.

Conclusion

However, the extracts of *S. gabonensis* co-administered with aspartame in the other experimental groups ameliorated the effects of aspartame as it is indicated in the decreased concentrations recorded in those group and the negative control group indicating *Sacoglottis gabonensis* potential as an antioxidant due to their free radical scavenging potential although the efficacy seems highest in group D coadministered extract of bark of *S. gabonensis*

REFERENCES

1. Walsh R. (2011). Lifestyle and Mental Health. *American Psychological Association*. 66, (7) 579–592.
2. Marinovich, M. Galli, C. L. Bosetti, C. Gallus, S. La Vecchia, C. (2013). Aspartame, low-calorie sweetener and disease: Regulatory safety and epidemiological issues. *Food and Chemical Toxicology* 60, 109–115.
3. Whitehouse, C. R., Boullata, J. & McCauley, L. A. (2008). The Potential Toxicity of Artificial Sweeteners. *Continuing education*. 56 (6) 251-261.
4. Ezereonye, O.U., Elijah, A.I., & Ojmelikwe, P.C. (2005). Effect of *Sacoglottis gabonensis* and *Alstonia boonei* on the fermentation of fresh palm wine sap by *Saccharomyces cerevisiae*. *Journal of Food Technology*; 3(40), 586-591.
5. Okoye, Z. S. C. & Neal, G. E. (1988). Enhanced Ethanol-Induced Changes In Disposition and Toxic Response To Dietary Aflatoxin B1 Due To *Sacoglottis Gabonensis* Bark Extract, A Nigerian Alcoholic Beverage Additive. *Food and Chemical Toxicology*. 26, (8), 679-689.
6. Maduka, H.C.C. & Okoye, Z.S.C. (2002). The effect of *Sacoglottis gabonensis* stem bark extract, a Nigerian alcoholic beverage additive, on the natural antioxidant defences during 2,4-dinitrophenyl hydrazine-induced membrane peroxidation in vivo. *Vascular Pharmacology*. 39, 21– 31.
7. Morah, F. N. I. & Robinson, I. G. (2015). *Sacoglottis gabonensis* as a Potential Preservative for Palm-Wine. *American Scientific Research Journal for Engineering, Technology, and Sciences*. (ASRJETS) 13, (1), 97-101.
8. Dounias, E. (2015). *Sacoglottis gabonensis* (Baill.) Urb. Protabase Record display www.prota.org.
9. Brigitte, K. K. Euserbe, A. A. Mama, K. Duni, S. & Paul, Y. A. (2018). Influence of an aqueous extract of *Sacoglottis gabonensis* (Baille) urban (Humiriaceae) stem bark, a plant used in the traditional treatment of Buruli ulcer, on anthropometric and hematological parameters in Wistar rat. *The Pharma Innovation Journal*. 7, (3), 104-110.
10. Reitman, S. Frankel, S. (1957). A Colorimetric Method for the Determination of Serum Glutamic Oxalacetic and Glutamic Pyruvic *Transaminases*. *American Journal of Clinical Pathology*. 28, (1), 56-63.
11. Belfield, A & Goldberg, D. (1971). Colorimetric determination of alkaline phosphatase activity enzyme. 12, 561-566.
12. Clairborne, A. (1985). Catalase activity. In: Greenwald, R. A. ED. *CRC Handbook of Methods for Oxygen Radical Research*, CRC Press, Boca Raton, 283-284
13. Ohkawa, H. Ohishi, N. & Yagi, K. (1979). Assay for lipid peroxides in animal tissues by thiobarbituric acid reaction. *Annals of Biochemistry*. 2, (95), 351-358.
14. Ellman, G.L (1959). Tissue sulfhydryl groups. *Arch. Biochem. Biophys*; 82: 70-77.
15. Anbara, H. Sheibani, M. T. & Razi, M. (2020). Long-term effect of aspartame on male reproductive system: evidence for testicular histomorphometrics, Hsp70-2 protein expression and biochemical status. *International Journal of Fertility and Sterility*. 14, (2): 91-101. doi: 10.22074/ijfs.2020.6065

16. Choudhary A. K. & Lee, Y. Y. (2017). Neurophysiological symptoms and aspartame: What is the connection? *Nutritional Neuroscience*, DOI: 10.1080/1028415X.2017.1288340.
17. Choudhary, A. K. & Lee, Y. Y. (2018). The debate over neurotransmitter interaction in aspartame usage. *Journal of Clinical Neuroscience* (2018), <https://doi.org/10.1016/j.jocn.2018.06.043>.
18. Ashok, I. & Sheeladevi, R. (2015). Oxidant stress evoked damage in rat hepatocyte leading to triggered nitric oxide synthase (NOS) levels on long term consumption of aspartame. *Journal of Food and Drug Analysis*. 23, 679-691
19. Abdelmonem G. Madboly, M. D. Eslam, S. Metwally, M. D. Ghada, A. & Abd El-Fattah, M. D. (2019). Nephrotoxicity of Two Food Additives (Aspartame and Monosodium Glutamate) in Adult Albino Rats: Biochemical and Histopathological Effects. *Journal of Environmental Science, Toxicology and Food Technology (IOSR-JESTFT)* 13, (4) 1, 20-29.
20. Humphries, P. Pretorius, E. & Naude, H. (2008). Direct and indirect cellular effects of aspartame on the brain. *European Journal of Clinical Nutrition*. 62, 451-462.