

Case report

CLINICOPATHOLOGICAL SPECTRUM OF GLANDULAR ODONTOGENIC CYST - REPORT OF THREE CASES

ABSTRACT:

Glandular odontogenic cyst (GOC) is rare locally aggressive lesion of jaw constituting 0.012% to 1.3% of all odontogenic cysts. It commonly occurs in mandible (70%) than maxilla (30%). It arises from rest of dental lamina. Cysts radiologically appear as unilocular or multilocular radiolucency with a well-defined corticated border which mimics dentigerous cyst and lateral periodontal cyst. Histopathologically intraepithelial microcysts, presence of hobnail cells, epithelial lining is of variable thickness with sometimes apocrine snouting are observed. Clinical and radiographic features are nonspecific, and to its similarities with other lesions, it can be misdiagnosed. Treatment modalities of GOC are curettage, enucleation or marsupialization depending on aggressiveness of lesion.

Reporting three cases of GOC, two cases in mandible and a case in maxilla. Diagnosis was confirmed by histopathology and immunohistochemistry (IHC) which were strongly positive for CK19 and negative for CK 18.

KEY WORDS:

Glandular odontogenic cyst, IHC, central mucoepidermoid carcinoma odontogenic cyst.

INTRODUCTION :

GOC is rare odontogenic cyst first reported by Padayachee and van Wykassialo in 1987. Due to presence of glandular tissue, they termed it as “Sialo odontogenic cyst.”¹ In 1988 Gardner et al termed it as glandular odontogenic cyst. In 1992 WHO categorized this entity under developmental odontogenic cyst.² High et al (1996) termed it as ‘polymorphous odontogenic cyst.’³ Incidence rate of GOC ranges from 0.012% to 1.3% of all the jaw cysts and its prevalence is 0.17%.⁴

Radiological finding revealed unilocular or multilocular radiolucencies with sclerotic borders which is non-specific and may mimic other cysts. Final diagnosis was confirmed on the histopathology.⁵

Though GOC is rare, correct diagnosis has clinical importance due to its aggressiveness and high recurrence. Curettage and enucleation is the treatment for GOC but due to high recurrence marginal resection is preferred.¹ Aim of this report is to emphasize on clinical, radiologic features and Histopathological criteria for GOC with IHC characteristics.

CASE PRESENTATIONS:

TABLE -1 – CASES :

Sr no.	Entity	Case- 1	Case-2	Case-3
1	Clinical features (fig-a and b)	51 yrs /Male Site - Posterior	14 yrs / Female Site - Posterior	21yrs Female E/O - diffuse swelling

		<p>mandible</p> <p>E/O – bony hard swelling over left mandibular ramus</p> <p>I/O - firm swelling extending from distal of 37 to ramus of mandible</p>	<p>mandible</p> <p>E/O - swelling over left body of mandible</p> <p>I/O - swelling extending from 34 to mesial of 36 with obliteration of buccal vestibule</p>	<p>on right zygomatic region.</p> <p>I/O - labial swelling extending from distal of 11 to mesial of 13 and swelling in right anterior palatal region.</p>
2	Radiological findings(fig-c)	<p>multilocular radiolucencies with well corticated borders extended from distal of 37 to mid ramus area.</p>	<p>unilocular radiolucency with well corticated borders in inter radicular area with 35 and 36</p>	<p>well defined radiolucency extending from 16 to 23 involving maxillary sinus with displacement of teeth</p>
3	Histopathological findings(fig-d)	<p>Fulfilled all the major and two minor Kaplan</p>	<p>Fulfilled all the major and two</p>	<p>Fulfilled all the major and two</p>

		criteria	minor Kaplan creteria	minor Kaplan criteria
4	IHC markers			
	CK19	Positive	Positive	Positive
	CK18	Negative	Negative	Negative

DISCUSSION:

GOC is considered to be a rare cyst, till date less than 300 cases have been discribed.³ It mainly affects fifth and sixth decades of life.⁶ In the present series affected age group is second to sixth decade. In the literature most of the GOCs have slight male predilection (57 : 43)⁷. In our series we found two females and one male was affected. It has predominance for anterior mandible than maxilla. If seen in maxilla it is evident in anterior maxilla.⁸ Reported cases were two in posterior mandible and one in anterior maxilla.

The common clinical feature of GOC is an asymptomatic swelling,⁹ In the series, extraoaraal and intraoral asymptomatic swelling were observed with displacement of teeth in one case.

Radiographically GOC may appear as a unilocular or multilocular radiolucent lesion with well-defined borders, root resorption and displacement of the teeth.¹ in our cases similar findings were observed with radio opacity in one case.

Clinical and histopathological finding of GOC overlap with other cysts or tumors, like dentigerous cysts and radicular cysts, botryoid cysts, lateral periodontal cysts, and mucoepidermoid carcinoma. This may have negative impact on treatment and patient prognosis.⁶ To overcome this Kaplan et al (2005) has suggested histopathologically five major and four minor criteria and concluded that all the major criteria should be fulfilled for diagnosis and the minor ones may aid in the same.³ they are as follows

TABLE - 2 - Kaplan et al criteria (2005)

Major criteria	Minor criteria
<ul style="list-style-type: none"> squamous epithelium lining lacking basal cell palisading 	<ul style="list-style-type: none"> papillary proliferation of the lining epithelium
<ul style="list-style-type: none"> focal luminal proliferation 	<ul style="list-style-type: none"> ciliated cells
<ul style="list-style-type: none"> hob nail cells 	<ul style="list-style-type: none"> multiluminal/multicystic architecture
<ul style="list-style-type: none"> goblet cells with or without crypts lined by mucous producing cells 	<ul style="list-style-type: none"> clear / vacuolated cells in basal or spinous layers
<ul style="list-style-type: none"> intraepithelial microcysts 	

But Fowler et al. did not segregate the major and minor criteria for GOC but proposed ten distinguishing features, out of which seven features should be fulfilled for the diagnosis of GOC.³ They are as follows

Surface eosinophilic cuboidal cells, also called “hobnail cells”

Intraepithelial microcysts or duct-like spaces

Apocrine snouting of hobnail cells

Clear or vacuolated cells

Variable thickness of the cyst lining

Papillary projections or “tufting” into the cyst lumen

Mucous goblet cells

Epithelial spheres or plaque-like thickenings

Cilia on the surface of eosinophilic cuboidal cells

Multiple compartments

In the case series all five major and two minor Histopathological Kaplan criteria and eight distinguishing features proposed by Fowler et al were fulfilled. Special stains like mucicarmine and periodic acid-schif (PAS) can be used for presence of mucin and mucous cells⁹, we used PAS stain and mucicaramine for confirmation.

Histopathologically GOC should be differentiated from dentigerous cyst, lateral periodontal cyst (LPC) and I mucoepidermoid carcinoma.¹

Presence of intraepithelial duct like spaces lined with mucous cells, ciliated cells, glandular or pseudoglandular structures, microcysts or mucous pools in the epithelium differentiate GOC from LPC.¹⁰

Presence of microcysts, focal luminal epithelial proliferation and clear cells differentiate GOC from dentigerous cyst.¹¹

Cuboidal cells, epithelial whorls, and intraepithelial and microcysts are not typical for central MEC which differentiate GOC from MEC. Immunohistochemical marker CK18 studies differentiate GOC from MEC.¹ The presence of MAML2 (mastermind-like 2) gene in low-grade central MEC may helpful to differentiate GOC from MEC.⁶

By immunohistochemical studies ,Odontogenic nature of GOC can be confirmed by cytokeratin - 7, 13, 14 and 19.¹² In the series, all the cases were strongly positive for CK 19. GOC can be differentiated from Low grade Mucoepidermoid Carcinoma by Negative expression of CK 8 & 18.¹³ In the case series all the cases were negative for CK 18.

To assess the proliferate nature of the GOC IHC staining can be done using Ki-67, p53.¹⁴

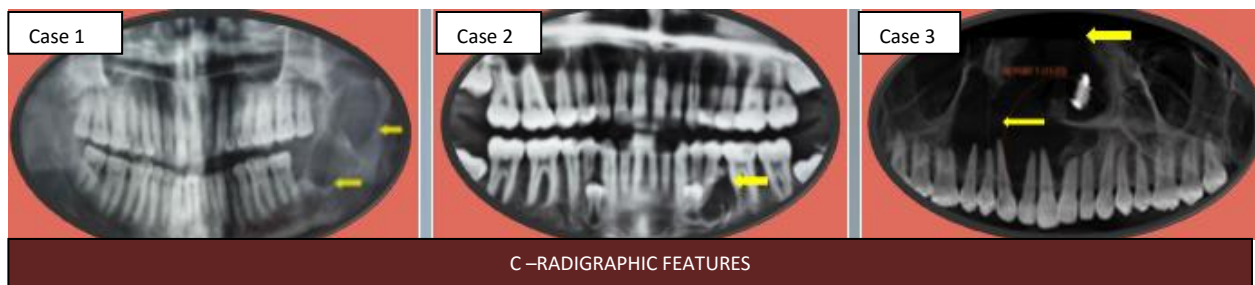
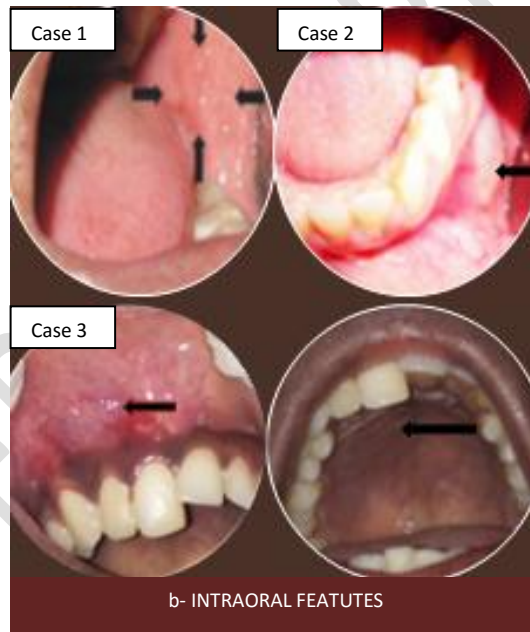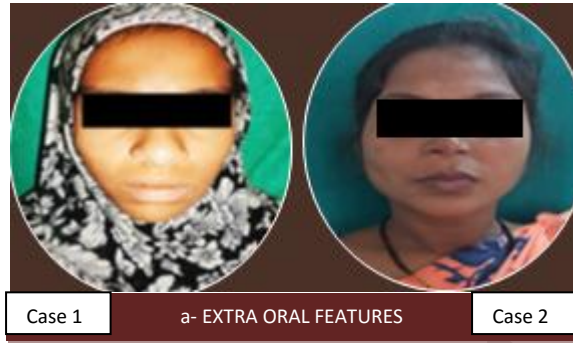
Treatment of GOC includes curettage with and without peripheral ostectomy ,enucleation or marsupialization.⁵ GOC recurrence is particularly associated with conservative surgical procedures, so adjunctive therapies like peripheral ostectomy, cryotherapy, or the application of Carnoy's solution are involved.⁶ Treatment of choice for one case was enblock resection due to ramus involvement and two cases were treated with enucleation.

GOC has high recurrence rate (21 % to 55%,) this attribute to the aggressive nature of cyst.³ Three to seven years follow up is advisable .² In our cases 2 years follow up was done, recurrence was not evident.

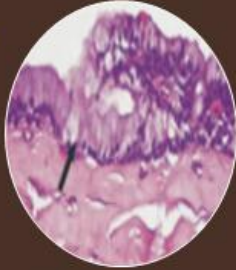
CONCLUSION:

GOC is a diagnostic challenge to oral pathologist due to clinical and histopathological overlapping,

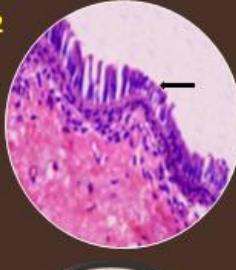
So a careful clinical, radiological and histopathological evaluation must be carried out with IHC to ensure correct diagnosis and treatment.



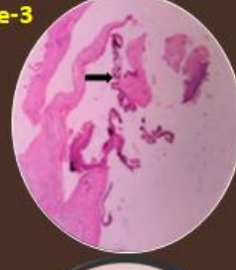
Case-1



Case 2



Case-3



NON KERATINIZED STRATIFIED SQUAMOUS EPITHELIUM OF VARYING THICKNESS, GOBLET, HOB NAIL CELLS AND CILIATED CELLS, INTRAEPITHELIAL CRYPTS, LUMINAL PROLIFERATION, INTRAEPITHELIAL MICROCYST,

d

REFERENCES :

1. Patil AA, Barpande SR, Bhavthankar JD, Mandale MS. Glandular Odontogenic Cyst Presenting as an Aggressive Multifocal Lesion: Case Report and Review of Literature. International Journal of Oral & Maxillofacial Pathology. 2014 Apr 1;5(2).
2. Rathod DB, Bhavthankar JD, Barpande SR. Glandular Odontogenic Cyst with an Odontome: An Unusual Association. JMSCR Volume||2||Issue||7||Page 1693-1705||July 2014
3. Singh J, Singh S, Singh D, Chandra S, Fatima T, Kour M, Gupta N. Glandular Odontogenic- The Multifaceted Cyst of the Jaw: An Unusual Case Report. Archives of Clinical and Medical Case Reports. 2020;4(4):682-9.
4. Venkateshwar G, Tamgadge S, Tamgadge A, Pereira T. Glandular odontogenic cyst: a case report in an asymptomatic patient. Journal of Experimental Therapeutics and Oncology. 2019 Dec 1;13:169-71.
5. Asha V, Baruah N, Jamadar S. Glandular odontogenic cyst: Report of a pediatric case in an uncommon location. Indian Journal of Case Reports. 2021 Jun 15:143-5.
6. Martins-Chaves RR, Granucci M, Gomez RS, de Castro WH. Glandular Odontogenic Cyst—A Case Series. Journal of Oral and Maxillofacial Surgery. 2021 May 1;79(5):1062-8.

7. Akiyama H, Hayashi K, Ikai A. Glandular odontogenic cyst: a case report and immunohistochemical study. *International Journal of Oral and Maxillofacial Surgery*. 2015 Oct 1;44:e184.
8. Tavargeri AK, Anehosur V, Niranjan KC, Nayyar A. Case report of a rare glandular odontogenic cyst in a child: A diagnostic dilemma. *International journal of health sciences*. 2019 May;13(3):53.
9. Kadam VD, Changule GR, Choudhary SH, Gade LP. Glandular odontogenic cyst in a young Indian female: A rare case report with review of literature. *Journal of Indian Academy of Oral Medicine and Radiology*. 20
10. Siponen M, Neville BW, Damm DD, Allen CM. Multifocal lateral periodontal cysts: a report of 4 cases and review of the literature. *Oral Surgery, Oral Medicine, Oral Pathology, Oral Radiology, and Endodontology*. 2011 Feb 1;111(2):225-33.
11. Ferreira JC, Vêncio EF, de Sá RT, Gasperini G. Glandular odontogenic cyst in dentigerous relationship: an uncommon case report. *Case reports in dentistry*. 2019 Jul 4;2019.
12. De Sousa SO, Cabezas NT, de Oliverira PT, de Araújo VC. Glandular odontogenic cyst: report of a case with cytokeratin expression. *Oral Surg Oral Med Oral Pathol Oral Radiol Endod* 1997;83(4):478–83
13. Sadiq H, Mahajan A, Shaikh S. Cytokeratins in Glandular Odontogenic Cyst—An Immunohistochemical Study of 4 Cases. *Annals of the Romanian Society for Cell Biology*. 2021 May 15;25(6):892-6.

14. Li L, Singh P, Ping J, Li X. Glandular odontogenic cyst of posterior maxilla: A rare entity. Int J

Case Rep Imag 2016;7(4):254–260

UNDER PEER REVIEW

UNDER PEER REVIEW