

**Autoimmune Hemolytic Anemia in Children:
Diagnostic Approach and Management**

ABSTRACT

Hemolytic anemia is not very uncommon in children. Many children are hospitalized every year due to sequelae of this heterogeneous group of disorders. Many extrinsic agents and disorders may lead to premature destruction of red blood cells. Autoimmune hemolytic anemia (AIHA) in childhood is an uncommon condition caused by the presence of auto-antibodies directed against RBCs Ag, leading to premature destruction of the cells. AIHA is generally categorized as "warm" or "cold" based on the thermal reactivity of the autoantibodies and is classified as primary (idiopathic) or secondary based on whether or not an underlying disease process is present. Early recognition and diagnosis are very important for successful management and outcome of hemolytic anemia. The evaluation of suspected immune hemolytic anemia includes a thorough history, physical examination and laboratory workup assessing for evidence of acute hemolytic anemia, possible diagnosis of an acute event,

to evaluate for concurrent causes and to rule out alternative causes. In this review article we will discuss classification, diagnostic approach and general management of hemolytic anemia in children especially focusing on autoimmune hemolytic anemia.

Key Words: Autoimmune, Hemolytic Anemia, Children, diagnostic approach, management

UNDER PEER REVIEW

INTRODUCTION

Hemolytic anemia is not very uncommon in children. Many children are hospitalized every year due to sequelae of this heterogeneous group of disorders. Many extrinsic agents and disorders may lead to premature destruction of red blood cells.

Autoimmune hemolytic anemia (AIHA) in childhood is an uncommon condition caused by the presence of auto-antibodies directed against RBCs Ag, leading to premature destruction of the cells. The hallmark of this group of diseases is the positive result of the direct antiglobulin (Coombs) test, which detects a coating of immunoglobulin or components of complement on the RBC surface. AIHA is generally categorized as "warm" or "cold" based on the thermal reactivity of the autoantibodies and is classified as primary (idiopathic) or secondary based on whether or not an underlying disease process is present. Etiology of AIHA is often idiopathic (37%), post-infective (10%), or secondary (53%); in this last case, AIHA is part of a more complex disease, usually of immunological, infective or neoplastic nature.

Early recognition and diagnosis are very important for successful management and outcome of hemolytic anemia. The evaluation of suspected immune hemolytic anemia includes a thorough history, physical examination and laboratory workup assessing for evidence of acute

hemolytic anemia, possible diagnosis of an acute event, to evaluate for concurrent causes and to rule out alternative causes. In this review article we will discuss classification, diagnostic approach and general management of hemolytic anemia in children especially focusing on autoimmune hemolytic anemia.

Classification of Hemolytic Anemia

Hemolytic anemia can be classified by various way ([see box 1](#)); extravascular/intravascular hemolysis, extracorporeal/corporeal causes or acquired/inherited.

Box 1: Classification of Hemolytic Anemia

Classification of Hemolytic Anemia
Corpuscular Causes of Hemolytic Anemia: usually inherited
<ul style="list-style-type: none">• RBC membrane disorders: Hereditary spherocytosis, hereditary elliptocytosis, hereditary stomatocytosis• Hemoglobinopathies (sickel cell anemia, thalassemia), other unstable Hb variants (HbE)• RBC enzyme deficiencies (e.g. G6PD/ PK deficiency)
Extracorporeal Causes Hemolytic Anemia
Immune Hemolytic Anemia (Coombs positive) <ul style="list-style-type: none">• Autoimmune hemolytic anemia (Primary/Secondary)• Drug-Induced hemolytic anemia• Alloantibody-Induced hemolytic anemia
Nonimmune Hemolytic Anemia (Coombs negative) <ul style="list-style-type: none">• Microangiopathic hemolytic anemia, other consumptive coagulopathy• Infection (e.g. infectious mononucleosis, viral hepatitis, streptococcal, E. coli, clostridium, bartonella, malaria, histoplasmosis)• Drugs and chemicals• Hematologic disorders (e.g. leukemia, aplastic anemia, megaloblastic anemia)• Lipid metabolism defects (e.g. abetalipoproteinemia, spur cell anemia, LCAT deficiency)• Miscellaneous (i.e. Wilson disease, erythropoietic porphyria hypersplenism)

IMMUNE HEMOLYTIC ANEMIA

Many extrinsic agents and disorders may lead to premature destruction of red blood cells. Among the most clearly defined are antibodies associated with immune hemolytic anemia (IHA). The hallmark of this group of diseases is the positive result of the direct antiglobulin (Coombs) test, which detects a coating of immunoglobulin or components of complement on the RBC surface.

Classification of Immune Hemolytic Anemia

Immune hemolytic anemia can be classified broadly into autoimmune, drug induced or alloantibody induced immune hemolytic anemia ([see box 2](#)).

Box 2: Classification of Immune Hemolytic Anemia

Autoimmune Hemolytic Anemia
Warm reacting AIHA Primary (idiopathic) Secondary (LPD, CTD – SLE, nonlymphoid neoplasms (e.g., ovarian tumors), chronic inflammatory diseases (e.g., ulcerative colitis), Immunodeficiency disorders, Evans syndrome, drugs)
Cold reacting AIHA Primary (idiopathic) Secondary (LPD, Infections; mycoplasma pneumoniae, EBV)
Paroxysmal cold hemoglobinuria Primary (idiopathic) Viral syndromes (most common) Congenital or tertiary syphilis
Mixed type AIHA
Drug-Induced Immune Hemolytic Anemia (DIIHA)
Penicillin, quinine or quinidine, methyldopa, aminosalicic acid, ceftriaxone, tetracycline, rifampin, sulfonamides, chlorpromazine, insulin; lead etc
Alloantibody-Induced Immune Hemolytic Anemia
Hemolytic disease of the fetus and newborn Hemolytic transfusion reaction

Abbreviations: LPD; lymphoproliferative disorders, CTD; connective tissue disease, SLE; systemic lupus erythematosus, EBV; Epstein–Barr virus

AUTOIMMUNE HEMOLYTIC ANEMIA

Autoimmune hemolytic anemia (AIHA) in childhood is an uncommon condition caused by the presence of auto-antibodies directed against RBCs Ag, leading to premature destruction of the cells.

AIHA is generally categorized as "warm" or "cold" based on the thermal reactivity of the autoantibodies (*see table 1*) and is classified as primary (idiopathic) or secondary based on whether or not an underlying disease process is present (*see box 2*). Etiology of AIHA is often idiopathic (37%), post-infective (10%), or secondary (53%); in this last case, AIHA is part of a more complex disease, usually of immunological, infective or neoplastic nature.

AIHA is diagnosed by positive DAT (Coombs' test) with the appropriate clinical and laboratory findings (i.e., jaundice, elevated unconjugated bilirubin, and anemia with reticulocytosis).

In children the majority of cases are acute and self-limited; arising 1-3 weeks after a viral infection and disappearing in 3 months. Overall mortality rate is 4% in children.

A positive mixed IgG/C3 DAT is more likely associated with chronic disease and younger children with an abrupt onset of symptoms have a better prognosis.

Differential Diagnosis

Box 3: Differential Diagnosis Autoimmune Hemolytic Anemia

Spherocytic Anemia

- DAT Positive: Autoimmune hemolytic anemia (warm > PCH > CAD)
- DAT Negative: Hereditary spherocytosis, clostridial sepsis, ABO incompatibility – HDN, severe burns or RBC thermal injuries, severe hypophosphatemia, Wilson disease or CDA II

Dark urine or hemoglobinuria

- Paroxysmal nocturnal hemoglobinuria

DAT Positive: DHTR, DIIHA

- Delayed hemolytic transfusion reaction (if h/o transfusion)
- Drugs (piperacillin, cefotetan, and ceftriaxone)

EVALUATION FOR SUSPECTED IMMUNE HEMOLYTIC ANEMIA

Early recognition and diagnosis are very important for successful management and outcome of hemolytic anemia. The evaluation of suspected immune hemolytic anemia (IHA) includes a thorough history, physical examination (see box 4) and laboratory workup assessing for evidence of acute hemolytic anemia, possible diagnosis of an acute event, to evaluate for concurrent causes and to rule out alternative causes (see figure 1).

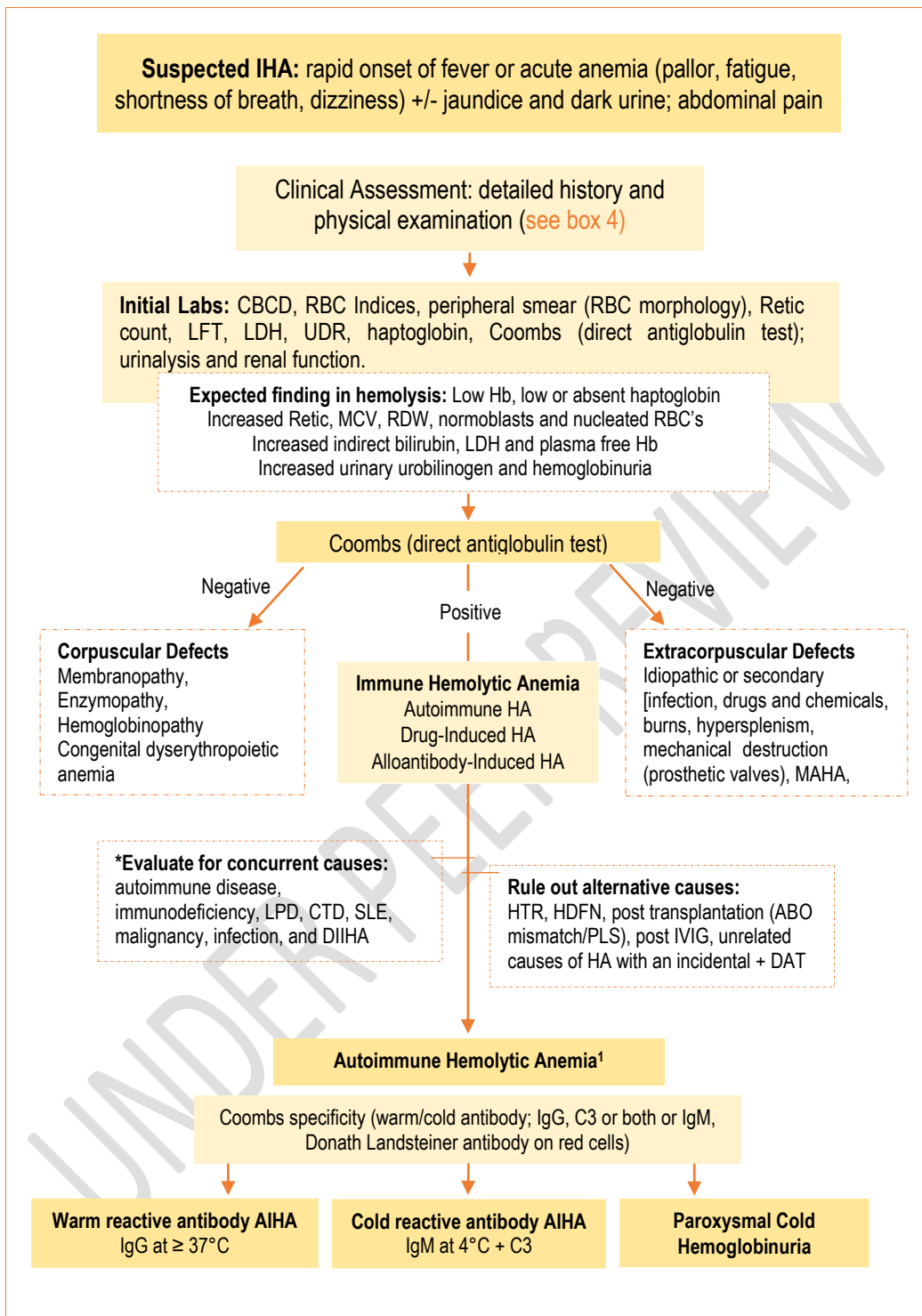
Box 4: Clinical Evaluation of Suspected Hemolytic Anemia

Clinical Evaluation of Suspected Hemolytic Anemia	
Present History	History of (h/o) fever, chills, abdominal/back pain and dark urine h/o recent infections (URTI, AGE), exposure to drugs or vaccination h/o recent travel (malaria); open wound/burns (clostridium septicemia) h/o prior transfusion (transfusion reaction) h/o intensive exercise (march hemoglobinuria)
Past Medical History [Personal and/or family]	h/o acute/persistent/recurrent anemia/jaundice and/or dark urine (after certain drugs, foods or infection) h/o cyanosis/polycythemia h/o transfusion (first time/frequency) h/o splenectomy, unexplained gallstones, autoimmune disorder (arthritis, rash, mouth ulcers) or immunodeficiency (recurrent infection, abscesses, pneumonia etc.)

Physical Examination	Pallor (note sign/symptoms of anemia; tachycardia, tachypnea, new murmur, gallop, hypotension, or shock), fever, facial bone changes (extramedullary hematopoiesis), growth retardation (chronic anemia or autoimmune disease), jaundice, petechiae/bruising, splenomegaly, hepatomegaly, lymphadenopathy (malignancy), chronic leg ulcers and cyanosis.
-----------------------------	--

Figure 1: Evaluation for Suspected Immune Hemolytic Anemia

UNDER PEER REVIEW



¹ DAT-negative AIHA is seen in 5-10% of all AIHAs. If there is strong clinical suspicion; retest with a column agglutination DAT method that includes monospecific anti-IgG/M/A and anti-C3d and for Donath-Landsteiner in children with haemoglobinuria. If still negative – do red cell eluate.

Abbreviations: IHA; immune hemolytic anemia, Hb; hemoglobin, DAT; direct antiglobulin MAHA; microangiopathic hemolytic anemia.test, LFT; liver function test, CDA; congenital dyserythropoietic anemia, LPD; lymphoproliferative disorder, CTD; connective tissue disease, SLE; systemic lupus erythematosus, EBV; Epstein–Barr virus, HDFN: Hemolytic disease of the fetus and newborn, HTR; Hemolytic transfusion reaction.

Additional testing is performed in patients with concerning clinical findings (e.g., history of recurrent infections, family history of autoimmune disease or immunodeficiency, other cytopenias [neutropenia and/or thrombocytopenia], lymphadenopathy, and/or organomegaly).

Box 5: Additional testing in selected patients with AIHA

Further investigation is required in selected patients with AIHA

- Antinuclear antibody testing
- Quantitative immunoglobulins
- Bone marrow examination
- Infection screen [serologic testing for *Mycoplasma pneumoniae* and Epstein-Barr virus (in patients with cold AIHA only)]
- Review of the patient's medications
- Antibody screen to detect alloantibodies in patients who have been exposed to foreign RBCs by previous transfusion
- Imaging as CT chest, pelvic and abdomen

Types of Autoimmune Hemolytic Anemia

AIHA is generally categorized as "warm" or "cold" based on the thermal reactivity of the autoantibodies ([see table 1](#)) and is classified as primary (idiopathic) or secondary based on whether or not an underlying disease process is present ([see box 2](#)).

UNDER PEER REVIEW

Table 1: Summary of Different types of Autoimmune Hemolytic Anemia

Characteristic		Warm Reacting AIHA	Cold Reacting AIHA	PCH	
Frequency		60-70%; secondary	50%	20-25%	6-12%
Immunoglobulin		IgG; rare IgM and IgA	IgM	IgG	
Thermal reactivity		≥ 37°C	4°C	4°C	
Fixes complement		± (usually not)	Yes	Yes	
Mechanism of Hemolysis		Macrophages digest Ab-coated RBCs	Complement mediated	Complement mediated	
DAT 4°C 37°C		Not performed IgG ± C3	C3 C3	IgG, C3 C3	
Plasma titer		Low/absent	High	Moderate	
Antigenic specificity		Rh and others ("common" Ag)	I/i	P	
Site of RBC destruction		RES; Spleen (extravascular clearance)	Liver, intravascular	Intravascular	
Treatment	Acute First line	Corticosteroids	Avoid cold, plasma exchange for severe disease	Supportive care ¹	
	Second line	Rituximab, IVIG, Splenectomy	Rituximab	Steroids	
	Third Line	Other Immunosuppressive	-	-	
	Refractory cases	Alemtuzumab, High-dose cyclophosphamide	Eculizumab, Bortezomib	Rituximab	

¹ PCH is self-limited illness, mostly resolved in days to weeks with supportive care only. Treat underlying causes e.g. infection. Stop steroid once diagnosis of PCH confirmed if empirically started. Splenectomy not usually helpful.

Management of Autoimmune Hemolytic Anemia

Acute Supportive Management

- Notify the blood bank that AIHA is suspected and that transfusion may be required. Send extra sample to blood bank as soon as Coombs+ is established to expedite typing.
- Call the blood bank supervisor if there is any delay, because failed cross matching initiates a workup that is always too slow.
- Transfusion with ABO, Rh and K matched blood is appropriate.

General Measures

- Watchful waiting and judicious in action.
- Avoid exposure to the cold in cold AIHA/ paroxysmal nocturnal hemoglobinuria.
- Maintain a good hydration status, monitor urine output and cardiac status if hemolysis is severe.
- Manage the underlying disorder, if identifiable (i.e.; infection)
- Folic acid supplement.
- Calcium and Vitamin D supplementation (with steroid therapy).

Careful Monitoring Should Require

- Check hemoglobin level (every 4-8 hourly)
- Daily (Retic, hemoglobinuria, splenic size)
- Weekly - DAT and haptoglobin level

Transfusion Therapy

- Transfusion of PRBCs is only recommended if patient is symptomatic and/or have very severe anemia.
- Use “least incompatible” matched PRBCs; start transfusion slowly.
- Do not delay transfusion if retic count is not robust.
- Transfuse for Hb < 5 in children and < 6 in teens unless very confident they are on the way up. Strongly consider transfusion in new/ freshly active AIHA if Hb < 6 in children and < 7 in teens with counts falling and inappropriate reticulocytosis.
- Use even more liberal criteria (treat for higher Hb level) in the setting of ICU illness of known heart or renal disease.
- It is recommended that only quantities sufficient to improve symptoms (approximately 3-5 mL/kg) are transfused, in order to minimize the complications of overload and incompatibility.
- For Cold/PCH: Use blood warmer! If hemolysis worsens with transfusion, consider transfusion of washed RBC's to reduce amount of complement provided.

Treatment of Warm Autoimmune Hemolytic Anemia

Primary Treatment

Corticosteroid Therapy

Starting dose of steroid is depends on patient condition, type of AIHA and disease severity.

In a patient with acute warm AIHA or PCH:

In case of rapid hemolysis and severe anemia –

- IV methylprednisolone 1-2 mg/kg every 6 hour for 1 to 3 days
- Consider blood transfusion/IVIG
- Once the patient's Hb level begins to rise and is clinically stable, shift to oral prednisone as below doses

In clinically stable patient –

- Start oral prednisone (2 mg/kg/day for children and 1 mg/kg/day for adolescents) for 2-4 weeks

If patient < 1 year of age, consider sending immune work-up prior to starting steroids.

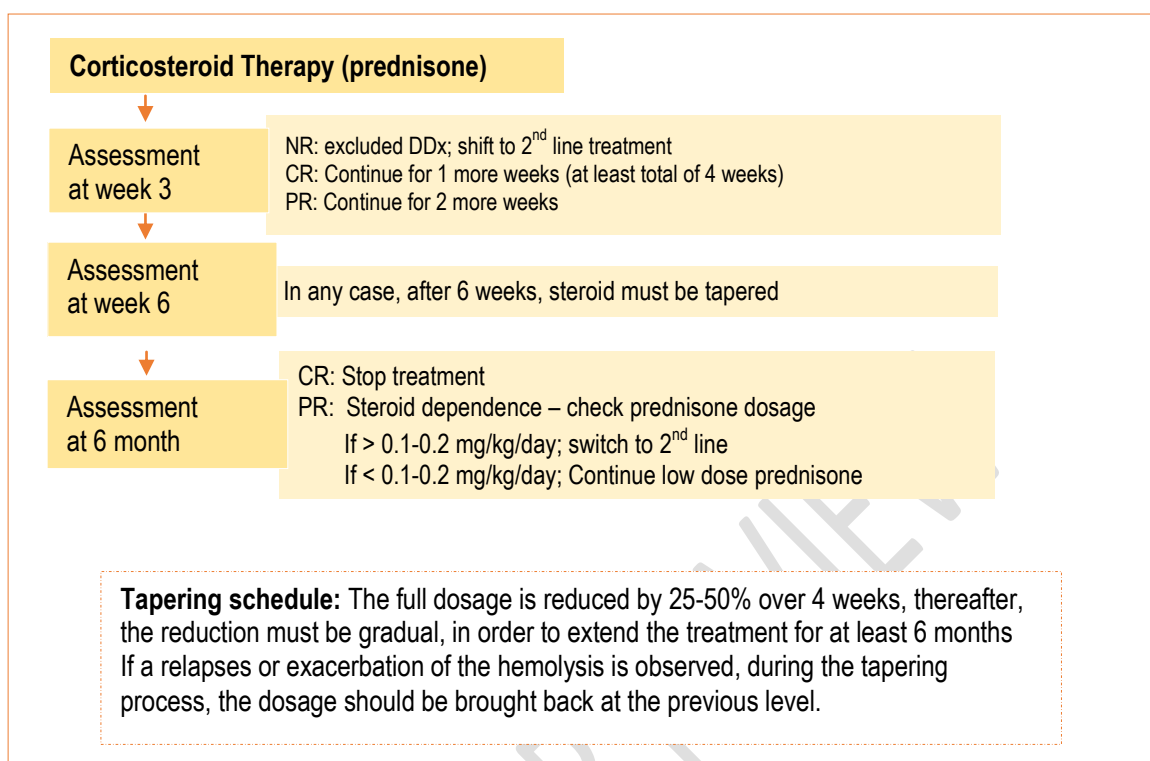
An overall clinical response of steroid treatment is ~80%, but ~60% of these loses their response upon weaning or discontinuing steroids.

Lack of response to steroids after 21 days should be considered steroid failure.

Tapering of Corticosteroid

- After 2-4 weeks of initial therapy tapering should be started gradually to avoid relapses.
- Goal is to maintain a stable Hb with a relatively low dose of corticosteroids and, preferably, an every-other-day regimen.
- 10% to 20% of dose tapering with each dose change is reasonable.
- Tapering of the corticosteroids is guided by the patient's Hb and reticulocyte count and, to a lesser degree, the DAT results.
- When a patient relapse, a very high dose of prednisone is usually required to achieve remission again.
- Total duration of corticosteroid therapy: 3-12 months after remission is achieved.
- Adverse effects of prolonged corticosteroid use should be considered and monitor.

Figure 2: Proposed Corticosteroid Treatment Plan of Warm antibody AIHA



Abbreviations: CR; complete response, PR; partial response, NR; no response, DDx; differential diagnosis

Response Assessment

Response of steroid treatment can be assessed by sign of hemolysis, increase in Hb level and transfusion requirement (see box 6).

Box 6: Steroid Response Assessment

Response Assessment	
Complete Response (CR)	Achievement of a Hb \geq lower normal limit for age, with no signs of hemolysis, i.e. normal reticulocyte count and bilirubin concentration
Partial Response (PR)	An increase of Hb of ≥ 2 g/dL, without the Hb concentration reaching a normal value for the patient's age
No Response (NR)	An increase of Hb < 2 g/dL and/or dependence on transfusions

Intravenous Immunoglobulin (IVIg)

IVIg may be considered as adjunctive therapy to steroids, in more severe cases and in a patient who is not responding to steroids.

Dose range of 0.4 to 2 gm/kg/day for 2 to 5 days.

It is beneficial in 55%, but whether they were receiving combined corticosteroid therapy is not reported.

Therapeutic Plasma Exchange (Plasmapheresis)

Although plasmapheresis is more effective in IgM-induced HA, in severely ill child with IgG-induced HA it may be considered as a temporizing option for those who has a suboptimal response to either transfusion or pharmacological therapy or may not have had time to respond to corticosteroid therapy.

Each cycle can remove up to 65% of the circulating autoantibodies, so, it is frequently necessary to repeat the procedure.

Treatment of Chronic or Refractory AIHA

All patients with chronic or refractory AIHA must be evaluated for secondary causes of hemolytic anemia.

Rituximab (anti CD20 antibody)

Indications: Non-responder/refractory to steroids, or who respond to steroids but have significant adverse effects.

Standard dose (375 mg/m² weekly) for 1 to 6 weeks.

> 90% of patients have a complete response that lasts 7 to 28 months.

If taking corticosteroids before the initiation of rituximab, should continue steroids until a response to rituximab is clearly established.

Adverse Effects: severe infusion reactions, infection, progressive multifocal leukoencephalopathy, and reactivation of hepatitis B and fulminant hepatitis.

Contraindication: Untreated hepatitis B infection

Immunizations should be delayed until the B-cell recovery

Post treatment hypogammaglobulinemia should be treated with prophylactic administration of IVIG.

Splenectomy

Splenectomy in childhood AIHA considered a third line treatment option.

Indication: If the hemolytic process is brisk despite the use of high-dose corticosteroid therapy, rituximab, and transfusions and the patient cannot maintain a reasonable hemoglobin level safely, or if chronic hemolysis develops.

Whenever possible, children should be older than 5 years of age and the disease should be present for at least 6-12 months with no significant response to medical treatment prior to undertaking splenectomy.

Splenectomy is beneficial in 60-75% of patients.

Pre/post splenectomy management plan should be instituted.

Alternative Immunotherapeutic Agents

Indications: corticosteroids non responder, rituximab, and splenectomy or for patients who have contraindications to those therapies.

Cyclophosphamide, cyclosporine, azathioprine (6-mercaptopurine), MMF (mycophenolate mofetil, Cell-CEPT) and Campath-1H.

A response may take months, and thus treatment should be continued for up to 6 months before it is considered to have failed.

40-60% response rate.

Other Options

Danazol effectiveness is controversial.

Monoclonal antibodies have been successfully used in patients with resistant disease ie Campath-1 HI (Alemtuzumab; anti CD52 antibody).

Hematopoietic stem cell transfusion is a potential option with limited experience.

Paroxysmal Cold Hemoglobinuria (PCH)

- PCH is an acute illness, often seen after viral URTI (Measles, mumps, varicella, syphilis, and mycoplasma)
- Cold reactive anti-erythrocyte autoantibodies of the IgG subtype (Donath Landsteiner Antibody) act against P antigen autoantigen on RBC surfaces and fixes complement at 4°C. On warming to 37°C, the complement is activated and hemolysis induced.
- PCH should be considered if the patient has hemoglobinuria and C3 alone is present on the RBC.

Treatment

- Self-limited illness, mostly resolved in days to weeks with supportive care only.
- Treat underlying cause e.g. infection
- Steroids (stop once diagnosis of PCH confirmed if empirically started)

- Splenectomy not usually helpful

SECONDARY AUTOIMMUNE HEMOLYTIC ANEMIA

- In pediatric studies, secondary causes were found in 24-63% of cases; 10% were purely post-infectious, and in 53% an underlying immunologic disorder was found.
- Common secondary causes of AIHA in children include autoimmune disease, immunodeficiency, Evans syndrome, malignancy, infection, transplantation, and drugs (*see box 7*).
- Children < 1 year of age warrants evaluation for an underlying immunodeficiency prior to corticosteroid or immunosuppressive agents.
- All patients with AIHA should be evaluated for the presence of concurrent causes.

Box 7: Etiology of Secondary Immune Hemolytic Anemia

Etiology of Secondary Immune Hemolytic Anemia

- Infection: Epstein-Barr virus, mycoplasma pneumonia, parvovirus B19, Cytomegalovirus, varicella, hepatitis C, rubella
- Drugs: Piperacillin, cefotetan, ceftriaxone (most common)
- Autoimmune disease: Evans syndrome, SLE, Autoimmune hepatitis/thyroiditis, Graves disease, vitiligo, rheumatic disease, type 1 DM, IBD
- Autoimmune lymphoproliferative disease
- Immunodeficiency: CVID, combined immunodeficiency, ADA deficiency, HIV/AIDS, Wiskott-Aldrich syndrome
- Cancer: Acute leukemia, lymphoma, myelodysplasia

Abbreviations: SLE: Systemic lupus erythematosus, DM: diabetes mellitus, IBD: inflammatory bowel disease, CVID: common variable immunodeficiency, ADA: adenosine deaminase deficiency, HIV: human immunodeficiency virus, AIDS; acquired immune deficiency syndrome.

Management

- Successful treatment of underlying condition may also improve the AIHA.
- If the associated condition does not require treatment, AIHA can usually be approached in a similar fashion to primary AIHA, although treatment decisions must be individualized.

REFERENCE

Hill A, Hill QA. Autoimmune hemolytic anemia. *Hematology Am Soc Hematol Educ Program.* 2018;2018(1):382-389.

doi:10.1182/asheducation-2018.1.382.

Nathan and Oski's hematology and oncology of infancy and childhood. — 8th Ed (2015), page 411-429.

Ladogana S, et al. Diagnosis and management of newly diagnosed childhood autoimmune haemolytic anaemia. Recommendations from the Red Cell Study Group of the Paediatric Haemato-Oncology Italian Association. *Blood Transfus.* 2017;15(3):259-267.

Hill QA, et al. The diagnosis and management of primary autoimmune haemolytic anaemia. *Br J Haematol.* 2017;176(3):395-411.

Aladjidi N, Jutand MA, Beaubois C, et al. Reliable assessment of the incidence of childhood autoimmune hemolytic anemia. *Pediatr Blood Cancer* 2017; 64.

Chou ST, Schreiber AD. Autoimmune hemolytic anemia. In: Nathan and Oski's Hematology and Oncology of Infancy and Childhood, 8th ed, Orkin SH, Fisher DE, Look T, Lux SE, Ginsburg D, Nathan DG (Eds), WB Saunders, Philadelphia 2015. p.411.

Aladjidi N, et al. New insights into childhood autoimmune hemolytic anemia: a French national observational study of 265 children. *Haematologica* 2011; 96:655.

Barcellini W, Fattizzo B, Zaninoni A. Current and emerging treatment options for autoimmune hemolytic anemia. *Expert Rev Clin Immunol* 2018; 14:857.

Teachey DT, Lambert MP. Diagnosis and management of autoimmune cytopenias in childhood. *Pediatr Clin North Am* 2013; 60:1489.

Naithani R, Agrawal N, Mahapatra M, et al. Autoimmune hemolytic anemia in children. *Pediatr Hematol Oncol* 2007; 24:309.

Vagace JM, Bajo R, Gervasini G. Diagnostic and therapeutic challenges of primary autoimmune haemolytic anaemia in children. *Arch Dis Child* 2014; 99:668.

Sankaran J, Rodriguez V, Jacob EK, et al. Autoimmune Hemolytic Anemia in Children: Mayo Clinic Experience. *J Pediatr Hematol Oncol* 2016; 38:e120.

Aladjidi N, et al. New insights into childhood autoimmune hemolytic anemia: a French national observational study of 265 children. *Haematologica* 2011; 96:655.

Barros MM, Blajchman MA, Bordin JO. Warm autoimmune hemolytic anemia: recent progress in understanding the immunobiology and the treatment. *Transfus Med Rev* 2010; 24:195.

Zanella A, Barcellini W. Treatment of autoimmune hemolytic anemias. *Haematologica* 2014; 99:1547.

Jaime-Pérez JC, et al. Current approaches for the treatment of autoimmune hemolytic anemia. *Arch Immunol Ther Exp (Warsz)* 2013; 61:385.

Naithani R, Agrawal N, Mahapatra M, et al. Autoimmune hemolytic anemia in children. *Pediatr Hematol Oncol* 2007; 24:309.

Barcellini W, Fattizzo B, Zaninoni A. Current and emerging treatment options for autoimmune hemolytic anemia. *Expert Rev Clin Immunol* 2018; 14:857.

Hill A, Hill QA. Autoimmune hemolytic anemia. *Hematology Am Soc Hematol Educ Program* 2018; 2018:382.

UNDER PEER REVIEW