

Case study

Anti-Tuberculosis Treatment Induced DRESS Syndrome – A Case Report

ABSTRACT

ABSTRACT:

INTRODUCTION: Drug Reaction with Eosinophilia and Systemic Symptoms (DRESS) is a medical condition that is a severe adverse drug event. Anti-tuberculosis medications may precipitate this condition.

Study design: case report.

Place and Duration of Study: Sample: Department of internal Medicine, and Department of Pathology, Krishna Institute of Medical Sciences (KIMS), KIMS Hospital HYDERABAD,
Methodology: A 73-year-old gentleman had complaints suggestive of left ankle arthritis of 8 months duration and was diagnosed with tuberculous osteomyelitis 6 weeks ago based on positive Xpert[®] MTB/RIF and necrotizing granulomatous inflammation on histopathology. He was started on anti-tuberculosis treatment and presented 6 weeks later with high-grade fever, generalized rashes, and itching. Eosinophilia was noted in the complete hemogram and liver enzymes were elevated. Skin biopsy showed SJS (Stevens-Johnson syndrome). He was diagnosed as DRESS syndrome. It was most likely caused by Anti-Tuberculosis medications. His tuberculosis medications were modified and steroids were started after which his condition improved.

Conclusion: Most of the first-line anti-tuberculosis medications can cause DRESS Syndrome. Clinical suspicion and early diagnosis with appropriate tests help to treat this condition early without any significant morbidity and mortality. The causative drug should be withdrawn, Steroids, and IVIg can be used for the treatment depending on the severity.

Keywords: Drug Reaction with Eosinophilia and Systemic Symptoms (DRESS), Anti-Tuberculosis Treatment (ATT), Stevens-Johnson Syndrome (SJS).

1. INTRODUCTION :

Drug Reaction with Eosinophilia and Systemic Symptoms is abbreviated as DRESS. It is also represented as drug-induced hypersensitivity syndrome (DIHS). Anti-tuberculosis medications may precipitate this condition.

It is a severe adverse drug event marked by skin eruptions, fever, swollen lymph nodes, liver abnormalities, leucocytosis abnormalities (leucocytosis, atypical lymphocytosis, or eosinophilia) and the involvement of visceral organs.⁽¹⁾

It is among the known prominent types of Severe Cutaneous Adverse Reactions (SCAR). According to the European federation, SCAR is a common criterion that constitutes various syndromes such as Acute Generalized Exanthematous Pustulosis (AGEP), Stevens-Johnson syndrome (SJS), and Toxic Epidermal Necrolysis (TEN).⁽²⁾ DRESS syndrome is predicted to have an incidence rate of 1:1000 to 1:10,000 drug exposures. DRESS is most commonly caused by sulphonamides, Non-Steroidal Anti-Inflammatory Drugs (NSAIDs), or antiepileptics, and almost all ATT.⁽³⁾ DRESS has a mortality rate of 10%. It can also lead to internal organ damage; Symptoms generally occur in two to three weeks after the administration of the causative drug.⁽⁴⁾

The Pathophysiology of DRESS is partially presumed. Various pathological triggering factors have been involved in the development of DRESS. Some of the factors that may lead to the development of DRESS are, reactivation of human herpes viruses, herpes virus (HHV)-6, herpes virus (HHV) -7, Epstein Barr virus (EBV), along with defects in detoxification of metabolites, and delayed acetylation.⁽⁵⁾

To Define DRESS more accurately, a RegiSCAR scoring system was established by the European registry association. This scoring system classified various medical conditions such as Drug Reaction with Eosinophilia and Systemic Symptoms (DRESS), Hypersensitivity Syndrome (HSS) cases as a) definite, b) possible, and c) no case. RegiSCAR has developed an European registry of severe cutaneous adverse reactions (SCAR) which includes, TEN, AGEP, SJS, and DRESS.⁽⁶⁾

The standard regimen for tuberculosis treatment involves the administration of a combination of antituberculosis medications for a minimum period of six months. Anti-tuberculosis treatment is classified as first-line and second-line therapy. The first-line treatment of tuberculosis is highly effective with less side effects. Standard first-line treatment consists of rifampicin, isoniazid, ethambutol, pyrazinamide, and Streptomycin. The Second-line treatment includes group A medication such as moxifloxacin or levofloxacin, linezolid, bedaquiline, Group B medication such as cycloserine, clofazimine, or terizidone, and Group C medication such as ethambutol, pyrazinamide, delamanid, imipenem-cilastatin or meropenem, streptomycin or amikacin, ethionamide. Adverse Drug Events caused by ATT increase the probability of treatment non-compliance, failure of treatment, morbidity, and mortality.⁽⁷⁾ DRESS syndrome must be detected as early as possible, and the offending medicine must be discontinued. The earlier the medicine is discontinued, the better is the outcome. Initially, the patient is treated with corticosteroids and other medications that symptomatically stabilize the patient's condition, but evidence for their efficacy is inadequate. Nonsteroidal immunosuppressants may also be required.⁽⁸⁾

2. CASE REPORT :

A 73-year-old gentleman was suffering from pain, swelling, restricted movement, and tenderness, in the left ankle of 8 months duration and was diagnosed with left ankle tuberculosis 6 weeks ago based on positive Xpert[®] MTB/RIF and necrotizing granulomatous inflammation on histopathology. He was being treated with rifampicin, isoniazid, pyrazinamide, ethambutol, and pyridoxine in weight-appropriate doses for 6 weeks. He was adherent to the medication advised. His pain and swelling in the left ankle improved. He presented 6 weeks later with generalized weakness, high-grade fever with intermittent chills for 3 days, bilateral lower limbs swelling, pain, reddish discoloration, and tenderness. He also had a generalized rash with mild itching. He had a fall at home with an abrasion on his left hand. He had no history of urinary or respiratory complaints.

On physical examination in the emergency ward, he had tachycardia (110 beats/min), blood pressure (BP)-90/50mm/Hg, Respiratory rate (RR)- 18/min, temperature- 102⁰F, and oxygen saturation of room air 98%. He had generalized darkening of the skin on bilateral lower limbs and had a non-palpable erythematous rash with mild itching over the chest, abdomen, trunk, limbs, and oral mucosa. He was normally oriented and alert. The patient's laboratory results are as shown In Table1.

Table – 1:

Tests	Day1	Day3	Day 6
CBP- Haemoglobin (gm%)	11.0	10.5	9.0
Haematocrit PCV (vol%)	33.6	31.0	27.3
WBC Count (cells/cumm)	10,100	8,330	7,170
Platelet count (lakhs/cumm)	2.19	2.02	2.31
Lymphocytes	08%	11%	22%
Eosinophils	11%	9%	6%

Monocytes	15%	10%	9%
LFT – Total bilirubin (mg/dl)	2.99	2.49	1.57
Direct bilirubin (mg/dl)	1.99	1.23	0.71
ALT (U/L)	108	68	43
AST (U/L)	285	117	41
Blood Urea (mg/dl)	62	39	41
Electrolytes – Sodium (mmol/l)	126	130	131.6

The laboratory reports showed normal leukocyte count with eosinophilia, hyponatremia, and transaminitis. Venous doppler was negative for Deep Venous Thrombosis and showed mild subcutaneous edema in bilateral foot extending to lower limbs and enlarged bilateral inguinal lymph nodes. HRCT showed interstitial lung disease with usual interstitial pneumonia and enlarged mediastinal lymph node.

He was initially suspected to have cellulitis with toxic shock syndrome. He was treated with meropenem, clindamycin after fluid resuscitation. Doxycycline was used for suspected rickettsial infection. Dengue was also considered but dengue NS1 was negative, IgM was positive (test done on day 3 of illness) representing likely a recent infection but not a current infection. With persisting erythema, the appearance of new bullae on pressure areas and changes of skin necrosis along with eosinophilia and liver dysfunction DRESS Syndrome was suspected. A Skin biopsy was done, it showed Stevens-Johnson Syndrome (*Fig. 1*) and according to the symptoms, the condition was confirmed as DRESS Syndrome.

The first-line ATT were stopped and modified ATT, of Amikacin, Levofloxacin, and linezolid were started. Hydrocortisone was initiated, ozenoxacin cream, fusidic acid cream, and excela may lotion were prescribed for topical application. The patient showed a good response to the treatment, eventually the fever, rashes subsided followed by skin peeling, and his hemogram and liver function tests normalized. After 12 days of treatment, his blood parameters improved and Rifampicin was rechallenged, the patient showed no new symptoms. He improved clinically and was discharged. The medications were to be continued and then reviewed at a visit in the outpatient department after 2 weeks. Isoniazid was rechallenged successfully later.

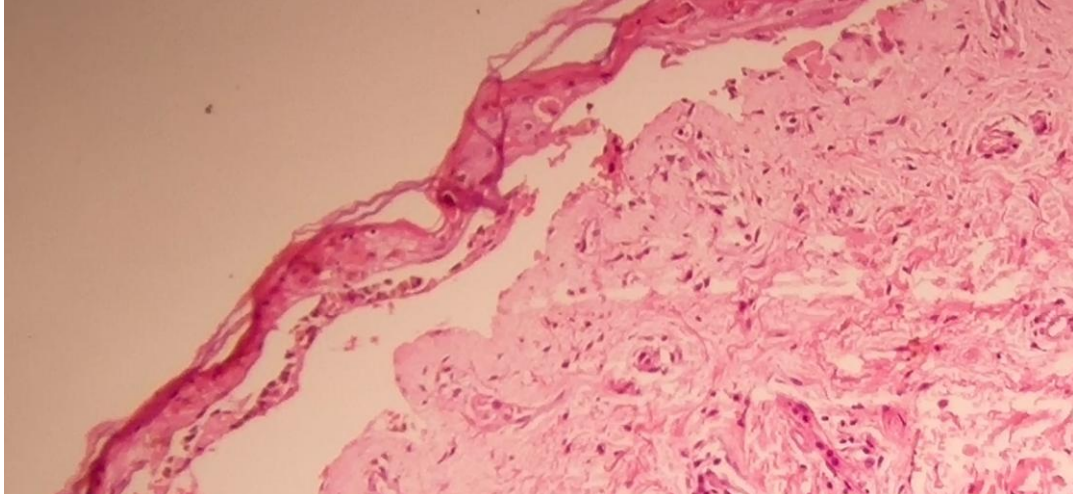


Fig.1- Skin Biopsy showing Necrotic epidermis separated from the underlying

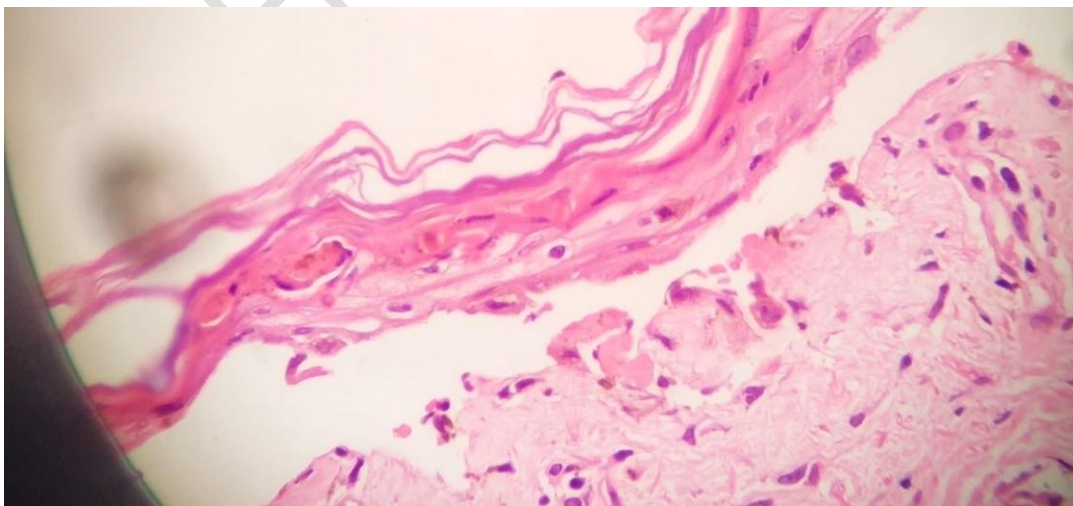


Fig.2 – Showing giant cell with bone granulomatic lesions

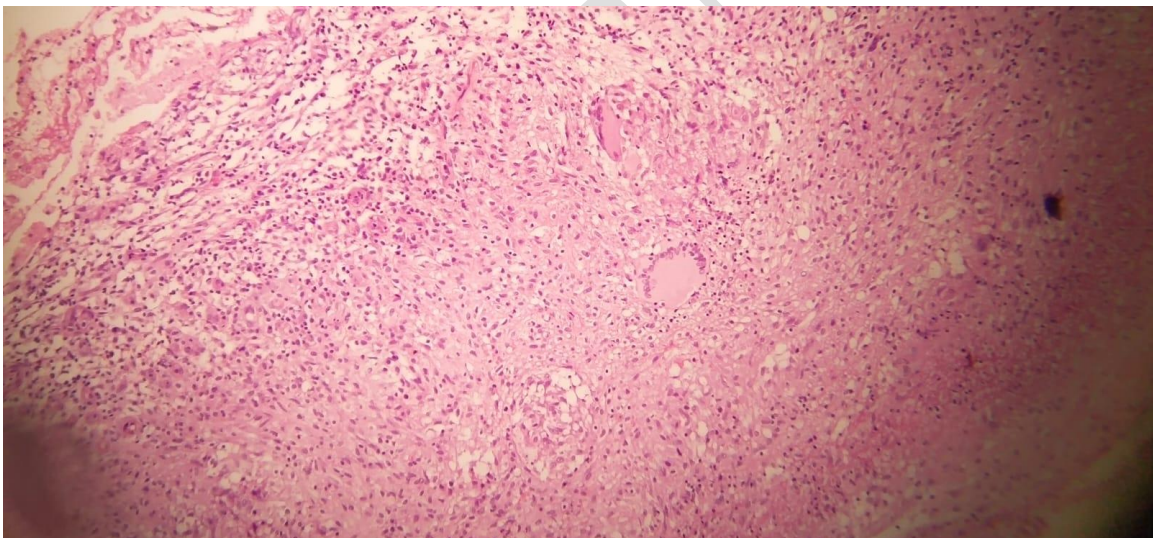


Fig 3.

3 DISCUSSION:

DRESS Syndrome is a severe delayed hypersensitivity reaction (type IV) which is often undiagnosed or diagnosed late. It can be due to many medications but anti-tuberculosis medications are a common cause. We present a case in which the patient met the typical diagnostic criteria for DRESS syndrome. Skin biopsy showed SJS, eosinophilia and transaminitis was observed in a complete hemogram which confirmed DRESS Syndrome. As per the REGISCAR SCORING guidelines the patient in this case report had a score of

five points (fever, eosinophilia, lymphadenopathy, liver abnormality and skin rash suggestive of dress) indicating a probable case of DRESS.

Young-HOON ET.AL in a combined review of several case reports, reported that almost all the first-line ATT caused DRESS syndrome.⁽⁹⁾ MARION ALLOUCHERY et al. investigated the French pharmacovigilance database for cases of the potent medications that may cause DRESS. In his literature study, he reported cases of DRESS with the use of pyrazinamide, rifampicin, ethambutol, and isoniazid. Their study included 67 patients who experienced ATT-associated DRESS; they had an average age of 61 years. The most affected organs were the liver and kidneys. Two patients did not recover. 11 patients had skin tests performed and 8 of them were found to be positive for rifampicin and isoniazid. In 20 of the cases, antituberculosis medicines were the only suspects. In terms of the study, the most suspected drug causing DRESS were found to be rifampicin and isoniazid.⁽¹⁰⁾ In a retrospective study by HO YEONG JUNG et al; 1,253 adult patients on ATT were taken out of which 15 were identified with DRESS syndrome, Among all anti-tuberculosis medication ethambutol had an incidence of 53.5%, Rifampicin 26.7%, Pyrazinamide 20.0%, Streptomycin 13.3% and Isoniazid 6.7% respectively.⁽¹¹⁾ PALMERO D et al; in their case study comprising 11 cases of ATT-induced DRESS syndrome noticed that almost all the subjects had acute hepatitis, and a rash. Among all those patients one, died of multiple organ dysfunction, and there was no progression of tuberculosis after corticosteroid treatment. The most common causative drug was rifampicin, In the majority of cases, retreatment involved the use of levofloxacin, ethambutol, streptomycin, and cycloserine.⁽¹²⁾

The mainstay of the management of DRESS syndrome is immediate withdrawal of the causative drug and administration of corticosteroids. Intensive care or burn unit settings are beneficial in the treatment of DRESS syndrome, which is exacerbated by exfoliative dermatitis.⁽¹³⁾ The management and treatment of SCARs necessitates close monitoring because it has the potential to cause multi-organ dysfunction and fluid loss as a result of skin damage. Fluid replacement should be initiated along with a hypercaloric and hyper protein diet. The wound should be taken care of using antiseptic baths or diluted antiseptic sprays daily. Dermatological care with the use of appropriate skin moisturizers is needed. During the acute phase, mucosal lubrication with emollients is recommended. Along with supportive care, many other therapeutic approaches are also available, such as plasmapheresis and use of several immunosuppressants (corticosteroids, cyclophosphamide, intravenous immunoglobulins, calcineurin inhibitors, and anti TNF therapies). The use of N-acetylcysteine in case of anticonvulsant induced DRESS syndrome may aid in drug detoxification and limit reactive metabolites. Systemic corticosteroids, in particular, methylprednisolone is administered in weight-appropriate doses up to 600-1000 mg/day. Cyclosporine, an anti-apoptotic drug, may block CD8 + T cell receptors, delaying disease development following a minuscule treatment of 3-10mg/kg. In addition, the anti-TNF drug etanercept was found to enhance healing.

Use of high dose intravenous immunoglobulins is also effective as it has anti-inflammatory properties and also replenishes the low levels of immunoglobulins in the patient's body. In case of patients with life-threatening conditions like hemophagocytosis with bone marrow failure, encephalitis, severe hepatitis, renal failure, and respiratory failure, steroids along with IVIG at a dose of 2 g/kg for 5 days can be used.⁽¹⁴⁾ A retrospective study by CHEN.ET.AL;

included 60 hospitalized patients with average age of 51 years having DRESS, and the culprit drugs were found to be allopurinol (19 patients), NSAIDs (3 patients), and Anti-tuberculosis drugs (2 patients). Systemic corticosteroids (Methylprednisolone and oral prednisone), were used to treat 75% of the patients. 2 patients were treated with Intravenous Immune Globulin (IVIG) and 10 patients were treated with supportive care. ⁽¹⁵⁾ A multi-centered study by DA WOON SIM involved 123 patients suffering with dress syndrome out of which 20% of the cases (25 patients) were due to ATT. Among them 79% of patients were treated with systemic steroids, IVIG (intravenous immunoglobulins) and 5% with cyclosporine (15). ⁽¹⁶⁾ JINBO CHEN ET AL; conducted study on 82 patients having Stevens-Johnson syndrome use of corticosteroids along with IVIG, the duration of hospitalization was shorter than those treated with monotherapy with steroids. ⁽¹⁷⁾

4. CONCLUSION

Drug Reaction with Eosinophilia and Systemic Symptoms (DRESS) Syndrome is not a common complication. However, it is to be considered as a possible diagnosis in patients presenting with or without cutaneous symptoms. The use of clinical criteria, laboratory data, histopathology, and diagnostic tests to establish an early diagnosis is critical. Common causes are the use of antiepileptics, sulphonamides, or Non-Steroidal Anti-Inflammatory Drugs (NSAIDs), and almost all first-line anti-tuberculosis medication. The causative medicine has to be stopped immediately, and the patient is provided supportive care, including systemic corticosteroids in some cases. ATT can then be rechallenged as the next step.

REFERENCES

1. Walsh SA, Creamer D. Drug reaction with eosinophilia and systemic symptoms (DRESS): a clinical update and review of current thinking. *Clinical and Experimental Dermatology: Clinical dermatology*. 2011 Jan;36(1):6-11.
- Adler NR, Aung AK, Ergen EN, Trubiano J, Goh MS, Phillips EJ. Recent advances in the understanding of severe cutaneous adverse reactions. *British Journal of Dermatology*. 2017 Nov;177(5):1234-47.
- Chiou CC, Yang LC, Hung SI, Chang YC, Kuo TT, Ho HC, Hu S, Hong HS, Chung WH. Clinicopathological features and prognosis of drug rash with eosinophilia and systemic symptoms: a study of 30 cases in Taiwan. *Journal*

of the European Academy of Dermatology and Venereology. 2008 Sep;22(9):1044-9.

4. Matta JM, Flores SM, Cherit JD. Drug reaction with eosinophilia and systemic symptoms (DRESS) and its relation with autoimmunity in a reference center in Mexico. *Anais brasileiros de dermatologia*. 2017 Jan;92:30-3.

Choudhary S, McLeod M, Torchia D, Romanelli P. Drug reaction with eosinophilia and systemic symptoms (DRESS) syndrome. *The Journal of clinical and aesthetic dermatology*. 2013 Jun;6(6):31.

Pannu AK, Saroch A. Diagnostic criteria for drug rash and eosinophilia with systemic symptoms. *Journal of family medicine and primary care*. 2017 Jul;6(3):693.

7 <https://tbfacts.org/second-line-drugs/>

Choudhary S, McLeod M, Torchia D, Romanelli P. Drug reaction with eosinophilia and systemic symptoms (DRESS) syndrome. *The Journal of clinical and aesthetic dermatology*. 2013 Jun;6(6):31.

황영훈, 장동연, 강성윤, 손경희, 강동윤, 이창훈, 강혜련. 1 차 및 2 차 항결핵제에 의한 DRESS (drug reaction with eosinophilia and systemic symptom) 증후군 1 예와 문헌 고찰. *Allergy, Asthma & Respiratory Disease*. 2017 Mar 1;5(2):111-6.

1Allouchery M, Logerot S, Cottin J, Pralong P, Villier C, Saïd BB, Network FP. Antituberculosis drug-associated DRESS: a case series. *The Journal of Allergy and Clinical Immunology: In Practice*. 2018 Jul 1;6(4):1373-80.

1Jung HY, Park S, Shin B, Lee JH, Lee SJ, Lee MK, Lee WY, Yong SJ, Kim SH. Prevalence and clinical features of drug reactions with eosinophilia and systemic symptoms syndrome caused by antituberculosis drugs: a retrospective cohort study. *Allergy, asthma & immunology research*. 2019 Jan 1;11(1):90-103.

1Palmero D, Castagnino J, Musella RM, Mosca C, Gonzalez Montaner P, de Casado GC. Difficult clinical management of anti-tuberculosis DRESS syndrome [Case study]. *The International Journal of tuberculosis and lung disease*. 2013 Jan 1;17(1):76-8.

- Husain Z, Reddy BY, Schwartz RA. DRESS syndrome: Part II. Management and therapeutics. *Journal of the American Academy of Dermatology*. 2013 May 1;68(5):709-e1.
- 1Duong TA, Valeyrie-Allanore L, Wolkenstein P, Chosidow O. Severe cutaneous adverse reactions to drugs. *Lancet*. 2017;390(10106):1996–2011.
- 1Chen YC, Chiu HC, Chu CY. Drug reaction with eosinophilia and systemic symptoms: a retrospective study of 60 cases. *Archives of dermatology*. 2010 Dec 20;146(12):1373-9
- 1Sim DW, Yu JE, Jeong J, Jung JW, Kang HR, Kang DY, Ye YM, Jee YK, Kim S, Park JW, Kang MG. Variation of clinical manifestations according to culprit drugs in DRESS syndrome. *Pharmacoepidemiology and drug safety*. 2019 Jun;28(6):840-8.
- 1Chen J, Wang B, Zeng Y, Xu H. High-dose intravenous immunoglobulins in the treatment of Stevens-Johnson syndrome and toxic epidermal necrolysis in Chinese patients: a retrospective study of 82 cases. *Eur J Dermatol*. 2010;20(6):743–7.