

EFFECT OF AQUEOUS EXTRACT OF *Moringa Oleifera* LEAVES ON SOME SERUM ENZYMES OF WISTAR RATS WITH CARBON TETRACHLORIDE-INDUCED LIVER DAMAGE

Abstract

The study was aimed at evaluating the hepatoprotective effect of *Moringa oleifera* leaf extract against liver damage induced by carbon tetrachloride (CCl₄). Twenty five (25) Wistar albino rats were used. They were administered orally with CCl₄ in a ratio of 1:1 at a dose of 1500mg/kg and allowed for five days before treated with *Moringa oleifera* leaf extract at concentrations of 50mg/kg, 100mg/kg, and 150mg/kg daily for one week. Alanine aminotransferase (ALT), aspartate aminotransferase (AST), alkaline phosphatase (ALP), gammaglutamyltransferase (GGT), and total protein (TP) in the blood cells were determined. The study lasted for 18 days. The liver enzyme, ALT, and TP were increased after injection with CCl₄. Treatment with *Moringa Oleifera* leave at various dose reveals a significant reduction ($p < 0.05$). AST was increased after treatment with CCl₄. Treatment with *Moringa oleifera* leaf reveals a dose-dependent significant reduction ($p \leq 0.05$). No significant reduction occurred at ALP in comparison to only CCl₄-treated group, but in comparison with the normal control, the result of this study shows that aqueous *Moringa oleifera* leaf extract may have hepatoprotective action against CCl₄-induced liver damage in rat.

Keywords: *Moringa oleifera*, antioxidant, hepatoprotective, carbon tetrachloride, liver damage.

INTRODUCTION

Liver is one of the largest organs found in human body and the chief site for intense metabolism and excretion (Ahsan *et al.*, 2009). Liver damage is associated with cellular necrosis, increase in tissue lipids peroxidation and depletion of reduced glutathione levels. In addition, serum levels of many biochemical markers like transaminases, alkaline phosphatase, bilirubin, triglyceride and cholesterol are elevated in liver diseases and such diseases cause a serious challenge to international public health (Ahsan *et al.*, 2009). Unfortunately, conventional or synthetic drugs used in the treatment of liver disease are inadequate and sometimes can have serious side effects (Rao *et al.*, 2005). Moreover, there are still no specific treatment in modern medicine that give protection to the liver against damage or help to regenerate hepatic cells (Chatterjee, 2000; Chattopadhyay, 2003).

The use of medicinal plants to cure various forms of liver diseases and dysfunctions is becoming increasingly popular and has received wide acceptance (Oyaghemi & Odetola, 2010). However, a large number of medicinal plants like *Moringa* (*Moringa oleifera*) have been found to offer some hepatoprotection (Trivedi & Rawal, 2000; Ghosh *et al.*,

2007; Prakash *et al.*, 2008; Ahsan *et al.*, 2009; & Oyagbemi & Odetola, 2011). The use of herbal product for medicinal benefits has played an important role in nearly every culture on earth. Herbal medicine was practiced by ancient people of Africa, Asia, Europe and the America (Wargovich *et al.*, 2001).

Over 50% of all modern clinical drugs are of natural product origin and natural products play an important role in drug development programs of the pharmaceutical industry. The consumption of variety of local herbs and vegetable by man is believed to contribute significantly to the improvement of human health, in terms of prevention, and/or cure of disease because plants have long served as a useful and rational source of therapeutic agents (Roberts & Tyler, 1999).

The liver plays numerous functions and carries out important activities. However the liver is exposed to a number of insults and is one of the body's organ most subjected to injury (diseases). Liver disease is a global problem. Conventional drugs used in the treatment of liver diseases are sometimes inadequate and can have serious adverse effect on human. This study evaluated the effect of moringa leaf extract on carbon tetrachloride (CCl₄)-induced liver damage of albino rat.

MATERIALS AND METHODS

Preparation of Aqueous *Moringa oleifera* extract

Seeds of *Moringa oleifera* were air dried for one week and then ground into fine powder using mortar and pestle. A total of 10g of the ground powder was soaked in 100ml of distilled water. The extract was separated using sterile muslin cloth and filtered through sterile whatman filter paper (No. 02).

Carbon tetrachloride Administration: 20ml of CCl₄ was diluted in 20ml of vegetable oil in 1:1 ratio and was used to induce liver damage in the test animals (Rao & Misra, 1998).

Preparation of the Animals

A total of twenty five wistar rats, weighing 140-160g were obtained from the animal house of the Department of physiology, University of Port Harcourt. They were housed in stainless steel cages (5 rats per cage) and kept in a well-ventilated room. The rats were fed with standard diet (Livestock Feeds Nig. Ltd. Ikeja, Nigeria) and water *ad libitum*. The standard guidelines for the use of experimental animals were adhered to.

Plant Extract Administration

The rats were divided into five experimental groups at the end of one week following grouping and acclimatization; 50mg/kg, 100mg/kg, and 150mg/kg of the aqueous *Moringa oleifera* extract was orally administered to the rats in groups 3, 4, 5. The CCl₄ was administered at a dose of 0.5ml/kg body weight orally to the rats in groups 3, 4 and 5. About 5ml of the extract was measured out and then 50ml of distilled water was added

to obtain an extract concentration of 50mg/kg. The procedure was serially repeated to obtain a 100mg/kg and 150mg/kg extract concentration required for treatment.

Five days after the extract administration, each rat was withdrawn from the cage, and placed in a desiccators containing cotton wool soaked in chloroform to anaesthetize it. They were sacrificed and fresh blood drawn by cardiac puncture and placed in anticoagulant sample bottles (lithium heparin). The collected blood was centrifuged at 4000rpm for 10 minutes and serum was collected into sample containers and used for the assay of hepatic enzyme activities of Alanine aminotransferase (ALT), aspartate aminotransferase (AST), alkaline phosphatase (ALP), gammaglutamyltransferase (GGT) and total protein (TP). For histopathology, fresh liver samples were immediately placed in 100% formaldehyde solution and assayed.

Enzyme assays

The determination of aspartate aminotransferase (AST) in the serum samples were performed by the method of Reitman & Frankel (1957) at 37°C using the Randox kit by measuring the amount of oxaloacetate hydrazone formed in the presence of L-aspartate, α -oxoglutarate and 2, 4-dinitrophenyl hydrazine reported by Ibekwe *et al.*, (2007). For Alanine aminotransferase (ALT), L-alanine replaced L-aspartate. The determination of activity used the Diagnosticum Rt. Kit by monitoring the amount of inorganic phosphate released from p-nitrophenyl phosphate following the procedure of Haussament (1977) and was assayed according to such procedure (method). Gammaglutamyltransferase (GGT) and total protein (TP) was assayed according to the method of calorimetry.

STATISTICAL ANALYSIS

All data were expressed as mean \pm SEM and statistically analyzed with the analysis of variance (ANOVA) at 95% confidence level using IBM SPSS statistics software latest version. A p value of ≤ 0.05 was considered statistically significant.

RESULTS

The results obtained for the serum enzyme levels of AST, ALT, ALP, GGT and TP are shown in figures 1 – 5. Liver function was assessed. Result of biochemical estimations was reported as shown below, where the determination of the effect of CCl₄ and *Moringa oleifera* extract on ALT, AST, ALP, GGT, and TP are seen in the figures below

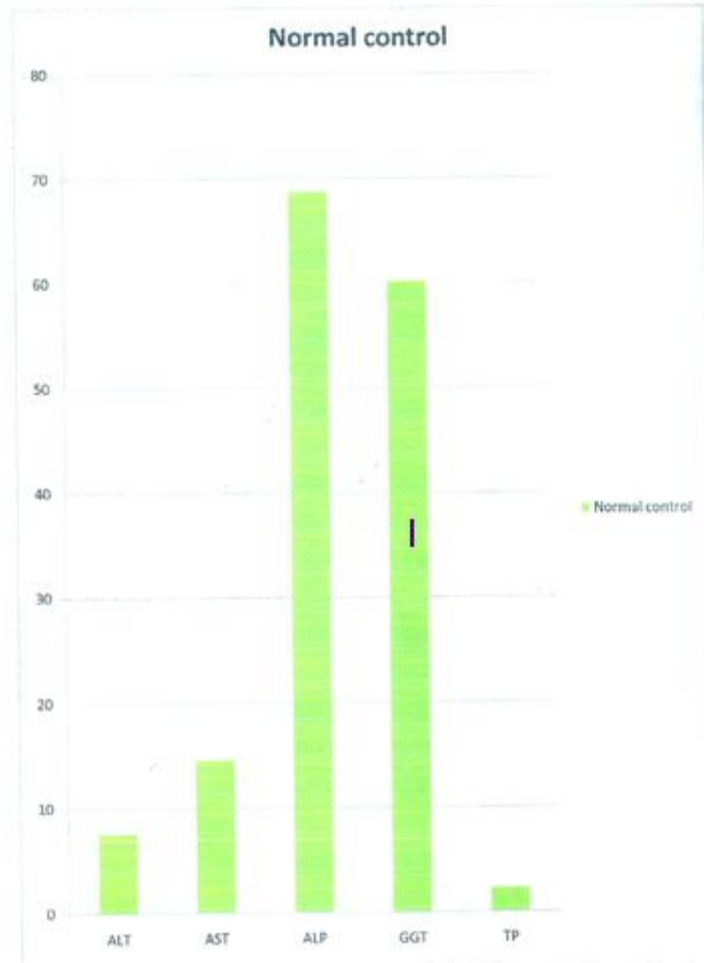


Figure 1: Showing the normal (control) group.

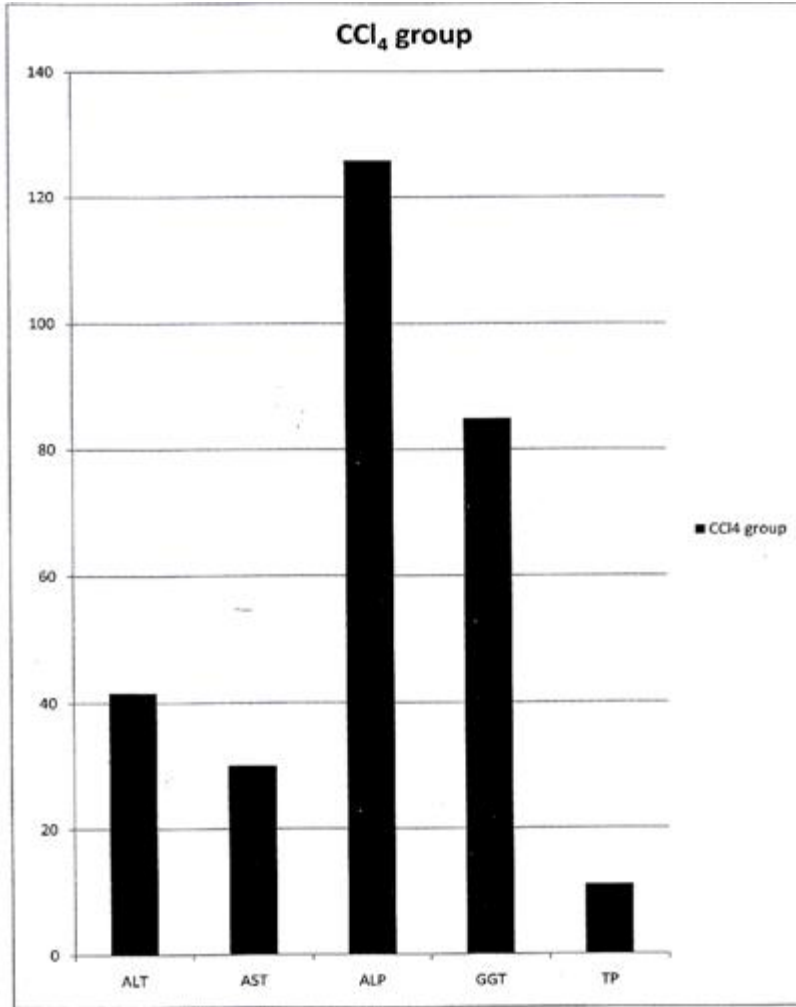


Figure 2: Showing the effect of extract of *Moringa oleifera* leaf on the serum CCl₄ level of wistar rat.

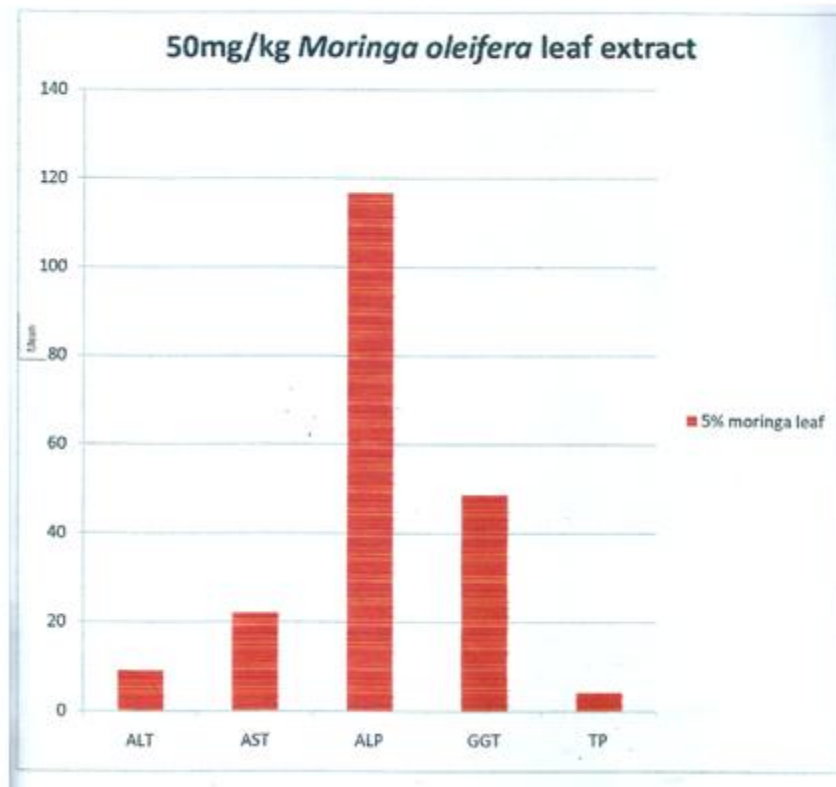


Figure 3: Showing the effect of extract of 50mg/kg *Moringa oleifera* leaf on the serum level of wistar rat.

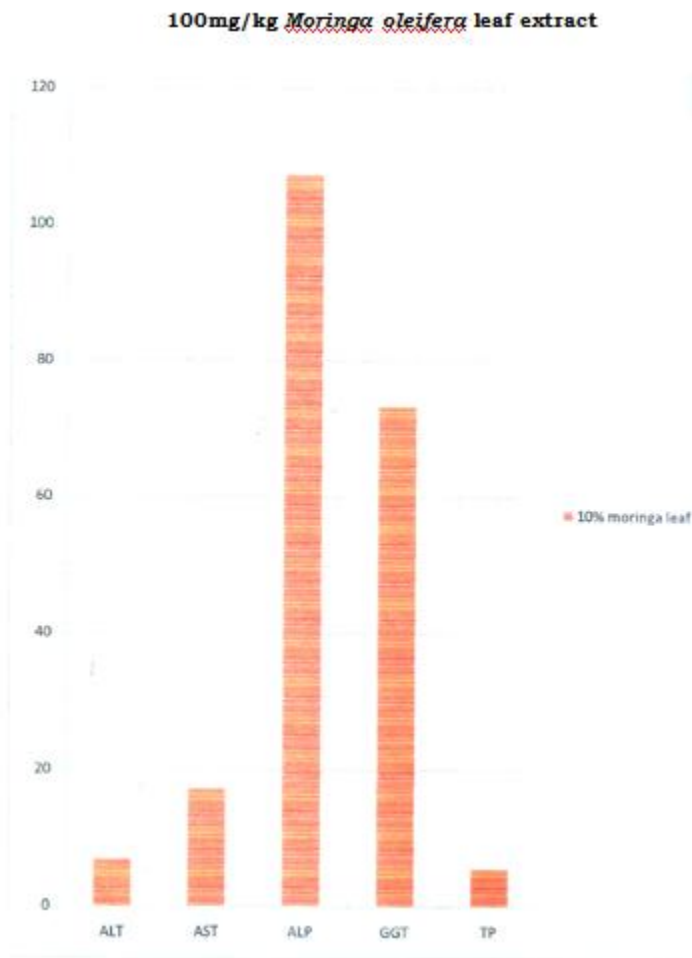


Figure 4: Showing the effect of extract of 100mg/kg *Moringa oleifera* leaf on the serum level of wistar rat.

150mg/kg *Moringa oleifera* leaf extract.

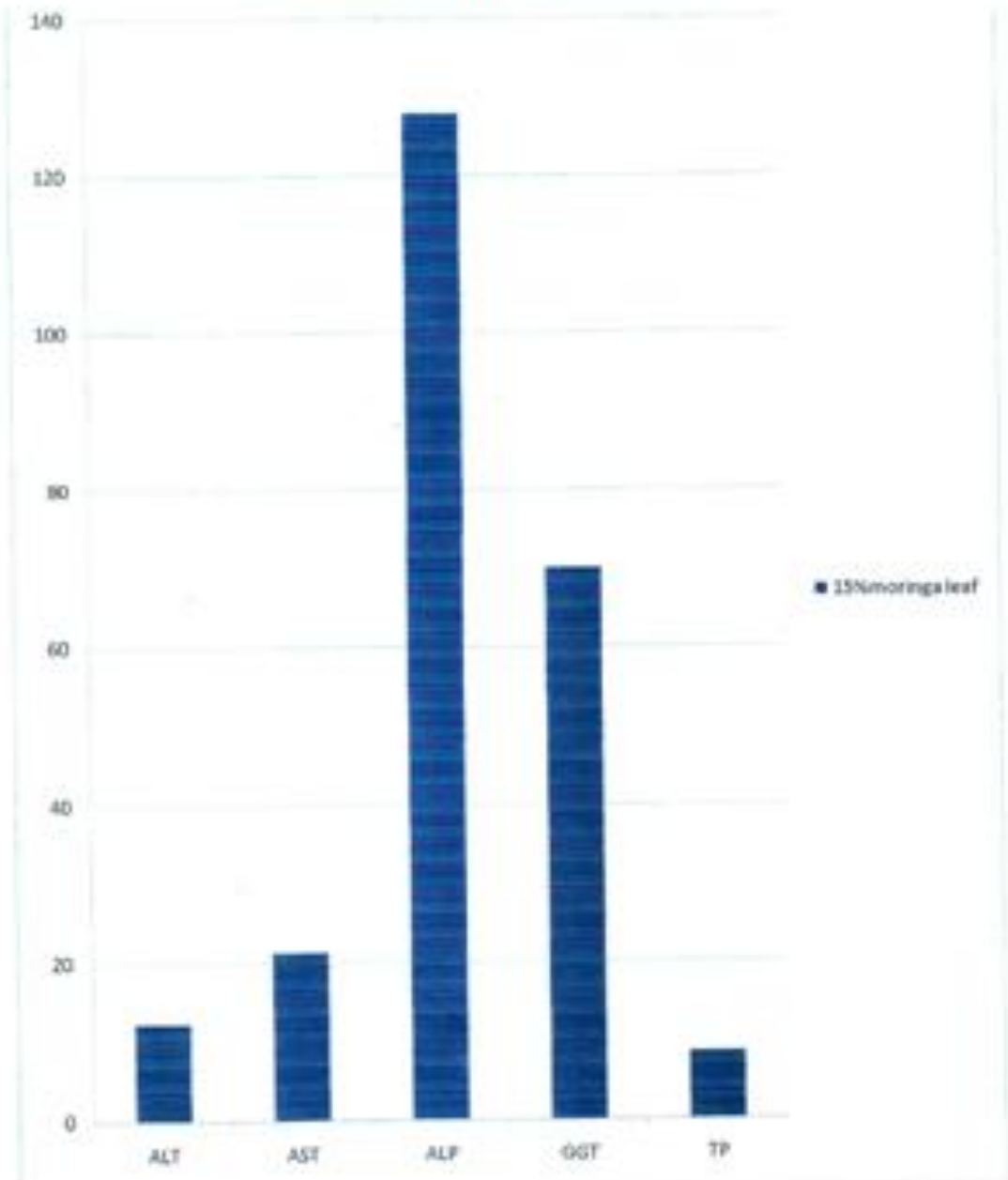


Figure 5: Showing the effect of extract of 150mg/kg *Moringa oleifera* leaf on the serum level of wistar rat.

UNDER PEER REVIEW

CONTROL

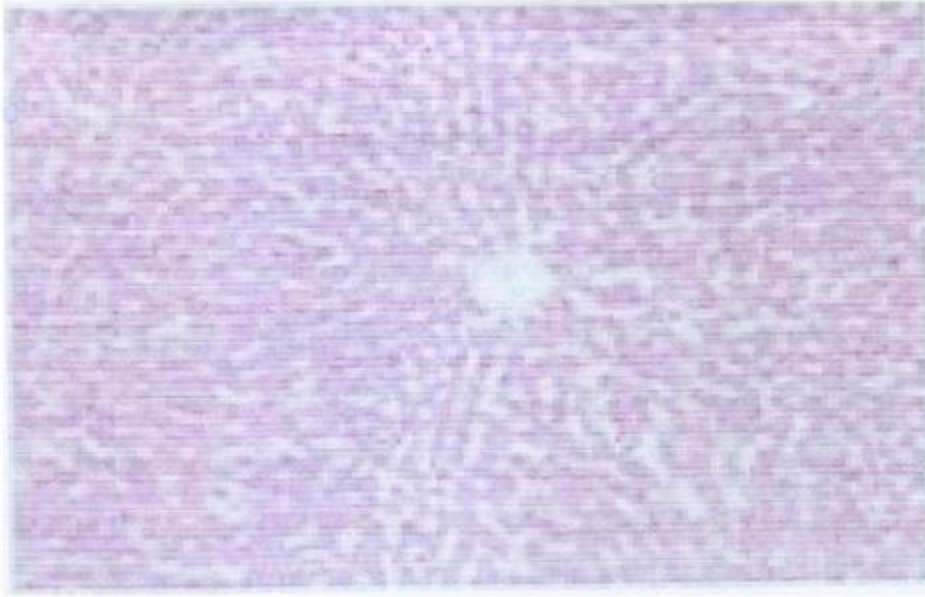


Plate 1: Picture showing normal liver architecture

UNDER PEER REVIEW

CONTROL

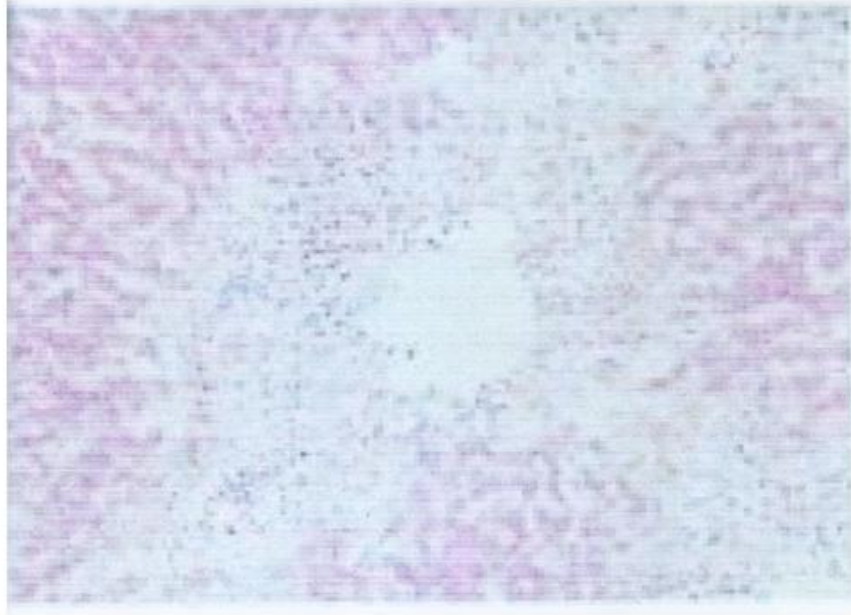


Plate 2: Picture showing the liver architecture of rat treated with CCl_4 . Liver necrosis with vacuolated cytoplasm seen.

UNDER PEER REVIEW

Discussion

CCl_4 is one of the most commonly used hepatotoxins in experimental studies to investigate the liver injury that is associated with oxidative stress and free radicals. This is because the metabolism of CCl_4 begins with the formation of trichloromethyl free radical (CCl_3) which was formed by the action of the mixed function of the cytochrome P450 oxygenase system. This free radical reacts very rapidly with oxygen to yield a highly reactive trichloromethyl peroxy radical (CCl_3OO). Both radicals are capable of binding to proteins or lipids, thus initiating tissue lipids peroxidation, inflammation, hepato-toxication and malonyldialdehyde (MDA) accumulation.

The result of the effect of aqueous extract of *Moringa oleifera* leaves on CCl_4 -induced liver damage on albino rats reveals a significant reduction ($p \leq 0.05$) in the ALT level in rats treated with various concentration of *Moringa* leaves: A dose dependent significant reduction ($p \leq 0.05$) in the AST level occurred at 100mg/kg concentration ($17.3 \pm 1.20\text{u/L}$) compared to the CCl_4 group ($30.0 \pm 3.00\text{u/L}$) and no significant difference occurred at 50mg/kg ($22.0 \pm 1.52\text{u/L}$) and 150mg/kg ($21.3 \pm 3.38\text{u/L}$) when compared to CCl_4 treated group and normal control. ALP showed no significant reduction ($p \leq 0.05$) in comparison to the CCl_4 group though in comparison with the normal control, there was a significant change in comparison to CCl_4 - treated group. GGT showed no significant difference ($p \leq 0.05$) when compared to the normal control and CCl_4 treated group. For TP, significant changes ($p \leq 0.05$) occurred in comparison to the CCl_4 treated group.

Conclusion

The study revealed that *Moringa oleifera* leaves can be of great value in the management of liver disease, at least that caused by CCl_4 damage in wistar rats.

COMPETING INTERESTS DISCLAIMER:

Authors have declared that no competing interests exist. The products used for this research are commonly and predominantly use products in our area of research and country. There is absolutely no conflict of interest between the authors and producers of the products because we do not intend to use these products as an avenue for any litigation but for the advancement of knowledge. Also, the research was not funded by the producing company rather it was funded by personal efforts of the authors.

REFERENCES

- Ahsan, R., Islam, M., Bulbul, J. I., Musaddik A., & Haque, E. (2009). Hepatoprotective activity of methanol extract of some medicinal plants against CCl₄-induced hepatotoxicity in rats. *European Journal of Scientific Research*, 37 (2): 302 – 310.
- Antioxidant and antidiabetic potentials of aqueous extract of Christmas bush (*Alchornea cordifolia*) leaf in carbon tetrachloride (CCl₄)-induced hepatic damage in wistar rats.
- Baker, F. J. & Silverton, R. E. (1985). *Introduction to Medical Laboratory Techniques*, 6th edition, Butterworths, London. Pp 320 – 330.
- Chatterjee, T. K. (2000). Medicinal plants with hepatoprotective properties. In:herbal options, 3rd edition. Calcuta books and allied publishers limited, pp. 135 – 137.
- Chattopadhyay, R.R (2003). Possible mechanism of hepatoprotective activity of *Adadirachta indica* leaf extract, part 11. *Journal of Ethnopharmacology*, 89 (2 – 3): 217 – 219.
- Cohosh, T., Maitya, T.K., Das, M., Bose, A. & Dash, D.K. (2007). *In vitro* antioxidant and hepatoprotective activity of ethanol of Bacopamonnierilinn, aerial parts. *Iranian Journal of Pharmacology and Therapeutics*, 6:7-85.
- Haussament, T. U. (1977). Quantitative determination of serum alkaline phosphatase. *Clinical Chemistry Acta*, 35:271 – 273.
- Ibekwe, S. E., Uwakwe, A. A., Monanu, M. O. (2007). *In vivo* effects of sodium benzoate on plasma aspartate aminotransferase and alkaline phosphatase of wistar albino rats. *Scientific Research & Essay*, 2(1): 010 – 012.
- Oyagbemi, A. A. & Odetola, A. A. (2011). Hepatoprotective effects of ethanolic extract of *Cnidioscolusa conitifolius* on paracetamol-induced hepatic damage in rats. *Pakistan Journal of Biological Sciences*, 13 (4): 164 – 169.
- Prakash, T., Faladu, S. D., Sharma, U. R., Surendra, V., Goli, D., Stamina, P., & Kotresha, D. (2008). Hepatoprotective activity of leaves of *Rhododendron arboretum* in CCl₄-induced hepatotoxicity in rats. *Journal of medicinal plants research*, 2(11): 315 – 320.
- Rao, G. M. M., Rao, C. V., Pushpaaangandan, P., & Shirwaikkar, A. (2005). Hepatoprotective effects of rubiadin, a major constituent of *Rubiao ehocordofolialinn*. *Journal of Ethnopharmacology* 103(3): 483 – 490.
- Rao, K. S., Mishra, S. H. (1998). Anti-inflammatory and Hepato-protective activities of fruits of *Moringa ptergosperma gaertn*. *Indian journal of Natural Products*, 14:3.

Reitman, S. & Frankel, S. (1957). Colorimetric methods for aspartate and alanine aminotransferases. *American Journal of Clinical Pathology*, 28: 55 – 60.

Roberts, J. E. & Tyler, V. E. (1999). Tyler's herbs of choice. The therapeutic use of phytomedicinals. The Haworth Herbal Press. New York pp. 11.

Trivedi, N. & Rawal, U. M. (2000). Hepatoprotective and toxicology evaluation of *Andrographis paniculata* on severe liver damage. *Indian Journal of Pharmacology*, 32:288 – 293.

Wargovich, M. J., Woods, C., Holis, D. M., & Zancler, M. E. (2001). Herbs, cancer prevention and health. *Journal of Nutrition*, 131(11): 30345 – 30365.

UNDER PEER REVIEW