

## Case study

### CASE REPORT: SECOND TRIMESTER INVASIVE PLACENTA –A DIAGNOSTIC DILEMMA

#### ABSTRACT:

**Introduction:** Placenta Percreta is an extremely rare but life threatening complication which involves placental penetration through the uterine serosa and into adjacent organs in few cases. Very few cases have been noted in second trimester and management is tricky.

**Case presentation:** In our present case we had a 30 year old, G4P2L2A1 with prev 2 lscs, present with bleeding on and off since 3 months, post spontaneous abortion at 13+ weeks followed by check curettage in which minimal tissue was obtained. Her NT-NB scan revealed a low lying placenta. On examination she was found to have a boggy mass per vagina and a BHCG which was slightly above normal. On MRI evaluation she was found to have a mass occupying the lower uterine cavity invading the myometrium with significant vascularity, reported as invasive mole provisionally. After correction of anemia she was taken up for laparotomy and hysterectomy after counselling the patient in detail about potential risk of torrential bleeding and uterine rupture considering she had completed family. Intra-op a ballooned out lower uterine segment with a vascular mass was noted which was partially invading the bladder wall. The bladder rent was repaired in 2 layers. 1 pint PRBC was transfused intra op. Patient had an uneventful post op period. Her final HPE report was placenta percreta with few viable chorionic tissue

**Discussion:** PAS is associated with high fetal and maternal mortality and morbidity and presentation can be unusual. Patient antenatal history of prev 2 lscs and low lying placenta in index pregnancy and a failed curettage gave us important clues to her diagnoses along with the MRI findings.

**Conclusion:** To conclude careful evaluation and planning is vital for patient management.

#### INTRODUCTION:

Placenta percreta in early pregnancy is an extremely rare but life-threatening complication, for which very few cases have been reported in the literature worldwide. Abnormal placentation during pregnancy is categorized into accreta, increta, and percreta in the order of increasing severity and increasing invasion of placental villi through the uterine wall. Accreta involves penetration of placental tissue beyond the endometrial lining into the myometrium, increta is characterized by deep myometrial invasion, and percreta involves placental penetration through the uterine serosa and into adjacent organs in some cases.

Placenta percreta accounts to 5-7% of adherent placenta.<sup>1</sup> Placenta percreta is the most severe form of placentation defect which can be lethal problem when encountered during a dilatation and evacuation or curettage performed for the

termination of first or second trimester pregnancy loss, leading to extensive haemorrhage within minutes of initiating the procedure. Individuals with risk factors for morbidly adherent placenta at term should be investigated early in pregnancy. Antenatal diagnosis is required to plan delivery and minimize complications. Ultrasound or Magnetic Resonance Imaging (MRI) is useful in establishing antenatal diagnosis. Here we present a case of placenta percreta presenting to us with on and off bleeding **3 months** post abortion which was managed appropriately with good outcome.

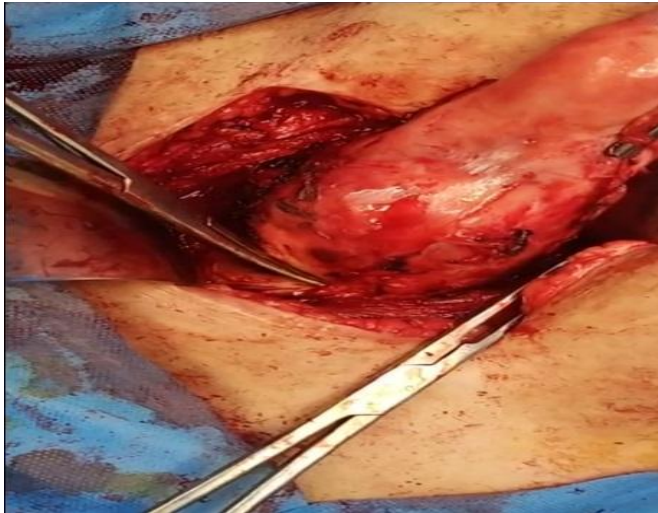
## CASE PRESENTATION

Case : A 30 years old female patient ,resident of Raichur, a case of Gravida 4 para 2 living 2 abortion 1 with 13+ weeks gestation was referred to us with suspicion of gestational trophoblastic neoplasia for further management. She gave us a history of spontaneous abortion at home 3 months back, followed by attempted check curettage at local hospital along with sterilisation done in the same sitting. However according to records, minimal tissue was obtained on curettage and misoprostol was inserted for retained products and discharged. She however continued to bleed on and off after that and on evaluation was found to have a large boggy mass per vagina when examined by local doctor 2 months later. Her ultrasound pelvis revealed a large lobulated lesion of 9.3 x 6.9 cmx 2.6 cm-260cc with multiple cystic areas and high internal vascularity in the lower uterine cavity with uterus measuring 12.9 x 4.23x 6.85cm. She was transfused 2 pint PRBC in view of low haemoglobin of 9 and referred here for further management. Further plain MRI done revealed an ill defined lesion 8.6 x 8.1x 9.2 cm in lower endometrial canal with hemorrhagic areas within. The possible diagnosis was reported as retained products of conception. Serum BHCG was done weekly which revealed serially decreasing values of 61,22.81 and 17 respectively.

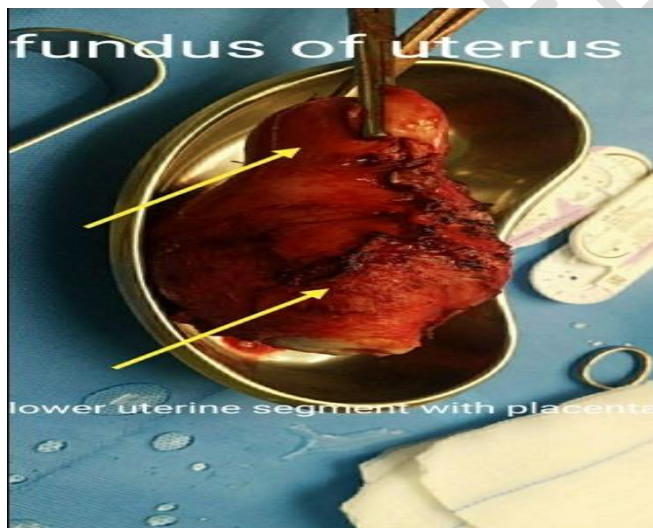
On further evaluation she gave us a obstetric history of prev 2 lscs(8 & 4 years) and a spontaneous abortion at 4 months prior to the present pregnancy. In the present pregnancy she gave a history of on and off bleeding since the time of conception with her NT-NB scan showing a single live intrauterine of 13+5 weeks gestation and low lying placenta. No other abnormality was otherwise mentioned. On speculum examination the cervix was found to be to be normal and on per vaginal examination a large boggy mass of 14 weeks size occupying all fornices was felt which was thought to be consistent with uterus and parametrium was found to be free.

On admission, Bhcg was repeated in our lab which was found to be 16. MRI with contrast revealed a large well defined uterine lesion of 8.5 x 7.8 x7.6 cm occupying mid and lower uterine cavity which was causing thinning of uterine wall and possibly adherent/infiltrating the wall with possible suspicion of trophoblastic tumor was reported. She was posted for laparotomy and hysterectomy with a suspicion of GTN /adherent placenta.

Intra op we found the fundus of uterus normal and the lower segment ballooned out with tumour which was very vascular on appearance with bladder completely adherent to the lower segment .We infiltrated the uterus with dilute vasopressin to achieve hemostasis and hysterectomy was carried out. During dissection of bladder adhesions, we noted a small rent of 2 cm in the bladder which was the region of invasion of placenta to bladder which was then repaired in 2 layers. The patient was transfused one pint PRBC intra op with estimated blood loss of approximately 700 ml. She recovered well in post op period and was discharged in 3 days in stable condition.



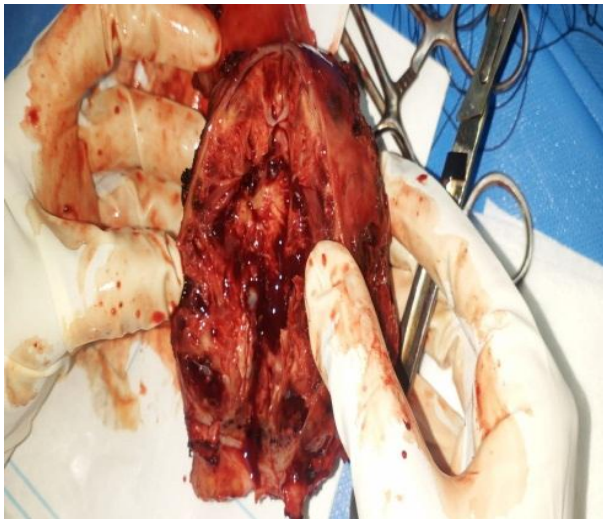
**Figure 1-intra op finding showing ballooned out lower segment**



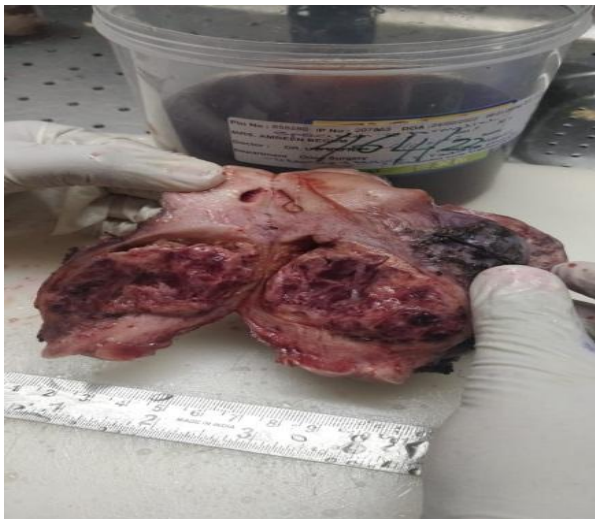**Figure 2-gross specimen**

Her HPE report on cut section of LUS revealed a polypoidal growth of 8 x 7 cm which was a lesion with extensive necrosis and haemorrhage and degenerated chorionic villi with few viable chorionic villi. Grossly the tumor involves the serosa. No hyperplastic trophoblastic proliferation seen. Thrombosed vessels and focally intermediate trophoblasts around vessels noted with necrosis seen extending upto

serosa at the isthmus. No decidualisation of endometrial stroma noted. Features were suggestive of adherent/invasive placenta-placenta percreta.



**Figure 3-cut section of lower uterine segment showing invasion**



**Figure 4-pathology specimen on cut section**

## **DISCUSSION:**

Placenta percreta is defined as an abnormal adherence of placenta to the uterine wall secondary to total or partial absence of the decidua basalis characterized by chorionic villi penetrating through the myometrium into the uterine serosa and may infiltrate the surrounding organs such as urinary bladder and bowel. Separation of such a placenta from the myometrium can result in fatal hemorrhage as trophoblastic tissue is very vascular. The incidence of accreta has increased from 1 in 30,000 to 1 in 2500 in the past 50 years, which is attributable to increase in the rate of cesarean deliveries<sup>2</sup>

The risk factors for defective placentation include previous uterine surgeries like cesarean section <sup>3</sup>, myomectomy and curettages, endometritis or pyometra, abnormal placental localization, and submucosal fibroids. In majority of the studies, predisposing factors for abnormal placentation in early pregnancy were related to thinning of the endometrium at the site of uterine scars from previous cesarean sections. Clark and colleagues studied the relationship between previous cesarean section and placental abnormalities and noted that risk of placental disorders including placenta previa increases with the number of previous cesarean sections <sup>4</sup>. Esmans et al. from Belgium reported a case of rupture of an unscarred uterus from placenta percreta in a woman with a history of manual extraction of placenta in previous pregnancy <sup>5</sup>.

Placenta accreta has been reported more commonly in early pregnancy as compared to percreta. They reviewed 7 cases of placenta accreta encountered during D and E in second trimester, all of which required hysterectomy <sup>6</sup>. We found 4 cases of early placenta percreta reported from Japan, Germany, Greece, and France. Komiya et al. from Japan described a case of incomplete abortion at 21 weeks, taken for curettage which resulted in profuse vaginal bleeding and hemorrhagic shock <sup>7</sup>. The patient received vasopressin, dobutamine, norepinephrine to maintain cardiocirculatory function, also a large amount of i.v fluids, packed cells, and finally a hysterectomy. Höpker et al. from Germany reported a similar presentation at 10 weeks gestation in a patient who was suspected to have molar pregnancy on sonogram and thus received CT, MRI as part of the work-up, all of these showed trophoblastic infiltration through the myometrium into the serosa <sup>8</sup>. A D and C was undertaken for suspected molar, which resulted in severe hemorrhage, and the patient needed hysterectomy despite uterine artery ligation. Pathology revealed placenta percreta, without any evidence of hydatiform mole. Papadakis and Christodoulou from Greece described another early placenta percreta that went unrecognized and required hysterectomy after a curettage resulted in heavy bleeding <sup>9</sup>. Also, Pont et al. from France noted a case of acute abdomen and hemoperitoneum at 13 weeks gestation <sup>10</sup>. Patient underwent laparotomy which diagnosed the placenta percreta and a hysterectomy was performed. All these cases describe unrecognized first or second trimester placenta percreta that led to extensive blood loss, lengthy operations, and caused considerable maternal morbidity.

Spontaneous rupture of uterus in early pregnancy is another lethal complication of early placenta percreta leading to significant hemoperitoneum and shock, thus necessitating hysterectomy. A few such cases of spontaneous rupture of uterus due to placenta percreta have been reported in countries other than USA, like Japan, Turkey, Mexico, and Germany <sup>11-15</sup>. All these patients underwent hysterectomy. This catastrophic complication from early percreta occurs due to thinning of the myometrium caused by invasion of the placental villi into the myometrium, at the site of placental implantation (particularly at previous scar site) leading to rupture of the uterus.

In this era of increasing cesarean deliveries, emphasis should be made on correct prenatal diagnosis of implantation defect, to prevent maternal morbidity in face of an

incomplete abortion. Some of the imaging tools recommended in the evaluation of placental invasion include—Doppler Sonography, gray-scale sonography, and magnetic resonance imaging (MRI) <sup>16</sup>. They identify thinned decidual endometrium, thinned myometrium, and placental extension into the myometrium. The diagnostic sensitivity and specificity approaches 85 to 90 percent with experienced sonographers. MRI can be used if sonogram findings are uncertain. Signs such as uterine bulging into the bladder, heterogeneous signal intensity within the placenta, and the presence of intra placental bands may predict accreta. Cystoscopy can be used to detect bladder involvement where placenta percreta is strongly suspected.

After survey of the literature, all of the cases presenting with defective placentation were treated with hysterectomy. Tocce et al. recommended performing a scheduled hysterectomy for second trimester abortion in a patient with placenta accrete <sup>17</sup>. Such a plan of care is possible when a diagnosis of placenta accreta or percreta is established early in the pregnancy with the use of color Doppler ultrasonography, MRI, and cystoscopy, in a setting of risk factors. Traditionally, hysterectomy has been the choice of modality, but it may be avoided by an early diagnosis of percreta. Yu et al. reviewed 31 cases of second trimester placenta accreta and employed conservative methods like uterine artery embolization and hysteroscopy with lesion resection, mostly in combination <sup>18</sup>. None of their patients needed hysterectomy. Some authors have suggested the use of methotrexate, in combination with curettage or embolization. These methods have been recommended by various authors based on their management of placenta accreta in second trimester or at full term. Same principles of diagnosis and treatment may also be employed for management of placenta percreta. Conservative treatment options although help to preserve the uterus, are not without associated risks. Help from urologists in a timely manner is recommended to avoid urinary complications. However, there is no available literature to guide the adequate diagnostic and treatment options of early placenta percreta, due to the rarity of this condition.

In our case, patient presented 3 months post her abortion with anemia which made her diagnosis even tricky. Her prior history of prev 2 lscs, low lying placenta in present pregnancy on early scan, incomplete curettage record, clinical and lab findings of S. BHCG levels and MRI findings gave us important clues to a possibility of adherent placenta though presenting 3 months post abortion. She was counselled in detail about her condition and hysterectomy seemed to be the best option for her considering the potential lethal complications and her completed family history.

## **CONCLUSION:**

Placenta percreta is a greatly feared obstetric complication. Manual separation of placenta in such a case causes life threatening intraoperative bleeding and subsequent development of DIC, acute respiratory distress syndrome, renal failure, and even death. Since it is seldom seen in early pregnancy high index of suspicion is necessary in patients with risk factors. As cesarean section rate is increasing,

modern obstetrician needs to anticipate the likelihood of an early percreta which can have varied presentations at varied time intervals. Hysterectomy seems to be the only adequate treatment available thus far particularly due to bladder involvement and safer alternatives needs to be explored further.

#### **COMPETING INTERESTS DISCLAIMER:**

Authors have declared that no competing interests exist. The products used for this research are commonly and predominantly use products in our area of research and country. There is absolutely no conflict of interest between the authors and producers of the products because we do not intend to use these products as an avenue for any litigation but for the advancement of knowledge. Also, the research was not funded by the producing company rather it was funded by personal efforts of the authors.

#### **REFERENCES:**

1. Hudon L, Belfort A, Broome R. Diagnosis and management of placenta percreta: a review. *Obstet Gynecol Surv.* 1998;53:509-17.
2. I. E. Timor-Tritsch and A. Monteagudo, "Unforeseen consequences of the increasing rate of cesarean deliveries: early placenta accreta and cesarean scar pregnancy. A review," *American Journal of Obstetrics and Gynecology*, vol. 207, no. 1, pp. 14–29, 2012. View at: [Google Scholar](#)
3. A. Wen, D. Qian, and X. Zhang, "Placenta accreta in early pregnancy: a case report and review of the literature," *Zhonghua Fu Chan Ke Za Zhi*, vol. 34, no. 10, pp. 606–608, 1999. View at: [Google Scholar](#)
4. S. L. Clark, P. P. Koonings, and J. P. Phelan, "Placenta previa/accreta and prior cesarean section," *Obstetrics and Gynecology*, vol. 66, no. 1, pp. 89–92, 1985. View at: [Google Scholar](#)
5. A. Esmans, J. Gerris, E. Corthout, P. Verdonk, and S. Declercq, "Placenta percreta causing rupture of an unscarred uterus at the end of the first trimester of pregnancy: case report," *Human Reproduction*, vol. 19, no. 10, pp. 2401–2403, 2004. View at: [Publisher Site](#) | [Google Scholar](#)
6. W. K. Rashbaum, E. J. Gates, J. Jones, B. Goldman, A. Morris, and W. D. Lyman, "Placenta accreta encountered during dilation and evacuation in the second trimester," *Obstetrics and Gynecology*, vol. 85, no. 5, pp. 701–703, 1995. View at: [Publisher Site](#) | [Google Scholar](#)

7. K. Komiya, K. Saitou, S. Inoue, T. Igarashi, Y. Hirabayashi, and N. Seo, "Massive hemorrhage associated with undiagnosed placenta percreta in a second-trimester pregnancy receiving abortion procedure," *Masui*, vol. 58, no. 8, pp. 1036–1038, 2009. View at: [Google Scholar](#)
8. M. Höpker, G. Fleckenstein, W. Heyl, B. Sattler, and G. Emons, "Placenta percreta in week 10 of pregnancy with consecutive hysterectomy," *Human Reproduction*, vol. 17, no. 3, pp. 817–820, 2002. View at: [Google Scholar](#)
9. J. C. Papadakis and N. Christodoulou, "Placenta percreta presenting in the first trimester: review of the literature," *Clinical and Experimental Obstetrics and Gynecology*, vol. 35, no. 2, pp. 98–102, 2008. View at: [Google Scholar](#)
10. M. Pont, E. Kouadio, M. P. Fernandez et al., "Placenta percreta at first trimester of pregnancy. Diagnostic and decision-making difficulties: about a case and a review of the literature," *Journal de Gynecologie Obstetrique et Biologie de la Reproduction*, vol. 39, no. 6, pp. 498–502, 2010. View at: [Publisher Site](#) | [Google Scholar](#)
11. M. C. Fleisch, J. Lux, M. Schoppe, K. Grieshaber, and M. Hampl, "Placenta percreta leading to spontaneous complete uterine rupture in the second trimester: example of a fatal complication of abnormal placentation following uterine scarring," *Gynecologic and Obstetric Investigation*, vol. 65, no. 2, pp. 81–83, 2008. View at: [Publisher Site](#) | [Google Scholar](#)
12. M. Moriya, H. Kusaka, K. Shimizu, and N. Toyoda, "Spontaneous rupture of the uterus caused by placenta percreta at 28 weeks of gestation: a case report," *Journal of Obstetrics and Gynaecology Research*, vol. 24, no. 3, pp. 211–214, 1998. View at: [Google Scholar](#)
13. T. Kinoshita, K. Ogawa, T. Yasumizu, and J. Kato, "Spontaneous rupture of the uterus due to placenta percreta at 25-weeks' gestation: a case report," *Journal of Obstetrics and Gynaecology Research*, vol. 22, no. 2, pp. 125–128, 1996. View at: [Google Scholar](#)
14. S. Topuz, "Spontaneous uterine rupture at an unusual site due to placenta percreta in a 21-week twin pregnancy with previous cesarean section," *Clinical and Experimental Obstetrics and Gynecology*, vol. 31, no. 3, pp. 239–241, 2004. View at: [Google Scholar](#)
15. S. Bernal-Martínez, H. Chávez, F. Villa, and A. Guzmán, "Uterine rupture and placenta percreta in the second trimester. Presentation of a case," *Ginecología y Obstetricia de México*, vol. 64, pp. 482–483, 1996. View at: [Google Scholar](#)

- 16.A. Sonin, "Nonoperative treatment of placenta percreta: value of MR imaging," *American Journal of Roentgenology*, vol. 177, no. 6, pp. 1301–1303, 2001. View at: [Google Scholar](#)
- 17.K. Tocce, V. W. Thomas, and S. Teal, "Scheduled hysterectomy for second-trimester abortion in a patient with placenta accreta," *Obstetrics and Gynecology*, vol. 113, no. 2, pp. 568–570, 2009. View at: [Publisher Site](#) | [Google Scholar](#)
- 18.M. Yu, X. Y. Liu, Q. Dai, Q. C. Cui, Z. Y. Jin, and J. H. Lang, "Diagnosis and treatment of placenta accreta in the second trimester of pregnancy," *Acta Academiae Medicinae Sinicae*, vol. 32, no. 5, pp. 501–504, 2010. View at: [Publisher Site](#) | [Google Scholar](#)

UNDER PEER REVIEW