

### **A rare case of oral field cancerization due to nutritional deficiency with an update on current concepts**

#### **Abstract:**

Squamous cell carcinoma of the oral cavity and upper aero-digestive tract has been linked to the use of tobacco products and alcohol consumption. However, a small minority of patients do not use either of these substances. Currently, the underlying etiology of head and neck cancer in such a patient population remains unclear. The most common etiological factor is related to constant long-term exposure to carcinogens. Therefore, it is rarely observed in patients who do not use tobacco or consume alcohol. To date, only a few cases of oral cancer caused due to nutritional deficiency have been reported.

In this report, we present a case of oral field cancerization in a sixty years old woman with no predisposing factors, except a history of nutritional deficiency and hematological investigations suggestive of iron, vitamin A, and vitamin B12 deficiencies.

In India, a developing country with the majority of the population with nutritional deficiency, there is a need for randomized controlled studies to determine the association between vitamin deficiency and oral malignancy. Further studies are required to determine whether micronutrient supplementation can prevent carcinogenesis.

**Keywords:** Mouth Neoplasm, Cancer of the head and neck, Nutritional Deficiency

## **Introduction:**

Oral cancer is the sixth most prevalent malignant tumor worldwide, with a particularly high prevalence in Southeast Asia (64.2 %), Europe (17.4 %), and North America (7.6%) (1). The oral cavity is one of the most potential sites for the development of malignancies because it comes into direct contact with many carcinogens (2).

Oral cancer exclusively includes a subgroup of neoplasms arising in the buccal mucosa, anterior two-thirds of the tongue, lips, alveolus, hard and soft palate, mucogingiva, and the floor of the mouth (3). Oral squamous cell carcinoma (OSCC) accounts for more than 90 percent of all oral cancers, with men having a five times higher prevalence than women (4).

Field cancerization, also called as *field effect*, is a well-known process of transforming an existing premalignant lesion into a malignancy (4). Oral field cancerization means that oral cancer does not develop as a single cellular phenomenon, but rather as an anaplastic tendency involving many cells at once, resulting in a multifocal development process of cancer at different rates across the entire field in response to a carcinogen such as tobacco (5). This definition is frequently used to describe the development of abnormal tissues around a tumorigenic area, resulting in oral multifocal cancer at separate sites that eventually coalesce to form atypical areas (6).

Tobacco and alcohol consumption are key risk factors for oral cancer; however, nutritional deficiencies can also cause it. Genetic factors, socioeconomic status, poor oral health, and a poor diet are other well-known factors (7).

Nutritional factors are responsible for approximately 30 per cent of malignancies, making nutrients secondary only to tobacco as a probable cause of cancer. Prolonged exposure to carcinogens changes the state of the epithelium, rendering it vulnerable to the development of multifocal carcinoma (8).

This report presents a case of oral field cancerization in a 60 year old elderly woman with no predisposing factors, except a history of chronic iron, vitamin A, and vitamin B12 deficiencies.

**Case report:**

A 60 years old female from the rural area of Belagavi District presented with a complaint of multiple ulcers in her mouth for the past six months. The patient had a history of non-healing ulcers in the right buccal mucosa, left buccal mucosa, and the lower labial vestibule. Ulcers gradually increased in size to their present size. The patient had a history of pain and burning sensations associated with sour taste and fetid odor. She also reported a gradual reduction in weight loss (5 kg), with decreased appetite and malaise over the previous six months. The patient was easily fatigued during daily activities and reported signs of dyspnea. There was no history of recurrent fever, cough, or diarrhea.

Personal history revealed no consumption of areca nut, tobacco, alcohol, hot beverages, corrosive ingestion in the past, or excessive consumption of spicy foods. The patient's family had no history of malignancy.

The patient had a history of recurrent trauma from cheek bites on left side and bleeding gums. The patient consulted a local doctor who prescribed vitamin B complex capsules for 30 days. The patient was also prescribed folic acid, and vitamin A and vitcofol (suspension of folic

acid, cyanocobalamine and ferrous fumarate) injections were administered intravenously multiple times over a period of one month, at a private hospital.

The patient had a history of self-exfoliation of the teeth (41, 31, and 32) three months prior, after which ulcerative lesions in the lower anterior region proliferated in size.

On general physical examination, the patient appeared malnourished, with an asthenic physique and body mass index of 17.6. She had evident pallor in the palpebral conjunctiva, chelosis, bald tongue, and koilonychias, suggestive of vitamin B and iron deficiencies. The lips were dry and bleeding (Figure 1). Lymph node: bilateral single sub-mandibular lymph node of size 1.5 cm was palpable on both sides, which was non tender, fixed and hard in consistency. No evidence of cervical lymphadenopathy or hepatosplenomegaly was found.

Intraoral examination revealed generalized gingival inflammation and gingival recession. Root stumps in relation to 13, 36, 47, and deep caries in relation to 37. Grade I mobility in 33, 43, and partially edentulous with respect to 31, 32, 41, and 46.

Lesion 1 (Figure 2): An ulceroproliferative growth, approximately 3.5 x 2.5 cm in size, extending from the mesial aspect of 43 to the mesial aspect of 34 and labio-lingually from the labial vestibule to lingual vestibule corresponding to 33, 32, 31, 41, and 42 was present in the lower anterior region. Irregularly shaped, covered with whitish-yellow necrotic slough was noted. On palpation, the lesion was tender, firm, indurated, and was fixed to the underlying tissue. Bleeding was noted upon palpation. No associated paraesthesia was reported.

Lesion 2 (Figure 3): An ulcerative lesion, approximately 2.5 x 1.5 cm in size, extending along the line of occlusion from mesial aspect of 26 to the distal aspect of 27 was noted on the right buccal mucosa. The ulcer was irregularly shaped and was surrounded by an erythematous area.

On palpation, the lesion was tender, firm, indurated at the margins, and was fixed to the underlying tissue.

Lesion 3 (Figure 4): A small, non-scrapable, whitish patch was noted on the left buccal mucosa along the occlusion line, corresponding to a distal aspect of 37. On palpation, the lesion was non-tender, non-indurated and not fixed to the underlying tissue.

Hematological investigation showed raised ESR and low Hemoglobin of 7.8 g/dl with low vitamin B12 (170 pg/mL), vitamin A (12 mcg/dL) and serum Iron levels (48 mcg/dL). Peripheral smear and blood reports showed vitamin B12 deficiency anemia with anisocytosis (macrocytic hypochromic type).

Subsequently, an orthopantomogram (OPG) was advised to check for hard tissue involvement in the lower anterior region, which revealed a diffuse, poorly defined radiolucency with ragged borders in relation to 34–43, extending laterally on either side and involving the surrounding alveolar bone (Figure 1).

Considering the clinical, hematological, and radiographic findings, the patient was provisionally diagnosed with carcinoma of the lower anterior alveolus, carcinoma of the right buccal mucosa, and frictional keratosis in the left buccal mucosa, secondary to nutritional deficiency and chronic trauma.

Multiple intralesional biopsies were performed at various sites and the obtained samples were sent for histopathological evaluation after blood investigations.

Histopathological examination of the posterior right buccal mucosa revealed severely dysplastic epithelial drop-shaped rete pegs, loss of basal cell polarity and architecture, prominent nucleoli with evidence of individual cell keratinization, and abundant keratin pearl formation. These

features were suggestive of well-differentiated squamous cell carcinoma. Histopathological sections of the anterior right buccal mucosa showed densely inflamed connective tissue with chronic inflammatory cells such as lymphocytes and plasma cells, suggesting severe dysplasia. Histopathological sections of the lower anterior alveolus showed discontinuous epithelium proliferating into the underlying sparse connective tissue in the form of islands, suggesting an early invasive squamous cell carcinoma.

Therefore, correlating the clinical, hematological, radiographic, and histopathological findings, this case was considered to be a case of oral field cancerization.

### **Discussion:**

Oral field cancerization is a rare entity in people without any habit of tobacco consumption because carcinogenesis requires constant exposure to carcinogens over a long latent period to manifest as multifocal carcinoma.

Oral carcinoma requires exposure to tobacco, alcohol, corrosives, fungal contaminants, and acid reflux, which cause dysplastic changes in the epithelium, leading to malignant changes. However, this was not true in the present case of oral field cancerization. The precursors of malignant changes in this patient may have been nutritional deficiencies (9).

Tobacco and alcohol use accounts for a high proportion of oral and pharyngeal cancer cases worldwide. According to an estimate, these two factors are responsible for three-quarters of all malignancies. Nevertheless, nutrition accounts for 35% of all cancer cases (10).

Various nutrients and vitamins in the diet have specific mechanisms of action that aid in cancer prevention. Dietary components with protective effects have different mechanisms that complement and overlap with antioxidant, anti-inflammatory, anti-angiogenic, and anti-

proliferative effects. Vitamin A, B, C, B-carotene, and iron are all found in fruits and vegetables and are thought to play a major role in cancer aetiology and prevention (11).

A large population-based, case-control, questionnaire study by Paluszczak *et al.* showed that nutrients from fruits and vegetables have a protective mechanism against oral cancer (12).

A study in Sweden found a link between diet and the etiology of Plummer-Vinson (also called Patterson-Kelly) syndrome and pharyngeal cancer in women (13).

Medrano *et al.* found that women with hypo-pharyngeal cancer had symptoms, such as dysphagia and anemia, which were suggestive of iron deficiencies exacerbated by a poor diet (14).

Bergen *et al.* recently reported the potential protective effects of vitamins against carcinogenesis. Vitamin A plays a key role in cell differentiation, and which explains why vitamin A deficiency can lead to cellular metaplasia. Vitamin A and retinoids, which are derivatives of vitamin A, have been postulated to affect tumor latency by retarding tumor growth (15).

Despite the methodological difficulties in studying diet, nutrition, and oral cancer, epidemiological evidence has demonstrated that nutrition plays an important role in the etiology of oral cancers (16).

To our knowledge, only a few cases of oral field cancerization in patients with nutritional deficits have been reported in the literature. This case is unique as it presents an oral field of cancerization in an elderly woman with no predisposing factors, except for a history suggestive of nutritional deficiencies.

In our case, the poor health of the patient, poor socio economic, and late diagnosis led to a poor prognosis.

### **Update:**

The main etiological factors are tobacco and alcohol consumption, although diet is currently considered an important determinant for the development of oral cancer. Several dietary components have particular mechanisms of action, contributing to an increased risk of development and protection against cancer, growth, and spread. A diet inclusive of fruits, vegetables, curcumin, and green tea can reduce the risk of oral cancer, whereas a pro-inflammatory diet, high in red meat and fried foods, can increase the risk of developing cancer (17).

A pro-inflammatory diet induces constant inflammation, which promotes cancer growth in various parts of the body, including cancers of the oral cavity (17). According to recent studies, dietary inflammation index (DII) relates diet and serum C-reactive protein levels to the degree of inflammation (18). High dietary inflammation index values indicate pro-inflammatory diets, whereas low dietary inflammation index values would indicate anti-inflammatory diets and a consequent reduced risk of developing oral malignant changes (19).

A pro-inflammatory diet can increase the risk of oral cancer through the generation of biomarkers, such as homocysteine, creatine reactive protein (CRP) and interleukin (IL-6). As a result, the inflammatory process is responsible for supplying bioactive molecules to the tumor environment. In addition, cytokines and other inflammatory biomarkers can activate transcription factors, which may interfere with the initiation and promotion of cancer. Therefore, modification of the dysbiotic oral microbiota has been proposed as another way to establish a link with head and neck cancer (19).

Among the pro-inflammatory factors, high consumption of iron has been linked to oral carcinoma, which is similar to lung, prostate, and breast cancers. This could be explained by role of iron in basic cellular functions, such as cell metabolism, growth, and proliferation, which can result in the synthesis of nitrogen compounds and catalyse the formation of free radicals, which can cause cell damage (20).

Oral cancer has also been linked to Omega 6 acid. The mechanism of action is dependent on the metabolism of Omega 6 acid generating arachidonic acid that produces proinflammatory prostaglandins and lipoxins by oxidation. The balance between Omega 3 and Omega 6 acids can help regulate the action of carcinogenic factors and lower the risk of oral cancer (21).

Through this update, we shed light on the relationship between oral cancer and diet, and highlight which factors may be detrimental and which may be considered protective owing to their properties.

In India, a developing country with a majority of the population with nutritional deficiency, randomized controlled studies linking vitamin deficiencies with oral malignancies are lacking. This case study could serve as a springboard for conducting randomized controlled trials in developing countries, to better understand the association between vitamin deficiency and oral cancer. Further studies are required to determine whether micronutrient supplementation can prevent carcinogenesis.

### **Conclusion:**

Several epidemiological studies have associated diet with the prevention of different types of malignancies. The beneficial effects of a diet rich in vegetables and fruits are attributed to different micronutrients, such as lycopene, catechins, curcuminoids, slowly digesting starches,

minerals (selenium, zinc, and copper), carotenes, vitamins (A, B, C, and E), folate and omega 3 acids.

Research on diet and oral cancer is limited. Most published studies refer to oropharyngeal or upper aero-digestive tract cancers without making a clear distinction from oral cancer. Further studies are required to investigate the specific relationship between oral cancer and diet.

Therefore, this case report can be an impetus for conducting randomized controlled trials in developing countries to study the association between vitamin deficiency and oral carcinomas.

**Declaration of patient consent:**

The authors certify that they have obtained all appropriate patient consent forms. In the form the patient(s) has/have given his/her/their consent for his/her/their images and other clinical information to be reported in the journal. The patients understand that their names and initials will not be published and due efforts will be made to conceal their identity, but anonymity cannot be guaranteed.

**Ethical Clearance:**

Ethical clearance was obtained from the institutional ethical board.

**References:**

1. Ferlay, J.; Colombet, M.; Soerjomataram, I.; Mathers, C.; Parkin, D.M.; Piñeros, M.; Znaor, A.; Bray, F. Estimating the Global Cancer Incidence and Mortality in 2018: GLOBOCAN Sources and Methods. *Int. J. Cancer* **2019**, *144*, 1941–1953.

2. El-Naggar, A.K.; Chan, J.K.C.; Grandis, J.R.; Takata, J.; Slootweg, P.J. WHO Classification of Head and Neck Tumours, 4th ed.; IARC Publications: Lyon, France, 2017.
3. Sarode, G.; Maniyar, N.; Sarode, S.C.; Jafer, M.; Patil, S.; Awan, K.H. Epidemiologic Aspects of Oral Cancer. *Dis. Mon.* **2020**, *66*, 100988
4. Scully, C.; Bagan, J. Oral Squamous Cell Carcinoma Overview. *Oral Oncol.* **2009**, *45*, 301–308.
5. Lambert, R.; Sauvaget, C.; de Camargo Cancela, M.; Sankaranarayanan, R. Epidemiology of Cancer from the Oral Cavity and Oropharynx. *Eur. J. Gastroenterol. Hepatol.* **2011**, *23*, 633–641.
6. Johnson, N.W.; Jayasekara, P.; Amarasinghe, A.A.; Hemantha, K. Squamous Cell Carcinoma and Precursor Lesions of the Oral Cavity: Epidemiology and Aetiology. *Periodontology*
7. Conway, D.I.; Purkayastha, M.; Chestnutt, I.G. The Changing Epidemiology of Oral Cancer: Definitions, Trends, and Risk Factors. *Br. Dent. J.* **2018**, *225*, 867–873.

8. Doll, R., Peto, R. (1981). The causes of cancer: quantitative estimates of avoidable risks of cancer in the United States today. *Journal of the National Cancer Institute*, 66: 1191–1308.
9. Decker J, Goldstein JC. Risk factors in head and neck cancer. *N Engl J Med* 1982;306:1151–5.
10. Elwood JM, Pearson JC, Skippen DH, et al. Alcohol, smoking, social and occupational factors in the aetiology of cancer of the oral cavity, pharynx and larynx. *Int J Cancer* 1984;34:603–12.
11. Zain, R.B. Cultural and Dietary Risk Factors of Oral Cancer and Precancer—A Brief Overview. *Oral Oncol.* **2001**, 37, 205–210.
12. Paluszczak, J.; Krajka-Kuźniak, V.; Baer-Dubowska, W. The Effect of Dietary Polyphenols on the Epigenetic Regulation of Gene Expression in MCF7 Breast Cancer Cells. *Toxicol. Lett.* **2010**, 192, 119–125.
13. Kelly A. Spasm at the entrance of the esophagus. *J Laryngol Rhinol Otol.* 1919;34:285–289.

14. Medrano M. Dysphagia in a patient with rheumatoid arthritis and iron deficiency anemia. *MedGenMed.* 2002;**4**(3):10.
15. Cavicchia, P.P.; Steck, S.E.; Hurley, T.G.; Hussey, J.R.; Ma, Y.; Ockene, I.S.; Hébert, J.R. A New Dietary Inflammatory Index Predicts Interval Changes in Serum High-Sensitivity C-Reactive Protein. *J. Nutr.* **2009**, 139, 2365–2372.
16. Herceg, Z. Epigenetics and Cancer: Towards an Evaluation of the Impact of Environmental and Dietary Factors. *Mutagenesis* **2007**, 22, 91–103.
17. Hua, R.; Liang, G.; Yang, F. Meta-Analysis of the Association between Dietary Inflammatory Index (DII) and Upper Aerodigestive Tract Cancer Risk. *Medicine* **2020**, 99, e19879.
18. Cavicchia, P.P.; Steck, S.E.; Hurley, T.G.; Hussey, J.R.; Ma, Y.; Ockene, I.S.; Hébert, J.R. A New Dietary Inflammatory Index Predicts Interval Changes in Serum High-Sensitivity C-Reactive Protein. *J. Nutr.* **2009**, 139, 2365–2372.

19. Hsu, J.; Arcot, J.; Alice Lee, N. Nitrate and Nitrite Quantification from Cured Meat and Vegetables and their Estimated Dietary Intake in Australians. *Food Chem.* **2009**, 115, 334–339.
20. Chan, T.Y.K. Vegetable-Borne Nitrate and Nitrite and the Risk of Methaemoglobinaemia. *Toxicol. Lett.* **2011**, 200, 107–108.
21. McClain, K.M.; Bradshaw, P.T.; Khankari, N.K.; Gammon, M.D.; Olshan, A.F. Fish/Shellfish Intake and the Risk of Head and Neck Cancer. *Eur. J. Cancer Prev.* **2019**, 28, 102–108.

**Legends:**

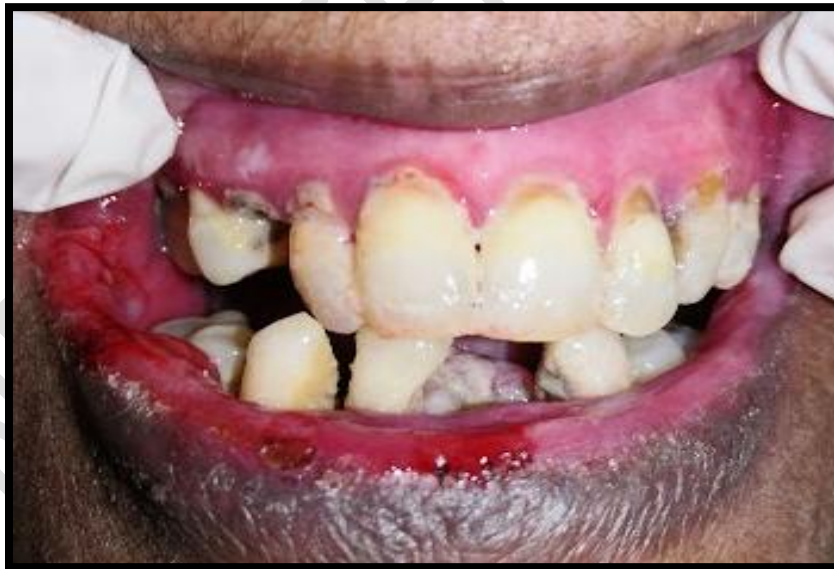**Figure 1:** Dried and bleeding lips

**Figure 2:** Ulceroproliferative growth, extending from the mesial aspect of 43 to the mesial aspect of 34 and labio-lingually from the labial vestibule to lingual vestibule corresponding to 33 – 42.

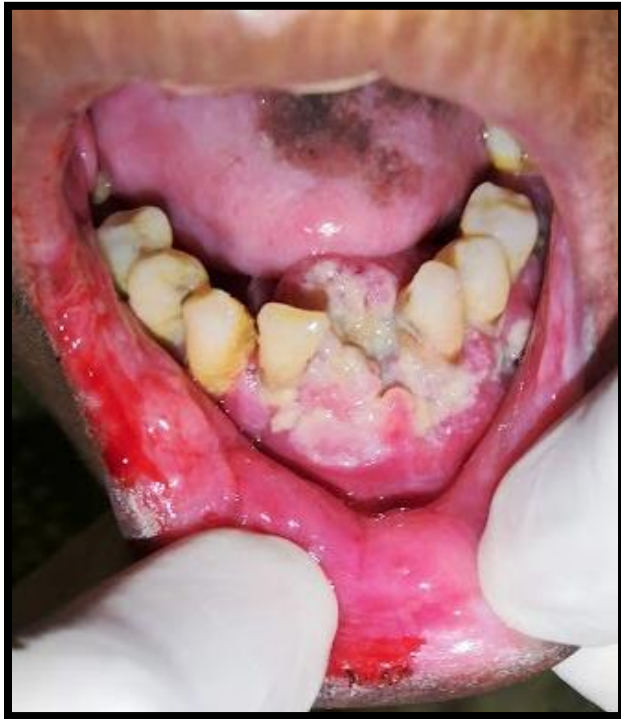**Figure 3:** An ulcerative lesion extending along the line of occlusion from the mesial aspect of 26 to the distal aspect of 27 was present on the right buccal mucosa.

**Figure 4:** Whitish, non-scrapable patch present on the left buccal mucosa along the occlusion line, corresponding to 37.

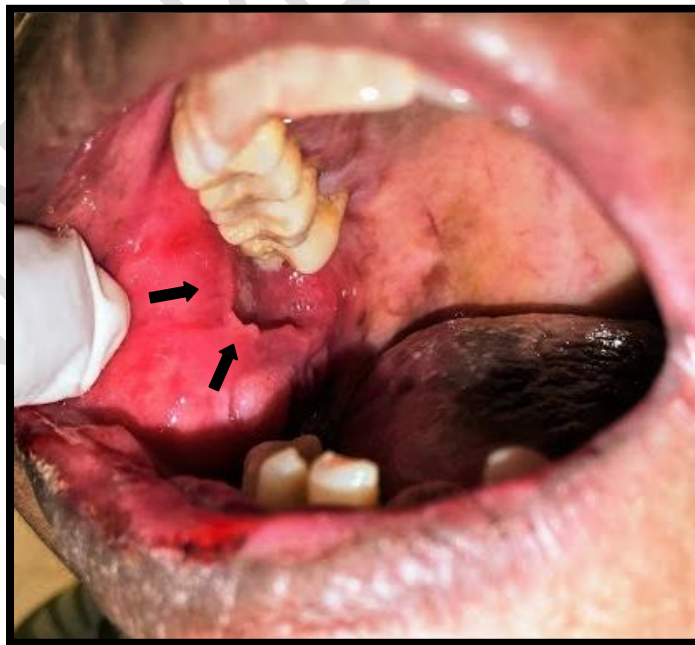**Figure 5:** Orthopantomogram revealing a diffuse, poorly defined radiolucency with ragged borders in relation to 34–43, extending laterally on either side and involving the surrounding alveolar bone.



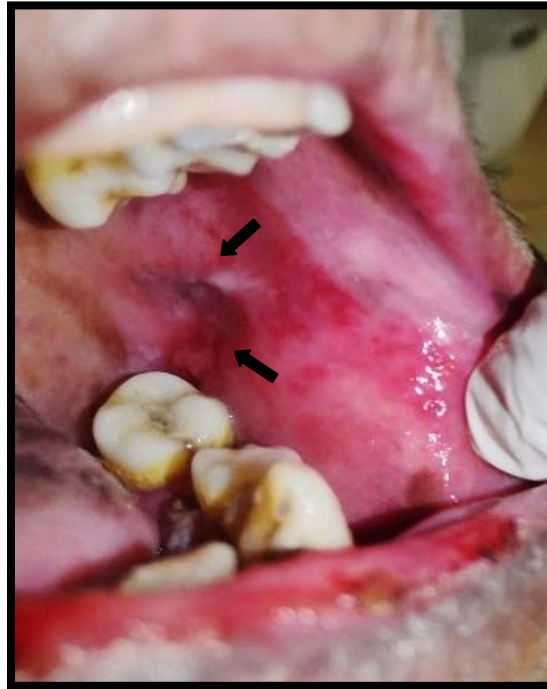
**Figure 1:** Dried and bleeding lips



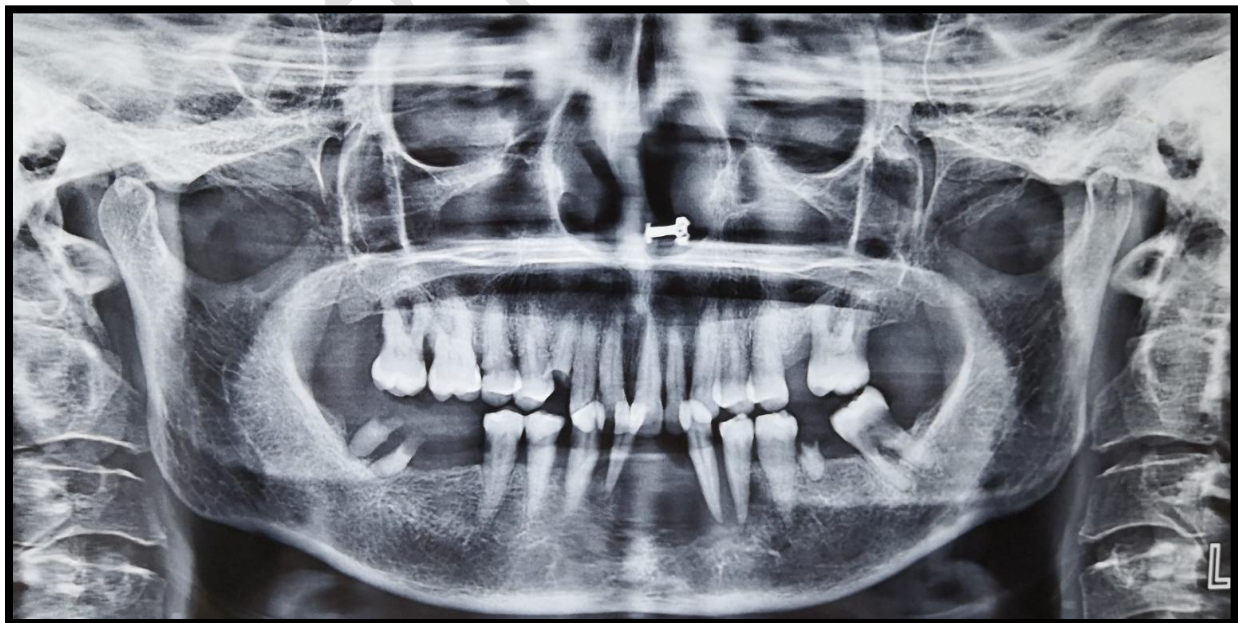
**Figure 2:** Ulceroproliferative growth, extending from the mesial aspect of 43 to the mesial aspect of 34 and labio-lingually from the labial vestibule to lingual vestibule corresponding to 33 – 42.



**Figure 3:** An ulcerative lesion extending along the line of occlusion from the mesial aspect of 26 to the distal aspect of 27 was present on the right buccal mucosa.



**Figure 4:** Whitish, non-scrapable patch present on the left buccal mucosa along the occlusion line, corresponding to 37.



**Figure 5:** Orthopantomogram revealing a diffuse, poorly defined radiolucency with ragged borders in relation to 34–43, extending laterally on either side and involving the surrounding alveolar bone.