

Distal revascularization with interval ligation (DRIL) – an extended indication and technical details

ABSTRACT

BACKGROUND: Mature autogenous arteriovenous fistula(AVF) seems to be the best way to access the circulation for chronic hemodialysis in patients with end stage renal disease(ESRD), but in some cases steal can occur in relation to these fistulas and resulted in distal ischemia manifested as attacks of severe ischemic pain during dialysis sessions (that may mandate discontinuation of the session) which may progress to digital ischemic rest pain, digital ulcers or gangrene. And in some cases long standing peripheral nerve ischemia can occur and manifests as a progressive atrophy of forearm and hand muscles with progressive weakening of hand grip. Over decades DRIL operation was described as a definitive treatment to cure this ischemic manifestation with preservation of the fistula, but criteria for patient selection, fine technical details and the spectrum of indications were lacking in these previous reports.

AIM OF THE WORK: The aim of this study is to define criteria for selection of cases for whom DRIL operation can be applied with good outcome, test the efficacy of this procedure to treat fistula induced distal ischemic neuropathy and achieving partial or complete nerve recovery. Along with description of the fine technical details during surgery.

MATERIALS AND METHODS: Twelve patients were enrolled in this study, all of them were having mature brachial artery based AVF for chronic hemodialysis with manifestations of distal ischemia caused by steal through the fistula. They were examined clinically and by duplex ultrasound, routine lab. and cardiac investigations were done. Nerve conduction studies were done for cases with suspected ischemic neuropathy. Surgery was planned for all of them where a vein was used as a bypass graft after ligation of the artery just distal to the fistula and patients were followed up over the next six months

RESULTS: DRIL operation was successfully applied to all selected patient with almost complete cure of ischemic manifestations and, surprisingly, a progressive recovery of severely damaged nerves, in cases presented with severe ischemic neuropathy, as the patients regained a near normal muscle mass and hand grip. All grafts were patent at the end of the follow up (100% primary patency).

CONCLUSION: Beside being an ideal solution for a selected cohort of patients suffering from fistula induced critical hand ischemia, DRIL operation offers an excellent treatment option for those suffering from fistula induced delayed ischemic neuropathy especially in its severe form.

Introduction

A substantial change in treatment strategies of hemodialysis (HD) patients occurred over last decades, thanks to James E. Cimino who advocated the use of mature arteriovenous fistula (AVF) to access the circulation for chronic hemodialysis after his notice that traumatic AVF in Korean war veterans did not affect their health significantly. [1–3]

Haemodialysis via a mature autogenous A-V vascular access seems to be the best resort for patients with end stage renal disease (ESRD) for chronic dialysis, but sometimes complications occur in relation to these mature well-functioning fistulae, which necessitate prompt intervention otherwise deleterious outcomes may ensue[4]

A mature AVF usually causes reduced blood flow distal to the arteriovenous anastomosis, which may lead to hypoxia, ischemia and tissue loss. This syndrome, known in the literature as the steal syndrome, are especially more prevalent in diabetics and elderly patients. Most of the time, an AVF does not reduce perfusion of the hand to a critical level [5] . However, about 1.6–8% of patients develop frank hand ischemia [6] with the classical manifestations of coldness, cyanosis, pain at rest or during dialysis or even digital ulcers or gangrene [7]. As with the reduced, or even retrograde, flow in the arterial territory distal to the fistula, hand perfusion is usually compromised.. This hemodynamic changes usually remains clinically asymptomatic until the moment when compensatory mechanisms for perfusion by peripheral arteries are exhausted [8]

The pathophysiology of this ischemic hand syndrome is assumed to be related to reduction of the blood flow in the arterial system caused by arterial occlusive disease proximal or distal to the arteriovenous anastomosis. The steal syndrome may arise from excessive blood flow through a dilated outflow veins together with insufficient vascular adaptation and reduced collateral supply to the distal arteries. For most cases this ischemic manifestations is often tolerable, but severe longstanding hypoperfusion may end by tissue necrosis requiring digital amputation or even forearm amputation in 1% of patients [5] .

Treatment can be just ligation of the access, which usually improves the condition, but this will sacrifice the access which may be the last option for this patient, so treating the condition with preservation of the fistula is the best strategy. According to the suspected etiology, multiple options exist for example: angioplasty of proximal lesions, proximalization of arterial inflow, banding, distal revascularization with interval ligation (DRIL) or revascularization using distal inflow (RUDI) [9]

Distal revascularization and interval ligation (DRIL) was first described by Schanzer and colleagues and has gained popularity as a treatment option for fistula associated steal syndrome. The technique involves ligation of the brachial artery just distal to the AVF inflow and revascularization of the distal arm via a bypass taken from the brachial artery proximal to the AVF.[10] Good results have been reported by many authors;[11–17] however, factors associated with failure of the procedure have not been clearly identified. Furthermore, details on operative technique, particularly the level of the bypass inflow, are often lacking and many authors suggest that a short bypass, originating only a few centimetres proximal to the AVF may be adequate.[10,12,15]

Aim of the work:

The aim of this study is to define the criteria for selection of the patients for whom DRIL operation is properly indicated, along with identification of a new indication for this operation rather than critical hand ischemia, with clear description of anatomical, technical and hemodynamic details.

Patients and methods:

This is a retrospective non comparative interventional study. It was conducted between January 2019 and July 2021 in the Departments of Vascular Surgery, Alexandria New Medical Center (ANMC) and Tanta University hospital, Egypt. The study included 12 patients with end stage renal disease (ESRD) and on chronic hemodialysis via mature brachial artery based A-V fistulae who were affected by manifestations of steal caused by these fistulas . Patient selection depended on clinical examination and color duplex ultrasound study

Inclusion criteria: Patients included in this study were those on chronic hemodialysis via mature AVF with manifestation of steal phenomena in the form of ischemic rest pain in the hand, digital ulcer or gangrene or delayed ischemic neuropathy resulting in progressive weakness in forearm and hand muscles with the experience of ischemic pain during dialysis sessions.

In this study, the presence of occlusive arterial disease distal to but away (>7cm) from the body of the fistula or if the radial pulse cannot be readily felt after closure of the fistula by manual compression, does not contraindicate the operation.

Exclusion criteria:

- Patients with satisfactory radial or ulnar pulse where the primary disease is assumed to be in the palmar arch or digital arteries
- Patients with vaso-occlusive disease proximal to the fistula.
- Patients with vaso-occlusive disease distal but near (<7cms) to the fistula when the occluded segment was present in the artery planned as an outflow vessel.
- Patients experiencing severe hypotension during dialysis sessions (risk of graft thrombosis)
- Patients with mixed ischemia and venous hypertension especially if the fistula feeds more than one axial vein, (as ligation of excess outflow veins usually solves the problem).
- Patients with grossly aneurysmal or inflamed AVF.

Preprocedural clinical examination and investigations:

- General examination to exclude additional systemic disease like icteric tinge in hepatic patients or the presence of anemia or hypoproteinemia.
- local examination of the affected limb regarding the shape, presence of edema or signs of venous hypertension, size and number of arterialized veins, presence of aneurysms or pseudoaneurysms, areas of inflammation or infection, state of muscle mass in the forearm and hand, color and temperature of the hand and digits and the presence of trophic changes, ulcers or gangrene. Any nearby vein other than the main arterialized one was marked and was considered as a potential graft material for this short bypass if it was of adequate length and diameter. Finally palpation of the thrill in arterialized veins and palpation of the radial and ulnar pulses before and after manual compression to cease the flow across the fistula
- Colored duplex study to examine patency and flow characteristics of the arteries proximal to the fistula (subclavian to brachial), flow across the fistula

(flowmetry), state of the arteries distal to the fistula regarding anatomical details, caliber, patency and direction of flow (antegrade or retrograde) and examination of the palmer arches. Finally examination of the veins near the fistula for selection of a potential graft material (a vein which is not a principle site for cannulation with a length of at least 12cms and a caliber of 3mms or more.

- Routine laboratory and cardiac investigations.

-Nerve conduction study and electromyogram for cases presented with progressive muscle atrophy in the ipsilateral forearm

Surgical intervention:

-**Anesthesia:** general anesthesia was offered to some patients but the vast majority were operated upon with supraclavicular brachial plexus block or local anesthesia with light sedation.

- **Surgical technique:** The first incision was placed over the course of the brachial artery seven to ten centimeters proximal to the AV fistula, dissection of about three centimeters of the artery and encirclement with a vessel loop. The second incision was placed over the distal brachial artery just distal to the body of the fistula, manual compression of the fistula helped us to recognize the exact site of the artery by feeling the pulse, dissection of the distal brachial artery and its bifurcation at this site was technically demanding due to dense adhesions, and the need to carry out the dissection as near as possible to the body of the fistula, meticulous patiently performed dissection was needed, isolation of two to three centimeters of distal brachial/ proximal radial or ulnar arteries without scarification of major side branches was done .

Next, harvest of a nearby adequate vein as a graft material, and after preparation and flushing of the vein, ligation of the distal brachial / proximal radial or ulnar artery as near as possible to the fistula using a 0 or 2/0 silk ligature. After flushing of the distal arterial bed using heparinized saline, arterial control and creation of the distal anastomosis, was carried out distal to the ligature using the proximal end of the vein. After testing the integrity of the anastomosis tunneling of graft to the proximal incision was done coursing medial to the fistula and the arterialized vein, then creation of the proximal anastomosis after arterial control using 6/0 polypropylene double armed suture After revision of the graft and getting sure of adequate arterial pulse distal to the distal anastomosis closure of the wounds in one layer and suction drains were inserted only if excessive soft tissue ooze was noticed (figure).

No systemic heparin was given.

Debridement of digital ulcers or gangrene was done immediately if the patient was under general anesthesia or supraclavicular block, but for cases done under local anesthesia debridement of necrotic tissues was delayed unless infected.

After completion of the procedure digital palpation of the radial or ulnar pulse was done and if not palpable examination using a hand held Doppler was carried out and compared to the preoperative status.

Follow up

Follow up visits were scheduled at 1 week (dressing), 2 weeks (suture removal and duplex assessment), one month (duplex), 3 months (duplex, nerve conduction study for cases of fistula induced ischemic neuropathy) and six months (duplex assessment and nerve conduction study).

Results:

Twelve patients were enrolled in this study, there were eleven males and one female. Their age ranged from 21 to 65 years with a mean of 35.6 years (SD \pm 13.225), two of them were diabetic but controlled and seven of them were hypertensive. Periods of dialysis via this stealing fistula ranged from 8 to 60 months with a mean of 23.67 months (SD \pm 15.135)

All patients complained of pain or at least discomfort specially during dialysis sessions, but the main complaints were digital ulcers or established gangrene (tissue loss) in 7 patients (58.3%), severe devastating rest pain in 3 patients (25 %) and muscle atrophy with weak hand grip and claw hand deformity (delayed ischemic neuropathy but warm well perfused hands) in 2 patients (16.67%) who had not gained any improvement with physiotherapy and reported the experience of severe ischemic pain near the end of each dialysis session. (Figure 1) All patients were on regular dialysis via mature AV fistulas for at least seven months before development of the complaints (delayed complications).

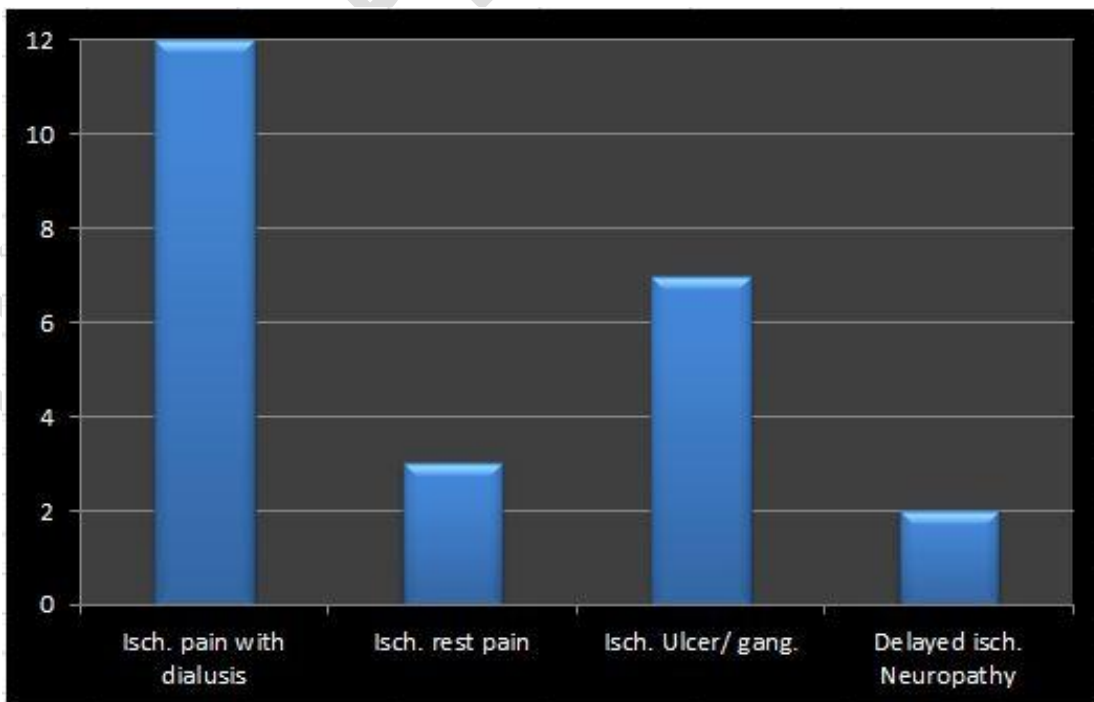


Figure 1 distribution of different clinical presentation among patients

On clinical examination all fistulae were functioning ones, with absent or very faintly felt radial pulse and with manual compression of the fistula, till ceasing the flow through it, radial pulse returned to be strongly felt in 9 patients (75%) but no remarkable changes were noticed in 3 patients where arterial occlusive disease distal to the fistula was concluded which was assured later on with **Duplex** examination which showed that the arterial walls distal to the fistula were healthy in 9 patients while 3 patients were having segments of chronic total occlusion (CTO) or multiple tight stenosis in distal arterial territories (seven centimeters or more distal to the fistula). Also duplex study found that the arterial flow just distal to the fistula was antegrade in 4 patients (figure 2) while it showed a retrograde flow in 8 patients (66.7%). The estimated flow across the fistulae ranged from 1700 to 3200 cc/minute with a mean of 2452 cc/min. SD \pm 396.78 as was shown by duplex study.

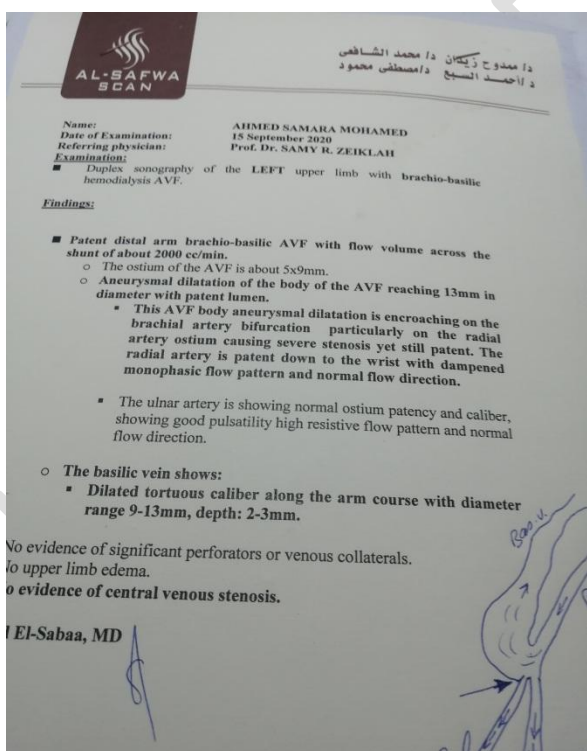


Figure 2. Duplex study showing encroachment of the fistula on the brachial bifurcation with distal antegrade flow in patient with critical hand ischemia

Nerve conduction studies were done for 2 patients suffered from progressive muscle atrophy of the forearms and hands of the fistula side compared to the other side, which started to develop several months after maturation of the fistula, and showed that there was ischemic nerve changes with axonal loss (figure 6)

We operated on patients with hemoglobin concentration of at least 9 gms/dl and a normal co-agulation parameters and platelet counts. No critical cardiac, pulmonary or hepatic conditions were found in our patients. General anesthesia was offered for 2 patients, while supraclavicular brachial plexus block was done for 8 patients, and 2 patients received local anesthesia with mild sedation.

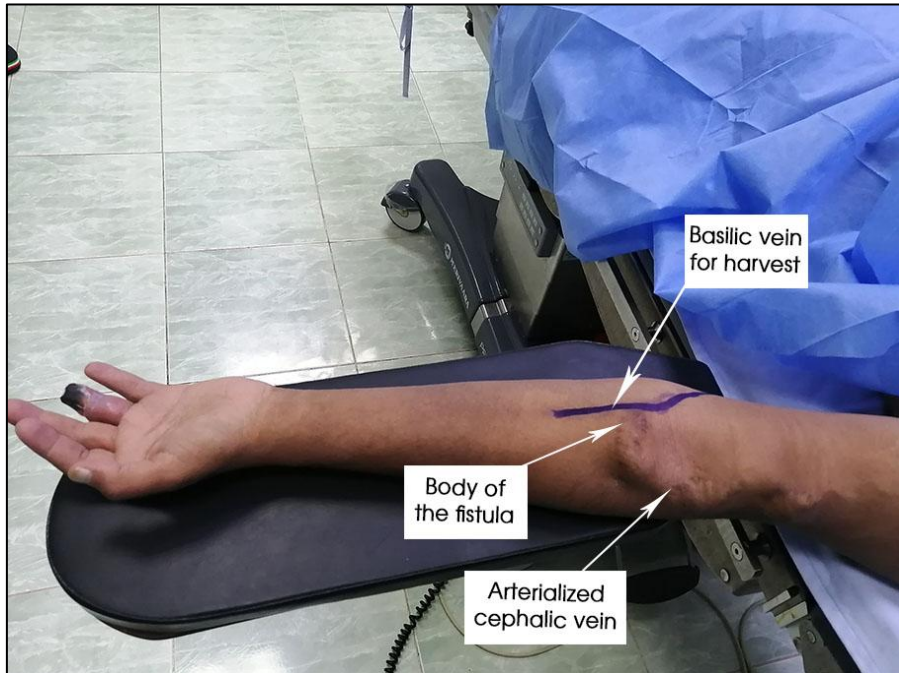


Figure 3. Just before intervention

During intervention we noticed that the brachial artery in almost all cases was hypertrophied unlike the arteries distal to the fistula which were of small caliber and almost pulseless which made their dissection and isolation in the field of adhesions a challenging mission. A sufficient segment (≥ 3 cms) of brachial artery distal to the fistula could be obtained in 3 patients (25%) while the body of the fistula was encroaching on the brachial bifurcation in the rest of the patients where the proximal radial or ulnar arteries were used as a site for outflow. Ligation of the artery distal but as near as possible to the body of the fistula was done in all cases and the distal anastomosis was created distal to this ligature after flushing of the artery distally with heparinized saline. In most cases there was an adequate vein near the fistula which could be used as a potential bypass graft (figures 3,4) as we used the basilic vein in 6 cases (as the main arterialized vein used for dialysis was the cephalic), the nearby cephalic vein was harvested in 4 cases, the descending forearm vein was used in one patient and a saphenous harvest was carried out in one patient where no adequate vein could be found in the operated limb (one of the 2 cases received general anesthesia). The length of the graft ranged from 10 to 15 cms. with a mean of 12.42 cms (SD \pm 1.4)

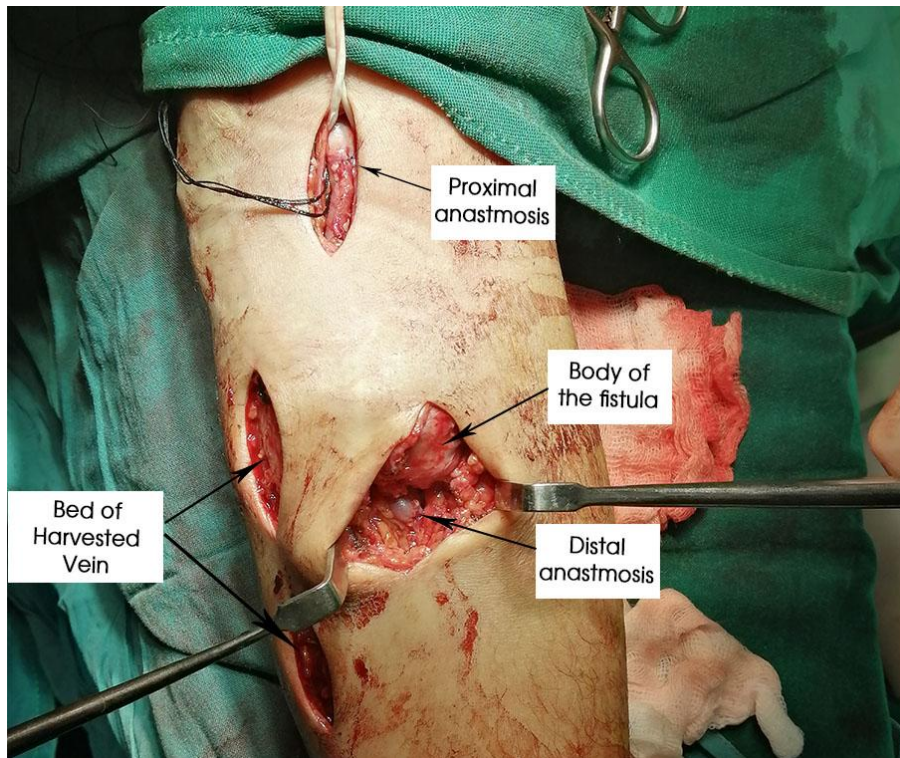


Figure 4 intra operative photography

We needed to insert a closed suction drain for 4 cases for excessive tissue ooze. At the end of the procedures all grafts were patent with fair pulse at the distal anastomosis, radial pulse was adequately felt in nine patients (75%) and debridement was done for 5 patients. All patients were discharged within 24 hours and were prescribed antibiotics, LMWH in subtherapeutic dose (Enoxaparin sodium 4000 to 6000 IU /12 hours subcutaneously) for ten days with dropping of one dose at the day of dialysis) and aspirin 100mg/day for 3 months

At the first and second follow up visits (at 5-7 and 12-15 post-operative days respectively) drains removal, dressing with further debridement and stitch removal were done. All grafts were found to be patent by hand-held Doppler. Seven patients (58%) were able to carry on dialysis via their fistulae within 3 days of the operation where parts of the arterialized vein could be sufficiently exposed so as punctures did not violate the surgical wounds, and for the other 5 patients temporary hemodialysis catheters were inserted and were removed just after stitch removal where patients could regain dialysis via their fistulae. No rest pain was reported during the first two visits but 2 cases of superficial wound infection had been found (one of them was a diabetic patient) and were treated with antibiotics and completely resolved without sequelae. Patients with muscle atrophy were advised to continue sessions of physiotherapy.

Subsequent visits were at one month after the operation where all patients attended it and complete healing of the surgical wounds was noted, patency of all grafts was confirmed and most of the sites of ischemic tissue loss were adequately healed (five out of seven patients showed total healing of digital ulcer or debridement sites. Figure 5)

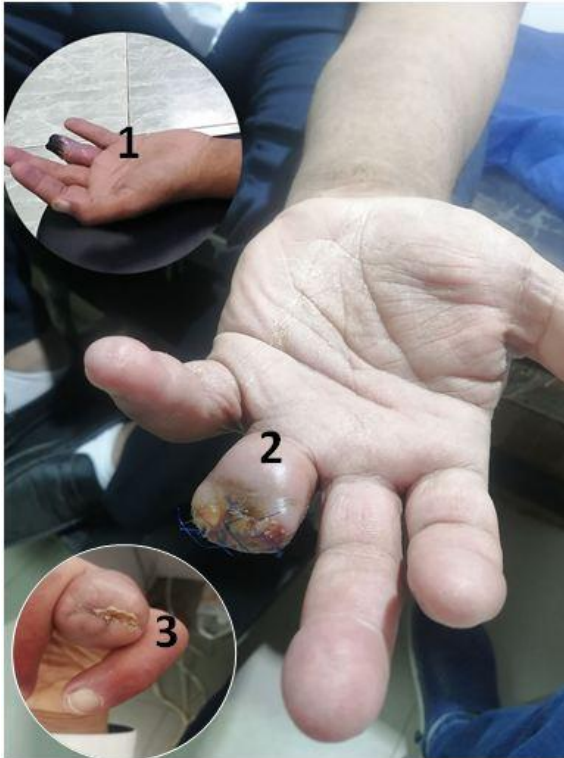

Figure 5. Digital gangren before, 2 weeks and one month after intervention

At three months all patients attended the follow up visit and all of them were enjoying a stable dialysis via their fistula with patent grafts and well perfused hands. Muscle atrophy started to improve with nerve conduction studies showed ongoing regeneration of the previously lost axons (figure 6)

At presentation

Conclusion

Sensorimotor electrophysiological study of both upper limbs showing **evidence of both left median and ulnar nerves neuropathy**, mostly at level of elbow, the pathology is demyelinating with severe axonal loss.

N.B: the patient was In-cooperative patient in using needle emg .

3 Months after Intervention

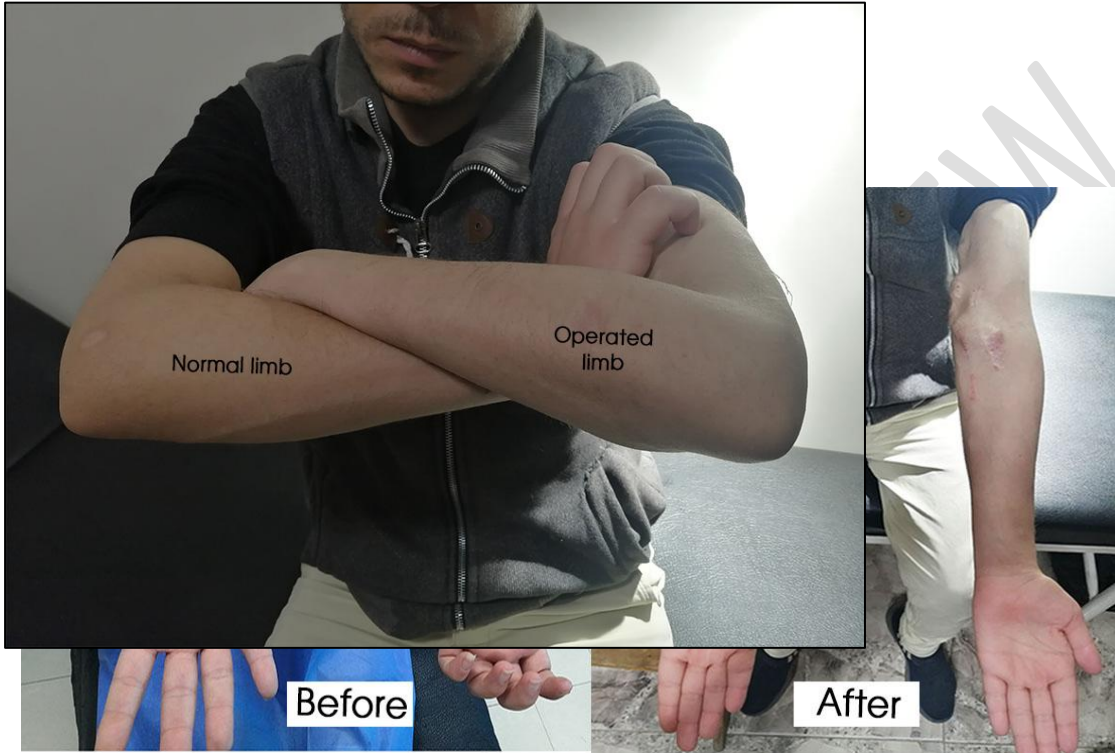Impression

- Electrophysiological follow up study of (left upper limb ischemic neuropathy) revealed:
- **SEVERE left median much more than ulnar sensori-motor and superficial radial sensory mixed demyelinating and axonal neuropathy affecting distal segment of nerves.**
- Normal proximal median nerve recorded from left FCR and distal radial motor fibers recorded from EIP muscles.
- EMG findings of denervation with **GOOD ongoing regeneration** from ulnar nerve recorded from ADM and **early reinnervation** sign from median nerve recorded from APB muscle.
- Follow up is recommended from 6 months to one year.

Thank you for your referral

Figure 6. Nerve conduction study before and 3 months after intervention

The last visit was at six months and ten patients attended as one patient died at the fifth month after the operation and one patient was in compliance with attendance. All of them were found with functioning fistulas through which regular dialysis was done, duplex scanning showed patent grafts in all of them. In patients with delayed ischemic neuropathy, electrophysiological studies



showed near total recovery of the affected nerves and clinically, complete resolution of clawing of near normal muscle mass and hand grip for **Figure 7: Improvement of the muscle mass**

Discussion:

We tried to summarize our experience with 12 cases to whom DRIL was done as a definitive treatment for steal phenomena developed as a delayed complication of AVF created for dialysis, and this relatively small number treated over more than 2 years were those patients having no exclusion criteria, as most of the patients presented to us were those with mixed ischemia and venous hypertension with the presence of multiple outflow veins where ligation of excess veins was enough to solve the problem, or those with extensive arterial steal. **Figure 8. Marked improvement of the muscle mass of the operated limb to be nearly identical to the other side** surgical details explained in this work may be followed adopting this technique as a

treatment strategy. We demonstrated that, unlike the original description, the graft for bypass can be harvested from the same surgical field, abolishing the need for incisions in the thigh or leg to have a saphenous harvest and enabled us to carry out the procedure under regional nerve block or even local anesthesia. The introduction of a new indication for DRIL, which is delayed ischemic neuropathy with progressive muscle atrophy and hand weakness, was an important point in our study that had never been described in the literature as we obtained very satisfactory results for these cases. Although there were 3 patients presented with arterial occlusive disease distal to the fistula (sub-optimal outflow), all patients enjoyed 100% graft patency till the end of their follow up periods, this may be explained by the short lengths of the grafts, the use of autogenous materials for grafting (veins), the relatively hypertrophied-high flow brachial artery at the site of proximal anastomosis and the short course anticoagulation given post operatively. Even with the presence of arterial disease in the forearm, once there is an adequate outflow segment, DRIL seemed to be sufficient for hand salvage depending on the extensive collateralization in the forearm and hand. Schanzer *et al.* (1988)[10] gave the first original description of this technique and they described the original hemodynamic features and surgical techniques and achieved 100% graft patency and clinical cure in their small numbered cohort (3 patients), the ischemic neuropathy as an indication was outside their scope.

Haimov *et al.* (1996)[18] reported cure rate of 86% with 95% graft patency in their 23 studied patients over a 24 months of follow up which was less than the cure and patency rates in this study and this is most probably due to the longer follow up time for those patients with a well-known increased risk of progressive peripheral vascular disease owing to their renal condition.

Stierli *et al.* (1998)[19] studied six patients and reported a cure rate of only 33% in spite of having all their grafts patent during the follow up, this may be related to the extensive obliteration of the palmar arches while Knox *et al.* (2002)[12] studied 52 patients over extended follow up periods (24-48 months) and they had a 86% patency rate with a cure rate of 55% and improvement in 25% in their patients. Lazarides *et al.* (1998)[20] and Field Blackweel and co-authors (2009)[21] reported their experience with seven and six patients respectively and they both achieved 100% graft patency with 100% cure rates. A decade separated the two studies and a longer period separated their studies from the current one, but the results were the same, this optimal results are almost attributed to the strict selection for candidates for this intervention.

Finally we found that careful pre and post operative duplex study was sufficient enough for diagnosis, planning intervention and follow up which minimizes the role of contrast based studies for these patients.

References :

- 1 Quinton WE, Dillard DH, Scribner BH: Cannulation of blood vessels for prolonged hemodialysis. *Trans Am Soc Artif Intern Organs* 1960; 6: 104–113.
- 2 Konner K: History of vascular access for haemodialysis. *Nephrol Dial Transplant* 2005;20: 2629–2635.
- 3 Allon M: Current management of vascular access. *Clin J Am Soc Nephrol* 2007; 2: 786–800.
4. Sidawy AN, et al: Recommended standards for reports dealing with arteriovenous hemodialysis accesses. *J Vasc Surg* 35:603–610, 2002.
5. Schanzer A, Nguyen LL, Owens CD, Schanzer H: Use of digital pressure measurements for the diagnosis of AV access-induced hand ischemia. *Vasc Med* 2006;11:227–231.
6. Leon C, Asif A: Arteriovenous access and hand pain: the distal hypoperfusion ischemic syndrome. *Clin J Am Soc Nephrol* 2007;2:175–183
7. Scheltinga MR, van Hoek F, Bruijninx CM: Time of onset in haemodialysis access-induced distal ischaemia (HAIDI) is related to the access type. *Nephrol Dial Transplant* 2009;24:3198-3204.
8. Lazarides MK, Stamos DN, Kopadis G, Maltezos C, Tzilalis VD, Georgiadis GS: Onset of arterial 'steal' following proximal angioaccess: immediate and delayed types. *Nephrol Dial Transplant* 2003;18:2387-90.
9. Zanow J, et al: Diagnosis and differentiated treatment of ischemia in patients with arteriovenous vascular access. In Henry ML, editor: *vascular access for hemodialysis–VII*, Chicago, 2001, Gore, pp 201– 9.
10. Schanzer H, Schwartz M, Harrington E, et al. Treatment of ischemia due to “steal” by arteriovenous fistula with distal artery ligation and revascularization. *J Vasc Surg* 1988;7:770-3.
11. Berman SS, Gentile AT, Glickman MH, et al. Distal revascularization interval ligation for limb salvage and maintenance of dialysis access in ischemic steal syndrome. *J Vasc Surg* 1997;26:393-404.
12. Knox RC, Berman SS, Hughes JD, et al. Distal revascularization interval ligation: A durable and effective treatment for ischemic steal syndrome after hemodialysis access. *J Vasc Surg* 2002;36:250-6.
13. Walz P, Ladowski JS, Hines A. Distal revascularization and interval ligation (DRIL) procedure for the treatment of ischemic steal syndrome after arm arteriovenous fistula. *Ann Vasc Surg* 2007; 21:468-73.
14. Mwipatayi BP, Bowles T, Balakrishnan S, et al. Ischemic steal syndrome:

a case series and review of current management. *Curr Surg* 2006;63:130-5.

15. Sessa C, Riehl G, Porcu P, et al. Treatment of hand ischemia following angioaccess surgery using the distal revascularization interval ligation technique with preservation of vascular access: description of an 18-case series. *Ann Vasc Surg* 2004;18:685-94.

16. Gupta N, You TH, Konig G, et al. Treatment strategies of arterial steal after arteriovenous access. *J Vasc Surg* 2011;54:162-7.

17. Field M, Blackwell J, Jaipersad A, et al. Distal revascularisation with interval ligation (DRIL): an experience. *Ann R Coll Surg Engl* 2009;91:394-8.

18. Haimov M, Schanzer H, Skladani M. Pathogenesis and management of upper-extremity ischemia following angioaccess surgery. *Blood Purif* 1996; **14**: 350-4.

19. Stierli P, Blumberg A, Pfister J, Zehnder C. Surgical treatment of 'steal syndrome' induced by arteriovenous graft for hemodialysis. *J Cardiovasc Surg* 1998; **39**: 441-3.

20. Lazarides MK, Stamos DN, Panagopoulos GN, Tzilalis VD, Eleftheriou GJ, Dayantas JN. Indications for the surgical treatment of angioaccess-induced arterial 'steal'. *J Am Coll Surg* 1998; **187**: 422-6.

21. Blackweel F, Wall J, Pherwani SM. Distal revascularization with interval ligation (DRIL): an experience. *Ann R Coll Surg* 394 *Engl* 2009; **91**: 394-398.