

### **Obturator Hernia Revisited; Two Case reports with Review of Literature**

#### **Abstract**

With very low reported incidence of 0.073% and 1.6% in western and Asian literature respectively, obturator hernia is a rare entity to encounter. Pre-operative diagnosis and timely management are key to survival. Here we are presenting two cases of obstructed obturator hernia which were timely diagnosed pre-operatively high index of suspicion with Emergency exploratory laparotomy. A review of literature concluded that a high index of suspicion with the proper physical examination which is guided by appropriate cross-sectional imaging can be the only way to go in an attempt to prevent mortality and morbidity associated with Obturator hernia.

#### **Introduction**

First described by Pierre Roland Arnaud de Ronsil in 1724, obturator hernia is herniation through obturator foramen which is formed by rami of ischium and pubis in the obturator canal.<sup>1,2</sup>

Obturator Hernia is a rare external abdominal hernia, described clearly in work of Skandalakis as hernia through obturator canal, never externally seen, rarely palpable, hence often unsuspected and undiagnosed.<sup>1</sup>

Published incidence of obturator hernia is low as 0.073% in western series, while in Asian countries it is about 1.6%.<sup>3</sup> Some reports claims that actual incidence can range from 6-8%, of which majority goes undiagnosed.<sup>4</sup> There is published predominance in female with female to male ratio of 9:1, which also reflects in clinically symptomatic scenario.<sup>5</sup>

Affected patients are generally thin built, short stature, aged multiparous female often with multiple comorbidities. Presentation is commonly as emergent case of intestinal obstruction with strangulation and obstruction and carry a very high mortality rate of up to 47%.<sup>6</sup>

Here we will be discussing two cases of Obturated hernia and will discuss associated literature available till date.

#### **Case presentation**

##### **Case 1**

81 years old male, known case of Asthma and BPH on treatment, was admitted with chief complaints of pain abdomen for 7 days associated with vomiting and obstipation for 3-4 days. Patient also gave history of intermittent pain right thigh, which was evaluated with MRI thigh and was non-conclusive.

On examination patient had tachycardia with abdominal distension.

On investigations X-ray abdomen suggested of distended small bowel loops with multiple air-fluid level suggestive of small bowel obstruction. Patient after resuscitation and hydration underwent CECT Whole abdomen which suggested an obstructed right sided Obturator hernia, with herniation of distal small bowel loop through right obturator foramen with abrupt luminal narrowing and dilated proximal bowel loops (Figure 1,2).

Patient was optimized and after PAC evaluation under ASA-3E underwent Emergency Laparotomy, which revealed dilated small bowel loops with Richter type herniation of ileum about 15cm proximal to ileocecal junction in right obturator canal. Bowel was reduced, viability confirmed and defect of about 2cmx1.5cm closed primarily with Prolene 2-0. Small contralateral obturator canal defect of size 1.0cmx0.5cm was also closed with a prolene stitch.

Post operatively patient was supported nutritionally with TPN. Patient had prolonged ileus postoperatively which was managed conservatively.

Patient was discharged on POD 13. He was doing well in his follow up.

## **Case 2**

81-year-old female, known Hypertensive and Hypothyroid was a follow up case of Exploratory laparotomy with Resection anastomosis of small bowel 6 months back for distal ileal stricture with intestinal obstruction, presented with complaints of nausea, recurrent vomiting and inability to pass flatus and motion for last 6-7 days.

Patient presented in a sarcopenic state with dehydration and tachycardia. Patient on examination had distended abdomen with tender palpable bowel loops.

Patient underwent CECT which suggested obstructing left obturator hernia. Proximal ileal loop was seen anterior to obturator externus muscle and further into adductor compartment of left thigh (Figure 3).

Patient was optimized pre-operatively and underwent Emergency Exploratory laparotomy which revealed strangulated left sided obturator hernia involving proximal ileal loop, with distended and edematous small bowel. Bowel was reduced and was resected in view of compromised vascularity and a double barrel stoma fashioned in view of intra-operative findings.

Post operatively patient was given nutritional support and was managed with supportive medications. Patient was discharged on POD 9. Subsequent follow up was uneventful.

## **Discussion**

Obturator hernia is rare hernia through obturator canal presents generally as case of mechanical bowel obstruction in about 0.2-1.6% cases of mechanical bowel obstruction.<sup>7,8,9</sup>

Risk factors for development of Obturator Hernia can be explained by adage "Little Old women Hernia". Pathophysiology wise thought to be arising due to progressive relaxation of pelvic floor muscle, which is associated with advanced age and multiparity. Associated malnutrition often leads to loss of pre-peritoneal fat and baring of vessels and Nerve, which finally with increased intra-abdominal pressure due to any cause viz COPD, Ascites, Chronic constipation etc, leads to Herniation.<sup>3</sup>

Above mentioned sequence can also be put in perspective of stage wise progression as described in literature for obturator hernia. Stage1- Pre-peritoneal fat enters obturator foramen, Stage2- Peritoneal dimpling, Stage3- Herniation of viscera.<sup>2,10,11</sup>

Most common site of occurrence is right side, explained due to protection of left sided canal by sigmoid colon.<sup>12,13,7,8,14</sup> Many studies published data on occult contralateral hernia ranging from 6-63%, but described to be dependent on surgical approach preferred.<sup>15,16,17</sup>

Most common presentation of obturator hernia is with features of intestinal obstruction with abdominal cramps, vomiting with abdominal distension. These episodes can be in acute presentation or can also presents as recurrent episodes. Highest incidence of Richter hernia is found to be associated with obturator hernia.<sup>18</sup>

Due to position of sac between Pectineus and Adductor longus muscles, physical findings are often not present. Described signs associated with obturator hernia - Howship Romberg sign, may be present in 15-50% of patients. This is due to irritation of obturator nerve by hernial sac. This sign can be demonstrated by extension, medial rotation and abduction of leg and manifest as pain over medial aspect of thigh. This sign is often tough to be evaluated in cases of pathologies of ipsilateral hip joints, arthritis etc.<sup>9,19</sup>

Plain X-Ray abdomen and CECT abdominopelvic area are two most commonly used imaging modality for diagnosing obturator hernia. Although have good sensitivity and specificity but have not shown any reduction in incidence of mortality and morbidity due to complications of obturator hernia. This may be because most patient present only when symptomatic. Sensitivity of CT is reported to be about 85% as reported in various studies.<sup>19</sup> Hence high index of suspicion with proper physical examination which is guided by appropriate cross-sectional imaging can be the only way to go in attempt to prevent mortality and morbidity associated with Obturator hernia.<sup>20,21</sup>

Various studies have reported varied approach for surgery including Cheatle-Henry retropubic, preperitoneal, inguinal, obturator, and intraabdominal approaches.<sup>22,23</sup> As the most common presentation is emergent, hence lower mid line laparotomy with intraabdominal approach is preferred root as it provides better exposure of content, evaluation of contralateral side and if needed resection of bowel.<sup>24,22</sup> Laparoscopic approach both trans peritoneal and extra peritoneal has been described and shown to be associated with less post-operative pain, short hospital stay and less post op ileus and respiratory complications. This is often difficult with dilated bowel encountered during surgery.<sup>25</sup> Hence, decision for operative approach should be guided by surgeon's choice and pre-operative suspicion of strangulation.

Various methods have been described in literature for closure of defect after reduction of hernia. Traditional method of primary peritoneal closure with stiches is still favoured by most specially in case of small defect size. This was done in one of our case with smaller defect, while the other went closure with mesh plug. Tension free closure using mesh or plugs are also defined and is mainly favoured in case of concomitant groin hernia in an uncontaminated case to widely cover all hernial sites.<sup>26,27,28</sup>

Recurrence rate after repair is reported to be very low as reported by Nakayama et al and Rodríguez-Hermosa et al.<sup>27</sup>

Reported morbidity and mortality post operatively is high pertaining to delayed diagnosis, associated bowel strangulation and overall physical profile of the patients.<sup>20,22,30,31,5</sup>

Hence prompt diagnosis guided by high clinical suspicion with CT scan followed by early repair is the way to go in cases of obturator hernia for decreasing associated morbidity and mortality.

## Conclusion

To Conclude, Pain radiating to thigh, palpable groin lump, and Obstruction in an elderly should alert one to possibility of obturator hernia, Opposite site of hernial defect (6%) should also be addressed and Prompt diagnosis and management can prevent mortality.

## Literature Table

<b>Authors</b>	<b>Size</b>	<b>Sex M/F</b>	<b>Site (R/L/B)</b>	<b>Pre-op Diagnosis</b>	<b>M/C Symptoms</b>	<b>Howship- Romberg sign</b>	<b>Duration</b>	<b>Need of resection</b>	<b>Hospital stay</b>	<b>Mortality</b>
Yokoyama <sup>7</sup>	36	1/35	29/7/0	21	Obstruction	16	5	21	28	4
Nakayama <sup>29</sup>	12	1/11	6/3/3	11	Obstruction	5	7	5	3	1
Hennekinne- Mucci <sup>32</sup>	17	1/16		4	Strangulation	4		11		6
Kammori <sup>8</sup>	43	2/41	20/11/12	26	Small bowel obstruction	20		16	15.5	8
Haraguchi <sup>19</sup>	22	0/22	17/5/0	13	Small bowel obstruction	15	5.8	17		1
Rodríguez- Hermosa <sup>27</sup>	16	0/16	9/7/0	3	Small bowel obstruction	5	4.1	12	14.7	3
Igari <sup>20</sup>	10	0/10	5/5/0	10	Small bowel obstruction	5		6	21.1	0
Chan <sup>21</sup>	21	0/21	11/9/1	14	Small bowel obstruction		3.1	11	14.4	10
Thanapaisan <sup>30</sup>	61	8/53	24/37/0		Small bowel	8		41		7

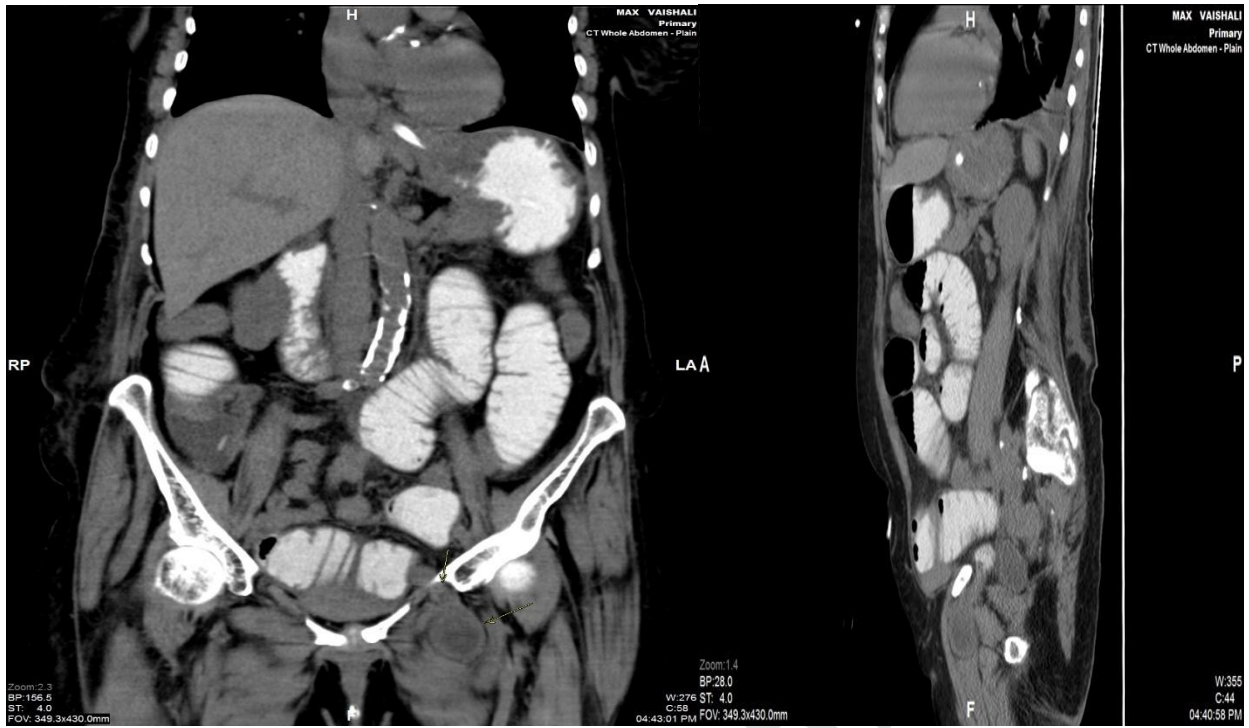					obstruction					
Ijiri <sup>31</sup>	17	1/16	9/8/0	12	Small bowel obstruction	11		9		1
B.S. Nasir <sup>14</sup>	30	1/29		9	Small bowel obstruction	11		14		3
Ng <sup>5</sup>	35	0/35	22/13/0	19	Small bowel obstruction	5		10	12.6	5
Chen D <sup>25</sup>	6	0/6			Small bowel obstruction			2	10.17	
Present Title	2	1/1	0/1/1	2	Small bowel obstruction	2		1	11	0

UNDER PEER REVIEW

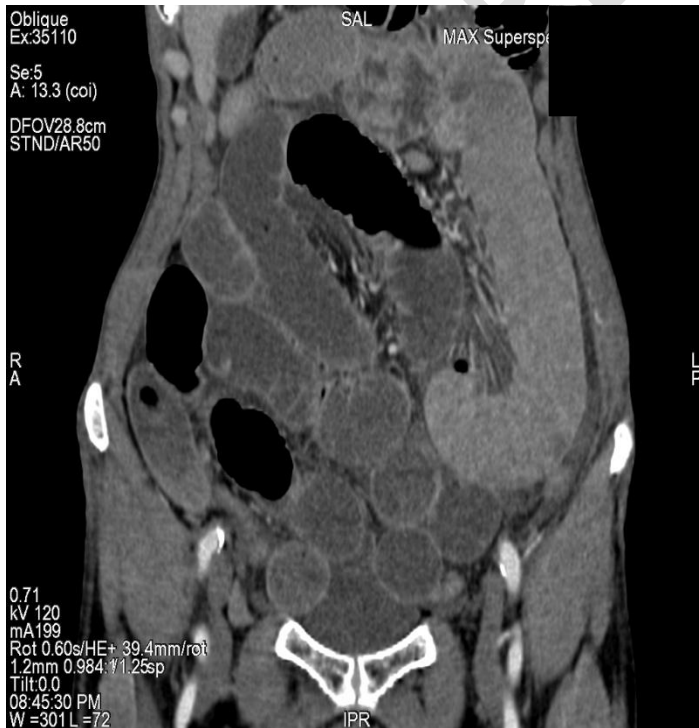
## References

1. Stamatiou D, Skandalakis LJ, Zoras O, Mirilas P (2011) Obturator hernia revisited: surgical anatomy, embryology, diagnosis, and technique of repair. *Am Surg* 77(9):1147–1157
2. Gray SW, Skandalakis JE, Soria RE, et al. Strangulated obturator hernia. *Surgery* 1974;75:20–7.
3. Bjork KJ, Mucha PJr, Cahill DR. Obturator hernia. *Surg Gynecol Obstet* 1988;167:217–22.
4. Susmallian S, Ponomarenko O, Barnea R, Paran H. Obturator hernia as a frequent finding during laparoscopic pelvic exploration: a retrospective observational study. *Medicine*. 2016 Jul;95(27).
5. Ng DC, Tung KL, Tang CN, Li MK (2014) Fifteen-year experience in managing obturator hernia: from open to laparoscopic approach. *Hernia* 18(3):381–386
6. Cresienzo D, Faranda C, Perrot L, et al. Laparoscopic treatment of a strangulated obturator hernia. *Hernia* 1998;2:203–5.
7. Yokoyama Y, Yamaguchi A, Isogai M, et al. Thirty-six cases of obturator hernia: does computed tomography contribute to postoperative outcome? *World J Surg* 1999;23:214–7.
8. Kammori M, Mafune K, Hirashima T, et al. Forty-three cases of obturator hernia. *Am J Surg* 2004;187:549–52.
9. Chang SS, Shan YS, Lin YJ, et al. A review of obturator hernia and a proposed algorithm for its diagnosis and treatment. *World J Surg* 2005;29:450–4.
10. Skandalakis LJ, Androulakis J, Colborn GL, Skandalakis JE (2000) Obturator hernia. Embryology, anatomy, and surgical applications. *Surg Clin N Am* 80(1):71–84.
11. Callaghan CJ, Whitaker RH (2002) Obturator canal fat plug: a pre-hernial condition? *Clin Anat* 15(4):276–279. <https://doi.org/10.1002/ca.10025>
12. Green BT (2001) Strangulated obturator hernia: still deadly. *South Med J* 94(1):81–83
13. Bergstein JM, Condon RE (1996) Obturator hernia: current diagnosis and treatment. *Surgery* 119(2):133–136.
14. Nasir BS, Zendejas B, Ali SM, Groenewald CB, Heller SF, Farley DR (2012) Obturator hernia: the Mayo Clinic experience. *Hernia* 16(3):315–319.
15. J. A (1997) Hernia. In: Zinner MJSS, Ellis H (eds) *Maingot's abdominal operation*, 10th edn. Appleton and Lange, Connecticut, pp 479–580
16. Hayama S, Ohtaka K, Takahashi Y, Ichimura T, Senmaru N, Hirano S (2015) Laparoscopic reduction and repair for incarcerated obturator hernia: comparison with open surgery. *Hernia* 19(5):809–814.
17. Yokoyama T, Kobayashi A, Kikuchi T, Hayashi K, Miyagawa S (2011) Transabdominal preperitoneal repair for obturator hernia. *World J Surg* 35(10):2323–2327.
18. Yip AW, AhChong AK, Lam KH (1993) Obturator hernia: a continuing diagnostic challenge. *Surgery* 113(3):266–269

19. Haraguchi M, Matsuo S, Kanetaka K, et al. Obturator hernia in an ageing society. *Ann Acad Med Singapore* 2007;36:413–5.
20. Igari K, Ochiai T, Aihara A, et al. Clinical presentation of obturator hernia and review of the literature. *Hernia* 2010;14:409–13.
21. Chan KV, Chan CK, Yau KW, et al. Surgical morbidity and mortality in obturator hernia: a 10-year retrospective risk factor evaluation. *Hernia* 2014;18:387–92.
22. Hodgins N, Cieplucha K, Conneally P, et al. Obturator hernia: a case report and review of the literature. *Int J Surg Case Rep* 2013;4: 889–92.
23. Kulkarni SR, Punamiya AR, Naniwadekar RG, et al. Obturator hernia: A diagnostic challenge. *Int J Surg Case Rep* 2013;4:606–8.
24. Mantoo SK, Mak K, Tan TJ. Obturator hernia: diagnosis and treatment in the modern era. *Singapore Med J* 2009;50:866–70.
25. Chen D, Fei Z, Wang X. Bowel obstruction secondary to incarcerated obturator hernia. *Asian J Surg* 2017;40:193–6.
26. Maharaj D, Maharaj S, Young L, Ramdass MJ, Naraynsingh V (2002) Obturator hernia repair—a new technique. *Hernia* 6(1):45–47.
27. Rodriguez-Hermosa JI, Codina-Cazador A, Maroto-Genover A, Puig-Alcantara J, Sirvent-Calvera JM, Garsot-Savall E, RoigGarcia J (2008) Obturator hernia: clinical analysis of 16 cases and algorithm for its diagnosis and treatment. *Hernia* 12(3):289– 297.
28. Miki Y, Sumimura J, Hasegawa T, Mizutani S, Yoshioka Y, Sasaki T, Kamike W, Ito T, Monta O, Nagai I (1998) A new technique of laparoscopic obturator hernia repair: report of a case. *Surg Today* 28(6):652– 656
29. Nakayama T, Kobayashi S, Shiraishi K, et al. Diagnosis and treatment of obturator hernia. *Keio J Med* 2002;51:129–32.
30. Thanapaisan C, Thanapaisal C. Sixty-one cases of obturator hernia in Chiangrai Regional Hospital: retrospective study. *J Med Assoc* 2006;89: 2081–5.
31. Ijiri R, Kanamaru H, Yokoyama H, et al. Obturator hernia: the usefulness of computed tomography in diagnosis. *Surgery* 1996;119: 137–40.



**Fig. 1 and 2- Coronal and Sagittal sections showing Obstructed Obturator Hernia**



**Figure 3- Dilated bowel loops due to obstructed right obturator hernia**

UNDER PEER REVIEW