

Optical Coherence Tomography Angiography and Fundus Fluorescein Angiography in Myopic Choroidal Neovascularization

Abstract:

Background: High myopia is defined as an axial length of the eye higher than 26mm or by a refractive error of more than -6 diopters. Pathologic myopia is the most common cause of Choroidal neovascularization (CNV) in patients younger than 50 years old. CNV is a severe retinal and choroidal lesion resulting in vision loss or blindness due to subretinal or intraretinal fluid, hemorrhage and ultimately the scar.

Aim: Study the role of Optical Coherence Tomography Angiography (OCTA) in the diagnosis of choroidal neovascularization in myopia and compare it with the findings of fluorescein angiography (FFA)

Patient and Methods: This study included 20 eyes of 20 patients had active myopic CNV in Ophthalmology Department, Tanta University.

Results: Spherical Equivalent ranged from - 6.5 diopters to - 16.0 diopters. The vessel density was significantly higher in OCTA, compared to FFA ($p < 0.001$). The CNV area was significantly less in OCTA, compared to FFA ($P = 0.012$) There was significant correlation between best corrected visual acuity (BCVA) as regard CNV site on FFA ($P = 0.002$). The BCVA is less in subfoveal CNV than in juxtafoveal CNV.

Conclusion: OCTA is a new imaging technique, non-invasive and safe with rapid image acquisition. The current gold standard for the diagnosis of myopic CNV is FFA where the presence of CNV is demonstrated by dye leakage, however FFA is invasive and may be associated with nausea, urticaria, and rarely anaphylaxis.

In routine practice, OCTA is still coupled with FFA for the diagnosis and the follow-up of myopic CNV.

Keywords: Myopic Choroidal Neovascularization, Optical Coherence Tomography Angiography.

Abbreviations

BCVA : Best Corrected Visual Acuity.

CNV : Choroidal Neovascularization

FFA : Fluorescein Angiography

OCTA : Optical Coherence Tomography Angiography.

VDZ : Vascular Density Zone.

Introduction:

pathological myopia is defined as myopia accompanied by degenerative changes in the sclera, choroid, and retinal pigment epithelium, associated with compromised visual function.⁽¹⁾ Myopic choroidal neovascularization is a common vision-threatening complication of myopia and pathological myopia.⁽²⁾ Optical coherence tomography angiography (OCTA) is a new technology that is used in diagnosis of Choroidal Neovascular Membrane as it visualizes both the retinal and choroidal vasculature.⁽³⁾ OCTA is non-invasive, uses motion contrast instead of intravenous dye, can be obtained within seconds, and provides accurate size and localization of lesion.^(3,4) FA is an invasive technique, time-consuming, requires an intravenous administration of dye.⁽⁵⁾

Patients and Methods:

This prospective randomised study was organized in the outpatient retina clinic at the Ophthalmology Department of Tanta University from September 2019 to December 2020. This study included 20 eyes of 20 patients who had active myopic CNV.

All the patients were informed and provided their written consent. The study was accepted by the local research ethical committee of the medicine faculty in Tanta University.

The ethical approval date: 11/2017

The approval code: 31947/11/17

- There are no risks for the subjects who share in this study.
- Patients' privacy was respected by hiding their names from data files and investigations using codal numbering.

Exclusion criteria:

- Patients with dense media opacity or narrow pupil that interfere with the reliability of imaging techniques.
- Patients with neurological conditions that interfere with proper detection of the OCTA image, as Parkinsonism or poor fixation.
- Patients with other causes of diminished visual acuity, optic atrophy.
- Systemic conditions in which fluorescein angiography is contraindicated, or risky, as pregnancy, or renal failure.
- History of intraocular surgery within the last 6 months.
- Patients with previous treatment. (injection of anti VEGF or laser photocoagulation).
- History of diabetic retinopathy
- History of glaucoma
- Other causes of subretinal neovascular membranes: AMD, Angioid streaks, Choroiditis and Traumatic choroidal ruptures.

Procedure

Each case had a thorough history taking and best corrected visual acuity testing (BCVA). To facilitate complete eye testing involving anterior and posterior segment testing, statistical analysis, FFA, OCT and OCTA imaging, Snellen visual acuity was changed to Decimal notation VA. In all instances, pupils were dilated with tropicamide 1% to facilitate imaging.

FFA was performed by the Heidelberg Retinal Angiogram following intravenous administration of 5 ml of 10% sodium fluorescein dye (Heidelberg Engineering, Germany).

OCT and OCTA imaging were done by a DRI OCT Triton and a swept source OCT (Topcon Corp., Japan).

OCTA imaging was performed using 3 x 3 mm and 6 x 6 mm scanning regions focused on the fovea. The OCTA software automatically fragmented the macular scans into 4 'en face' OCT slabs: (1) Superficial capillary plexus (SCP): includes the space from the inner border of ILM to the inner border of IPL. (2) Deep capillary plexus (DCP): includes the space from the outer border of IPL to the outer border of INL. (3) Outer retina: which is normally avascular and extends from OPL to RPE. (4) Choriocapillaris: a 20 µm thick slab starting 10 mm below RPE – Bruch's membrane.

In order to quantify the OCTA findings within the macula, two parameters were used: CNV area in mm² and vascular density zone (VDZ) (%).

CNV dimensions were done by outlining the CNV membrane in the outer retina images by the observer and the area was then estimated by the device.

Vascular Density Zone (VDZ) is defined as the percentage of the area occupied by vessels in the segmented area, which is the 3 x 3 millimeter squares scanned area centered on the fovea. It was then quantified after converting the images obtained into binary forms using Image J software (Image J 1.48v; National Institutes of Health, Bethesda, Maryland, USA)

FFA images were aligned to the OCTA images using retinal vascular landmarks and cropped to the corresponding dimensions (3 mm x 3 mm) to facilitate comparison and analysis. The CNV area in early FFA measurement was performed manually using the freehand selection tool of Prime ruler programme. (Android, 2v

Masyukovsch, china str., Minsk). The vessel density of CNV in early phase of FFA and OCTA (outer retina) were measured by the Image J software.

Statistical analysis:

Statistical presentation and analysis of the present study was conducted, using the mean, standard deviation, Paired t-test, Linear Correlation Coefficient and Analysis of variance (ANOVA) tests by Statistical Package for Social Sciences version 20 (SPSS© v. 20.0, SPSS Inc., Chicago, IL, USA). Linear Correlation coefficient was used for detection of correlation between two quantitative variables in one group. ANOVA test was used for comparison among different times in the same group in quantitative data. The level of significant was adopted at p value less than 0.05.

Results:

The study comprised of 20 eyes of 20 Patients; 7 males (35%) and 13 females (65%). Their age ranged from 38 to 60 years with a mean \pm SD was 49.4 ± 5.6 . Spherical Equivalent ranged from - 6.5 diopters to - 16.0 diopters (table 1). Best corrected visual acuity (BCVA) (decimal) ranged from 0.02 to 0.1 with a mean of 0.05 ± 0.02 . All patients diagnosed by FFA and OCTA. According to FFA: CNV was subfoveal in 13 patients (65%), juxtafoveal in 7 patients (35%). According to OCT: All patients were diagnosed with Type II CNV associated with subretinal fluid only in 10 patients (50%), subretinal & intraretinal fluid in 7 patients (35%) and intraretinal fluid only in 3 patients (15%) as in (table 2). OCTA show interlacing vascular network of CNV as 75% of patients (15) were organized interlacing neovascular pattern and 25% of patients (5) were disorganized neovascular loops pattern. The vessel density was significantly higher in OCTA, compared to FFA ($p < 0.001$) as in (table 3). The CNV area was significantly less in OCTA, compared to FFA ($P = 0.012$) as in (table 4). There was non-significant correlation between BCVA as regard Vessel density in OCTA (%) and in early FFA (%) There was non-significant correlation between BCVA as regard CNV area in OCTA (%) and in early FFA (%)

There was significant correlation between BCVA as regard CNV site on FFA ($P = 0.002$) as in (table 5). The BCVA is less in subfoveal CNV than in juxtafoveal CNV. There was significant correlation between BCVA as regard presence of intraretinal & subretinal fluid ($P = 0.005$). There was significant correlation between presence of subretinal fluid as regard presence of SRF&IRF ($P = 0.004$) There was significant correlation between CNV site as regard CNV area in OCTA (mm^2)

Discussion:

In the present study, the mean age was 49.4 ± 5.6 y which near to the results in the study done by Sakhsoukh et al., 2021⁽⁶⁾ who found the mean age was 56.60 ± 14.66 years) comparable to Bruyère et al., 2017⁽⁷⁾, Querques et al., 2017⁽⁸⁾, Bagchi et al., 2019⁽⁹⁾ and Mohsen and Kishk, (2019)⁽¹⁰⁾.

Regarding to sex of the patient, the result of the study cleared that more females were affected with myopic CNV compared to males which was comparable to Bruyère et al., 2017⁽⁷⁾, Querques et al., 2017⁽⁸⁾ study, Mohsen and Kishk, (2019) study⁽¹⁰⁾ Thus, high myopia is more often observed in females, and myopic CNV would be more commonly found in females.⁽¹¹⁾

In the current study, Spherical Equivalent ranged from - 6.5 diopters to - 16.0 diopters with a mean of $- 10.98 \pm 2.87$ diopters which agree with Sakhsoukh et al., 2021⁽⁶⁾ who found that mean spherical equivalent refraction was $- 12.72 \pm 4.75$. Also in another study by LI et al., 2020⁽¹²⁾ The mean spherical equivalent refraction was $- 11.71 \pm 4.80$ D.

In the study done by Wang et al., 2021⁽¹³⁾ the overall pattern of high-flow neovascular network could be categorized into two phenotypes: organized interlacing pattern (83.87%) and disorganized vascular loops pattern (16.13%) which agree with our results.

In our study, CNV was associated with subretinal fluid only in 10 patients (50%), subretinal & intraretinal fluid in 7 patients (35%) and intraretinal fluid only in 3 patients (15%) which partially coincide with Sakhsoukh et al., 2021⁽⁶⁾ who found Spectral domain optical coherence tomography (SD-OCT) showed subretinal fluid in 38 eyes (76.0%) and intra retinal cysts in 18 eyes (36.0%).

Due to FA invasiveness, FA cannot be performed at every visit, and active myopic CNV can sometimes be misdiagnosed on the basis of FA alone. Thus, OCT and OCTA in patients with myopic CNV could both serve as a non-invasive alternative for monitoring CNV and for making treatment decisions during follow-up.⁽¹⁴⁾

As regard to Vessel density, Vessel density in OCTA (the outer retina) ranged from 60.24 - 86.25 % with a mean \pm SD was 73.09 ± 6.07 which near to the results in the study done by Wang et al., 2021⁽¹³⁾ who found the a mean vessel density of 74.49 ± 1.69 also in the study done by Mao et al., 2019⁽¹⁵⁾ the mean vessel density was 42.24 ± 5.9

In the present study, CNV area in OCTA (the outer retina) ranged from 0.3 - 4.2 mm^2 with a mean \pm SD was 1.4 ± 1.1 . While CNV area in early FFA ranged from 0.3- 7.8 mm^2 with a mean \pm SD was 2.5 ± 2.0 while in the study done by LI et al., 2020⁽¹²⁾ CNV area in OCTA (the outer retina) ranged from (0.23 to 1.26) mm^2 with a

mean \pm SD was 0.62 ± 0.58 . While CNV area in early FFA ranged from 0.02 to 1.17 mm² with a mean \pm SD was 0.30 ± 0.43

In our study, The CNV area was significantly less in OCTA, compared to FFA which agree with Chhablani et al., 2015⁽¹⁶⁾. This supports that FFA has more consensus between the clinicians for making a diagnosis of myopic CNV. This is similar to the previously reported studies in cases of CNV secondary to age-related macular degeneration, as well as myopic CNV.⁽¹⁷⁾ Milani et al., 2013⁽¹⁸⁾ reported overall agreement of 0.53 between the observers for FFA in eyes with myopic CNV.

Recommendations:

1. Further studies are necessary to understand the possibility of noninvasive OCTA to completely replace conventional dye tests, avoiding their unpredictable side effects.
2. Larger studies should be performed with long term follow up to determine the prognostic value of OCTA.

References:

1. **Ren P, Lu L, Tang X, Lu H, Zhao Y, Lou D, Han W.** Clinical features of simple hemorrhage and myopic choroidal neovascularization associated with lacquer cracks in pathologic myopia. *Graefe's Archive for Clinical and Experimental Ophthalmology*. 2020 Dec; 258(12):2661-9.
2. **Neelam K, Cheung CM, Ohno-Matsui K, Lai TY, Wong TY.** Choroidal neovascularization in pathological myopia. *Prog Ret-in Eye Res* 2012; 31:495–525
3. **De Carlo TE, Romano A, Waheed NK, Duker JS.** A review of optical coherence tomography angiography (OCTA). *International Journal of Retina and Vitreous*. 2015 Dec 1; 1(1):5.
4. **Coscas GJ, Lupidi M, Coscas F, Cagini C, Souied EH.** Optical coherence tomography angiography versus traditional multimodal imaging in assessing the activity of exudative age-related macular degeneration: a new diagnostic challenge. *Retina*. 2015 Nov 1; 35(11):2219-28.
5. **Spaide RF, Klancnik JM, Cooney MJ.** Retinal vascular layers imaged by fluorescein angiography and optical coherence tomography angiography. *JAMA Ophthalmol*. 2015; 133(1):45–50
6. **Medhat Sakhsoikh M, M Youssef A, Ibrahim Abd El-Ghany AE.** Optical coherence tomography angiography changes in myopic choroidal neovascularization before and after intravitreal ranibizumab injection. *Al-Azhar Medical Journal*. 2021 Apr 1; 50(2):1169-86
7. **Bruyère E, Miere A, Cohen SY, Martiano D, Sikorav A, Popeanga A, Semoun O, Querques G, Souied EH.** Neovascularization secondary to high myopia imaged by optical coherence tomography angiography. *Retina*. 2017 Nov 1; 37(11):2095-101.
8. **Querques L, Giuffrè C, Corvi F, Zucchiatti I, Carnevali A, De Vitis LA, Querques G, Bandello F.** Optical coherence tomography angiography of myopic choroidal neovascularisation. *British Journal of Ophthalmology*. 2017 May 1; 101(5):609-15
9. **Bagchi A, Schwartz R, Hykin P, Sivaprasad S.** Diagnostic algorithm utilising multimodal imaging including optical coherence tomography angiography for the detection of myopic choroidal neovascularisation. *Eye*. 2019 Jul; 33(7):1111-8
10. **Mohsen TA, Kishk HM.** Optical coherence tomography angiography in the diagnosis of choroidal neovascular membrane. *Journal of the Egyptian Ophthalmological Society*. 2019 Jul 1; 112(3):108
11. **Mushiga Y, Minami S, Uchida A, Nagai N, Suzuki M, Kurihara T, Sonobe H, Ban N, Watanabe K, Shinoda H, Tsubota K.** Hyperreflective Material in Optical Coherence Tomography Images of Eyes with Myopic Choroidal Neovascularization May Affect the Visual Outcome. *Journal of Clinical Medicine*. 2020 Aug; 9(8):2394.
12. **Li S, Sun L, Zhao X, Huang S, Luo X, Zhang A, Chen C, Wang Z, Liu C, Ding X.** Assessing the activity of myopic choroidal neovascularization: comparison between optical coherence tomography angiography and dye angiography. *Retina (Philadelphia, Pa.)*. 2020 Sep;40(9):1757-64.
13. **Wang Y, Hu Z, Zhu T, Su Z, Fang X, Lin J, Chen Z, Su Z, Ye P, Ma J, Zhang L.** Optical Coherence Tomography Angiography-Based Quantitative Assessment of Morphologic Changes in Active Myopic Choroidal Neovascularization During Anti-vascular Endothelial Growth Factor Therapy. *Frontiers in Medicine*. 2021 May 7; 8:586.
14. **Lee DH, Kang HG, Lee SC, Kim M.** Features of optical coherence tomography predictive of choroidal neovascularisation treatment response in pathological myopia in association with fluorescein angiography. *British Journal of Ophthalmology*. 2018 Feb 1; 102(2):238-42
15. **Mao J, Shao Y, Liu C, Zhang C, Chen Y, Zhang Y, Xu Z, Shen L.** Optical coherence tomography angiography of myopic choroidal neovascularization treated by anti-VEGF therapy. *Research Square*.2019;1-13
16. **Chhablani J, Deepa MJ, Tyagi M, Narayanan R, Kozak I.** Fluorescein angiography and optical coherence tomography in myopic choroidal neovascularization. *Eye* 2015 Apr; 29(4):519-24.

17. Mokwa NF, Ristau T, Keane PA, Kirchof B, Sadda SR, Liakopoulos S. Grading of age-related macular degeneration: comparison between color fundus photography, fluorescein angiography, and spectral domain optical coherence tomography. *J Ophthalmol.* 2013; 385915.
18. Milani P, Massacesi A, Setaccioli M, Moschini S, Mantovani E, Ciaccia S, Bergamini F. Sensitivity of fluorescein angiography alone or with SD-OCT for the diagnosis of myopic choroidal neovascularization. *Graefes Arch Clin Exp Ophthalmol* 2013; 251 (8): 1891-1900

Table (1): Spherical Equivalent

Spherical Equivalent	Patient (n=20)
Mean ± SD	-10.981 ± 2.866
Range	(- 6.5) – (-16)

n: number

Table (2): OCT association

OCT association		
	N	%
Subretinal fluid	10	50
Intraretinal fluid	3	15
SRF & IRF	7	35
Total	20	100

N: number

SRF: subretinal fluid

IRF :intraretinal fluid

Table (3): Vessel density (%) in patients

	Vessel density			Differences		Paired Test	
	Range	Mean ± SD	Mean	SD	t	P-value	
Vessel density in OCTA (%)	60.24 - 86.252	73.093 ± 6.069	20.336	11.693	7.778	<0.001*	
Vessel density in early FFA (%)	36.234 - 76.378	52.757 ± 11.167					

SD: standard deviation

**: statistically significant*

t: independent samples t-test

Table (4): Area of CNV (mm²) in patients

	Area of CNV			Differences		Paired Test	
	Range	Mean ± SD	Mean	SD	t	P-value	
Area of CNV in OCTA (mm ²)	0.3 - 4.2	1.411 ± 1.119	-1.085	1.741	-2.786	0.012*	
Area of CNV in early FFA(mm ²)	0.29 - 7.79	2.496 ± 2.027					

**: statistically significant*

SD: standard deviation.

t: independent samples t-test

Table (5): Correlation between BCVA and CNV site

	CNV site on FFA						T- Test	
	Subfoveal			Juxtafoveal				
	Mean	±	SD	Mean	±	SD	t	P-value
BCVA (decimal)	0.044	±	0.014	0.070	±	0.018	-3.525	0.002*

*: statistically significant SD: standard deviation. t: independent samples t-test

Case (1):

Female patient, 47 years old, with negative medical history. Complain: dropping of vision in her right eye. Refraction is -9.00 D. Her BCVA was 0.05 decimal.

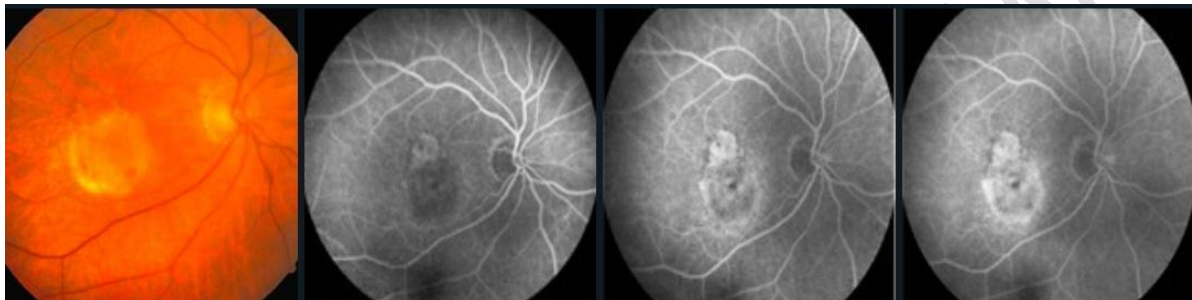


Figure 1: Color fundus photograph shows tessellated fundus in a high-myopic patient with macular lesion. FFA shows hyper fluorescent lesion and increasing hyperfluorescence along phases of angiogram associated with late dye leakage. Indicating the presence of an active subfoveal myopic CNV.

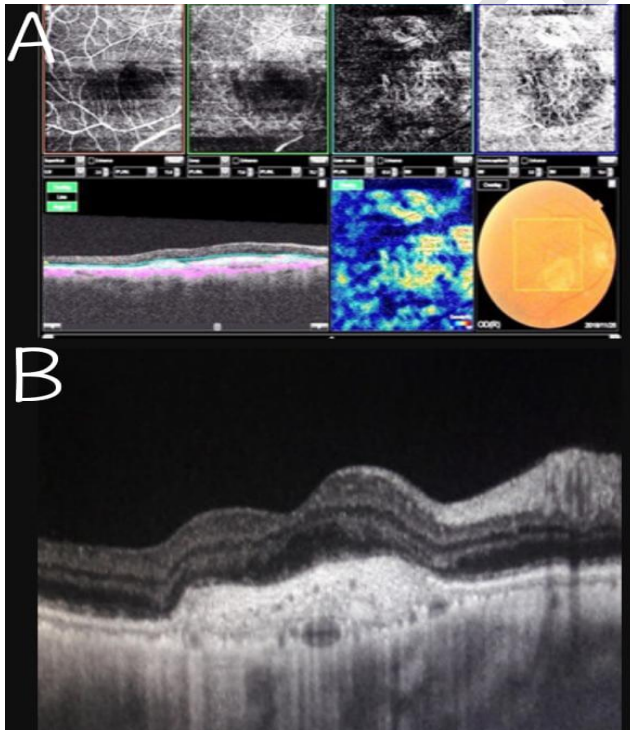


Figure 2: (A):OCTA(3x3mm) showing sharply defined, dense organized interlacing neovascular network in Outer retina. Correspond to active myopic type II CNV. (B): Spectral-domain OCT show a hyper-reflective lesion with subretinal & intraretinal fluid.Suggestive of an active typeII CNV.

Case (2):

Male myopic patient, 55 years old, with history of hypertension since 7 years. Complain: dropping of vision in his left eye. Refraction - 6.50 D. BCVA was 0.085 decimal.

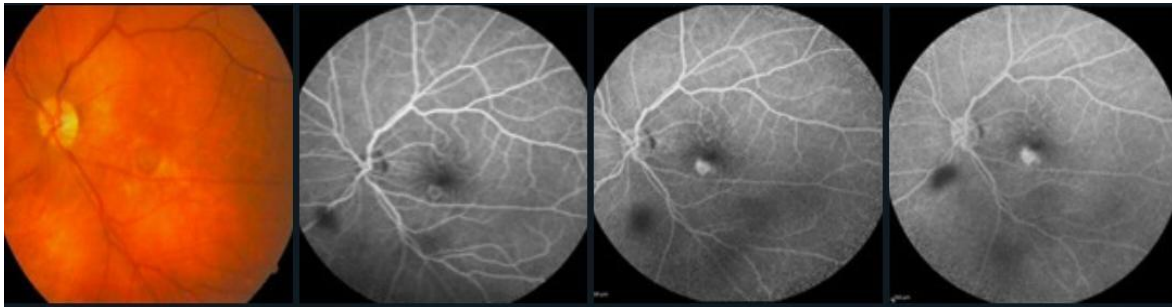


Figure 3: Color fundus photograph shows macular lesion. FFA shows early hyperfluorescence in early phase with minimal leakage in the late phase. Indicating the presence of an active myopic juxtafoveal CNV.

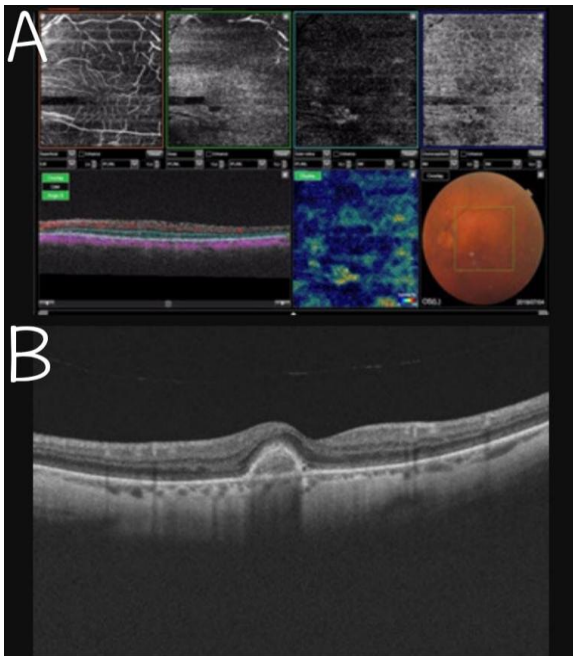


Figure 4:(A): OCTA(3x3mm)showing sharply defined, small,disorganized vascular loop showing irregular blood flow and a small tree bud shape. Correspond to active typeII CNV.
(B): OCT Spectral-domain show a hyper-reflective lesion with a small amount of intraretinal fluid. Suggestive of active typeII CNV.