

Conjunctival Pyogenic Granuloma Associated with Untreated Eye Stye : A Case Report

ABSTRACT

Introduction: To report a case of conjunctival pyogenic granuloma (PG) associated with untreated eye stye that was successfully treated with corticosteroids.

Presentation of Case: 69 years old male was presented with redness and foreign body sensation (FBS) on his left eye (LE) that had lasted for a week. He has no history of eye trauma but he had eye stye one month earlier, which was left untreated and unintentionally ruptured. Visual acuity (VA) of 6/7,5 was measured on LE with normal intraocular pressure (IOP). Anterior segment evaluation found conjunctival vascular injection (CVI) on the bulbar conjunctiva and sessile mass of granulation tissue on the superior tarsal conjunctiva. He was treated by oral and topical corticosteroids with tapering dose. After five weeks of treatment, significant improvements were observed in the eye symptoms together with decreasing granuloma size, i.e., smaller and thinner without recurrence.

Discussion: PG is diagnosed through clinical presentations supported by the patient's historical predisposing factors. Corticosteroid therapy can effectively reduce the size of PG with relatively simple procedure. However, it requires close monitoring of the IOP and tapering dose to anticipate the potential side effects. Surgical excision and histological evaluation are considered if the lesions cannot be resolved by corticosteroid therapy.

Conclusion: Combined oral and topical corticosteroids therapy is recommended as an initial treatment for PG patients.

Keywords: Conjunctival pyogenic granuloma; eye stye; foreign body sensation; conjunctival vascular injection; oral corticosteroid; topical corticosteroid; combined therapy.

1. INTRODUCTION

Pyogenic granuloma (PG) is a benign vascular tumor that is commonly encountered in clinical practice. It is an acquired vascular lesion usually found on the skin and mucosal surfaces. Ocular PG is also known as lobular capillary hemangioma, which can typically develop on the palpebral or bulbar conjunctiva following any form of inflammatory insults inclusive of post ocular or adnexal surgery, chalazion or eye stye rupture, ill-fitting ocular prosthesis and after accidental trauma [1,2].

Retrospective study by Elshazly in Cairo, Egypt reported the most frequently identified excised conjunctival lesions was classified as PG, taking 30.7% (59 cases) of the total cases. Among the diagnosed PGs, 20.3% of the cases develop on the palpebral conjunctiva following chalazion excision and 27.2% of the cases are diagnosed on the bulbar conjunctiva, which are attributed to pterygium excision (20,3%), squint surgery (1,8%) and trauma (5,1%), while the remaining 52.5% of the cases were reported with no specific etiology. PGs can occur at any age with the occurrence peaked in the second decade of life and are more commonly found in males [3].

Pyogenic granuloma is an inflammatory lesion composed of granulation tissues. It is an example of excessive or abnormal wound healing reactions typically encountered in the clinical setting of a poorly

apposed wound. It usually occurs spontaneously and grows rapidly. It may appear in small or large size, smooth or rough texture, sessile or pedunculated, or as reddish exophytic vascular nodules. PG tends to bleed heavily. Bleeding is of great concern for most of PG patients. The affected tissue is usually the eyelid or conjunctival skin [4,5].

The common medical complaints include foreign body sensation (FBS), inflammation, discharge, unsightly mass, and infrequent pain. There are numerous treatment options for ocular surface PG, i.e., excisional surgery, cryotherapy, electrocautery, laser ablation, and medical therapy, e.g., topical and oral corticosteroids [1,2,6].

We present one case of conjunctival pyogenic granuloma associated with untreated eye stye history, which developed about a month after eye stye rupture. Clinical findings on conjunctival pyogenic granuloma and its treatment are discussed in this report.

2. PRESENTATION OF CASE

This is a single case study, which has been approved by the Ramata Eye Hospital Denpasar. The patient was treated and monitored closely from August 2021 to September 2021.

A 69 years old male presented with redness and foreign body sensation (FBS) on his left eye (LE), which had lasted for a week before the patient admission. The redness was not accompanied by discharge, itchiness, decrease of VA, or systemic symptoms, e.g., fever, nausea, or others. He neither had history of any trauma nor similar presentation in the past. He had history of eye stye about a month earlier, but it was left untreated and unintentionally ruptured. Patient has hypertension and regularly takes antihypertensive medications.

Upon examination, his visual acuities (VA) were measured at 6/9,5 for right eye (RE) and 6/7,5 for LE, but the best-corrected visual acuity (BCVA) both eyes was 6/6 with his current spectacles. Intraocular pressure level (IOP) was normal, at 15 mmHg for RE and 19 mmHg for LE. From anterior segment examination on LE, a sessile mass of granulation tissue on superior tarsal conjunctiva was found. It measures at 1 cm x 0.5 cm x 0.3 cm with broad base. The mass was fleshy, rough, and the color was bright red without bleeding. The margins of the upper eyelid were clear. Conjunctival vascular injection (CVI) was found in the bulbar conjunctiva. The cornea was relatively clear with no epithelial defects. His Iris had normal color and pattern. His pupillary light reflex was also found to be normal. No noticeable changes can be seen in his lens. Posterior segment was within normal limits and the RE was also in normal condition.

Based on the key features observed in the patient, i.e., sessile mass of granulation tissue, red and present on mucosal surface (conjunctiva), and rapid growth, the clinical diagnosis of conjunctival pyogenic granuloma was made. The qualitative assessments and the measured data support the presumption of the untreated eye stye being the main risk factor of the granuloma on the tarsal conjunctiva.

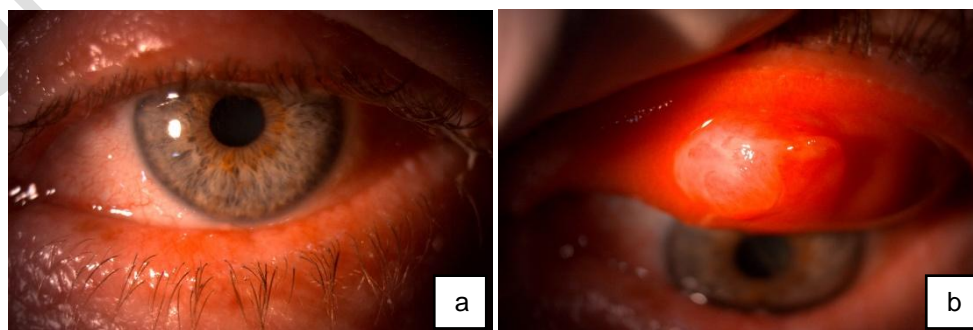


Fig. 1. Anterior segment examination. (a) Conjunctival vascular injection in bulbar conjunctiva, (b) Granuloma in superior tarsal conjunctiva

The patient was treated by anti-inflammatory drugs, i.e., oral and topical corticosteroid, for five weeks with tapering dose. He was also treated with antibiotic eyedrop as prophylaxis in first 2 weeks and artificial tears eye drop as a lubricant. The corresponding dose of the drugs and eye drops are summarized in the following table.

Table 1. Medications and tapering dose of corticosteroids

Period	The dose of corticosteroids		Eye drop	
	Oral - Methylprednisolone (mg/day)	Topical - Prednisolone Acetate (drops/day)	Artificial Tears	Antibiotic
Week 1	24	6	✓	✓
Week 2	12	6	✓	✓
Week 3	8	4	✓	×
Week 4	4	2	✓	×
Week 5	4	1	✓	×

This patient came to the clinic once a week to undergo clinical evaluation and IOP monitoring because of the long-term corticosteroid therapy. The measured IOP during the therapy was in the range of 19-20 mmHg with the maximum IOP of 20 mmHg was measured on LE on his final visit, while the IOP of the RE was normal throughout the therapy, i.e., 15-18 mmHg. After five weeks of treatment, there were significant improvement in the symptoms and the granuloma size. The redness was no longer observed and the patient felt gradual decrease of FBS. In the examination of the anterior segment, the CVI was absent and the granuloma became thinner and smaller. There were no local or systemic adverse events observed in this patient until the last therapy and was no recurrence after 2 months.

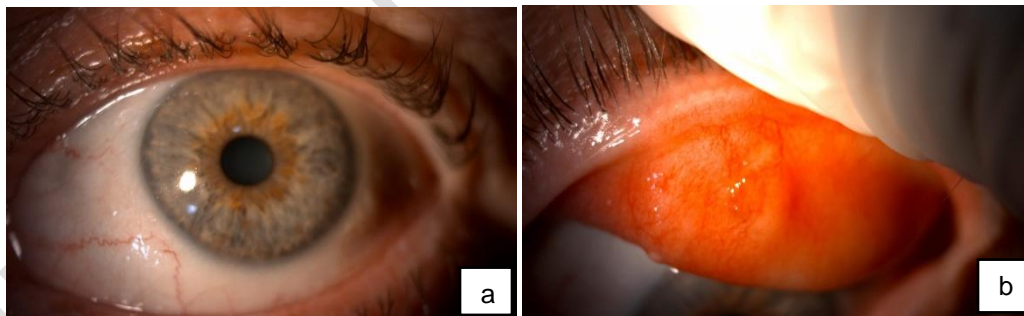


Fig. 2. Anterior segment examination after 5 weeks of steroid anti-inflammation therapy (a) no found CVI at bulbar conjunctiva, (b) decrease size of granuloma significantly in superior tarsal conjunctiva

3. DISCUSSION

Pyogenic granulomas represent benign, acquired, vascular tumors, usually seen following an episode of inflammation potentially induced by various causes such as ocular or adnexal surgery, chalazion or eye stye rupture, and eye trauma. It usually denotes sequelae of incomplete surgical or traumatic wound healing [1,5].

Pyogenic granulomas are generally diagnosed through clinical presentations and patient's medical history with associated predisposing factor. It can also be confirmed histologically. They often bleed, cause discomfort, and appear unsightly, prompting patients to seek treatment. In clinical findings, the lesions generally appear as single, bright red, pedunculated papules those are very brittle or may appear as sessile plaques as observed in this case. It exhibits rapid growth and often affects ocular mucous membranes [4,7]. In this case, CVI was also found in the bulbar conjunctiva due to conjunctival irritation, which was probably caused by the granuloma mass rubbing against the conjunctival surface while blinking. In this case, the occurrence of PG is suggested to be potentially due to untreated eye stye, which resulted in incomplete healing process.

Many ophthalmologists may diagnose these conjunctival masses as pyogenic granulomas (PGs) because of their appearance. However, according to the histopathologic findings the term PG is misnomer because it does not include inflammatory (purulent) exudate or the epithelioid giant cell reaction typically found in granulomatous inflammation. It is a lesion composed of granulation tissue, similar to wound healing. Histopathological findings of PG are indicated by acute and chronic mixed inflammatory cells with lobular pattern of capillary proliferation. Acute and chronic inflammatory cells are frequently interspersed between fibrovascular elements [8,9].

The etiology of PGs anywhere on the body has not been clearly understood. This is suggested to be due to an imbalance between pro-angiogenic and anti-angiogenic factors during wound healing. PG is hypothesized to occur secondary to local tissue hypoxia in traumatized endothelial cells, resulting in the expression of growth factors such as vascular endothelial growth factor and basic fibroblast growth factor, resulting in abnormal healing and ultimately believed to result in mass formation. It is plausible that conjunctival PG formation can be due to angiogenic imbalance during wound healing [10]. Increases in growth factors of vascular endothelial, basic fibroblast, and connective tissue have been associated with the clinical manifestations of the rapid growth of the mass. Nakamura reported on a comparative study showing that PGs have lower apoptosis rate and higher frequency of Bax/Bcl2 protein expression than granulation tissue that recedes into scar tissue [9,11].

Treatment options for PG include surgical excision, cryotherapy, electrocautery, laser ablation, medical therapy and observation. However, due to its relatively simple implementation and yet high success rate, corticosteroid is the treatment of choice in most cases. As a first approach, corticosteroids are recommended, especially for less cooperative patients, as they have a lower side effect profile than conventional surgical treatments. Corticosteroid also reduces the size of the PG prior to surgical excision, thereby minimizing the risk of additional scar tissue [5,6]. Espinoza and Lueder reported that topical corticosteroid shows a 90% success rate in the treatment of conjunctival PG. The average duration of topical therapy in their cohort is reported around 30 days, with some patients requiring treatment up to 80 days [9,12].

Most corticosteroids used in ophthalmology are glucocorticoids, which have anti-inflammatory and immune-suppressive activity. Topical prednisolone was used for this patient treatment, which is a synthetic glucocorticoid, while oral methylprednisolone was used as a systemic synthetic corticosteroid. The anti-inflammatory effect of corticosteroids is caused by inhibiting the transcription of inflammatory and immune genes. These actions block the release of arachidonic acid and subsequent eicosanoids (prostaglandins, thromboxane, prostacyclin, leukotrienes). This affects the blood-retinal barrier with a reduction in fibroblast proliferation, collagen and scar formation, fibrin deposition, capillary leakage, and levels of vascular endothelial growth factor [13].

Surgical excision is highly recommended for patients who do not respond to corticosteroids. Surgical biopsy and histological examination are also recommended in case of non-responsiveness, recurrence, or clinical uncertainty [5].

Topical corticosteroid therapy is arguably more convenient than most of the available treatments, but it is not without side effects. Topical corticosteroids are known to cause an increase in IOP. Long-term use of topical corticosteroids has been shown to cause ocular hypertension with an increase in IOP of 6-15 mm Hg after 4-6 weeks of use in 30% of healthy patients [14]. Therefore, IOP should be monitored regularly,

while employing topical corticosteroids treatment. In this case, the IOP was monitored closely every week and tapering dose of the topical and oral corticosteroid were given to anticipate the side effects. There was a minimum increase of IOP throughout the treatment with the maximum IOP reached 20 mmHg. In this conjunctival PG case, corticosteroid therapy can successfully treat the lesion without significant corticosteroid side effects or recurrence.

4. CONCLUSION

Pyogenic granuloma (PG) is relatively common in clinical practice. Combined oral and topical corticosteroids therapy are recommended as an initial treatment option. Surgical excision and histological evaluation should be considered if the lesions cannot be resolved with corticosteroids therapy.

CONSENT

All authors declare that written informed consent was obtained from the patient for publication of this case report and accompanying images.

ETHICAL APPROVAL

As per international standard or university standard written ethical approval has been collected and preserved by the author(s).

REFERENCES

1. Nair AG, George RJ, Natarajan S, Jain V. Topical timolol for the treatment of conjunctival pyogenic granulomas: Outcomes and effect on intraocular pressure. *Indian J Ophthalmol* 2020;68:2170-4. DOI: 10.4103/ijo.IJO_183_20
2. DeMaria LN, Silverman NK, Shinder R. Ophthalmic pyogenic granulomas treated with topical timolol - Clinical features of 17 cases. *Ophthalmic Plast Reconstr Surg* 2018;34:579-82. DOI: 10.1097/IOP.0000000000001116
3. Elshazly Laila HM. A Clinicopathologic Study of Excised Conjunctival Lesions. *Middle East African Journal of Ophthalmology*. 2011;18(1):48-54. DOI: 10.4103/0974-9233.75886
4. Tidake PK, Jaiswal S, Wagh V. Conjunctival pyogenic granuloma – a case report. *J Evolution Med Dent Sci* 2021;10(02):111-113, DOI: 10.14260/jemds/2021/23
5. Yunjin Lee, Joon YH, Hyun SJ. Conjunctival Pyogenic Granuloma: Cases with Undetermined Etiologies. *Korean J Ophthalmol*. 2019;33(5):483-4. DOI:https://doi.org/10.3341/kjo.2019.0017
6. Oke I, Alkharashi M, Petersen RA, et al. Treatment of ocular pyogenic granuloma with topical timolol. *JAMA Ophthalmol*. 2017;135:383-5. DOI : 10.1001/jamaophthalmol.2017.0110
7. Sagiv O, Piven I, Rosner M. Conjunctival pyogenic granuloma associated with intravitreal bevacizumab injection. *Retin Cases Brief Rep* 2013;7:291-3. DOI : 10.1097/ICB.0b013e31828ef010.
8. Aemero A, Sisay B. Corneal Pyogenic Granuloma: Rare Complication of Infectious Keratitis. *Ethiop J Health Sci*. 2014;24(1):85-8. DOI: http://dx.doi.org/10.4314/ejhs.v24i1.11
9. Espinoza GM, Lueder GT. Conjunctival pyogenic granulomas after strabismus surgery. *Ophthalmology* 2005;112:1283-6. DOI : 10.1016/j.ophtha.2005.01.048

10. Kasturi N, Senthamizh T, Bheemanathi HS, Babu KR. Subconjunctival bevacizumab for recurrent conjunctival pyogenic granuloma. *J Pharmacol Pharmacother* 2019;10:42-4. DOI : 10.4103/jpp.JPP_123_18
11. Nakamura T. Apoptosis and expression of Bax/Bcl-2 proteins in pyogenic granuloma: a comparative study with granulation tissue and capillary hemangioma. *J Cutan Pathol* 2000;27:400–5. DOI : 10.1034/j.1600-0560.2000.027008400.x
12. Wu D, Qian T, Nakao T, Xu J, Liu Z, Sun X, Chu Y, Hong J. Medically uncontrolled conjunctival pyogenic granulomas: correlation between clinical characteristics and histological findings. *Oncotarget*. 2017;8(2):2020-4. DOI : 10.18632/oncotarget.13961.
13. Fung AT, Tran T, Lim LL, et al. Local delivery of corticosteroids in clinical ophthalmology: A review. *Clin Experiment Ophthalmol*. 2020;48:366–401. DOI : <https://doi.org/10.1111/ceo.13702>
14. Jones R 3rd, Rhee DJ. Corticosteroid-induced ocular hypertension and glaucoma: A brief review and update of the literature. *Curr Opin Ophthalmol* 2006;17:163-7. DOI:10.1097/01.icu.0000193079.55240.18

UNDER PEER REVIEW