

## Review Article

### Glaucoma: Diagnosis and Treatment

#### Abstract

Background: Glaucoma is the second most common cause of formal blindness in the United States. Open-angle glaucoma is asymptomatic, progressive optic neuropathy characterized by increased optic disc cupping and loss of visual acuity. Patients at high risk for open glaucoma include blacks over the age of 40, whites over the age of 65, and individuals with a family history of glaucoma or a personal history of diabetes or acute myopia. High intraocular pressure is a strong, variable risk of open glaucoma, but it is not diagnostic. Some patients with glaucoma have normal intraocular pressure (i.e., normal pressure glaucoma), and most patients with high intraocular pressure do not have glaucoma (i.e., suspected glaucoma). A standard measurement of intraocular pressure is not recommended by physicians who care for patients diagnosed with glaucoma. Open-angle glaucoma is usually diagnosed in adults during eye exams. The final diagnosis and treatment is done in collaboration with ophthalmologists and ophthalmologists. The systemic area of visual acuity (perimetry) is the main basis for the diagnosis and management of glaucoma. For eye drops, beta-blockers are usually administered via intravenous or prostaglandin analog drops, which is usually the first treatment to reduce intraocular pressure. Laser therapy and surgery are usually reserved for patients who fail treatment. Without treatment, open angle glaucoma can lead to irreversible vision loss.

Conclusion: Glaucoma represents the challenge of many diseases. Our understanding of the basic pathophysiology of many types of glaucoma remains incomplete.

**Keywords:** *Glaucoma, Chronic disease, Intraocular pressure, Primary Angle Closure Glaucoma.*

#### Introduction

Glaucoma is a group of eye conditions that damage the optic nerve, the health of which is essential for optimal vision. This damage is usually caused by abnormally high pressure in your eye. Glaucoma is one of the leading causes of blindness in people over 60 years of age. It can occur at any age but is more common in adults. Most forms of glaucoma have no warning signs. The effect is so gradual that you will not see a change in vision until the situation reaches its climax. Because glaucoma does not lead to recurrent vision loss, it is important to have regular eye examinations, including measurements of your eye pressure, to get an early diagnosis and treatment. If glaucoma is detected early, vision loss can be reduced or avoided. If you have this condition, you will usually need treatment for the rest of your life (1).

#### Causes and Risk Factors

Glaucoma is the result of damage to the optic nerve. As these sensors malfunction, blind spots appear in your eyes. For reasons that doctors do not fully understand, this type of nerve damage is usually associated with increased pressure in the eye. High eye pressure is caused by the formation of fluid (aqueous humor) flowing inside your eye. This internal fluid is usually secreted through a tissue called the trabecular meshwork at the junction of the iris and the cornea. If fluid is used excessively or the drainage system is not working properly, the fluid cannot go beyond its normal range and eye pressure increases. Glaucoma is more common in families. In some people, scientists have identified genes associated with high eye pressure and damage to the optic nerve. Risks: Chronic forms of glaucoma can detect symptoms or the onset of symptoms, so beware of these risk factors: high internal eye pressure (intraocular pressure), over 60, opacity, Asian or Spanish, having a family history of glaucoma, certain health problems, such as Diabetes, heart disease, high blood pressure and sickle cell anemia, thin cornea in the middle, too much or too far vision, eye injuries or certain types of eye surgery and corticosteroids, especially eye drops, for a long time (2).

### **Pathophysiology**

The mechanisms underlying glaucoma are not fully understood. In many clinical cases, a painless elevation of IOP occurs, which can lead to further damage to the optic nerve and loss of visual acuity. Theoretical mechanical strength (in the juxtacanalicular network) is a prescribed form of glaucoma. Trabecular meshwork (TM) collagen alteration, TM endothelial cell dysfunction, lower membrane stiffness, glycosaminoglycan deposition, decreased intertrabecular spaces, and / or Schlemm's duct collapse may occur. Experimental and clinical studies indicate that progressive IOP can cause optic nerve damage, such as primary open-angle glaucoma (POAG), supporting the role of IOP. Vascular risk factors and the role of optic nerve perfusion may be important. The blood supply to the optic nerve, the metabolism of axonal or ganglion cells, and the extracellular matrix of the lamina cribrosa may play a role. This is especially important for a small group of people with chronic low-voltage glaucoma despite an IOP below 21 mm Hg (3).

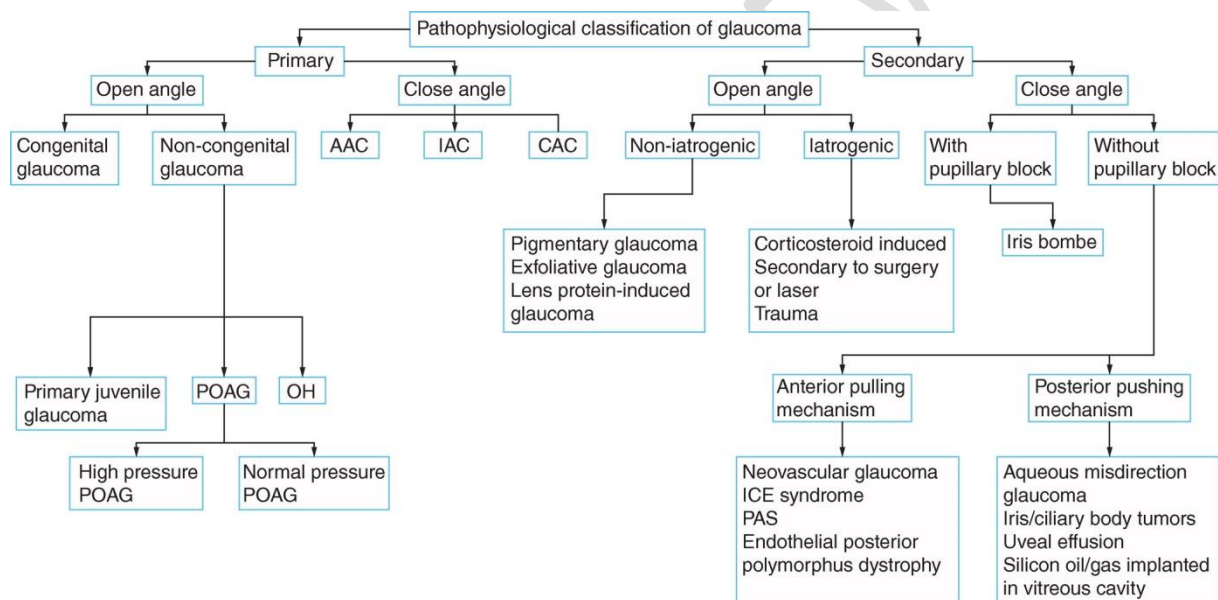
The incidence of optic nerve damage varies from person to person. In addition to other risk factors, it depends on the level of IOP. Certain historical and demographic factors, including age, race, family history and eye history, have been shown to be highly correlated with the disease. The sleeping space also plays a role; as it was shown that normal sleeping positions lead to higher levels of IOP in patients with pigmentation. Birth defects, especially optic nerve or concurrent vascular insufficiency, may be the root cause of patient findings and subsequent diagnosis of glaucoma. It is important that there is a continuum (4).

### **Classification**

The types of glaucoma are: Angle glaucoma is the most common form of the disease. The drainage angle formed by the cornea and iris remains open, but the trabecular meshwork is slightly blocked. This will gradually increase the pressure on your eyes. This pressure damages the optic nerve. It happens so slowly that you may lose track of the problem before you know it. Angle-closure glaucoma, also known as angle-closure glaucoma, when the iris further ruptures to reduce or block the drainage angle formed by the cornea and iris. As a

result, the fluid cannot circulate in the eye and the pressure rises. Some people have a small drainage angle, which increases the risk of angle-closure glaucoma. Angle-closure glaucoma can occur spontaneously (acute angle-closure glaucoma) or phased (chronic angle-closure glaucoma). Acute angle loss glaucoma is an emergency disease. Normal-tension glaucoma: In normal-tension glaucoma, the optic nerve is damaged even when the intraocular pressure is within the normal range. No one knows the exact reason for this. You may have severe optic nerves or poor blood supply to the optic nerves. This restricted blood flow can be caused by atherosclerosis, the formation of fat (plaques) in the arteries, or in other cases obstructing blood flow (5).

Glaucoma in children: Infants and children may have glaucoma. It may be present at birth or in the first few years of life. Damage to the optic nerve can result from fluid retention or poor health. Pigmentary glaucoma: In pigmentary glaucoma, pigment granules in the iris form in the waterways, reducing or blocking fluid entry into the eye. Functions such as race sometimes move the pigment granules, placing them in the trabecular meshwork and sometimes creating more pressure (figure 1) (6).



**Figure 1 Classification of Glaucoma (6)**

## Signs and Symptoms

Glaucoma symptoms vary depending on the type of glaucoma you have. You should see a doctor as soon as you notice any signs of glaucoma. It is also important to have your eyes examined regularly, as open-angle glaucoma usually doesn't show any symptoms until the damage is done. Common symptoms of open-angle glaucoma: Open-angle glaucoma will not show any symptoms until you have lost your sight. Vision loss usually begins on the sides of your field of vision, leads to tunnel view, and spreads to the center of your field of vision. Common symptoms of angle or acute glaucoma: Angle closure glaucoma usually indicates a sudden onset of symptoms. Sometimes any of these symptoms can be very serious: abdominal pain (vagus nerve stimulation), eye pain, halos visible near lights, headache associated with

eye symptoms, loss of vision or visual disturbances, nausea or absence of vomiting, redness, pain in the eyes (bloody eyes) (7).

**Common Symptoms of Congenital Glaucoma:** Congenital glaucoma is present at birth, although the symptoms usually do not appear for a few months. Symptoms include: clear cornea, hair loss (front of the eye), increased sensitivity to light, redness, sore eyes (bleeding from the eyes), swelling of one or both eyes, general symptoms of secondary glaucoma: Symptoms of secondary glaucoma appear as open eyes. The angle or angle of closure of glaucoma depending on the cause. Secondary glaucoma may occur as a result of certain medications, medical procedures, or other medical conditions. Symptoms that indicate a serious condition: Acute narrow-angle glaucoma is a serious condition and should be evaluated immediately in an emergency. If you have any of the following serious symptoms: blurred vision, eye pain, visible halos, headache, loss of vision and nausea with or without vomiting (8).

### **Complications**

The potential complications of glaucoma are not fatal. However, if left untreated, glaucoma can lead to serious vision problems, even blindness. You can help reduce the risk of serious complications by getting immediate medical help and following your personal treatment plan and design plan. Complications of glaucoma include: chronic glaucoma (loss of vision), moderate or partial (partial) loss of vision, and vision loss or blurred vision. May have different symptoms. Adults with glaucoma. Can cause pediatric glaucoma: sensitivity to light, cloudy cornea, large eye (condition can be seen in picture before detection), severe stress, loss of vision. In addition to eye-related symptoms, some children may be associated with this system. . Symptoms Children may be very restless, may not like food, or may start vomiting. These symptoms are associated with angle closure and can be relieved by reducing the pressure in the eye. Symptoms of congenital glaucoma (from birth) can appear as soon as the baby is 1 month old (9).

**Chronic symptoms of congenital glaucoma:** Blinking, sadness, avoidance of light, congenital glaucoma can develop if the fluid system of the eye is inadequate and requires treatment, traumatic glaucoma, traumatic glaucoma It can happen to anyone, but it is usually related to sports. Also, if the ball or bat hits someone in the eye, blunt trauma can cause eye bleeding. Plasma and other residues can block the fluid system of the eye and increase intraocular pressure. Acute eye damage can lead to delayed glaucoma. The pressure may be low at first, but when the wound closes, it begins to swell and the pressure rises, causing glaucoma. Trauma can rupture in the space between the iris and the cornea, a tissue they know, leading to a reduction in glaucoma, which ultimately leads to glaucoma. Be sure to report an eye injury to an ophthalmologist, as acute glaucoma can occur after 10 to 20 years or more. If treatment is too late, symptoms usually do not appear until vision is lost. Other symptoms to watch out for include eye pain, nausea, vomiting, and sudden loss of vision. These problems can occur immediately after an injury or years later. Symptoms indicate elevated intraocular pressure and require immediate attention (10).

### **Diagnosis**

Your eyes need to be checked regularly. You should have a basic eye examination at age 40. The first symptoms of eye disease and changes in vision may begin to occur in recent years. Your dentist will tell you that you usually do follow-up tests based on the results of those tests. If you have high risk factors for glaucoma, diabetes, high blood pressure or a family history of glaucoma, you should see an eye doctor now to determine how often you should check your eyes (11).

## Tonometry

Tonometry measures the pressure inside the eye. During tonometry, eye drops are used to detect the eye. The doctor or ophthalmologist then uses an instrument called a tonometer to measure the internal pressure in the eye. Light pressure is applied to the eye with a small device or air heater. Normal pressure range is 12-22 mmHg. ("MmHg." Most glaucoma patients have blood pressure above 20 mmHg. However, some people can develop glaucoma at 12-22 mmHg. Eye pressure varies from person to person (figure 2) (12).

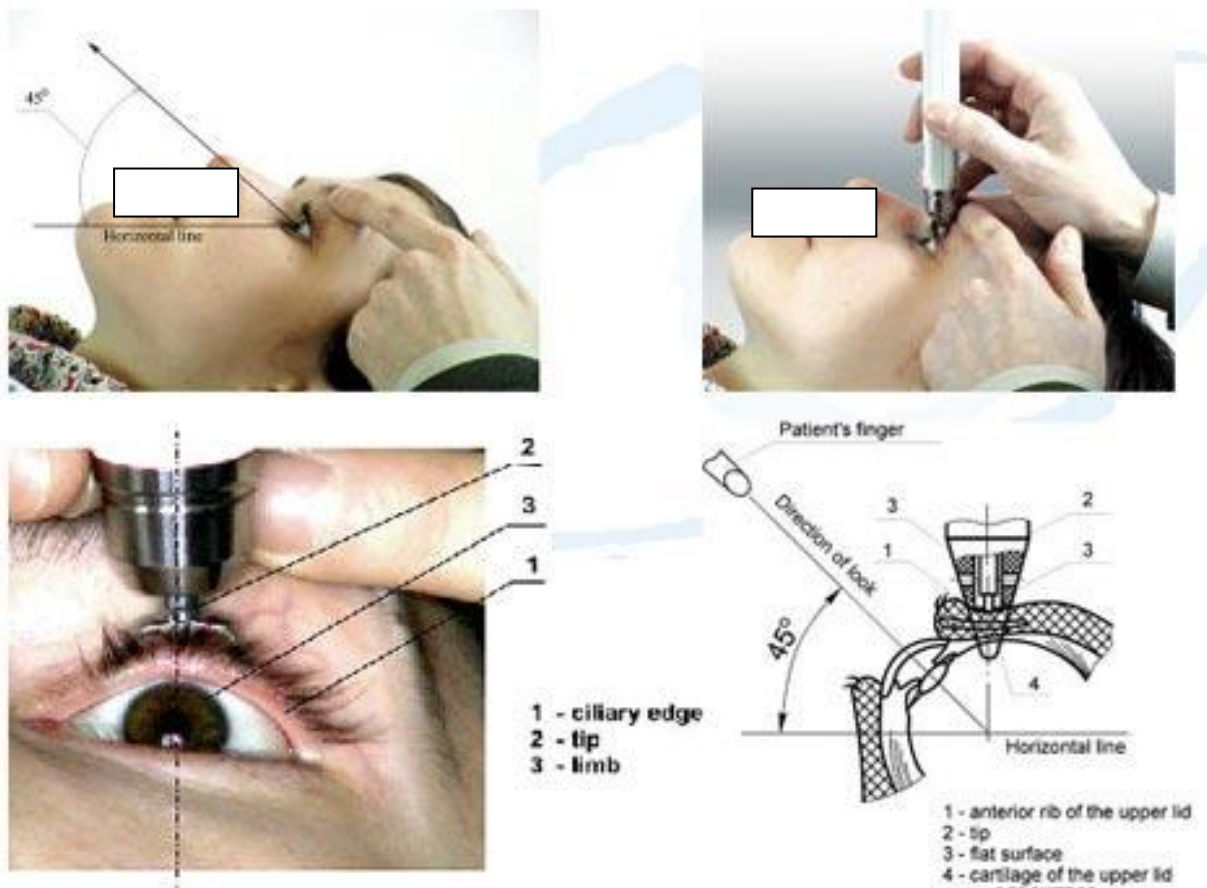
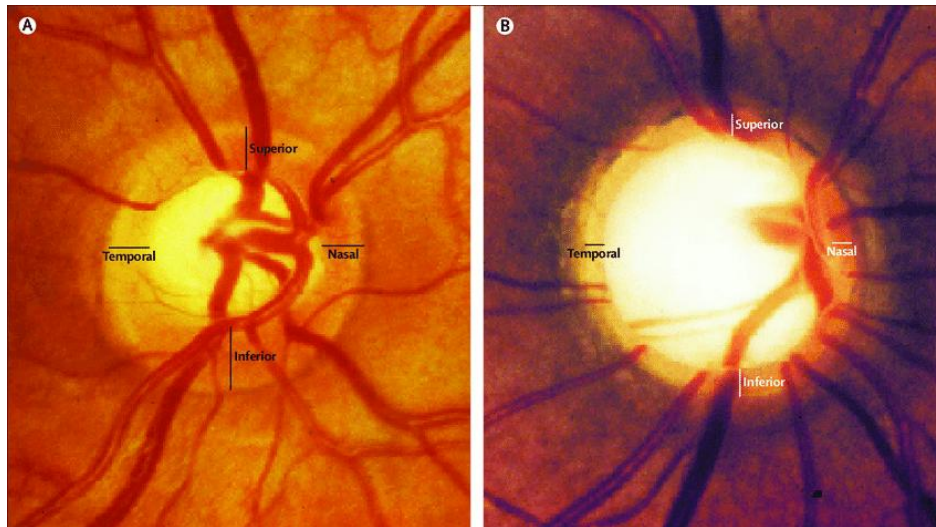


Figure 2 Tonometry (12)

## Ophthalmoscopy

This diagnostic procedure helps the doctor examine your optic nerve for glaucoma damage. Eye drops are used to enlarge the pupil so that the doctor can examine the size and color of the optic nerve in your eye. The doctor will then use a small light device to brighten and enlarge the optic nerve. If your intraocular pressure (IOP) is not within normal range or if the

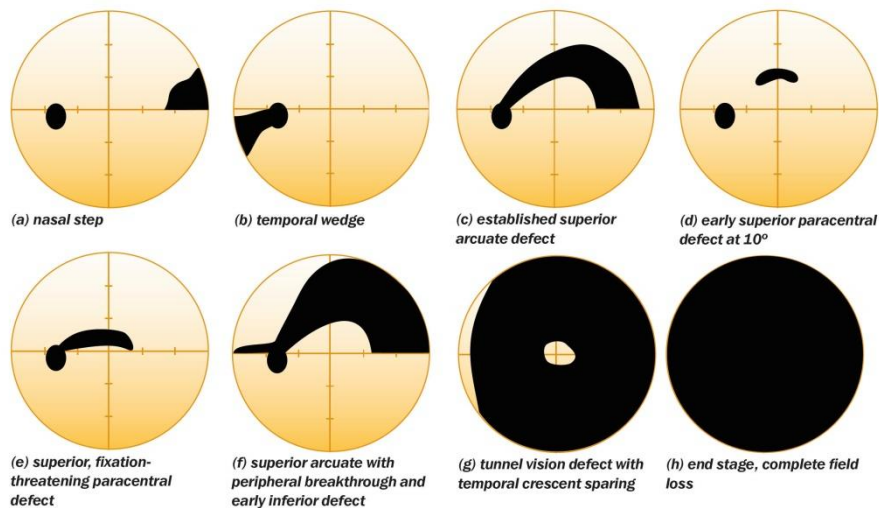
optic nerve appears abnormal, your doctor may ask you to perform one or two tests for glaucoma: perimetry and gonioscopy (figure 3) (13).



**Figure 3 Ophthalmoscopic images of healthy optic discs and glaucomatous Optic Images were taken with the right eye. (A) In a healthy optic disc, the neuroretinal rim has its normal shape with its widest part in the subcutaneous area, followed by the upper and lower nasal region, and finally the temporal region. (B) In the glaucomatous optic disc, the neuroretinal rim is surprisingly thinner than in a healthy optic disc, and the optic cup becomes larger next, and the cup is deeper (13).**

### **Perimetry**

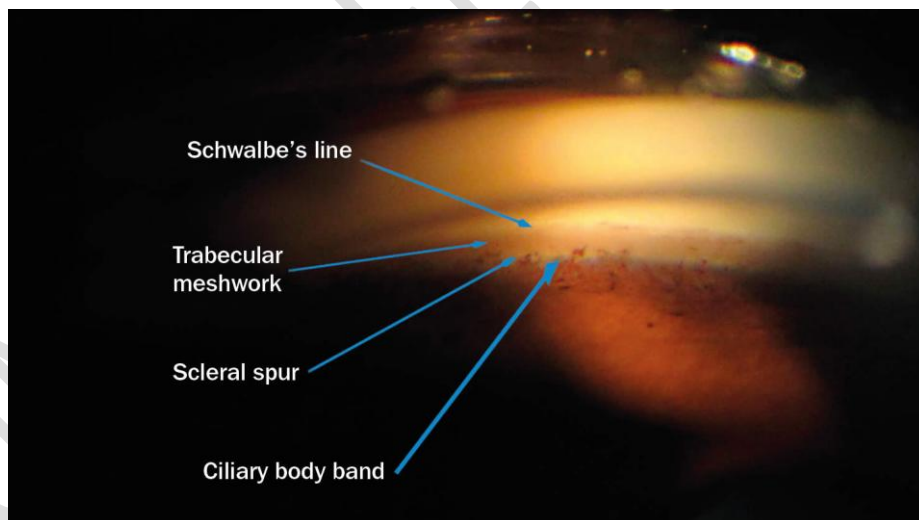
Perimetry is a visual field test that maps the entire visual field. This test will help your doctor determine if your eyesight is affected by glaucoma. During this test, bright spots repeatedly appear in different areas of the side view and are encouraged to look forward to. It helps to create a "map" of your thoughts. Don't worry if the blind spot or the light around the blind spot is delayed. This is normal and does not mean that your eyesight is impaired. During the test, relax and try to be as accurate as possible. Your doctor may need to look at you again to see if the results are the same as what you were taking. After diagnosing glaucoma, visual aids are usually used once or twice a year to check for changes in vision (figure 4) (14).



**Figure 4 Perimetry (14)**

### Gonioscopy

This diagnostic test helps determine if the angle at which the iris cornea meets is open and wide or narrow and closed. During the test, eye drops are used to numb the eye. The hand-held contact lens is gently placed over the eye. This contact lens contains a mirror that shows the doctor whether the angle between iris and cornea is closed and closed (closed angle, possible sign of acute glaucoma) or wide and open (open angle, possible sign of chronic glaucoma) (figure 5) (15).

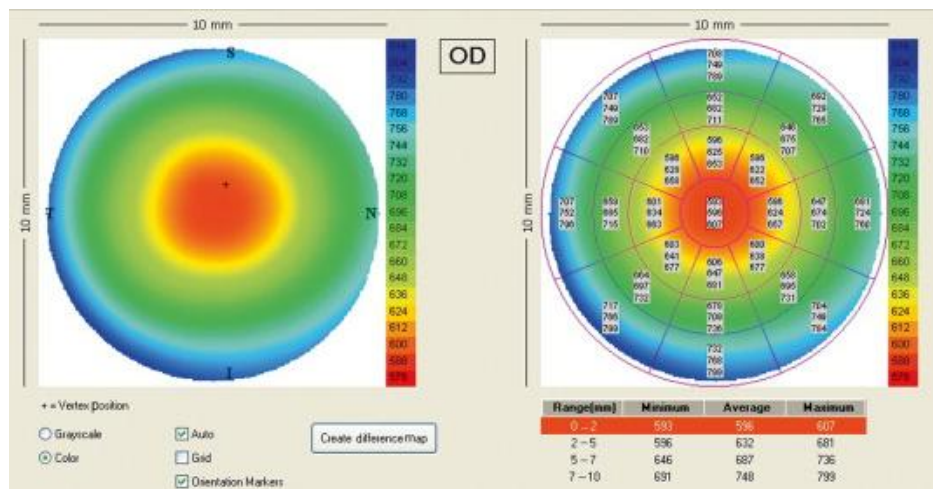


**Figure 5 Gonioscopy (15)**

### Pachymetry

Pachymetry is a simple and painless exercise for measuring the thickness of the cornea, the transparent window in front of you. A probe called a patch meter is lightly placed in front of you (cornea) and its thickness is measured. Patch metry is useful for diagnosis because the size of the cornea can affect the study of intraocular pressure. At this rate, your doctor will be

able to better understand your IOP readings and develop the correct treatment plan for you. The procedure takes only 1 minute to measure both eyes (figure 6) (16).



**Figure 6 Pachymetry (16)**

## Treatment

Damage caused by glaucoma is irreversible. However, regular treatment and testing can help delay or prevent vision loss, especially if you have an early infection. Glaucoma is treated by lowering the intraocular pressure (intraocular pressure). Depending on your condition, your options may include eye drops, oral medications, laser treatment, surgery, or a combination of these, as directed by your doctor. Eye drops: Treatment for glaucoma usually begins with eye drops prescribed by a doctor. This helps reduce intraocular pressure by improving the flow of fluid from the eye or by reducing the amount of fluid produced by the eye. Multiple eye drops may be needed depending on low intraocular pressure. Prescription eye drops include the following. Prostaglandins: These increase the flow of water from the eye (aqueous humor) and reduce intraocular pressure. Drugs in this category include latanoprost, travoprost (Travatan Z), tefluprost, bimatoprost, and letanoprostin bonodo. Possible side effects include mild redness and itching of the eyes, darkening of the iris, darkening of the eyelids or eyelid skin, and hazy eyes. This range of drugs has been shown to be used once daily (17).

Beta blockers: This reduces the production of water in the eye and reduces eye pressure (intraocular pressure). Examples are timolol (istalol, timoptic) and betaxolol. Possible side effects include shortness of breath, low heart rate, low blood pressure, weakness, and malaise. This class of medication may be prescribed once or twice daily, depending on your condition. Alpha adrenergic agonists: These reduce the production of aqueous jokes and increase the secretion of water from the eyes. Examples are applaclonidine (iopidine) and brimonidine (alphagan P, qoliana). Possible side effects include arrhythmia, high blood pressure, malaise, redness, itching and swelling of the eyes and mouth. This range of medications is usually prescribed to be used twice daily, but may be used three times daily. Organic anhydrase inhibitors: These drugs reduce the production of water in the eye. Examples include dorzolamide (Trusopt) and brinzolamide (Azopt). Possible side effects include iron taste, pollakiuria, and tingling fingers and toes. This range of medications is usually prescribed to

be used twice daily, but may be used three times daily. Rho-kinase inhibitors: This drug reduces intraocular pressure by suppressing the rho-kinase enzymes involved in water retention. Available as netarsudil (Rhopressa), it is prescribed for once-daily use. Possible side effects include redness of the eyes, discomfort of the eyes, and formation of the cornea (18).

Miotic or cholinergic agents: These increase the flow of fluid through your eye. An example is isopto carpine. Side effects include headache, blurred vision, small pupils, possible or blurred vision, and blurred vision. This class of drugs is usually recommended for use four times a day. Due to the possible side effects and the need for daily use, these drugs are no longer recommended. Because some eye drops may enter your bloodstream, you may experience side effects that have nothing to do with your eyesight. Close your eyes for one to two minutes after injecting to reduce this absorption. You can close the crying canal for a minute or two by gently pressing the corner of your eye near your nose. Clean any unused drops in your eyebrows. If you have been given multiple eye drops or need to use artificial tears, separate them between types of drops to wait at least five minutes. Oral Medications: If the eye drop does not reduce your eye pressure to the level you want, your doctor may also prescribe oral medications, usually inhibitors of carbonic anhydrides. Possible side effects include frequent urination, tingling of fingers and toes, depression, upset stomach, and kidney stones (18).

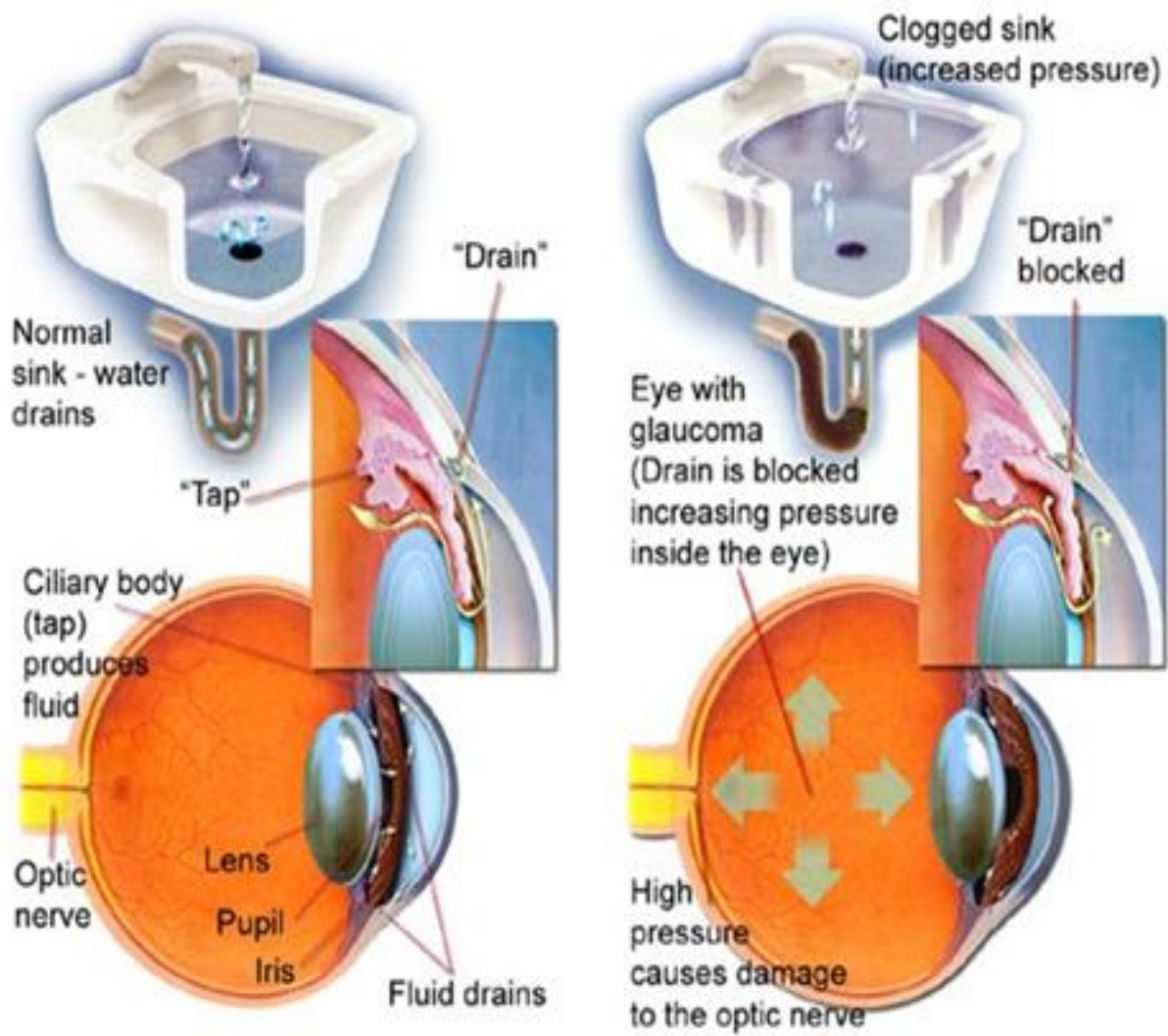
Surgery and other treatments: Other treatment options include laser therapy and various surgical procedures. The following techniques aim to improve the drainage of fluid inside the eye, thus reducing pressure (19):

### **Laser therapy**

A type of laser trabeculoplasty for open glaucoma. This is done in your doctor's office. Your doctor uses a small laser to open closed channels in the trabecular meshwork. It may take several weeks before the effect of the procedure becomes apparent (19).

### **Filtering surgery**

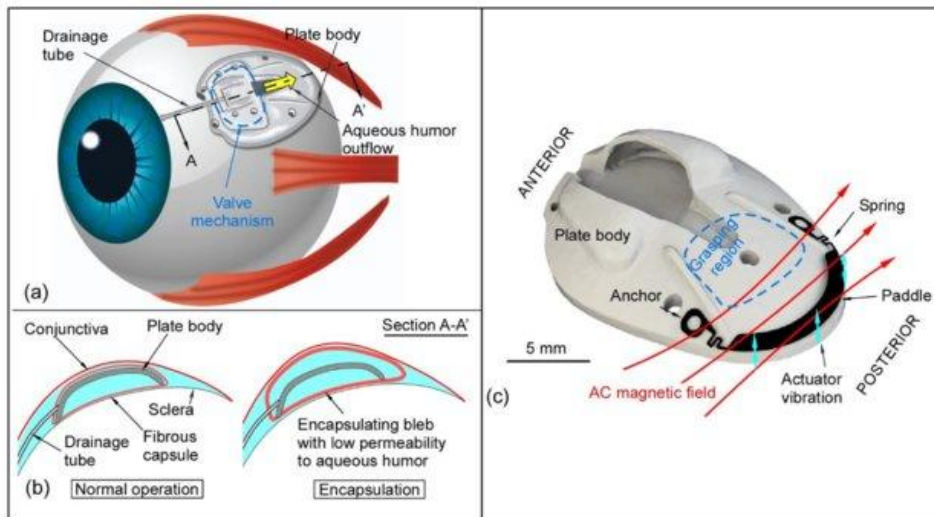
With a surgical procedure called a trabeculectomy, your surgeon opens the white part of the eye (the sclera) and removes part of the trabecular meshwork (figure 7) (19).



**Figure 7 Filtering Surgery for Glaucoma (19)**

### **Drainage tubes**

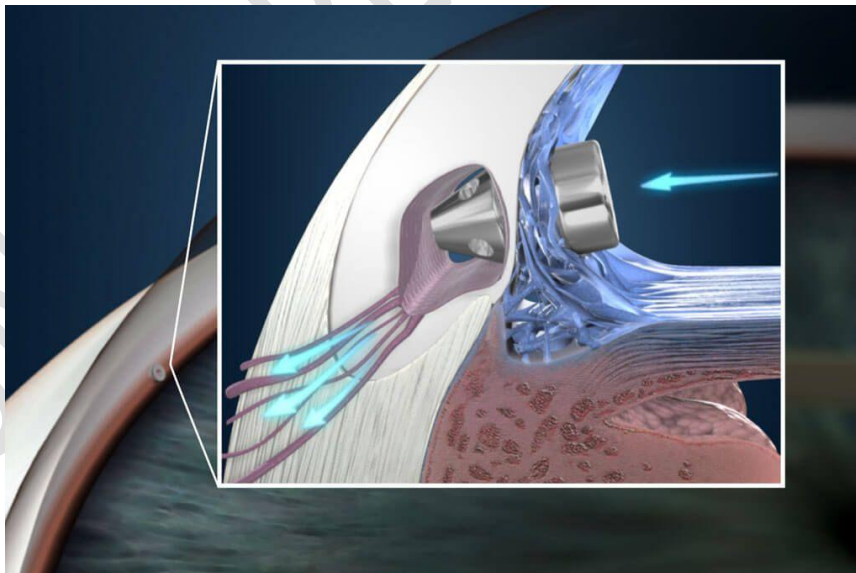
In this procedure, the surgeon inserts a small tube into the eye to remove excess fluid and reduce intraocular pressure (figure 8) (20).



**Figure 8 Drainage tubes (20)**

### **Minimally invasive glaucoma surgery (MIGS)**

Your doctor may recommend a MIGS procedure to help lower your intraocular pressure. These procedures generally require less care and risk immediately after surgery than a trabeculectomy or implantation. They are often combined with cataract surgery. There are a number of MIGS strategies and your doctor will discuss with you which one is best for you. You will need to see your doctor for follow-up exams after your procedure. Finally, if your eye pressure begins to increase or other changes occur in your eye, you may need to have additional procedures (figure 9) (21).



**Figure 9 Minimally invasive glaucoma surgery (MIGS) (21)**

Treatment of acute angle-closure glaucoma: Acute angle-closure glaucoma is a medical emergency. If you are diagnosed with this condition, you will need immediate treatment to reduce the pressure in your eye. This usually requires medication and laser or other surgical procedures. When a doctor makes a small hole in your iris using a laser, you may have a

procedure called laser peripheral iridotomy. This allows the fluid to flow (aqueous humor), relieves eye pressure (21).

## **Prevention**

These self-care measures can help you see glaucoma in its early stages, which is important to prevent or slow the progression of vision loss. Get regular eye checkups. Regular general eye exams before severe damage can help detect glaucoma in its early stages. As a general rule, the American Academy of Ophthalmology recommends a comprehensive eye exam every five to 10 years if you are younger than 40; Every two to four years if you are between 40 and 54 years old; From one to three years if you are between 55 and 64 years old; And for two years every year if you are over 65. If you are at risk for glaucoma, you will need to be tested more often. Ask your doctor to recommend a suitable testing schedule. Know your family's eye health history. Glaucoma runs in families. If you are at high risk, you may need regular check-ups. Exercise safely. Regular, moderate exercise can help prevent glaucoma by reducing eye pressure. Talk to your doctor about the right exercise program. Take regular eye drops. Gouty glaucoma can reduce the risk of high pressure in the eye causing glaucoma. To be effective, you must use eye drops regularly, even if you have no symptoms, as directed by your doctor. Wear eye protection. Severe damage to the eye can lead to glaucoma. Wear eye protection when using powerful equipment or playing high-speed racing games in the court (21).

## **Discussion**

Glaucoma is the name of a number of conditions that damage the optic nerve, usually due to increased pressure in the eye that pulls fluid (aqueous humor) out of the eye. There may be little water flow with normal eye anatomy (open-angle glaucoma) or structural problems in the fluid (angle-closure glaucoma). Optic nerve damage from glaucoma often affects your lateral vision, which leads to tunnel vision, and slows down to include your central vision. The most common type of glaucoma is called open-angle or chronic glaucoma and is caused by a gradual build-up of pressure in the eye over time. A rare form of open-angle glaucoma, called normal tension glaucoma, indicates damage to the optic nerve, although normal eye pressure is normal. Another type of glaucoma is narrow-angle glaucoma or acute glaucoma, in which fluid builds up and there is a sudden increase in eye pressure. Glaucoma may be present at birth (congenital glaucoma) or may be the result of medications, medical conditions, or surgery (secondary glaucoma) (22).

Although glaucoma can affect anyone, it is most commonly diagnosed in people over 60 years of age. In addition, African Americans are five times more likely to develop glaucoma than other patients and may develop at an early age. Finally, people with a family history of glaucoma are more likely to develop glaucoma. In most cases, glaucoma progresses slowly without any symptoms until significant damage is done. Therefore, regular eye examinations are important, especially if you are a Native American or have a family history of glaucoma. Immediate treatment can stop the progression of glaucoma. If left untreated, glaucoma can lead to permanent vision loss or blindness. Although glaucoma is not dangerous to health, it can cause serious vision problems. In most cases, significant losses occur gradually over time.

However, angular or acute closed glaucoma can occur suddenly and cause permanent damage to the eye or loss of vision if not treated immediately (22).

## Conclusion

Glaucoma poses a challenge to many diseases. Our understanding of the basic pathophysiology of many types of glaucoma is still incomplete. However, it is clear that recent advances in medical treatment, laser and incision surgery, and imaging of optic/retinal nerve fiber layers have changed the practice and pattern of operations. Many challenges remain, including better identification of patients with glaucoma, appropriate long-term follow-up and post-diagnosis treatment, and the development of safe, effective and widely used therapies. Given the demographic change and competitive financial situation, it will also be important to promote and develop glaucoma specialists and medical professionals. While the challenges are great, there are also great opportunities. By fostering a creative and collaborative environment and developing diagnostic and therapeutic approaches, it will enable perspective to be taken in patients with glaucoma.

## References

- 1) Andreoli CM, Miller JW. Anti-vascular endothelial growth factor therapy for ocular neovascular disease. *Curr Opin Ophthalmol*. 2007 Nov. 18(6):502-8.
- 2) Cheng Y, Liu XH, Shen X, Zhong YS. Ahmed valve implantation for neovascular glaucoma after 23-gauge vitrectomy in eyes with proliferative diabetic retinopathy. *Int J Ophthalmol*. 2013. 6(3):316-20.
- 3) Costa VP, Jimenez-Roman J, Carrasco FG, Lupinacci A, Harris A. Twenty-four-hour ocular perfusion pressure in primary open-angle glaucoma. *Br J Ophthalmol*. 2010 Oct. 94(10):1291-4.
- 4) Czudowska MA, Ramdas WD, Wolfs RC, Hofman A, De Jong PT, Vingerling JR, et al. Incidence of Glaucomatous Visual Field Loss: A Ten-Year Follow-up from the Rotterdam Study. *Ophthalmology*. 2010 Sep. 117(9):1705-12.
- 5) De Moraes CG, Juthani VJ, Liebmann JM, Teng CC, Tello C, Susanna R Jr, et al. Risk factors for visual field progression in treated glaucoma. *Arch Ophthalmol*. 2011 May. 129(5):562-8.
- 6) Ehlers JP, Spirn MJ, Lam A, Sivalingam A, Samuel MA, Tasman W. Combination intravitreal bevacizumab/panretinal photocoagulation versus panretinal photocoagulation alone in the treatment of neovascular glaucoma. *Retina*. 2008 May. 28(5):696-702.
- 7) Eid TM, Radwan A, el-Manawy W, el-Hawary I. Intravitreal bevacizumab and aqueous shunting surgery for neovascular glaucoma: safety and efficacy. *Can J Ophthalmol*. 2009 Aug. 44(4):451-6.
- 8) Falavarjani KG, Modarres M, Nazari H. Therapeutic effect of bevacizumab injected into the silicone oil in eyes with neovascular glaucoma after vitrectomy for advanced diabetic retinopathy. *Eye (Lond)*. 2009 May 1.

- 9) Gupta V, Jha R, Rao A, Kong G, Sihota R. The effect of different doses of intracameral bevacizumab on surgical outcomes of trabeculectomy for neovascular glaucoma. *Eur J Ophthalmol*. 2009 May-Jun. 19(3):435-41.
- 10) Hasanreisoglu M, Weinberger D, Mimouni K, Luski M, Bourla D, Kramer M, et al. Intravitreal bevacizumab as an adjunct treatment for neovascular glaucoma. *Eur J Ophthalmol*. 2009 Jul-Aug. 19(4):607-12.
- 11) Higashide T, Murotani E, Saito Y, Ohkubo S, Sugiyama K. Adverse events associated with intraocular injections of bevacizumab in eyes with neovascular glaucoma. *Graefes Arch Clin Exp Ophthalmol*. 2012 Apr. 250(4):603-10.
- 12) Higashide T, Ohkubo S, Sugiyama K. Long-Term Outcomes and Prognostic Factors of Trabeculectomy following Intraocular Bevacizumab Injection for Neovascular Glaucoma. *PLoS One*. 2015. 10 (8):e0135766.
- 13) Ishibashi S, Tawara A, Sohma R, Kubota T, Toh N. Angiographic changes in iris and iridocorneal angle neovascularization after intravitreal bevacizumab injection. *Arch Ophthalmol*. 2010 Dec. 128(12):1539-45.
- 14) Kotecha A, Spratt A, Ogunbowale L, et al. Intravitreal bevacizumab in refractory neovascular glaucoma: a prospective, observational case series. *Arch Ophthalmol*. 2011 Feb. 129(2):145-50.
- 15) Lee SJ, Lee JJ, Kim SY, Kim SD. Intravitreal bevacizumab (Avastin) treatment of neovascular glaucoma in ocular ischemic syndrome. *Korean J Ophthalmol*. 2009 Jun. 23(2):132-4.
- 16) Li XJ, Yang XP, Li QM, Wang YY, Lyu XB. Ranibizumab Plus Combined Surgery for Treatment of Neovascular Glaucoma with Vitreous Hemorrhage. *Chin Med J (Engl)*. 2015 Aug 5. 128 (15):2078-83.
- 17) Luke J, Luke M, Grisanti S. [Antiangiogenic treatment for neovascular glaucoma and after filtering surgery]. *Ophthalmology*. 2009 May. 106(5):407-12.
- 18) Lüke J, Nassar K, Lüke M, Grisanti S. Ranibizumab as adjuvant in the treatment of rubeosis iridis and neovascular glaucoma-results from a prospective interventional case series. *Graefes Arch Clin Exp Ophthalmol*. 2013 Oct. 251(10):2403-13.
- 19) Martinez-Carpio PA, Bonafonte-Marquez E, Heredia-Garcia CD, Bonafonte-Royo S. [Efficacy and safety of intravitreal injection of bevacizumab in the treatment of neovascular glaucoma: systematic review]. *Arch Soc Esp Oftalmol*. 2008 Oct. 83(10):579-88.
- 20) Rao HL, Kumar AU, Babu JG, Senthil S, Garudadri CS. Relationship between Severity of Visual Field Loss at Presentation and Rate of Visual Field Progression in Glaucoma. *Ophthalmology*. 2011 Feb. 118(2):249-53.
- 21) Takihara Y, Inatani M, Fukushima M, Iwao K, Iwao M, Tanihara H. Trabeculectomy with mitomycin C for neovascular glaucoma: prognostic factors for surgical failure. *Am J Ophthalmol*. 2009 May. 147(5):912-8, 918.e1.
- 22) Wakabayashi T, Oshima Y, Sakaguchi H, Ikuno Y, Miki A, Gomi F, et al. Intravitreal bevacizumab to treat iris neovascularization and neovascular glaucoma secondary to ischemic retinal diseases in 41 consecutive cases. *Ophthalmology*. 2008 Sep. 115(9):1571-1580.