

## Case study

### Drug-resistant epilepsy revealing pseudo-hypoparathyroidism

#### Abstracts :

Pseudohypoparathyroidism (PHP) is a very rare disease, due to genetic abnormalities of variable expressivity, resulting in resistance of target tissues to the action of parathyroid hormone (PTH). It is a disease that presents in several varieties depending on the existence or not of dysmorphic phenotype, resistance to other hormones and on the responses of hormonal signaling pathways to exogenous PTH supply. Fahr's syndrome is one of the consequences of pseudohypoparathyroidism, it is defined by the presence of intracerebral calcifications, bilateral and symmetrical, non arteriosclerotic, located in the basal ganglia. We report in this work, the observation of a 12 years old child, suffering from a PHP complicated with a Fahr syndrome, discovered after several years of evolution of persistent neurological disorders and refractory to treatments. This work underlines the interest of the research of the disorders of the phosphocalcic metabolism in the presence of neuropsychiatric demonstrations, in order to detect a PHP or any other etiology of a syndrome of Fahr and to adopt thus, the most appropriate therapeutic measures .

Keywords : Fahr's syndrome; Pseudohypoparathyroidism; Neuropsychiatric symptoms; Hypocalcaemia

#### Introduction:

Pseudohypoparathyroidism is a rare inherited genetic disorder subdivided into several distinct entities characterized by resistance to parathyroid hormone action, accompanied by distinct skeletal and developmental malformations. Fahr's syndrome, first described in 1930 by Theodor Fahr, is characterized by the presence of bilateral and symmetrical, non-arteriosclerotic intracerebral calcifications located in the basal ganglia. One of the main etiologies is pseudohypoparathyroidism (PHP), which shows resistance to the action of parathyroid hormone (PTH).

This work underlines, through the case of a child followed in the Neuropediatrics and Neurometabolic Diseases Unit of the Pediatric Service 2 of the Children's Hospital of Rabat in Morocco, the interest of the research of phosphocalcic metabolism disorders before any neurological disorder, in order to detect PHP, or other etiologies of Fahr's syndrome, and to avoid the worsening of the symptomatology by using molecules without neurological side effects or hypocalcemic effect.

#### Case présentation:

The child Z. A, aged 12 years, resident of a small town, from a consanguineous marriage, known asthmatic and followed for several episodes of convulsions considered of epileptic origin since the

age of 5 months, Hospitalized for exploration of a hypocalcemia discovered at the time of convulsive seizures and tetany attacks. The physical examination is normal and does not objective a dysmorphic syndrome. The paraclinical examination showed hypocalcemia at 24.7 ng/l, an elevated parathyroid hormone level of 242 pg/l, a vitamin D deficiency of 8.5 µg/l, a TSHus level of 18.3 µui/ml (normal level <4.94µui/ml). The standard skeletal X-ray showed an Albright osteosyrophy syndrome and a Fahr syndrome was found on the brain scan. In front of this picture, the syndrome of pseudohypoparathyroidism type (PHP1a) was retained.

The clinico-biological evolution was favorable under calcium substitution, vitamin D derivative, Levothyroxine sodium.

## **Discussion:**

PHP1A is a rare disease of autosomal dominant transmission with parental imprinting, necessarily inherited from the mother. It is due to a maternal heterozygous loss-of-function mutation in the coding sequence of GNAS1 . It is discovered during the investigation of hypocalcemia (most often revealing symptom), obesity, growth retardation, hypothyroidism or subcutaneous ossifications.

The typical picture of PTH resistance is hypocalcemia, hyperphosphatemia, elevated PTH and renal failure; the vast majority of PHP1A patients have a chondrodysplasia called Albright's hereditary osteodystrophy (OHA) : Brachydactyly always affecting at least the 4 th radius, but sometimes all fingers or toes/ Narrow lumbar canal/ Short femoral necks and Sometimes cone epiphyses. Finally, mental retardation remains a completely unexplained aspect of PHP1A.

Hypocalcemia results from a defect in the production of 1,25-(OH)<sub>2</sub> vitamin D by the proximal tubule, and thus from a defect in intestinal calcium absorption, but probably also from a defect in the skeletal response to elevated PTH. In contrast, in the renal distal tubule, where Gsa expression is biallelic, PTH-dependent urinary calcium reabsorption is long retained and contributes to the prolonged tolerance of PTH resistance. TSH resistance is almost always present in PHP1A.

Fahr's syndrome occurs preferentially in patients with dysparathyroidism, primarily hypoparathyroidism, and is characterized by the presence of bilateral and symmetrical, non-arteriosclerotic, intracerebral calcifications localized to the gray nuclei.

The treatment consists in giving an active derivative of vitamin D, alfacalcidol or calcitriol . The addition of vitamin D can facilitate calcium homeostasis. Calcium supplements are given for one year after diagnosis if dietary calcium intake is inadequate. Treatment is adjusted quarterly to serum calcium and PTH levels, calciuria and annual renal ultrasound. TSH resistance is routinely treated in PHP1A patients because of their obesity, growth retardation and learning disabilities.

## **Conclusion:**

In children, pseudohypoparathyroidism is a rare but classic cause of basal ganglia calcifications . It is a disease that presents in several varieties depending on the existence or not of a dysmorphic phenotype, resistance to other hormones and the responses of the hormonal signalling pathways to exogenous PTH supply. The main manifestation is hypocalcemia which can be symptomatic. It is a serious disease because of its complications but generally has a good prognosis under treatment.

## COMPETING INTERESTS DISCLAIMER:

Authors have declared that no competing interests exist. The products used for this research are commonly and predominantly used products in our area of research and country. There is absolutely no conflict of interest between the authors and producers of the products because we do not intend to use these products as an avenue for any litigation but for the advancement of knowledge. Also, the research was not funded by the producing company rather it was funded by personal efforts of the authors.

## Références :

1. Albright F, Burnett CH, Smith PH, Parson W. Pseudohypoparathyroidism - an example of 'Seabright-Bantam syndrome'. *Endocrinology* 1942;30:922-32.
2. Weinstein LS. Albright hereditary osteodystrophy, pseudohypoparathyroidism, and Gs deficiency. Dans Spiegel AM, ed. *G proteins, receptors, and disease*. Totowa, New Jersey : Humana Press, 1998:23-56.
3. Levine MA, Downs RW Jr, Moses AM et al. Resistance to multiple hormones in patients with pseudohypoparathyroidism. Association with deficient activity of guanine nucleotide regulatory protein. *Am J Med* 1983;74(4):545-56.
4. Linglart A, Maupetit-Méhouas S, Silve C. Les troubles de perte de fonction liés à la GNAS et le rôle de l'empreinte. *Horm Res Paediatr* 2013;79(3):119-29.
5. Zhang P, Jobert AS, Couvineau A, Silve C. Une mutation inactivatrice homozygote dans le récepteur de l'hormone parathyroïdienne/du peptide lié à l'hormone parathyroïdienne causant la chondrodysplasie de Blomstrand. *J Clin Endocrinol Metab* 1998;83(9):3365-8. Fahr et dysparathyroïdie : trois observations. *Presse Med* 1995;24:1301-4.
6. Khadir K, Moussaid L, el Ouazzani T, et al. Syndrome de Fahr secondaire à une hypoparathyroïdie à révélation dermatologique. *Ann Dermatol Venerol* 2004;131:979-83.
7. Linglart A, Bastepe M, Carel JC, et al. Caractéristiques cliniques des différentes formes de PHP Ib : autosomique dominante ou sporadique ? *Ann Endocrinol* 2006;67(5) 426-35.
8. Mantovani G, Bondioni S, Linglart A, et al. Genetic analysis and evaluation of resistance to thyrotropin and growth hormone releasing hormone in pseudo-hypoparathyroidism type Ib. *J Clin Endocrinol Metab* 2007;92:3738-42.
9. Morgane L, Trimarchi F, Benvenega S. La maladie de Fahr. *Lancet* 2002;359:759.
10. Shakibai SV, Johnson JP, Bourgeois JA, et al. Paranoid delusions and cognitive impairment suggesting Fahr's disease. *Psychosomat*.

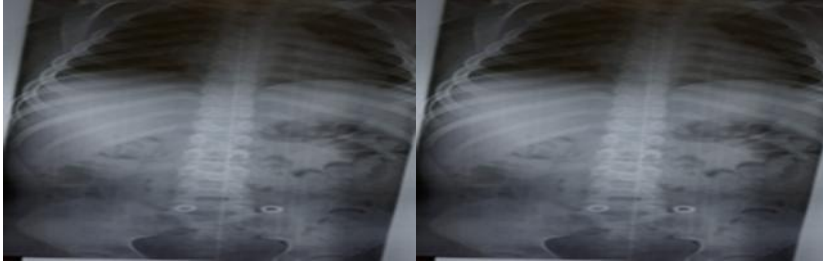


Figure1 : ALBRIGHT's osteodystrophy

UNDER PEER REVIEW