

Tubercular Dactylitis-A Case Report

ABSTRACT

Tuberculous dactylitis is an unusual form of osteoarticular tuberculosis involving the short tubular bones of hands and feet. We report the case of a three-year-old female child who was diagnosed with tuberculous dactylitis, involving metacarpal of hand. Her diagnosis was delayed due to lack of suspicion of this rare entity. The report also examines the diagnostic difficulties faced by clinicians in arriving at an appropriate diagnosis.

Key words: Dactylitis, , Spina Ventosa, Tuberculour osteomyelitis

INTRODUCTION

Osteoarticular tuberculosis (TB) is a relatively rare presentation of TB, constituting around 10%–15% of all cases of extrapulmonary TB [1]. Tuberculous infection of metacarpals, metatarsals, and phalanges of hands and feet is known as tuberculous dactylitis. Eighty-five percent of the patients are younger than six years of age [2]. Tuberculosis at this site is quite unusual leading to confusion in diagnosis and delays in proper treatment. Since tubercular dactylitis mimicks conditions like infection and malignancy , hence proper assessment of patient with establishment of definitive diagnosis are absolutely essential before embarking upon a treatment option.

CASE REPORT

A 3-year-old female child of migrant labourer presented to us with swelling on dorsum of right hand for last 6 month . Initially swelling was insidious in onset but showed rapid growth in last 3 weeks (Fig. 1) . Patient was febrile for last 7 days with functional impairment in the form of inability to grasp objects. Keeping in view long history of 6 months, a possibility of tuberculosis was kept at this stage , but other supporting features like loss of weight and appetite, history of antitubercular drug intake, and history of contact with tubercular patient were absent. Lab investigations revealed Anemia (Hb=7.2 mg/dl, Hematocrit 24.2%) while TLC and DLC was in normal range. Routine HIV screening was negative.

Digital radiography of right hand revealed scalloping of the 3rd metacarpal with underlying subtle cortical irregularities and osteopenia (Fig. 2). At this stage possibilities of neoplasia and an infective aetiology were entertained. NCCT revealed lytic destructive area involving 3rd metacarpal bone with flaring of medullary cavity with destruction along lateral aspect with significant soft tissue content along fascial planes with extension and fullness in the carpal tunnel (Fig.3). On USG examination dorsal hypoechoic collection 1.6x1.8 cm indicative of soft tissue collection over right hand and underlying cortical irregularity of right metacarpals were noted. Aspiration of the swelling revealed purulent material. No microorganisms were detected from the aspirate, while CBNATT detected Mycobacterium Tuberculosis. Patient was initiated on Antitubercular therapy as per INDEX tuberculosis guidelines and showed full resolution of symptoms and signs, with functional improvement at one year follow up.

DISCUSSION

Diagnosis of skeletal tuberculosis in children is based more on suspicion as classical features on history, clinical examination and investigations may be absent. This could be due to various factors like absent high index of suspicion and poor awareness among the clinicians regarding this condition in children, atypical presentation, uncommon beyond 6 years of age, absence of concomitant pulmonary involvement and paucibacillary nature of lesion [3,4]. Still differential diagnosis of dactylitis including pyogenic osteomyelitis, sarcoidosis and enchondroma need to be excluded considering their features on X Ray and histopathology. While osteomyelitis and enchondroma present as a skeletal lytic lesion, skeletal sarcoidosis has a lacy pattern of lytic lesion with periosteal reaction akin to Tuberculosis [5]. However careful consideration of history, clinicoradiology and histopathology together can help arrive at diagnosis of skeletal tuberculosis. In the present case too the diagnosis of tuberculous dactylitis was established on basis of long history, cortical destruction on X Ray, and positive CBNAAT for Tuberculosis from aspirate.

Some studies have suggested to start ATT without delay even in a suspicion of tuberculosis on clinic-radiological presentation [6]. In the present case there was no classical presentation of skeletal tuberculosis. Long disease history (6 months) and a poor socioeconomic status were the only supporting observation. Although Anemia was noted on initial investigation, DLC was found to be in normal range. Aspiration revealed purulent material but detection of tuberculosis on CBNAAT along with cortical destruction of 3rd

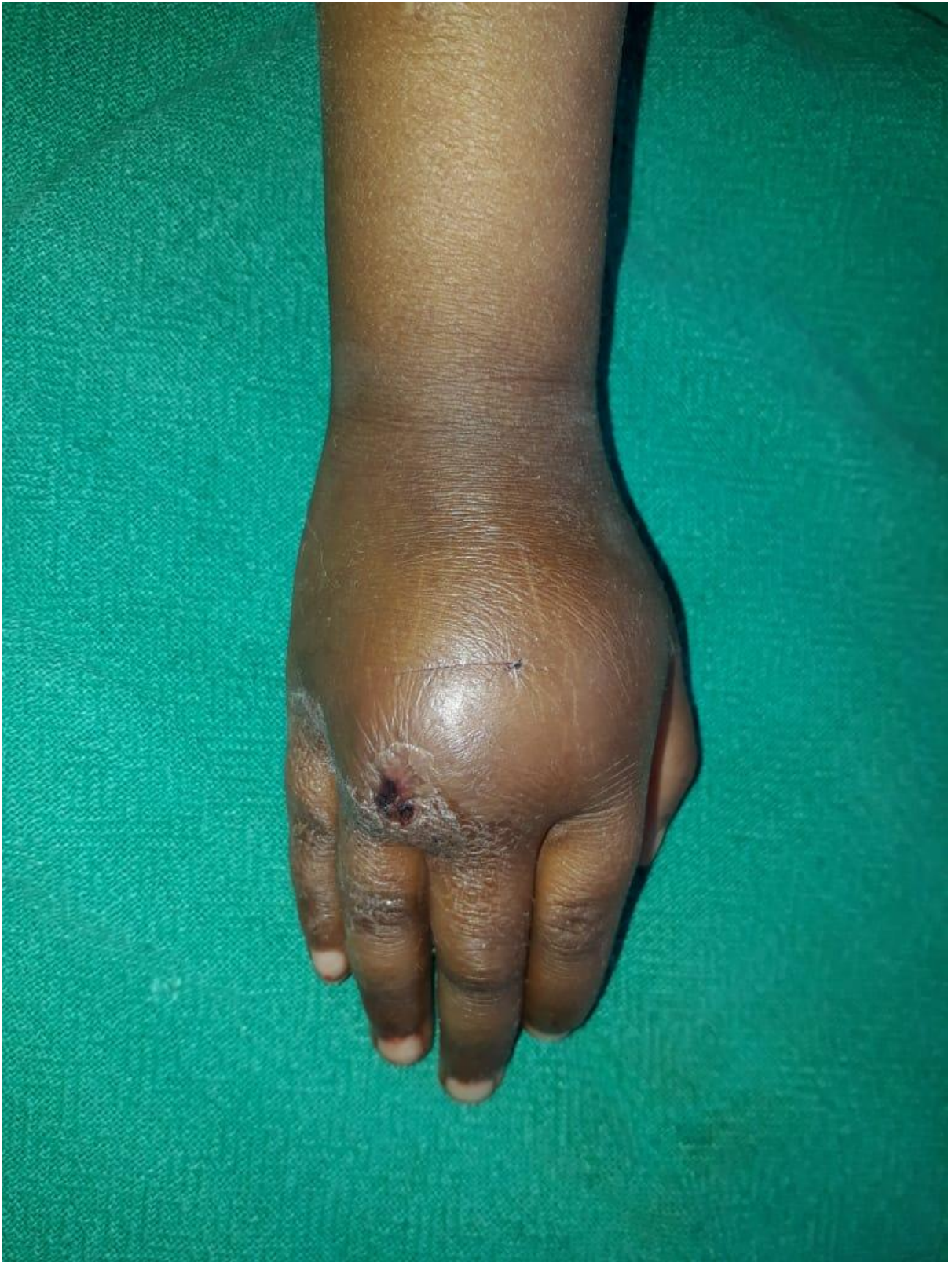metacarpal clinched the diagnosis of tubercular dactylitis. Hence tubercular dactylitis, although a rare manifestation of an important disorder (skeletal tuberculosis) should always be kept as a possibility in a child with swelling hand .The diagnosis can be amicably established after meticulous exclusion of other pathologies with identical presentation.

CONCLUSION Skeletal Tuberculosis has very low incidence and tuberculus dactylitis is a rare entity. The patients presenting with swelling hand may be misdiagnosed as pyogenic osteomyelitis , malignancy or other granulomatous conditions. As no single feature is diagnostic of tubercular aetiology, a collective approach involving history taking, clinicoradiology along with histopathological diagnosis are mandatory to establish diagnosis of tubercular osteomyelitis and initiate appropriate treatment.

CONSENT As per international standard informed and written participant consent has been collected and preserved by the authors.

ETHICAL APPROVAL As per international standard written ethical permission has been collected and preserved by the author(s).

Figure Legends



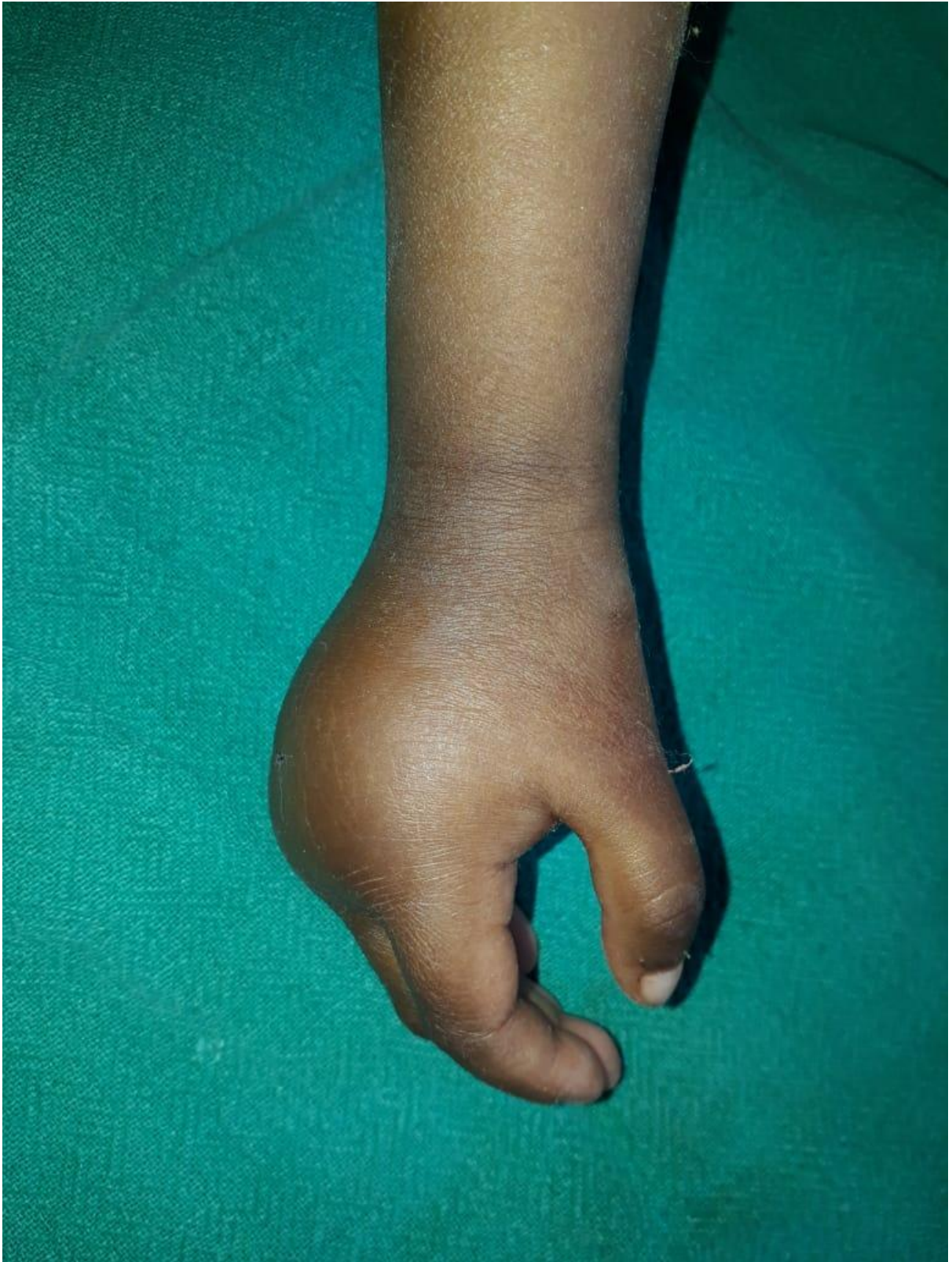

Fig.1 Clinical pic Right Hand at the time of presentation

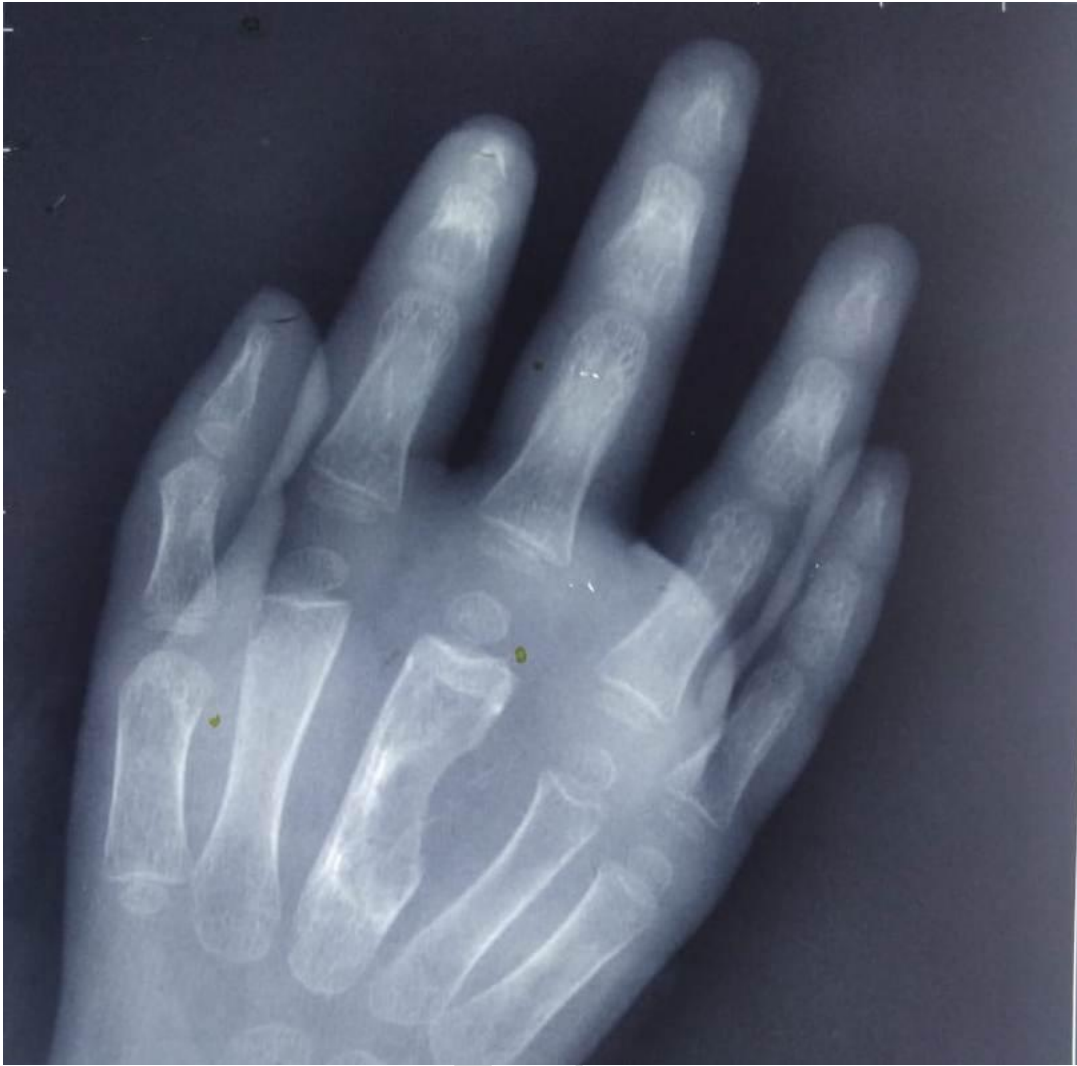

Fig.2 Radiograph showing scalloping of the 3rd meracarpal , subtle cortical irregularities and Osteopenia

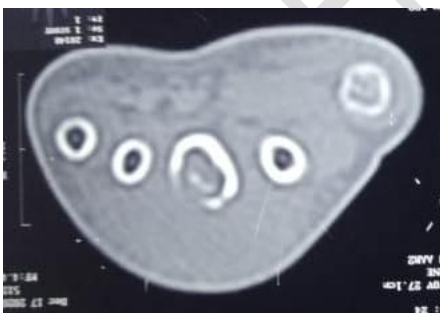
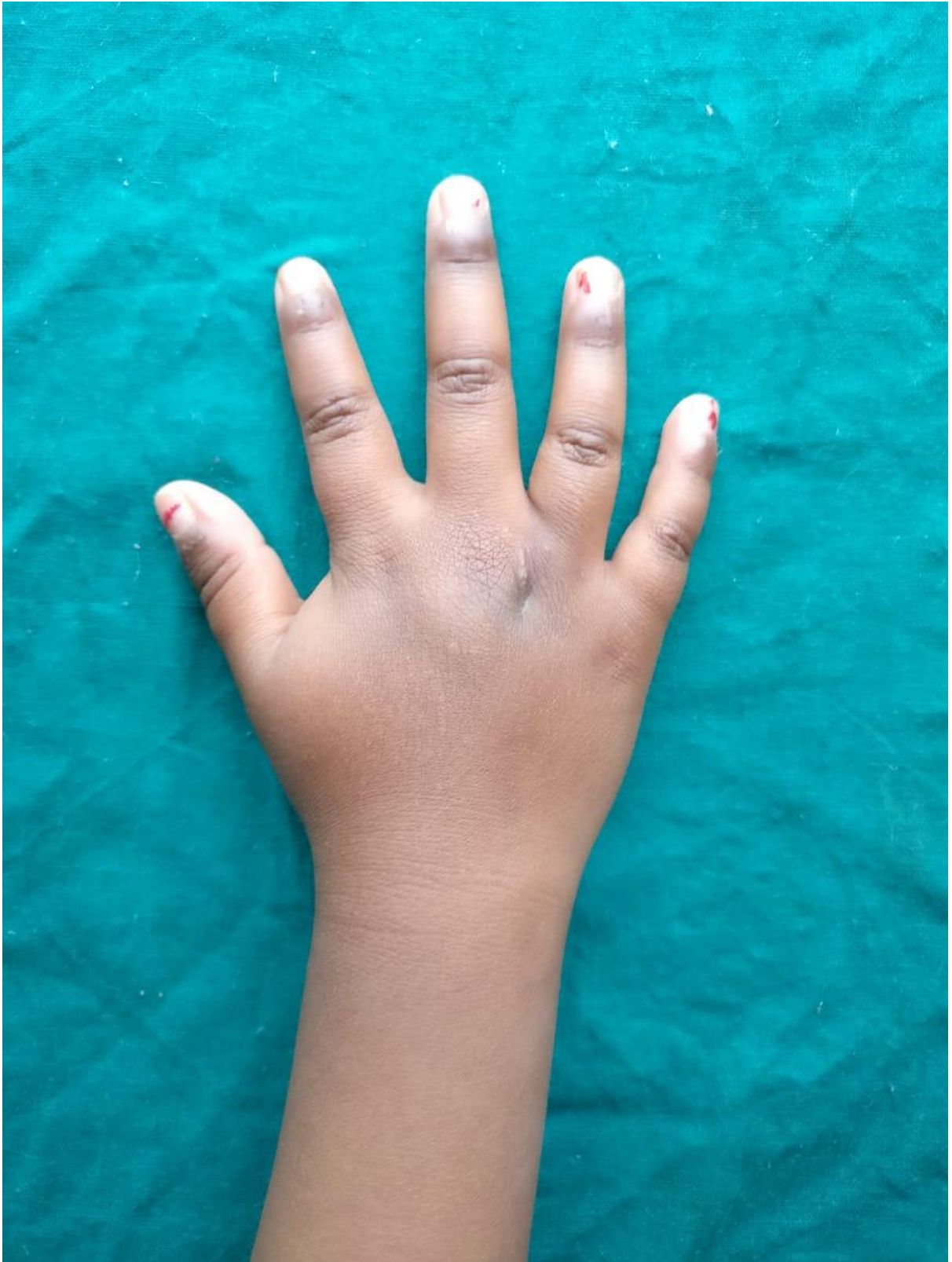
Fig.3 CT Scan showing lytic destructive area 3rd metacarpal bone, flaring of medullary cavity with destruction



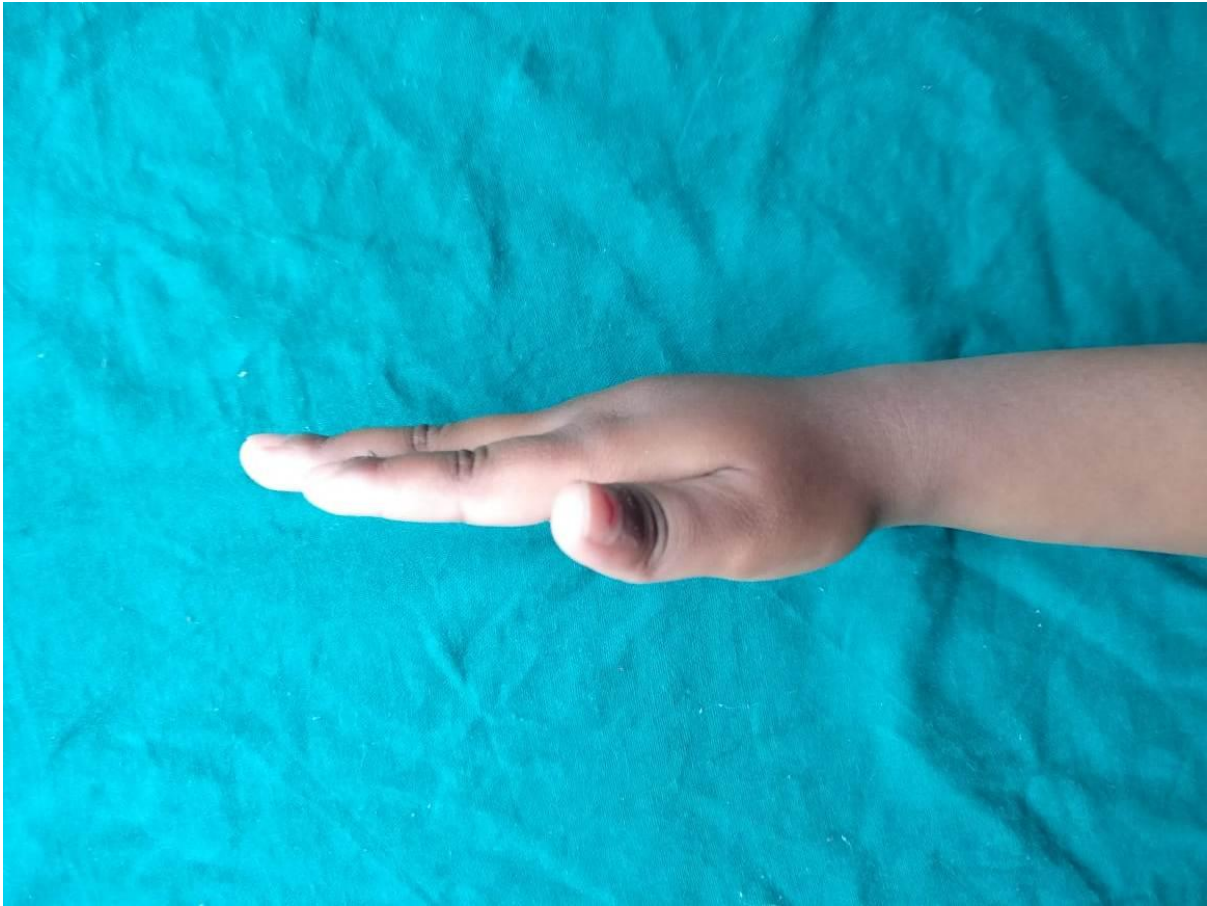


Fig.4 Clinical pics post ATT at one year

References

1. Ahammadunny R, Rathish B, Wilson A, Warriar A. Pubic symphysis tuberculosis: A diagnostic dilemma. *Int J Mycobacteriol* 2021;10:98-100.
2. Salimpour R, Salimpour P. Picture of the Month. *Arch Pediatr Adolesc Med.* 1997;151(8): 851–852.
3. Sunderamoorthy D, Gupta V, Bleetman A. TB or not TB : an unusual sore finger. *Emergency Medicine Journal.* 2001;18:490–491.
4. Panchonia, Kulkarni CV, Meher R, Mandwariya S. Isolated tuberculous dactylitis [Spina

ventosa] in a 9 year old boy-a rare entity. International Journal of Basic and Applied Medical Sciences. 2012;2:55.

5. Jha S, Dhooria A, Jain S. Tuberculous Dactylitis: A Rare Form of Skeletal Tuberculosis. J Clin Rheumatol. 2020 Aug;26(5):e93.

6. Index TB Guidelines. Available from : http://www.tbonline.info/media/uploads/documents/index-tb_guidelines_-_green_colour_2594164.pdf. [Last accessed 2020 Dec 15].

UNDER PEER REVIEW