

Fatal spontaneous intracranial hemorrhage in a low risk parturient – A case report with review of literature

Abstract:

Intracerebral hemorrhage is uncommon during pregnancy when compared to puerperium and associated with devastating outcomes. This is a case of fatal intracerebral and subarachnoid hemorrhage in a 25 years woman who had supervised antenatal care in her second pregnancy. The first pregnancy was uneventful and in her second pregnancy, she had one transient high diastolic blood pressure (BP) recording of 92mmHg at 35 weeks of gestation. She presented at 39 weeks to emergency room in labour with signs of concealed abruption. There was history of headache lasted for few hours before admission. She had doubtful seizure-like activity soon after arrival followed by which she lost her consciousness, and a magnesium sulfate regimen (MgSO₄) was started. She progressed spontaneously and delivered a 2.8Kg fresh stillborn. Investigations suggested features of microangiopathic hemolytic anemia and acute kidney injury. Atonic postpartum hemorrhage was managed aggressively with oxytocics and blood products. There were two consecutive episodes of generalized tonic-clonic seizures (GTCS) despite MgSO₄. Neuroimaging revealed diffuse subarachnoid hemorrhage (SAH) with multiple petechial bleeds in bilateral hemispheres. Despite worsening neurological symptoms with increased intracranial pressure, timely neurosurgical intervention was not possible due to associated coagulopathy. Subsequently, she became comatose and perished on postnatal day 6. A retrospective history revealed antepartum eclampsia in her sister. Routine screening for preeclampsia in some form using either phenotypic or biomarkers will be lifesaving and unusual headaches in a pregnant woman warrant through evaluation as time is golden in cerebrovascular accidents.

Keywords: Intracerebral hemorrhage, abruption, subarachnoid hemorrhage, disseminated intravascular coagulation, headache, pregnancy, cerebrovascular accidents

Introduction:

Cerebrovascular accidents (CVA) are rare but potentially life threatening complication and pregnancy is an independent risk factor for both ischemic stroke (IS) as well as hemorrhagic stroke (HS)^[1]. A well-known fact is that the physiological changes in the coagulation cascade make pregnancy a prothrombotic state and the risk is maximum in the postpartum period. Every 1 in 600 women has a chance of developing cerebrovascular accidents (CVA) during pregnancy/postpartum and the incidence of HS is about 1 in 15,000 pregnancies^[2]. Another end of the hemostasis spectrum is bleeding which could be due to various causes and hypertension tops the list during pregnancy^[3]. There is high chance of CVA when the systolic blood pressure (BP) is 160 mmHg or more during pregnancy. Though uncommon, ICH due to aneurysmal rupture or AV malformation can occur for the first time in pregnancy. Rarely does it occur without high BP in the setting of coagulopathy like abruptio placenta or HELLP syndrome. We report a case of a massive ICH in the setting of disseminated intravascular coagulation (DIC) in a low risk parturient.

Case report

A 25-year G2P1L1, registered with us at 26 weeks of gestation for regular antenatal care. The previous pregnancy was low risk and had an uneventful antepartum and peripartum course in our facility. In her second pregnancy, her BP was 128/91mmHg once during her visit to the hospital at 35 weeks. Home BP chartings and BP recordings in subsequent visits were normal. There was no significant medical or surgical illness in the past. She had received the first dose of covid vaccine at 32 weeks of gestation. The last visit to antenatal clinic was at 37 weeks and maternal/fetal conditions were reassuring. She was advised to continue home BP charting and to review in antenatal clinic after a week. But, she came to emergency at 39 weeks with abdominal pain and history of leaking per vaginum. She also gave history of unusual headache on the same day before arrival which got subsided with home care. She was conscious, well oriented, and had stable vitals in emergency department. On abdominal examination, the uterus was tense, non-tender, contracting and the symphysis-fundal height corresponded to the period of gestation. The fetal heart rate was absent. On vaginal examination, the cervix was 75% effaced, 3cm dilated and clear liquor drained, vertex was at -2 station. Ultra-sonogram showed intrauterine fetal demise without any retroplacental clot in the posterior placenta. She was unresponsive and had a seizure-like activity in the labor room after 2 hours after admission. She responded to

commands but was drowsy and her BP was 130/80mmHg; started on low dose magnesium sulfate [(MgSO₄); Dhaka regimen]. She progressed well on her own and had a spontaneous vaginal delivery of 2.8kg fresh stillborn with 600ml of clots behind the placenta within an hour. There was atonic postpartum hemorrhage (PPH) which was managed aggressively with medical measures. She also received blood transfusion in the form of components as there was a picture of DIC. Soon after delivery, she developed generalized tonic-clonic seizures (GTCS) twice while on MgSO₄ and was managed with an additional dose of MgSO₄ and Inj.Levetiracetam, following which she did not regain her consciousness. She was intubated as the Glasgow Coma Score (GCS) was 3 and urgent neuroimaging was done.

Non-contrast computer tomography (NCCT) brain showed Left frontal small bleed, intraventricular hemorrhage, diffuse subarachnoid hemorrhage, multiple diffuse petechial hemorrhages in both hemispheres without midline shift (**Figure No. 1**).

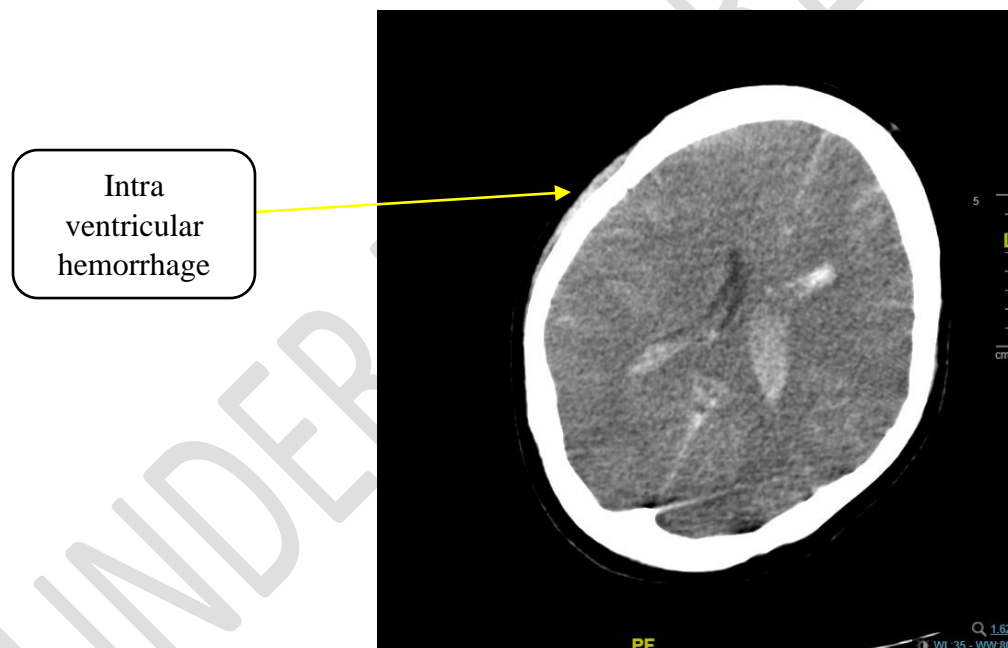


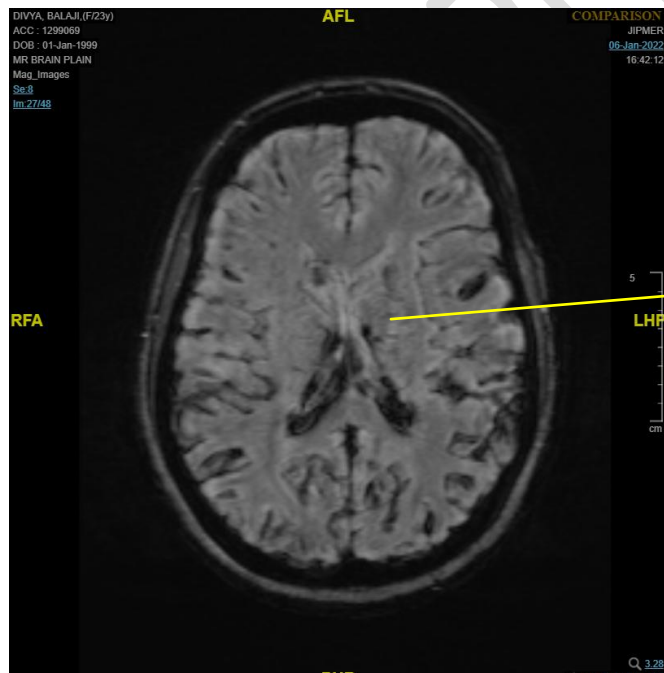
Figure 1: NCCT brain

She required single dose of Inj.Labetalol 20mg IV while she developed recurrent seizures after delivery when the BP was >160/100mmHg; subsequently the medication was withheld as

the BP was <140/90mmHg. Her laboratory parameters showed features of thrombotic microangiopathy and the possibility of HELLP syndrome and DIC due to abruption were kept in mind and she was transfused with appropriate components and supportive measures were undertaken. She had developed AKI post-delivery which required a setting of hemodialysis. (The parameters are shown in **Table.No.1**). Multidisciplinary consultation was sought and the neurosurgical intervention was withheld as there was coagulopathy. There was serous retinal detachment threatening the macula in both eyes on fundus examination. She gradually deteriorated requiring inotrope support and succumbed on postnatal day 6. A retrospective history revealed a history of antepartum eclampsia in her sister at 31 weeks of gestation and hospitalized for 21 days after delivery and seizure disorder in her mother.

Magnetic Resonance Angiography (MRA) brain after 48 hours showed diffuse cerebral edema, basal cisterns, tonsillar herniation, extensive bilateral subarachnoid hemorrhage (SAH), and there was no flow in intracranial vessels. (**Figure No. 2**)

An axial image showing a hyperdense intracerebral and subarachnoid bleed with ventricular extension (**Figure 2**). A sagittal section showing gliotic changes in the cerebral hemisphere and cerebellar tonsil herniation.



Intracerebral bleed with
Ventricular extension

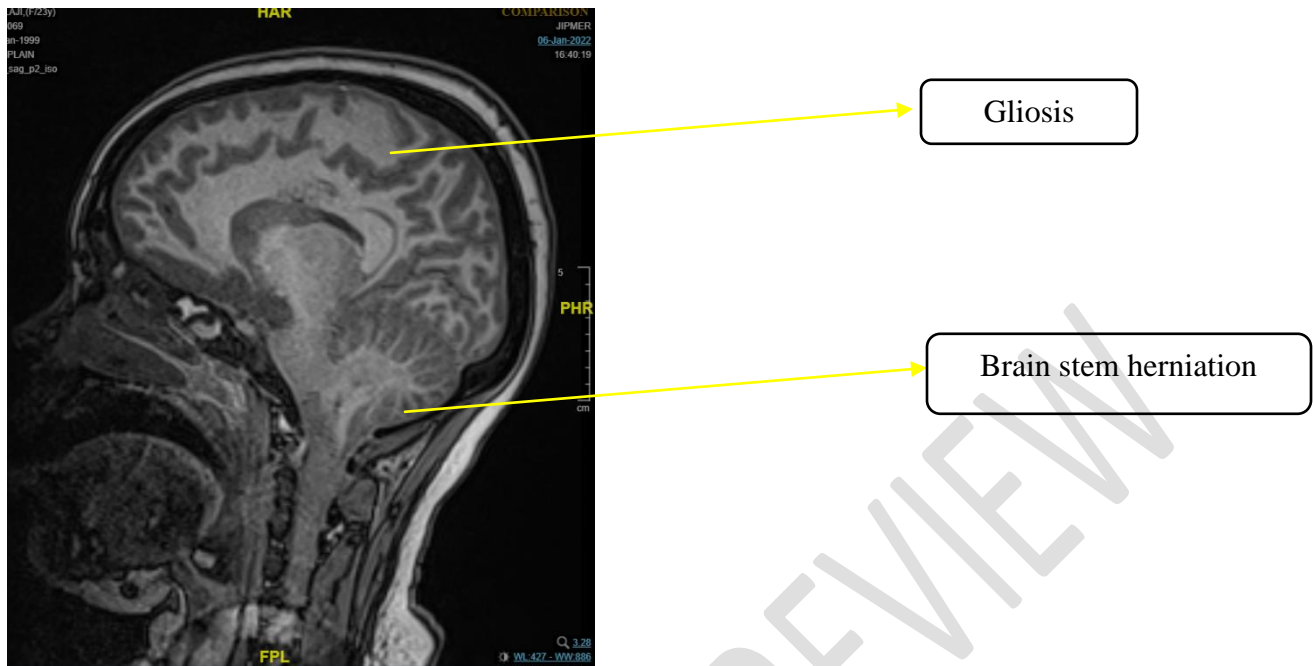


Fig 2:

Discussion:

CVA are common cause of disability worldwide and the occurrence of stroke is increasing in younger individuals. Hemorrhage, vascular malformations and coagulopathy are the important causes of stroke^[4]. Pregnant women are at three times higher risk of developing stroke compared to non-pregnant counterparts^[5]. Overall, these CVA could be ischemic, haemorrhagic or thrombotic and all of them have equal contribution in pregnancy unlike non pregnant population in whom majority are ischemic (80-85%)^[5,6]. There are five types of ICH depending on the site of the bleed. It can be intracerebral, intraventricular, extradural, subdural, or subarachnoid^[5]. The most common type is subarachnoid haemorrhage (SAH) and majority are due to AV malformation (50%) and the most common site of intracerebral hemorrhage is basal ganglia. Recognizing the type of CVA is important as the management is different in various types of CVA and the site of bleed may prompt us to look for specific cause. In hypertensive pregnant women, hemorrhage occurs due to increased vascular permeability secondary to a rise in cerebral perfusion pressure and endothelial dysfunction, leading to loss of cerebral autoregulation^[6]. The combination of hemorrhage and cerebral edema causes a rise in the intracranial pressure leading to a sudden drop in consciousness. A persistent increased intracranial tension causes cerebral herniation and a permanent loss of neural tissues which could be fatal. Experts should be

informed immediately if such an acute event occurs during pregnancy as it can cause detrimental outcomes in both mother and the fetus especially when the stroke is of progressive spontaneous hemorrhagic type. Ascanio et al^[4]. A systematic review on intracranial hemorrhage (ICH) has shown distribution of ICH as follows: 51.3% with intracerebral bleed, 34.8% with sub-arachnoid bleed, and 11.6% with subdural bleed among 43 gravid women from 20 studies. The maternal mortality was more in intra-parenchymal haemorrhage (68.1%) than SAH (26.7%). However, some reports show a favorable outcome in ICH. One was a lobar hemorrhage following HELLP syndrome and the other was a massive cerebral bleed following eclampsia, both underwent a successful decompressive surgical procedure^[7,-9].

In general, new onset seizure in pregnant women should be considered as eclampsia until proven otherwise especially after 20 weeks and within 7 days postpartum. However urgent neuroimaging is recommended in the presence of breakthrough seizures despite MgSO₄, focal neurological deficits or worsening of consciousness. Timely involvement of neurosurgeons for decompression craniotomy could be lifesaving in the presence of cerebellar haemorrhage, ventricular bleed or with brain stem compression. Treatment of hypertension, seizure prophylaxis and correction of underlying coagulopathy are important in addition to compression stockings for the prevention of thromboembolism in these women. Maternal age of >35yrs (odds ratio [OR] 2.3), migraine (OR 8.5), gestational diabetes (OR 26.8), preeclampsia/eclampsia (OR 7.7) and pre-existing hypertension (OR 8.5) are the independent risk factors for CVA in pregnancy^[6].

Pregnancy-related changes on the vessel wall might predispose to rupture in at-risk individuals⁸. The incidence of ICH following rupture of vascular malformation is widely ranging from 20% to 67%¹⁰. The risk of rupture is 3 times higher in pregnant women with vascular malformations and 2.7 times higher in women with gestational hypertension^[1,11]. Vascular malformations are responsible for 50% of SAH¹¹. Multidisciplinary approach with involvement of neurosurgery, neurology, anaesthesia and maternal-fetal medicine specialists are important for optimal outcome and caesarean delivery is favoured by multidisciplinary team when the AVM is untreated. Rarely coagulopathy in pregnancy or HELLP syndrome can cause massive SAH.

Though SAH are common with vascular malformations and coagulopathy, it is not uncommon to find high blood pressure in the setting of SAH. It is essential to maintain MAP around 120mmHg and systolic BP in the range of 120-160mmHg. In our case it is difficult to say

sudden high blood pressure after delivery would have caused ICH or the high blood pressure was observed because of massive SAH. The coagulopathy would have been due to abruptio than HELLP syndrome however the management was supportive in both and they recover following delivery. There was a family history of early onset severe preeclampsia however the first pregnancy was uneventful in our patient. The possibility of HELLP syndrome cannot be certainly ruled out without biochemical markers (especially sFlt-1/PlGF ratio) however was not warranted in our patient. As there was recovery in terms of laboratory parameters after delivery, we did not perform. Vaccine-induced thrombotic thrombocytopenia (VITT) is a rare adverse reaction that was observed following Oxford-AstraZeneca covid vaccine. A case report described the development of ICH after 12 days following Oxford-AstraZeneca vaccination secondary to VIT^[13]. However, our patient received a single dose of a different strain vaccine at 32 weeks and it should be unlikely to be VITT.

In CVA, the clinical manifestations could be varying ranging from headache to coma. Such abrupt onset of massive ICH can have an aura before the onset of eclampsia. Almost 50% of individuals can have a throbbing headache before the onset of hemorrhage^[14]. The headache is typically described as a sentinel or thunderclap headache. It is essential that pregnant women should reach hospital at the earliest when they experience unusual or severe headache as timely interventions could be lifesaving. Our patient came to hospital when she experienced labour pain which was almost 8 hours after headache.

A plain CT brain with an abdominal shield should be performed irrespective of the gestation period during an episode of rapid deterioration of neurological functions following eclampsia or with suspicion of CVA. The dose exposed following a CT brain is $< 0.01 \text{ Gy}$ ¹² which is much below the safety dose during pregnancy. The management is similar to that of a non-obstetric case but it should be individualized. Sometimes there can be a hemorrhagic transformation of ischemic stroke or combined ischemic and hemorrhagic components might coexist. A cerebral angiography along with a venogram can be performed if arterio-venous malformations (AVM) are suspected. In our case, there could have been a thrombotic vascular occlusion of the carotid arteries leading to absent cranial blood flow secondary to coagulopathy. When there is a drop or improvement in the GCS, repeat neuroimaging has to be performed to know the progression or regression of the hemorrhage.

With HS, the pregnancy should be terminated by caesarean, but the surgery by itself is a stress factor that can increase intracranial pressure transiently leading to the progression of hemorrhage in women with ongoing bleed ^[16-18]. So it requires multidisciplinary team management. The obstetric management in ICH before the viability period should be managed after discussion with the family members. If the woman is in the second stage, assisted vaginal delivery can be performed under adequate labor analgesia, thereby avoiding Valsalva ^[4].

Though successful recovery has been reported in literature following neurosurgical procedures for intracerebral bleeds, the prognosis following surgery would be better following hemorrhage in extradural or subarachnoid space. A concurrent decompressive craniotomy during caesarean section would be required in some situations as explained earlier. The surgery was deferred in our case despite massive SAH, because of DIC. There prognosis is grave following HS than the IS and if they survive 40% can have a permanent neurological deficit ^[19,20]. The site, size, and volume of the hemorrhage may also predict the prognosis. Studies have shown that the risk of recurrence following a stroke is 1% in 1 year and 2.3% in 5 years^[11,16-18]. Various case reports/case series on intracranial hemorrhage during pregnancy are summarized in Table No.2.

Conclusion

We highlight that timely identification of the risk factors causing ICH and addressing it appropriately along with creating awareness should be the key aim of prevention. A thorough history and examination should be performed on every pregnant woman and some form of risk assessment should be the norm in early pregnancy. If a woman becomes a high-risk candidate and active monitoring should be done from late gestation to her puerperal period. An integrated approach from the experts in the field of obstetrics, critical care, radiology, neurology, and neurosurgery provides an effective decision that can save the life of a pregnant woman with a sub-massive intracerebral bleed.

Informed consent:

Written informed consent has been obtained from patient and her husband.

dReferences

1. Meeks JR, Bambhroliya AB, Alex KM, Sheth SA, Savitz SI, Miller EC, McCullough LD, Vahidy FS. Association of Primary Intracerebral Hemorrhage With Pregnancy and the Postpartum Period. *JAMA Netw Open*. 2020;1;3(4):e202769. doi: 10.1001/jamanetworkopen.2020.2769
2. VERMA, Kamala; AGRAWAL, Sudesh. A life threatening intracerebral hemorrhage during pregnancy. *Int J Reprod Contracept Obstet Gynecol*, [S.l.], v. 4, n. 3, p. 840-842, 2017. ISSN 2320-1789. Available at :< <https://www.ijrcog.org/index.php/ijrcog/article/view/1957>>. Date accessed: 15 june 2022. doi:<http://dx.doi.org/10.18203/2320-1770.ijrcog20150104>
3. Lin LT, Tsui KH, Cheng JT, Cheng JS, Huang WC, Liou WS, Tang PL. Increased Risk of Intracranial Hemorrhage in Patients With Pregnancy-Induced Hypertension: A Nationwide Population-Based Retrospective Cohort Study. *Medicine (Baltimore)*. 2016 ;95(20):e3732. doi: 10.1097/MD.00000000000003732
4. Ascanio LC, Maragkos GA, Young BC, Boone MD, Kasper EM. Spontaneous Intracranial Hemorrhage in Pregnancy: A Systematic Review of the Literature. *Neurocrit Care*. 2019;30(1):5-15. doi: 10.1007/s12028-018-0501-4
5. Cavaliere AF, Turrini I, Pallottini M, Vidiri A, Marchi L, Perelli F, Zaami S, Scambia G, Signore F. Genetic Profiling of Idiopathic Antenatal Intracranial Haemorrhage: What We Know? *Genes (Basel)*. 2021;15;12(4):573. doi: 10.3390/genes12040573
6. Khalid A, Hadbavna A, Williams D, Byrne B. A review of stroke in pregnancy: incidence, investigations and management. *The Obstetrician & Gynaecologist* 2020;22:21–33. <https://doi.org/10.1111/tog.12624>

7. Rayes M, Konyukhov A, Fayad V, Chaturvedi S, Norris G. Good outcome in HELLP syndrome with lobar cerebral hematomas. *Neurocrit Care*. 2011;14(2):276-80. doi: 10.1007/s12028-010-9487-2
8. Ghaly RF, Candido KD, Sauer R, Knezevic NN. Complete recovery after antepartum massive intracerebral hemorrhage in an atypical case of sudden eclampsia. *Surg Neurol Int*. 2012;3:65. doi: 10.4103/2152-7806.97167. Epub 2012 Jun 19
9. Miller EC, Sundheim KM, Willey JZ, Boehme AK, Agalliu D, Marshall RS. The Impact of Pregnancy on Hemorrhagic Stroke in Young Women. *Cerebrovasc Dis*. 2018;46(1-2):10-15. doi: 10.1159/000490803
10. Tang CH, Wu CS, Lee TH, Hung ST, Yang CY, Lee CH, Chu PH. Preeclampsia-eclampsia and the risk of stroke among peripartum in Taiwan. *Stroke*. 2009;40(4):1162-8. doi: 10.1161/STROKEAHA.108.540880
11. Lee S, Kim Y, Navi BB, Abdelkhaleq R, Salazar-Marioni S, Blackburn SL, Bambhroliya AB, Lopez-Rivera V, Vahidy F, Savitz SI, Medhus A, Kamel H, Grotta JC, McCullough L, Chen PR, Sheth SA. Risk of intracranial hemorrhage associated with pregnancy in women with cerebral arteriovenous malformations. *J Neurointerv Surg*. 2021 ;13(8):707-710. doi: 10.1136/neurintsurg-2020-016838
12. Carvalho CS, Resende F, Centeno MJ, Ribeiro I, Moreira J. Anesthetic approach of pregnant woman with cerebral arteriovenous malformation and subarachnoid hemorrhage during pregnancy: Case report. *Braz J Anesthesiol*. 2013;63(2):223-6. doi: 10.1016/j.bjane.2012.05.004
13. Mendes-de-Almeida DP, Martins-Gonçalves R, Morato-Santos R, De Carvalho GAC, Martins SA, Palhinha L, et al. Intracerebral hemorrhage associated with vaccine-induced

thrombotic thrombocytopenia following ChAdOx1 nCOVID-19 vaccine in a pregnant woman. *haematol* [Internet]. 2021; Available from: <https://haematologica.org/article/view/haematol.2021.279407>

14. Gonullu H, Karadas S, Oncu MR, Tasdemir M. Two patients with subarachnoid hemorrhage in pregnancy. *Eastern Journal of Medicine*. 2013;1;18(2):76-80
15. Kutlesic M, Ilic-Mostic T, Ilic D, Kutlesic R. A case of eclampsia complicated by cerebral haemorrhage and iatrogenic hypopharyngeal oedema and haematoma. *Vojnosanitetski pregled*. 2017;74(9):884-90
16. Bateman BT, Schumacher HC, Bushnell CD, Pile-Spellman J, Simpson LL, Sacco RL, Berman MF. Intracerebral hemorrhage in pregnancy: frequency, risk factors, and outcome. *Neurology*. 2006;8;67(3):424-9
17. Stein-Fredbeck L, Rosenberg R, Frank R. A case report of maternal cerebral hemorrhage in preterm pregnancy. *Journal of Obstetric, Gynecologic & Neonatal Nursing*. 2017, 1;46(4):609-16
18. Tolefac PN, Awungafac NS, Minkande JZ. Spontaneous haemorrhagic stroke complicating severe pre-eclampsia in pregnancy: a case report in a resource-limited setting in Cameroon. *BMC Pregnancy and Childbirth*. 2018;18(1):1-4
19. Kaur T, Kaur A. Intracranial Hemorrhage in Eclampsia: An Unusual Case Report. *AMEI's Current Trends in Diagnosis & Treatment*. 2021;22;4(2):105-6
20. Kulsum K, Suryadi T. Critical Care Problem in a Case of Intracerebral Hemorrhage Due to Eclampsia and Its Ethics and Medicolegal Consideration. *Open Access Macedonian Journal of Medical Sciences*. 2022;26;10(C):67-71

Table No 1: Laboratory parameters in the peripartum period

Laboratory parameters	At admission	After delivery				
	Day 1	Day 2 (PND1)	Day 3 (PND2)	Day 4 (PND3)	Day 5 (PND4)	Day 6 (PND5)
Haematological						
Hemoglobin (g/l)	91	84	75	64	61	88
Total leucocyte count (10 ⁹ /L)	29.5 N88 L7	18 N85 L12	22.8 N90 L6	31.2 N94 L4	32.1 N91 L5	27.2 N92 L5
Differential count (10 ⁹ /L)						
Platelet (10 ⁹ /L)	130	75	41	60	62	60
Biochemical						
S.Urea/Creatinine mg/dl	33/1.2	62/2.2	63/2.3	77/3.2	77/3.5	88/2.7
S.Electrolytes (Na/K) [#] mEq/L	133/3.9	141/3.5	144/3.3	148/4.2	155/4.4	158/4.7
Total/Direct Bilirubin mg/dl	1.8/0.9	0.8/0.2	0.5/0.1	0.4/0.1	0.4/0.1	0.5/0.1
AST/ALT [*] IU/L	207/37	128/37	82/43	60/47	57/45	49/46
Total Protein/Albumin mg/dl	6.1/2.9	4.7/2.3	5.1/2.6	5.2/2.5	5.2/2.5	5.1/2.5
LDH ^{**} IU/L	1814	1322	1426	1049	1042	1133
Others	Peripheral smear- Microangiopathic haemolytic anaemia, 2.5% schistocytes, neutrophilic leucocytosis, decreased platelet Fibrinogen- 298 mg/dl FDP (Fibrin degradation products) - 1600 ng/ml PT/INR (Prothrombin time/International normalized ratio) - 15 sec/1.1 ; aPTT (activated partial thromboplastin time) -34 seconds D-Dimer- 4.6 mg/L Urine PCR (Protein creatinine ratio) - 3					

[#]**Na/K:** Sodium/Potassium; ^{*}**AST/ALT:** Aspartate amino transferase and alanine amino transaminase; ^{**} **LDH:** Lactate dehydrogenase

Table No.2: Summary of case reports/series on intracranial haemorrhages during pregnancy

Study	Age, obstetric index, and gestational age	Risk factors	Site of bleed and neurosurgical management	Obstetric management	Maternal outcome	Neonatal outcome
Rayes et al ⁶ , 2010	38 years G6P5 30 weeks	Severe preeclampsia HELLP* syndrome DIC**	Two large right frontal lobe bleed with midline shift and subarachnoid haemorrhage Decompressive craniectomy	Emergency LSCS [#] under GA ^{##}	Discharged after one month	
Gonullu et al ¹³ , 2011	Case 1 G6P5A1 28 weeks Case 2 25 years G1 28 weeks		Subarachnoid haemorrhage Subarachnoid haemorrhage	Elective LSCS [#] at 36 weeks due premature rupture of membrane Vaginal delivery	 Expired on day five of hospitalization	Healthy Still born
Ghaly et al ⁷ , 2012	32 years G2P1 34 weeks	Eclampsia HELLP* syndrome DIC**	Right frontal hematoma and intraventricular haemorrhage Right frontotemporal craniotomy	Emergency LSCS [#] under GA ^{##}	Discharged after three weeks	Healthy
Verma et al ² , 2015	35 years G2 32 weeks	Severe preeclampsia	Left parieto-occipital bleed with midline shift Medical management	Emergency LSCS [#] under GA ^{##}	Expired on Day 5 after delivery	Healthy
Fredbeck et al ¹⁶ , 2017	28 years G2P1 34 weeks		Right posterior cerebellar bleed Craniotomy and hematoma evacuation	Emergency LSCS [#] under GA ^{##}	Discharged after 7 days	Healthy
Kutlesic et al ¹⁴ , 2017	22 years G1	Eclampsia	Right occipital lobe hematoma Medical management	Emergency LSCS [#] under GA ^{##}	Discharged after 15 days	Healthy
Tolefac et al ¹⁷ , 2018	32 years G4P3 34 weeks	Severe preeclampsia	Left parietal bleed Medical management	Emergency LSCS [#] under spinal	Discharged after 10 days	Healthy

Pahwa et al ¹⁸ ., 2020	25 years G1 35+3 weeks	Eclampsia	Right capsule-ganglionic and thalamic bleed with midline shift Posterior decompressive craniotomy	Emergency LSCS [#]	Discharged after 22 days	Healthy
Kulsum et al ¹⁹ ., 2022	23 years G2P1L1	Eclampsia HELLP* syndrome	Subarachnoid haemorrhage, hematoma in bilateral parietal and occipital lobes Medical management	Emergency LSCS [#]	Terminal stage with poor E1V1M1	Not available
Present case 2022	25 years G2P1L1 39 weeks	Eclampsia HELLP* syndrome DIC**	Left frontal small bleed, intraventricular haemorrhage, diffuse subarachnoid haemorrhage, multiple diffuse petechial haemorrhages in both hemispheres Medical management	Normal vaginal delivery	Expired on Day 6 after delivery	Fresh still born

*HELLP – Haemolysis elevated liver enzymes and low platelet count; **DIC- disseminated intravascular coagulation; # LSCS- lower segment caesarean section, ##GA- general anaesthesia,