

## A CASE REPORT ON TALONAVICULAR ARTHRITIS

---

### **ABSTRACT:**

**INTRODUCTION:** Talonavicular Arthritis is a condition in which (talonavicular joint undergoes deform) arthritis occurs in the talonavicular joint leading to joint inflammation and severe pain. Talonavicular arthritis can be caused by the conditions involving cartilage damage .The symptoms of talonavicular arthritis includes swelling,pain and stiffness. The early diagnosis is most important to identify joint injury by X-rays ,CT scans, MRI. Medical treatment for talonavicular arthritis includes analgesics and NSAID's. Surgical procedures like arthrodesis can be performed when medical treatment fail to improve the conditions.

**CASE PRESENTATION:** The patient was 64 years old male patient who has classical presentation of talonavicular arthritis .He had complained of pain in the left foot and pain on weight bearing since a fall 6 years back. Radiographs and Computed Tomography (CT) scans revealed Arthritis of talonavicular bone MRI revealed the mild arthritic change in talonavicular joint .Patient have undergone arthrodesis of talonavicular joint.

**CONCLUSION:** Talonavicular arthrodesis is one of the most effective procedures for the treatment of traumatic talonavicular arthritis by providing the functional improvement and by reducing the pain .

---

**KEY WORDS:** Talonavicular Junction ,Talonavicular Arthritis , Arthrodesis.

### **INTRODUCTION:**

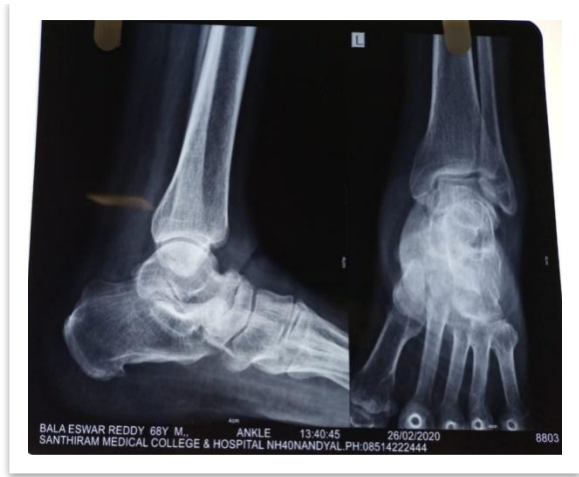Talonavicular joint is a ball and socket type of joint subjected to multidirectional forces with multi-axis forming a part of the medial column joint complex that provides stability during the gait cycle[1].

Any damage to the cartilages causing inflammation, pain and stiffness leading to the talonavicular joint causes Talonavicular arthritis .The talonavicular arthritis is associated with classical symptoms like severe pain, swelling and stiffness restricting movements in the joint[9] . Talonavicular arthritis can be caused due to any potential conditions like primary Osteoarthritis [8] ,infection in the joint ,inflammatory diseases ,trauma and injury to the Talonavicular joint such as navicular bone fracture. Avascular necrosis of necrosis talus and navicular bone[3].This condition can be promptly diagnosed by CT scan , MRI scan ,X-rays to identify the degree of deformity .This condition can be treated primarily with analgesics and NSAID's [3].If the condition is not subsided with medical treatment then widely approved surgical procedure like arthrodesis can be done .Here, We report a case of Osteoarthritis of talonavicular joint accompanied by traumatic injury of talus and navicular bone being treated by surgical manifestation such as isolated arthrodesis of talonavicular joint. The necessity for the fusion of atonavicular joint arises from the isolated arthritis of post-tramautic etiology [5] .The mini plate fusion is superior biomechanically than to fusion with screws and staples. The lateral incision is made in this condition to reduce infections and it allows reliable pain reduction and morbidity of the foot.

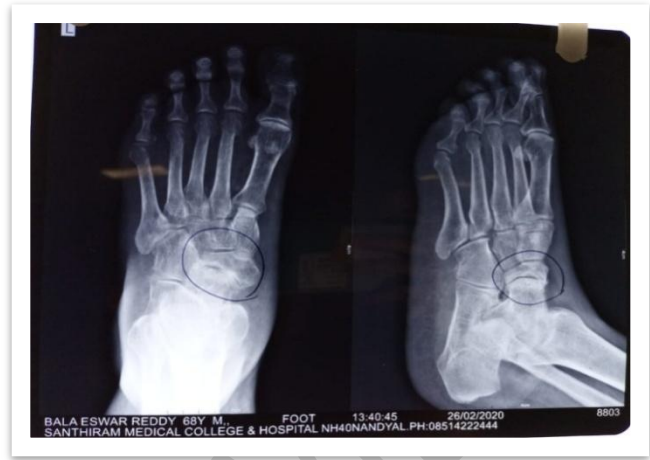#### **CASE PRESENTATION:**

A male patient of age 64 years old was reported to Orthopedic department with complaints of pain in left foot and pain on weight bearing since 6 years .The patient have the history of Hamorrhoidectomy done 2 years back and excision of cyst on chest. Patient has past medical history of Hypertension and Diabetes Mellitus since 7 years and is on regular medications ,On general examinations patient was presented with Grade-IV mallamapati Lab investigations were notable for Random blood Glucose of 158mg/dl and fasting blood glucose of 118mg/d .The chest X-ray revealed mild Cardiomegaly subsequently radiographic examinations such as CT scan & X-ray of the foot revealed deformity in the talonavicular joint and misalignment of the joint .The clinical and radiological findings confirms the talonavicular arthritis .The patient was given with oral analgesics and advised for the arthrodesis surgery of the left talonavicular joint.

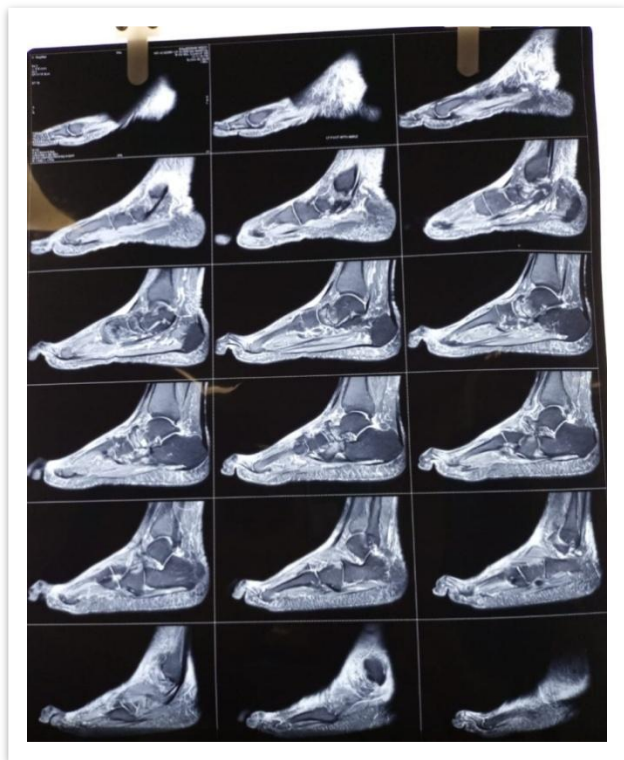
**X-ray :**



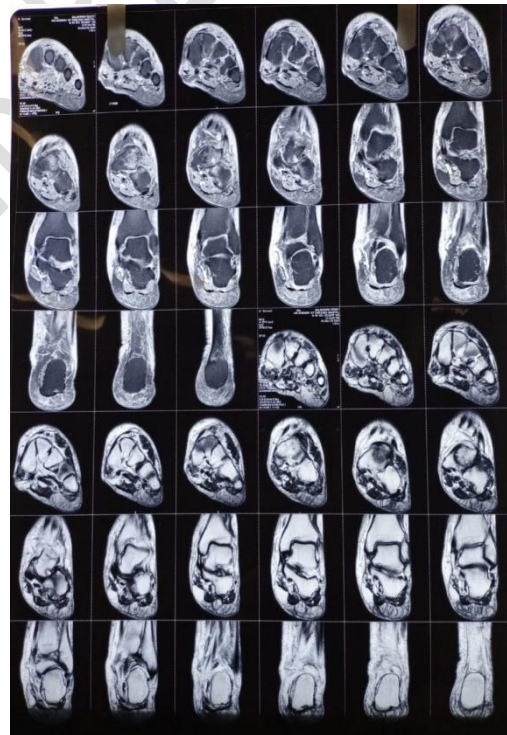
**Figure 1. Lateral Radiograph**



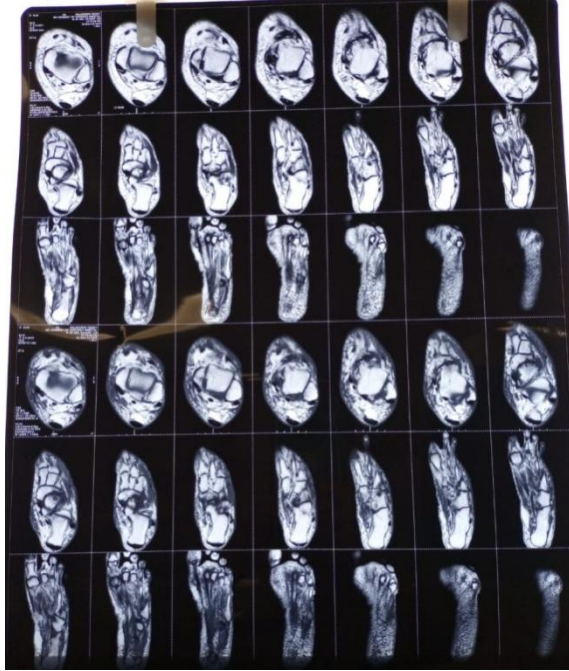
**Figure 2. Computed Tomography :**



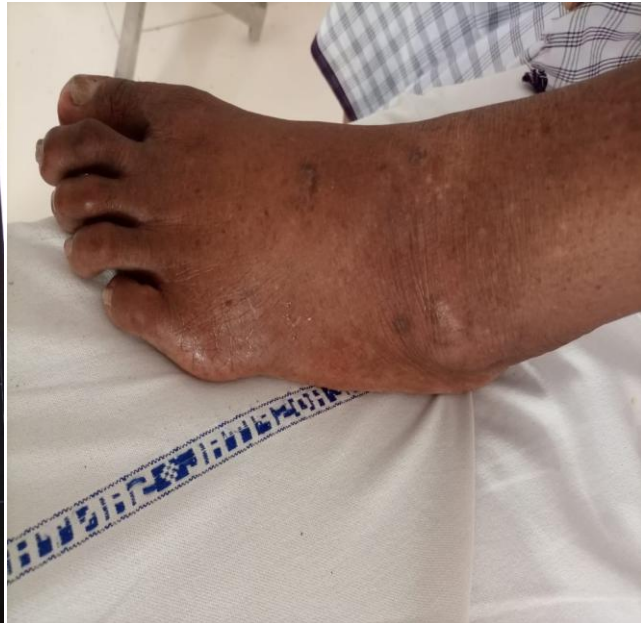**Figure 3. X-ray image of foot**



**Figure 4. X-ray**



**Figure 5. MRI scan image**



**Figure 6. Left ankle swelling**

## **DISCUSSION:**

Talonavicular arthritis is the condition caused by various potential conditions such as inflammatory diseases, Primary Osteoarthritis, infections, Traumatic injury to the Talonavicular joint [3]. It is associated with triad of symptoms of severe pain, swelling and stiffness of joint. The exact cause of talonavicular arthritis in this patient is traumatic injury occurred 6 years back. The CT-scan and X-ray of the foot are the most used technique to visualize the degree of deformity. This condition can usually be treated with oral analgesics and NSAID's but surgical procedure like arthrodesis is more prominent for pain reduction and morbidity of the foot. In this patient Arthrodesis was advised for the symptomatic relief and improvement of the patient condition.

## **CONCLUSION:**

It is important to recognize this injury as early diagnosis and management favours good outcomes. Talonavicular arthrodesis is one of the effective procedures for the treatment of traumatic talonavicular arthritis due to an

united navicular bone without abnormal movement both in providing pain relief and functional improvement.

#### REFERENCES:

1. Bilal M. Barkatali, Mantravadi Sundar; *ISOLATED TN ARTHRODESIS FOR TN ARTRITIS: A follow up study*. The Journal of foot and ankle Surgery .53(2014)8-11.
2. Kanzaki, N., Nishiyama, T., Fujishiro, J. et al., *OSTEOARTHRITIS OF TALONAVICULAR JOINT WITH PSEUDOARTHRITIS OF NAVICULAR BONE: A Case report*. J Med case reports 5,547 (Aug 2011). DOI-10.1186/1752-1947-5-547.
3. Adam Ajis, Nicola Maffulli, et al. *CHRONIC RUPTURE OF TENDON ACILIS; TN ARTRITIS*; The London foot ankle clin. doi-1016/j.fcl.2007.07.007.
4. Popelka S, Homadka R, Vavrik P, et al: *ISOLATED TALONAVICULAR ARTHRODESIS IN PATIENTS WITH RHEUMATOID ARTHRITIS OF LEFT FOOT AND TIBIAL POSTERIOR TENDON DYSFUNCTION*. BMC Musculoskeletal Disord .2010,11-238-10.1186/141-2774-11-38.
5. Swaroop VT, Wenger DR, Mubarak SJ: *Talonavicular fusion for dorsal subluxation of the navicular in resistant club foot*. Clin Orthop Res .2009,467:1314-1318 doi-10.1007/11999-009-0758-1.
6. Camasta CA, Menke CR, et al: *A REVIEW OF TALONAVICULAR JOINT ARTHRODESIS FOR FLEXIBLE PER VAGUS DEFORMITY*. J Foot Ankle Surgery .2010,49:113-118. doi-10.1053/j.jfas.2009.08.016.
7. Rammelt, S., Marti, RK & Zwipp, H. *Arthrodesis of the Talonavicular joint*. *Ortopede* 35,428-434 (Apr.2006) doi.10.1007/s00132-005-0868-8.
8. Matar HE, Iyengar KP, Toh EM –*PRIMARY SEPTIC ARTHRITIS OF TNJ*. BMJ Case Rep 2014; doi-10.1136/bcr-2013-203346.

**9.Sally Wright ,Matthew James welek, Helen Cohen , Don't put your foot in it :A CASE OF TALONAVICUAR SEPTIC ARTHRITIS ,BMJ case Rep2018;doi-10.1136/bcr-2017-222912.**

**10.Robert H. Seinberg .et .al .TALONAVICUAR JOINT ARTHRITIS ;Florida Sport medicine .com.**

UNDER PEER REVIEW