

## **Case study**

### **RETAINED BONE FRAGMENT MASQUERADING AS FOREIGN BODY CAUSING SECONDARY INFERTILITY**

#### **ABSTRACT**

**BACKGROUND** - With advent of multiple options, safer abortion practices and easily available facilities, termination of pregnancy in India is slowly on rising trend. Termination of pregnancy (abortion) is a reasonably safe procedure when properly performed. Pregnancy termination is associated with complications like haemorrhage and uterine perforation which are immediate and delayed complications like Asherman's syndrome, menstrual disturbances and quite commonly secondary infertility. However, even after being performed with due precautions, complications may occur. Retention of fetal products following a mid-trimester abortion is a rare complication of abortion which can then result in secondary infertility.

Retained foetal bone fragments may cause acute pelvic inflammatory disease in rare cases regardless of the time interval after abortion. This condition can also present as recurrent vaginitis or endometritis refractory to empirical antimicrobial treatment. In such cases, foreign body in uterine cavity should be kept in mind. Such patients should primarily be evaluated by ultrasonography which has substantial clinical importance in differential diagnosis of these cases.

#### **CASE –**

We are here presenting a case of 25 year old young women who underwent an abortion in 14th week of gestation due to anencephaly in the fetus and who then failed to conceive for the next 5 years. Transvaginal Ultrasonographic examination suggested the presence of ? foreign body ? endometrial calcification in the upper uterine cavity which was removed hysteroscopically. The patient was able to conceive after the hysteroscopic removal of bony fragments. Retained bony fragments from a previous mid-trimester abortion should thus be kept in the list of differentials of secondary infertility.

#### **OBJECTIVES –**

We examined the causative factors, radiographic abnormalities, treatment strategies and clinical recovery in secondary infertility

#### **CONCLUSIONS –**

Secondary infertility due to retained foetal bones is a rare entity which an obstetrician should keep in mind while evaluating such patients with a prior history of mid-trimester abortion. Transvaginal ultrasound is an effective modality for initial diagnosis. Hysteroscopy is effective for both confirmation and treatment. Fertility is expected to return for most of such patients. All patients with second-trimester abortion should have a trans-vaginal ultrasound in the post-abortion period to confirm complete evacuation of all the products of conception.

## **KEYWORDS –**

Foreign body, secondary infertility, ultrasonography, hysteroscopy, bony fragment

## **INTRODUCTION –**

After an abortion, the presence of intrauterine bone structures is an uncommon occurrence. The precise occurrence is uncertain. In developing nations, illegal abortion is one of the most under-reported health concerns. Retained products of pregnancy are a relatively uncommon complication of unsafe abortion. In patients undergoing diagnostic hysteroscopy, the prevalence is around 0.15 percent. There are no obvious signs or symptoms in the patients. Subfertility, irregular uterine bleeding, lower abdominal pain, abnormal vaginal discharge, dyspareunia, dysmenorrhoea, and spontaneous passage of bony fragments were all studied extensively.

Conceiving and giving birth have become safer as a result of advances in medicine, both in terms of diagnosis and care. The right to terminate or abort a pregnancy due to foetal abnormalities prevents the unborn child and the family from pain that would have resulted if the child had been born. Even though terminating a pregnancy is a safe procedure, it can cause immediate complications such as haemorrhage, uterine perforation, and cervical injury, as well as late complications such as infections, bleeding, menstrual irregularities, and uterine synechiae. Since 50 percent of patients seeking surgical termination are young adults, there is a risk of secondary infertility as a result of a complicated abortion.

Few bits of the foetus may unintentionally be left behind in the uterine cavity if the abortion is performed in the second trimester or if the foetus are removed by destructive means. Pelvic pain, irregular bleeding, infection, dyspareunia, or even the passage of foetal parts per vaginum could all occur in this situation. Retained foetal parts may also induce secondary infertility in women. In the majority of such patients, retained foetal parts are likely to cause a uterine reaction in the form of vaginal discharge and/or discomfort, as well as secondary infertility.

We present a case of secondary infertility caused by foetal bone fragments remaining in the uterine cavity. The patient may have no symptoms or may have symptoms such as dysmenorrhoea, vaginal discharge, or abnormal uterine bleeding. The diagnosis and treatment of such a case can be accomplished successfully using hysteroscopic techniques.

## **CASE PRESENTATION -**

A 25-year-old woman was referred to the AVBRH Hospital's Gynecology out-patient clinic for infertility assessment and treatment. A detailed medical history showed that she was suffering from secondary infertility.

She had been suffering from dyspareunia for two months. She had a history of second trimester abortion. On an ultrasonographic test two years ago, the foetus was discovered to have anencephaly. The pregnancy was terminated, and labour was induced. Over the period

of the past five years, she consulted multiple physicians and received numerous treatments, but was unsuccessful in conceiving. She was then referred to our hospital. Both couples were exposed to infertility investigations. The man's sperm count was normal. There were no abnormalities in the woman's hormonal profile.

The patient appeared to be of average build on physical inspection. Her vital signs were all within normal limits. Pelvic examinations were performed vaginally and abdominally and found to be unremarkable in both cases. Her Transvaginal sonography showed the presence of linear calcific density hyperechoic area measuring approx 12 mm noted embedded within the upper endometrium, horizontally oriented, shows twinkling artifact on color doppler imaging which was suspected to be foreign body or endometrial calcification. The findings were confirmed by the consultant radiologist of our hospital. Diagnostic Hysterolaparoscopy with removal of the foreign body was planned.

A procedure was performed under general anaesthesia that revealed the existence of a cylindrical structure in the uterus that appeared like a miniature long bone fragment under vision. Dilation and curettage was performed to remove the fragments under vision. The bony piece fragment was retrieved from the patient's uterus. In the post hysterolaparoscopy period, the patient was kept under cover of intravenous antibiotics for 24 hours. The extracted material was sent for histopathological examination and was reported by the pathologist as bone. On histopathological examination single, irregular, whitish thread like tissue piece measuring 0.5 x 0.5 cm. Section from given specimen shows histopathological features suggestive of bone trabeculae of normal morphology probably retained products of conception. Her first check-up took place after she had her first period. Following that, monthly follow-ups were carried out. Her menstrual cycle was unaffected by the operation, and five months after the hysteroscopic removal of bone fragments, she was able to conceive. As a result, the preserved foetal bony fragments confirmed our suspicions of secondary infertility.

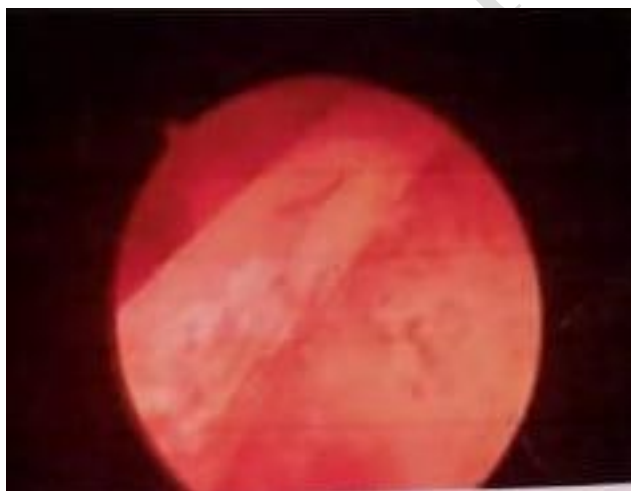


FIGURE 1 : LONGITUDINAL PROFOUND ECHOIC STRUCTURE FILLING THE CERVICAL CANAL AND ENDOMETRIAL CAVITY

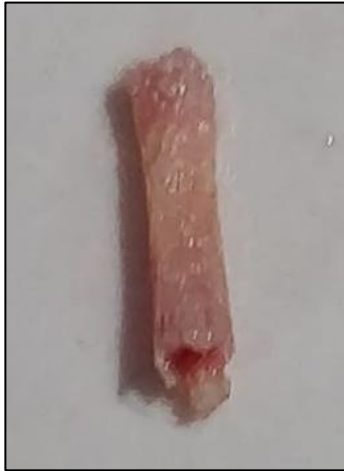

FIGURE 2 SHOWING : CORAL-LIKE THIN CALCIFIED BONY MATERIAL ON HYSTERESCOPIC EVALUATION

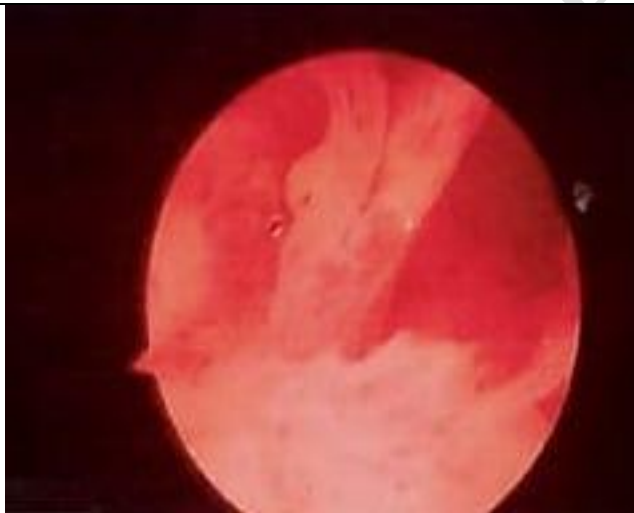

FIGURE 3 SHOWING : HYSTEROSCOPICALLY RETRIEVED INTRAUTERINE FETAL BONES

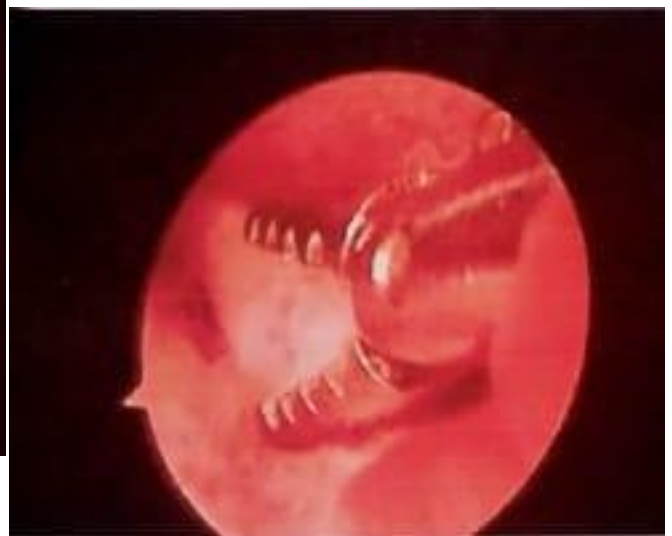

FIGURE 4 SHOWING : HYSTEROSCOPIC IMAGE SHOWING THE WHITISH COLORED BONY STRUCTURE

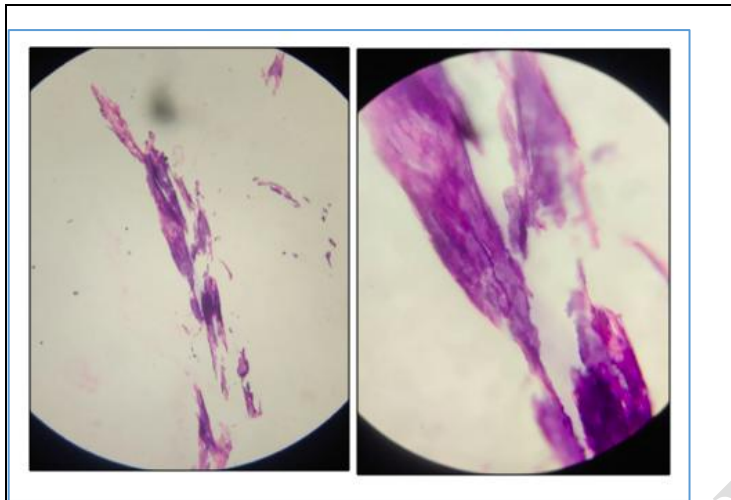


FIGURE 5. HISTOPATHOLOGIC IMAGE SHOWING BONY TRABECULAE

## DISCUSSION –

Endometrial ossification has been reported in many studies. It's thought to be mostly caused by foetal bone fragments, but it may also be caused by metaplasia of mature endometrial stromal cells in response to chronic inflammation or trauma in some cases.

Metaplasia of mature endometrial stromal cells into bony tissue occurs in response to chronic inflammation or trauma, according to the Roth and Taylor hypothesis. The bone fragments, according to the researchers, trigger infertility by serving as an intrauterine device, increasing endometrial prostaglandins and preventing the implantation phase.

In a related case of infertility, Naftolin came to the conclusion that "the bone remains had been functioning as an intrauterine contraceptive system and that a pregnancy following their removal is more than coincidence." Bone fragments held within the uterine cavity might stimulate myometrial contractions, which may further embed the fragments deep into the myometrium. Thus, spontaneous expulsion becomes less likely with passing time and normal endometrium can then overgrow the deeply embedded fragments.

Many women with retained fetal bone will have symptoms of menometrorrhagia, dysmenorrhea, vaginal discharge, pelvic pain and spontaneous elimination of bony fragments in the menses in addition to their infertility[1]. Lewis et al. measured menstrual blood volume and prostaglandin E2 concentrations before and after the removal of retained fetal bones in a woman with infertility and menorrhagia. He found the menstrual volume and total prostaglandin concentration decreased by 50% after the retained bone was removed[2].

A unusual complication of induced abortion, spontaneous intrauterine foetal death, and missed abortion is prolonged intrauterine retention of foetal bone sections. Although abortion is a safe procedure when done correctly, it does come with its own set of risks. Incomplete uterine evacuation can lead to a variety of problems, including the uncommon complication of secondary infertility, as we've seen in this case. In order to clarify the potential cause of infertility in such situations, a variety of theories have been suggested in the literature. The hypothesis proposes that retained foetal tissues from a previous incomplete abortion can stimulate dystrophic calcification and lead to an ossification of the foetal tissue thereby resulting in bone formation. Chronic inflammation and tissue destruction have also been postulated to stimulate heterotopic bone formation in mature uterine stroma. Both the scenarios are highly unlikely in the case presented here. The extraction of a relatively large tubular bone resembling a long bone of foetus was indicative of its origin from being from a foetus and not because of dystrophic or heterotrophic calcification. Also, the histopathologic examination of the extracted fragments confirmed the diagnosis.

Retained foetal bone has been thought to act as an intrauterine contraceptive device altering the uterine milieu and preventing implantation. Other hypothesised as to why retained foetal bones lead to infertility include prevention of implantation because of obliteration of the uterine cavity and toxicity of bone particles on an implanted embryo [3].

Whatever the etiology might be, obtaining a thorough history is a must while evaluating a patient of secondary infertility. TVS must be done in all cases to evaluate the completeness of evacuation and in case any suspicious echoes are seen hysteroscopy should be planned.

Hysteroscopic removal of the bony pieces followed by curettage should be done in a patient with retained foetal bones as it has been proven to be a sufficient treatment of such infertility. In the present case too, after removal of the bone pieces, the menses resumed, and the patient conceived in six months' time.

Recognition of foreign bodies in the uterine cavity is of great importance for successful treatment of secondary infertility: e.g., a piece of intrauterine contraceptive (after a removal failure), suture after cesarean section, or cylindrical and flat small bones after abortions. Kazakov et al. reported 69 foreign bodies that were removed with a wire loop resectoscope during 1992–1993 [4]. Sixty-one of the foreign bodies were intrauterine devices. The remaining eight women (11.9%) underwent fetal bone removals. Transcervical resection of foreign bodies (TCRF) is safe and efficient. Sufficient cervical canal distension, selection of equipment and methods to be used are important for successful TCRF [4]. As a non-invasive and effective monitoring method, B mode ultrasonography is the first choice to monitor for TCRF.

We believe that the present report adds to the pool of knowledge of practising obstetricians and makes them aware about considering retained bones from previous abortion in the list of differentials of secondary infertility.

The number of pregnancy terminations being done for various reasons are on the rise. Even though the safety quotient has risen over the years, complications still do occur. As in our case, they may remain asymptomatic making it difficult to diagnose. It acts like an

intrauterine contraceptive device and prevents conception which is proven by the fact that the lady conceived within four months of removal of the bone pieces. Cases of secondary infertility should be dealt with suspicion and the hysteroscopy should be performed for accurate diagnosis and treatment in the same sitting. The presence of intrauterine bony structures has been reported in the literature. These structures are most commonly believed to be due to retained fetal bone fragments, but some cases may be due to metaplasia of mature endometrial stromal cells, in response to chronic inflammation or trauma.

It is interesting to note that the presence of retained fetal bones may be more common in cases of uterine anomalies[5,6]. In these cases, care must be taken to understand the anomaly before instrumentation. This will minimize the risk of uterine perforation and will help to facilitate complete removal of the fragments.

Today, many studies emphasize the role of transvaginal sonographic diagnosis of the female genital tract as a first line diagnostic test rather than the traditional laparohysteroscopy. A simple, ultrasound-based approach to investigate the infertile patient can be used effectively as an initial examination modality during the couple's work-up. A regular myometrial-endometrial interface and homogeneous endometrial structure on TVS congruent with the phase of the menstrual cycle indicate a normal endometrium and preclude the need for diagnostic hysteroscopy. TVS may be used as the initial diagnostic procedure to select patients for hysteroscopy.

#### CONCLUSIONS -

All patients with infertility, dysfunctional uterine bleeding, dysmenorrhea, or other signs related to a pregnancy or pregnancy termination should be evaluated for retained foetal bones[7,8]. TVS should be performed in all women presenting as secondary infertility who had a prior pregnancy that progressed past 11 weeks gestation and resulted in spontaneous or surgical abortion should have a transvaginal sonogram done. Prolonged retention of intrauterine bone is a recognized cause of secondary infertility. TVS can also be used to track patients who have had their bony fragments surgically removed. Few bony fragments may be lodged in the endometrium or myometrium, making curettage difficult to identify. Because of the accessibility of care and the favourable postoperative prognosis, all women with secondary infertility who have had an abortion should have a thorough transvaginal sonographic review of the endometrium. This examination would not only expose irregular endometrial pathology, but it may also reveal uterine abnormalities that were previously undetected. In both determining the diagnosis and extracting bony fragments, a diagnostic hysteroscopy accompanied by an operative procedure using a wire loop resectoscope is invaluable. The reintroduction of the hysteroscope to record that the cavity is clear after attempts at bone removal are complete is an integral part of the procedure. Following the removal of the bony fragments, it is expected that fertility will be regained and symptoms will improve.

#### REFERENCES-

1. Chervenak FA, Amin HKo, Neuwirth RS (1982) Symptomatic intrauterine retention of fetal bones. *Obstet Gynecol* 59 [Suppl]:58S–61 8

2. Lewis V, Khan-Dawood F, King M, Beckmann C, Dawood MY (1990) Retention of fetal bone increases menstrual prostaglandins. *Obstet Gynecol* 75:561–563
3. First trimester abortion: a rare cause of intrauterine bony spicules. Singla A, Gupta B, Guleria K. *Case Rep Obstet Gynecol*. 2012;2012:701021. [[PMC free article](#)] [[PubMed](#)] [[Google Scholar](#)]
4. Kazakov BJ, Khankoev IM, Pererva W (1994) Results of hysteroscopic method of foreign body removal out of the uterus cavity. *J Am Assoc Gynecol Laparosc* 1:S16
5. Melius FA, Julian TM, Nagel TC (1991) Prolonged retention of intrauterine bones *Obstet Gynecol* 78:919–921
6. Chervenak FA, Amin HKo, Neuwirth RS (1982) Symptomatic intrauterine retention of fetal bones. *Obstet Gynecol* 59 [Suppl]:58S–61 8
7. Wong SF, Lam MH, Ho LC (2002) Transvaginal sonography in the detection of retained products of conception after first-trimester spontaneous abortion. *J Clin Ultrasound* 30:428–432
8. Usha Kiran TS, Bhal PS (2002) The potential consequence of early recognition and treatment of retained fetal bony fragments. *J Obstet Gynaecol* 22:443–444

UNDER PEER REVIEW