

Case report

Reticular Oral Lichen Planus of the Jugal Mucosa: A Classical Presentation

Abstract

Reticular oral lichen planus (OLP) is a chronic inflammatory lesion that affects the mucosa of the oral cavity. Being in most cases asymptomatic, it is often detected incidentally during routine oral examination. This report presents the case of a 38-year-old male who consulted for mild burning sensation in his mouth while consuming acidic foods and liquids. Intraoral examination revealed bilateral reticular OLP on the jugal mucosa which diagnosis was confirmed histopathologically. Treatment with topical corticosteroids led to significant symptoms improvement. Yearly long-term follow-up was requested to observe the disease activity and to rule out any malignant transformation.

Keywords: Oral lichen planus, reticular, Wickham striae, biopsy, histological examination, topical corticosteroid

Introduction

Oral lichen planus (OLP) is a chronic inflammatory disorder that affects the mucosa of the oral cavity. Clinically, it may occur in many forms (reticular, erosive/ulcerative, papular, plaque-like, atrophic, and bullous). Reticular OLP is the most common and is characterized by fine, white, linear and lace-like lesions referred to as Wickham striae [1, 2]. Being most of the time asymptomatic, the reticular OLP is often incidentally detected during routine oral examination [1]. For definitive diagnosis, a biopsy and histological examination of lesional tissue are performed [3].

In this report, a case of a classical reticular OLP is presented.

Case presentation

A 38-year-old male was referred to our Department of Oral Medicine and Maxillofacial Radiology at the Lebanese University with a chief complaint of burning sensation in his mouth whilst consuming acidic foods and liquids, since approximately eight months. Patient's medical history was non-contributory except having suffered itchy red lesions on the ankle, right knee, genital, and mental regions a year back. He was a heavy smoker (60 cigarettes per day) since the age of 17 years. Intraorally, the patient presented bilateral non-scrapable intercrossed fine white lines on

the top of a papular rash located on the jugal mucosa, typical of the Wickham striae (Figure 1).

The aspect of the lesions, the accompanying symptoms, and the history of cutaneous lesions supported the preliminary diagnosis of reticular OLP.

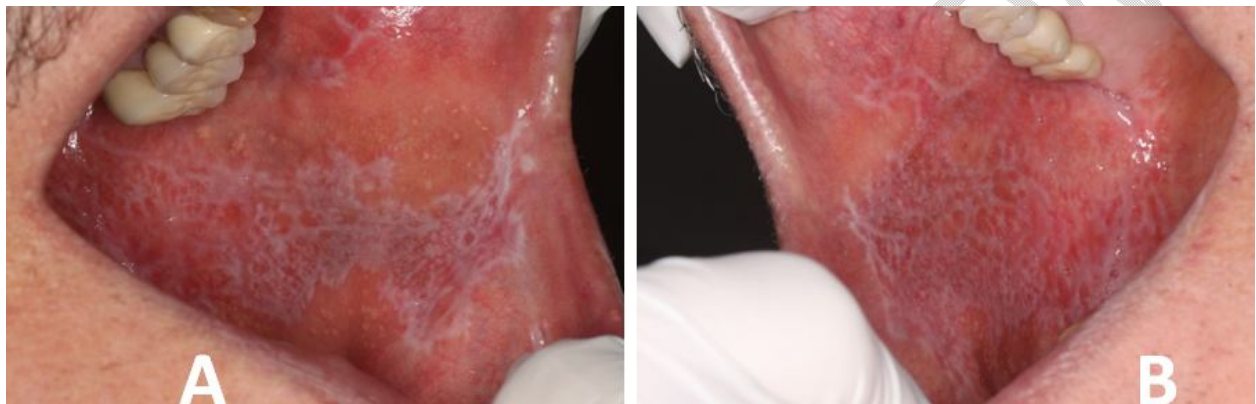


Figure 1: Intraoral photographs showing the bilateral (A: left; B: right) jugal lesions

Complete blood test including hepatitis C serology, which is a possible trigger for lichen planus, was done. Results were normal but HCV antibody was found positive.

The lesions were biopsied and sent for histological assessment which revealed perturbation of the integrity of the basal layer, lymphocytic infiltration in the lamina propria, just below the epithelium, and the absence of epithelial dysplasia; moreover, at the epithelial level, irregular acanthosis and formation of foci of

parakeratosis were observed. This histological aspect was consistent with OLP.

A topical corticosteroid was prescribed twice daily for 2 months and symptoms improvement was obtained. Regular yearly long-term follow-up was requested to monitor the disease activity and to rule out any malignant transformation.

Discussion

Lichen planus (LP) is an immune-mediated inflammatory disorder which affects the skin, the nails, the scalp, the lips, and other mucosal surfaces including the oral mucosa, the esophagus, the pharynx, and the genital mucosa (the glans penis, the vulvar and vaginal mucosa, the labia majora, and the labia minora) [4].

OLP is more frequent than the cutaneous and genital variants, with a prevalence of 1% to 4% of adults worldwide [5]. It mainly affects adults with age ranging between 30 and 60 years. A slight female predilection (1.5:1) has been reported [6].

OLP etiology remains unclear; stress, drugs (antimalarials, ACEIs, thiazide diuretics, NSAIDs, quinidine, beta-blockers, and tumor necrosis factor alpha (TNF α) inhibitors), dental fillings, genetic factors, immunity, and hyper-sensitivity reactions have been suggested to be contributing factors to its pathogenesis [7].

Additionally, contact allergens and viruses, especially the hepatitis C virus (HCV), have been reported to be associated with LP development [8-10]. Many studies have considered OLP as T cell-mediated autoimmune condition, in which cytotoxic CD8⁺ T-cells that release different cytokines like TNF α and interleukin-12 (IL-12) leading to the perturbation of the lining epithelial basement membrane integrity [11].

The World Health Organization (WHO) Collaborating Center for Oral Cancer has defined OLP as an oral potentially malignant disorder (OPMD) [12]. However, OLP transformation risk has remained a controversial topic [13].

Although the clinical feature of reticular OLP is specific, a wide differential diagnosis must be considered. It includes in the first place lichenoid mucositis (drug related or caused by the contact with restorative dental materials) which may also present clinical and histological presentations that mimic reticular OLP, leukoplakia, lupus erythematosus, pemphigus vulgaris, and mucous membrane pemphigoid [1, 7].

If asymptomatic, reticular OLP does not necessitate treatment and routine periodically assessments are essential to observe the disease activity and to rule out any potential malignant transformation [1, 7]. When symptomatic, like in the discussed case,

topical corticosteroids are used. They can be applied twice daily for 1 to 2 months, and then administered as required. Intralesional steroid injections or systemic corticosteroids are reserved for patients with severe painful cases failing to respond to topical therapy [1, 4, 14].

Conclusion

Although reticular OLP presents characteristic feature and good prognosis, it is essential for the dental practitioner to make an accurate and timely diagnosis, to provide the appropriate treatment in case of symptomatic lesion, and to request regular long-term follow-up to monitor the disease activity and to rule out any malignant transformation.

Patient's Consent

Written informed consent was obtained from the patient for publication of this case report.

COMPETING INTERESTS DISCLAIMER:

Authors have declared that they have no known competing financial interests OR non-financial interests OR personal relationships that could have appeared to influence the work reported in this paper.

References

1. Cox T, Woodhead J, Nelson BL. Reticular oral lichen planus. *Head Neck Pathol.* 2020; 14(1): 192-194.
2. Au J, Patel D, Campbell JH. Oral lichen planus. *Oral Maxillofac Surg Clin North Am.* 2013; 25(1): 93-100.
3. Kumaraswamy KL, Vidhya M, Rao PK, Mukunda A. Oral biopsy: oral pathologist's perspective. *J Cancer Res Ther.* 2012; 8(2): 192-198.
4. Boch K, Langan EA, Kridin K, Zillikens D, Ludwig RJ, Bieber K. Lichen planus. *Front Med (Lausanne).* 2021; 8: 737813.
5. Boyd AS, Neldner KH. Lichen planus. *J Am Acad Dermatol.* 1991; 25(4): 593-619.
6. Le Cleach L, Chosidow O. Clinical practice. Lichen planus. *N Engl J Med.* 2012; 366(8): 723-732.
7. Vlad CS, Vlad DC, Popescu R, Borugă VM, Istrate SL, Flangea C, et al. Oral lichen planus - case report. *Rom J Morphol Embryol.* 2020; 61(2): 563-567.
8. Asarch A, Gottlieb AB, Lee J, Masterpol KS, Scheinman PL, Stadecker MJ, et al. Lichen planus-like eruptions: an emerging side effect of tumor necrosis factor-alpha antagonists. *J Am Acad Dermatol.* 2009; 61(1): 104-111.

9. Alaizari NA, Al-Maweri SA, Al-Shamiri HM, Tarakji B, Shugaa-Addin B. Hepatitis C virus infections in oral lichen planus: a systematic review and meta-analysis. *Aust Dent J.* 2016; 61(3): 282-287.
10. Robledo-Sierra J, van der Waal I. How general dentists could manage a patient with oral lichen planus. *Med Oral Patol Oral Cir Bucal.* 2018; 23(2): e198-e202.
11. Chaitanya NC, Chintada S, Kandi P, Kanikella S, Kammari A, Waghmare RS. Zinc therapy in treatment of symptomatic oral lichen planus. *Indian Dermatol Online J.* 2019; 10(2): 174-177.
12. Warnakulasuriya S, Johnson NW, van der Waal I. Nomenclature and classification of potentially malignant disorders of the oral mucosa. *J Oral Pathol Med.* 2007; 36(10): 575-580.
13. Rosa EA, Hurtado-Puerto AM, Falcão DP, Brietzke AP, De Almeida Prado Franceschi LE, Cavalcanti Neto FF, et al. Oral lichen planus and malignant transformation: The role of p16, Ki-67, Bub-3 and SOX4 in assessing precancerous potential. *Exp Ther Med.* 2018; 15(5): 4157-4166.
14. Ioannides D, Vakirlis E, Kemeny L, Marinovic B, Massone C, Murphy R, et al. European S1 guidelines on the management of lichen planus: a cooperation of the European dermatology

forum with the European academy of dermatology and venereology. J Eur Acad Dermatol Venereol. 2020; 34(7): 1403-1414.

UNDER PEER REVIEW